This is a digital copy of a book that was preserved for generations on library shelves before it was carefully scanned by Google as part of a project to make the world's books discoverable online.

It has survived long enough for the copyright to expire and the book to enter the public domain. A public domain book is one that was never subject to copyright or whose legal copyright term has expired. Whether a book is in the public domain may vary country to country. Public domain books are our gateways to the past, representing a wealth of history, culture and knowledge that's often difficult to discover.

Marks, notations and other marginalia present in the original volume will appear in this file - a reminder of this book's long journey from the publisher to a library and finally to you.

**Usage guidelines**

Google is proud to partner with libraries to digitize public domain materials and make them widely accessible. Public domain books belong to the public and we are merely their custodians. Nevertheless, this work is expensive, so in order to keep providing this resource, we have taken steps to prevent abuse by commercial parties, including placing technical restrictions on automated querying.

We also ask that you:

+ *Make non-commercial use of the files* We designed Google Book Search for use by individuals, and we request that you use these files for personal, non-commercial purposes.
+ *Refrain from automated querying* Do not send automated queries of any sort to Google's system: If you are conducting research on machine translation, optical character recognition or other areas where access to a large amount of text is helpful, please contact us. We encourage the use of public domain materials for these purposes and may be able to help.
+ *Maintain attribution* The Google "watermark" you see on each file is essential for informing people about this project and helping them find additional materials through Google Book Search. Please do not remove it.
+ *Keep it legal* Whatever your use, remember that you are responsible for ensuring that what you are doing is legal. Do not assume that just because we believe a book is in the public domain for users in the United States, that the work is also in the public domain for users in other countries. Whether a book is still in copyright varies from country to country, and we can't offer guidance on whether any specific use of any specific book is allowed. Please do not assume that a book's appearance in Google Book Search means it can be used in any manner anywhere in the world. Copyright infringement liability can be quite severe.

**About Google Book Search**

Google's mission is to organize the world's information and to make it universally accessible and useful. Google Book Search helps readers discover the world's books while helping authors and publishers reach new audiences. You can search through the full text of this book on the web at `http://books.google.com/`

THE FRANCIS A. COUNTWAY LIBRARY OF MEDICINE
HARVARD MEDICAL LIBRARY-BOSTON MEDICAL LIBRARY

# TRANSACTIONS

OF THE

# PATHOLOGICAL SOCIETY OF LONDON.

VOLUME THE THIRTIETH.

COMPRISING THE REPORT OF THE PROCEEDINGS FOR THE SESSION 1878-79.

LONDON:
PRINTED FOR THE SOCIETY BY J. E. ADLARD, BARTHOLOMEW CLOSE.
1879.

THE present publication, being the Thirtieth Volume of Transactions, constitutes the Thirty-third published Annual Report of the Pathological Society's Proceedings.

The COUNCIL think it right to repeat that the exhibitors are alone responsible for the descriptions given of the Specimens exhibited by them, the only change made in the Reports furnished by the authors being such verbal alterations as were absolutely necessary.

53, BERNERS STREET, OXFORD STREET.
*October*, 1879.

# TABLE OF CONTENTS

## OF VOLUME XXX.


List of Presidents of the Society . . . . . iv
List of Officers and Members for 1879 . . v—xxxiii
Annual Report of Council for 1878 . . . . . xxxv
List of Specimens Exhibited during the Session 1877-8 . . . . . xxxix
List of Specimens Reported on by the Committee on Morbid Growths . . . . . xlvii
List of Plates . . . . . xlix
List of Woodcuts . . . . . liii
Report of the Committee on Pyæmia, Septicæmia, and Purulent Infection . . . . . 1
Diseases, etc., of the Nervous System . . . . 189
Diseases, etc., of the Organs of Respiration . . 220
Diseases, etc., of the Organs of Circulation . . 258
Diseases, etc., of the Organs of Digestion . . 297
Diseases, etc., of the Genito-Urinary Organs . 310
Diseases, etc., of the Osseous System . . . . 332
Morbid Growths . . . . . 360
Diseases, etc., of the Skin . . . . . 439
Diseases, etc., of the Ductless Glands and Lymphatic System . . . . . 478
Special Communications . . . . . 511
Miscellaneous Specimens . . . . . 583
Index . . . . . 593

# Presidents of the Society.

ELECTED

1846 CHARLES J. B. WILLIAMS, M.D., F.R.S.
1848 CHARLES ASTON KEY.
1850 PETER MERE LATHAM, M.D.
1852 CÆSAR H. HAWKINS, F.R.S.
1853 BENJAMIN GUY BABINGTON, M.D., F.R.S.
1855 JAMES MONCRIEFF ARNOTT, F.R.S.
1857 SIR THOMAS WATSON, BART., M.D., F.R.S.
1859 SIR WILLIAM FERGUSSON, BART., F.R.S.
1861 JAMES COPLAND, M.D., F.R.S.
1863 PRESCOTT G. HEWETT, F.R.S.
1865 THOMAS BEVILL PEACOCK, M.D.
1867 JOHN SIMON, D.C.L., F.R.S.
1869 RICHARD QUAIN, M.D., F.R.S.
1871 JOHN HILTON, F.R.S.
1873 SIR WILLIAM JENNER, BART., M.D., K.C.B., D.C.L., F.R.S.
1875 GEORGE D. POLLOCK.
1877 CHARLES MURCHISON, M.D., LL.D., F.R.S.
1879 JONATHAN HUTCHINSON.

# OFFICERS AND COUNCIL

OF THE

# Pathological Society of London,

ELECTED AT

THE GENERAL MEETING, JANUARY 7TH, 1879.

---

**President.**

JONATHAN HUTCHINSON.

**Vice-Presidents.**

GEORGE HARLEY, M.D., F.R.S.
JAMES EDWARD POLLOCK, M.D.
HERMANN WEBER, M.D.
THOMAS BRYANT.
CHRISTOPHER HEATH.
THOMAS WILLIAM NUNN.
SEPTIMUS WILLIAM SIBLEY.

**Treasurer.**

JOHN WHITAKER HULKE, F.R.S.

**Council.**

THOMAS BARLOW, M.D.
SIDNEY COUPLAND, M.D.
WILLIAM RICHARD GOWERS, M.D.
T. HENRY GREEN, M.D.
WILLIAM SMITH GREENFIELD, M.D.
JAMES PEARSON IRVINE, M.D.
CHARLES HENRY RALFE, M.D.
FREDERICK TAYLOR, M.D.
JOHN WILLIAMS, M.D.
RICKMAN JOHN GODLEE.
JOHN WARRINGTON HAWARD.
HENRY GREENWAY HOWSE.
WILLIAM BEDFORD KESTEVEN, M.D.
JEREMIAH McCARTHY.
WILLIAM MAC CORMAC
HENRY MORRIS.
ARTHUR TREHERNE NORTON.
WILLIAM JOHNSON SMITH.
WILLIAM W. WAGSTAFFE.

**Honorary Secretaries.**

R. DOUGLAS POWELL, M.D. | W. MORRANT BAKER.

**Trustees.**

THOS. BEVILL PEACOCK, M.D. | RICHARD QUAIN, M.D., F.R.S.
GEORGE D. POLLOCK.

*** *Members are requested to indicate to the Secretaries corrections when necessary.*

# LIST OF MEMBERS OF THE SOCIETY.

## Honorary Members.

ARNOTT, JAMES MONCRIEFF, F.R.S., Chapel House, Lady Bank, Fifeshire; and 36, Sussex-gardens, Hyde-park, W.

BILLROTH, THEODOR, M.D., Professor of Surgery in the University of Vienna.

BRUECKE, ERNST, M.D., Professor of Physiology in the University of Vienna.

CHARCOT, J. M., M.D., Physician to the "Hôpital de la Salpêtrière," and Professor at the Faculty of Medicine of Paris.

CHAUVEAU, A., M.D., Professor of Physiology at the Medical School of Lyons.

COHNHEIM, JULIUS, M.D., Professor of General Pathology and Pathological Anatomy in the University of Breslau.

GROSS, SAMUEL D., M.D., D.C.L. Oxon., LL.D., Professor of Surgery in the Jefferson Medical College of Philadelphia.

HELMHOLTZ, H., M.D., Professor of Physiology in the University of Heidelberg.

HENLE, J., M.D., Professor of Anatomy and Physiology in the University of Göttingen.

LUDWIG, C., M.D., Professor of Physiology in the University of Leipzig.

PIROGOFF, NIKOLAUS, M.D., Professor of Surgery to the Medico-Chirurgical Academy of St. Petersburg.

RINDFLEISCH, EDOUARD, M.D., Professor of Pathological Anatomy in the University of Bonn.

ROBIN, CHARLES, M.D., Professor of Histology at the Faculty of Medicine of Paris.

SCHWANN, THEODOR, Professor of Physiology at the University of Liège.

THIERSCH, CARL, M.D., Professor of Surgery in the University of Leipzig.

VIRCHOW, RUDOLF, M.D., Professor of Pathological Anatomy in the University of Berlin.

VOGEL, JULIUS, M.D., Professor of Cutaneous Diseases in the University of Halle.

### EXPLANATION OF ABBREVIATIONS.

| | |
|---|---|
| O.M.—Original Member. | V.-P.—Vice-President. |
| *Pres.*—President. | S.—Secretary. |
| T.—Treasurer. | C.—Member of Council. |

Those marked thus (†) have paid Composition Fee for Annual Subscription.
Those marked thus (‡) have paid Composition Fee for Transactions.

# GENERAL LIST OF MEMBERS.

*Elected*

1879 ABERCROMBIE, JOHN, M.B., Hospital for Sick Children, 49, Great Ormond-street.

1858 ACLAND, HENRY WENTWORTH, M.D., F.R.S., Regius Professor of Medicine, University of Oxford, Physician to the Radcliffe Infirmary, Oxford.

*Elected*

‡1866 ADAMS, ARTHUR BAYLEY.

1869 ADAMS, JAMES EDWARD, Surgeon to the London Hospital, 10, Finsbury-circus, E.C.

O.M. ADAMS, WILLIAM, Consulting Surgeon to the National Orthopædic Hospital, 5, Henrietta-street, Cavendish-square, W. (C. 1851-4. V.-P. 1867-9.)

1859 ADAMS, WILLIAM, 37, Harrington-square, N.W. (C. 1877-8.)

1848 AIKIN, CHARLES A., 7, Clifton-place, Sussex-square, Hyde-park, W. (C. 1864-6.)

1872 AIKIN, CHARLES EDMUND, 7, Clifton-place, Sussex-square, Hyde-park, W.

1871 AIR, A. CUMMINGS, 88, Kennington-park-road, S.E.

1869 ALLBUTT, THOMAS CLIFFORD, M.D., Physician to the Leeds General Infirmary, 35, Park-square, Leeds.

1877 ALTHAUS, JULIUS, M.D., Senior Physician to the Hospital for Epilepsy and Paralysis, Regent's Park, 36, Bryanston-street, Portman-square.

1878 AMPHLETT, EDWARD, M.B., Assistant Surgeon to the Charing Cross Hospital, 40, Weymouth-street, Portland-place, W.

1868 ANDERSON, J. FORD, M.D., 28, Buckland-crescent, Belsize-park, N.W.

1871 ANDERSON, WILLIAM, Professor of Medical Science at the University of Yeddo, Japan.

1859 ANDREW, EDWYN, M.D., Hardwick House, St. John's-hill, Shrewsbury.

1863 ANDREW, JAMES, M.D., Physician to St. Bartholomew's Hospital, 22, Harley-street, W. (C. 1868-70.)

1866 ARNOTT, REV. HENRY, Braeside, Beckenham. (C. 1872, 1875-6. S. 1873, 1874.)

1863 BAGSHAWE, FREDERICK, M.A., M.D., 16, Warrior-square, Hastings.

1864 BAKER, WILLIAM MORRANT (HON. SECRETARY), Assistant Surgeon to, and Lecturer on Physiology at, St. Bartholomew's Hospital, 26, Wimpole-street, Cavendish-square, W. (C. 1873-6. S. 1878-79.)

‡1856 BALDING, DANIEL BARLEY, Royston, Herts.

1851 BARCLAY, A. WHYTE, M.D., Physician to St. George's Hospital, 23A, Bruton-street, Berkeley-square, W. (C. 1858-61.)

1875 BARKER, ARTHUR C. J., Assistant Surgeon and Assistant Teacher of Clinical Surgery, University College Hospital, 28, Welbeck-street, Cavendish-square, W.

1874 BARLOW, THOMAS, M.D., B.S. (C.), Assistant Physician to the London Hospital and to the Children's Hospital, Great Ormond-street, 10, Montague-street, Russell-square, W.C. (C. 1879.)

1871 BARNES, ROBERT, M.D., Obstetric Physician to St. George's Hospital, 15, Harley-street, Cavendish-square, W.

1862 BARRATT, JOSEPH GILLMAN, M.D., Accoucheur to the St. George's and St. James's Dispensary, 8, Cleveland-gardens, Bayswater, W.

1877 BARROW, A. BOYCE, Pathological Registrar, King's College Hospital, 17, Welbeck-street, Cavendish-square, W.

*Elected*

1853 BARWELL, RICHARD, Surgeon to, and Lecturer on Surgery at, the Charing Cross Hospital, 32, George-street, Hanover-square, W. (C. 1862-4.)

1861 BASTIAN, H. CHARLTON, M.A., M.D., F.R.S., Professor of Pathological Anatomy in University College, and Physician to University College Hospital, 20, Queen Anne-street, W. (C. 1869-71.)

1877 BATEMAN, ARTHUR W., B.A., Tenterfield, New South Wales.

†1876 BATTESON, JOHN, Medical Officer of the Royal Humane Society, 1, Coborn-place, Bow-road, E.

1870 BÄUMLER, CHRISTIAN G. H., M.D., Professor of Materia Medica in the University of Erlangen.

1871 BAXTER, EVAN BUCHANAN, M.D., Professor of Materia Medica, King's College, London, and Assistant Physician to King's College Hospital, 28, Weymouth-street, Portland-place, W.

1874 BEACH, FLETCHER, M.B., Metropolitan District Asylum, Darenth, near Dartford, Kent.

1852 BEALE, LIONEL S., M.B., F.R.S., Professor of Medicine at King's College, Physician to King's College Hospital, 61, Grosvenor-street, W. (C. 1858-9. V.-P. 1874-5.)

1856 BEALEY, ADAM, M.D., M.A., Oak-lea, Harrogate.

†1878 BEANEY, JAMES GEORGE, Senior Surgeon to the Melbourne Hospital, Melbourne, Victoria.

1870 BECK, MARCUS, M.S., Assistant Surgeon to University College Hospital, 30, Wimpole-street, Cavendish-square, W. (C. 1875-7.)

1865 BEEBY, WALTER, M.D., Bromley, Kent.

1875 BELL, H. ROYES, Surgeon to King's College Hospital, 44, Harley-street, Cavendish-square, W.

1865 BELLAMY, EDWARD, Surgeon to the Charing Cross Hospital, 17, Wimpole-street, Cavendish-square, W. (C. 1876-8.)

1847 BENNET, JAMES HENRY, M.D., Weybridge, Surrey.

1876 BENNETT, ALEX. HUGHES, M.D., Assistant Physician to the Westminster Hospital, 1, Petersham-terrace, Queen's-gate, S.W.

O.M. BENNETT, JAMES RISDON, M.D., F.R.S., Consulting Physician to St. Thomas's Hospital, and to the City of London Hospital for Diseases of the Chest, 22, Cavendish-square, W. (C. 1846-8. V.-P. 1856-9.)

1877 BENNETT, WILLIAM HENRY, Surgeon to the Belgrave Hospital for Children, 5, Savile-row, Burlington-gardens.

1878 BERNARD, FRANCIS W., M.D., Medical Superintendent, Stockwell Small-pox Hospital, Stockwell, S.W.

‡1856 BICKERSTETH, EDWARD R., Surgeon to the Liverpool Royal Infirmary, 2, Rodney-street, Liverpool.

1878 BINDON, WILLIAM JOHN VEREKER, M.D., 2, Elm-villas, Kilburn, N.W.

1850 BIRKETT, EDMUND LLOYD, M.D., Consulting Physician to the City of London Hospital for Diseases of the Chest, 48, Russell-square, W.C. (C. 1856-7.)

O.M. BIRKETT, JOHN, Consulting Surgeon to Guy's Hospital, 59, Green-street, Grosvenor-square, W. (C. 1851. V.-P. 1860-2.)

*Elected*

1865 BISSHOPP, JAMES, Bedford-place, Tunbridge Wells.

1853 BLACK, CORNELIUS, M.D., Physician to the Chesterfield Dispensary, St. Mary's-gate, Chesterfield.

1877 BLACK, JAMES, 41, Aytoun-road, Stockwell-road, Brixton.

1850 BLAGDEN, ROBERT, Stroud, Gloucestershire.

1863 BLANCHET, JEAN B., M.D., M.S., Montreal, Quebec, Canada.

1876 BLASSON, WILLIAM, Edgeware, Middlesex.

1879 BOILEAU, J. P. H., M.D., Surgeon-Major, Army Medical Department, Assistant Professor of Pathology, Netley School of Medicine, Netley.

1876 BOND, THOMAS, M.B., Assistant Surgeon and Lecturer on Forensic Medicine to Westminster Hospital, 17, Delahay-street, Westminster, S.W.

1869 BOURNE, WALTER, M.D.

1861 BOWER, RICHARD NORRIS, 14, Doughty-street, Mecklenburg-square, W.C.

1851 BOWMAN, WILLIAM, F.R.S., Surgeon to the Royal Ophthalmic Hospital, 5, Clifford-street, Bond-street, W. (C. 1855-6.)

1877 BRIDGES, ROBERT, M.B., M.A. Oxford, Casualty Physician to St. Bartholomew's Hospital, 52, Bedford-square, W.C.

1867 BRIDGEWATER, THOMAS, M.B. Lond., Harrow-on-the-hill, Middlesex.

1873 BRIGGS, JACOB MYERS, M.D., Coeymans, New York, U.S.

1868 BRIGHT, G. C., M.B., 29, Lüttichanstrasse, Dresden.

1857 BRISCOE, JOHN, 12, Broad-street, Oxford.

†1851 BRISTOWE, JOHN S., M.D., Physician to, and Lecturer on the Theory and Practice of Medicine at, St. Thomas's Hospital, 11, Old Burlington-street, W. (C. 1854-8. S. 1861-4. C. 1865-7. V.-P. 1868-76.)

1860 BROADBENT, WILLIAM HENRY, M.D. Lond., Physician to St. Mary's Hospital, and Physician to the London Fever Hospital, 34, Seymour-street, Portman-square, W. (C. 1871-3.)

1877 BROCKMAN, E. F., Madras Medical Service [18, Addison-gardens North, Kensington, W.].

1852 BRODHURST, BERNARD E., Surgeon to the Royal Orthopædic Hospital, 20, Grosvenor-street, W. (C. 1862-4.)

1863 BRODIE, GEORGE BERNARD, M.D., Consulting Physician-Accoucheur to Queen Charlotte's Hospital, 3, Chesterfield-street, Mayfair, W.

1865 BROWN, AUGUSTUS, M.D., 29, Belitha-villas, Barnsbury-park, N.

1871 BROWN, FREDERICK GORDON, 16, Finsbury-circus, E.C.

1875 BROWNE, GEORGE BUCKSTONE, 80, Wimpole-street, Cavendish-square, W

1866 BROWNE, LENNOX, Surgeon to the Central Throat and Ear Hospital, and to the Royal Society of Musicians, 36, Weymouth-street, Portland-place, W.

O.M. BROWNE, JOSEPH HULLETT, M.D., Physician to the St. Pancras Royal General Dispensary, 55, Gordon-square, W.C. (C. 1859-60.)

1877 BRUCE, J. MITCHELL, M.D., Assistant Physician to Charing Cross Hospital and to the Hospital for Consumption, Brompton, 60, Queen Anne-street, Cavendish-square, W.

1855 BRYANT, THOMAS (V.-P.), Surgeon to Guy's Hospital, 53, Upper Brook-street, Grosvenor-square, W. (C. 1863-6. V.-P. 1877-79.)

*Elected*

1854 BUCHANAN, GEORGE, M.D., Inspector Medical Department Local Government Board, 24, Nottingham-place, Marylebone-road, W. (C. 1864-6.)

1862 BUCHANAN, ALBERT, M.B. Lond., 382, Camden-road, N.

1858 BUDD, GEORGE, M.D., F.R.S., Ashleigh, Barnstaple. (C. 1862-4.)

1878 BURNETT, ROBERT WILLIAM, M.D., 10, Nottingham-place, Marylebone-road, W.

1860 BURTON, ALFRED, 13, Dover-street, Piccadilly, W.

1853 BURTON, JOHN M., Lee-park Lodge, Lee, Kent, S.E.

1872 BUTLIN, HENRY TRENTHAM, Surgical Registrar to St. Bartholomew's Hospital, Assistant Surgeon to the West London Hospital, 47, Queen Anne-street, W. (C. 1876-8.)

1866 BUTT, WILLIAM FREDERICK, 25, Park-street, Park-lane, W.

1856 BUZZARD, THOMAS, M.D., Physician to the National Hospital for the Epileptic and Paralysed, 56, Grosvenor-street, W. (C. 1869-70.)

†O.M. CAMPS, WILLIAM, M.D. (C. 1856-9.)

‡1855 CARPENTER, ALFRED, M.D., High-street, Croydon.

1879 CARRINGTON, ROBERT E., M.B., 13, Loughborough-road, Brixton, S.W.

1871 CARTER, CHARLES HENRY, M.D., B.S. Lond., Physician to the Hospital for Women, 45, Great Cumberland-place, Hyde-park, W.

1855 CARTER, H. VANDYKE, M.D., Professor of Anatomy and Physiology, Grant Medical College, Bombay. [22, Clarendon-road, Victoria-road, Kensington, W.]

1876 CARTER, ROBERT BRUDENELL, Ophthalmic Surgeon to, and Lecturer on Ophthalmic Surgery at, St. George's Hospital, 69, Wimpole-street, Cavendish-square, W.

1879 CASSIDY, JOSEPH LAMONT, M.D., 82, Guilford-street, Russell-square, W.C.

1877 CASSON, JOHN HORNSEY.

†1868 CAVAFY, JOHN, M.D., Senior Assistant Physician to, and Lecturer on Physiology at, St. George's Hospital, 2, Upper Berkeley-street, Portman-square, W.

1864 CAY, CHARLES VIDLER, Smedleys, Matlock Bank, Derby.

1863 CAYLEY, WILLIAM, M.D., Physician to, and Lecturer on the Principles and Practice of Medicine at, the Middlesex Hospital, 58, Welbeck-street, Cavendish-square, W. (C. 1870-1, 1875-8. S. 1872-4.)

1869 CHAFFERS, EDWARD, Keighley, Yorkshire.

1849 CHALK, WILLIAM OLIVER, 3, Nottingham-terrace, Regent's-park, N.W. (C. 1856-7.)

1876 CHARLES, T. CRANSTOUN, M.D., M.C., Lecturer on Practical Physiology at St. Thomas's Hospital, 10, Mitre Court Chambers, Temple.

1870 CHEADLE, WALTER BUTLER, M.D., Assistant Physician to St. Mary's Hospital, and to the Hospital for Sick Children, Great Ormond-street, 2, Hyde-park-place, Cumberland-gate, W.

O.M. CHEVERS, NORMAN, M.D., 32, Tavistock-road, Notting-hill, W. (C. 1848.)

*Elected*

1879 CHEYNE, WILLIAM WATSON, M.B., C.M., 6, Old Cavendish-street, W.

1858 CHILD, GILBERT W.

1873 CHISHOLM, EDWIN, M.D., Abergeldie, Ashfield, near Sydney, New South Wales.

1855 CHOLMELEY, WILLIAM, M.D., Physician to the Great Northern Hospital, and to the Margaret-street Infirmary for Consumption, 63, Grosvenor-street, W. (C. 1871-3.)

1871 CHRISTIE, THOMAS BEATH, M.D., Superintendent of the Royal India Asylum, Ealing, Middlesex.

1865 CHURCH, WILLIAM SELBY, M.D., Physician to St. Bartholomew's Hospital, 130, Harley-street, Cavendish-square, W. (C. 1871-3.)

†1868 CHURCHILL, FREDERICK, M.B., Assistant Surgeon to the Victoria Hospital for Children, 6, Sumner-place, S.W.

1861 CLAPTON, EDWARD, M.D., 10A, St. Thomas's-street, Southwark, S.E.

1854 CLARK, ANDREW, M.D., Physician to the London Hospital, 16, Cavendish-square, W. (C. 1862-5.)

1872 CLARK, ANDREW, Assistant Surgeon to the Middlesex Hospital, 19, Cavendish-place, W.

1865 CLARKE, JACOB LOCKHART, M.D., F.R.S., 21, New Cavendish-street, W. (C. 1868-70.)

1867 CLARKE, WILLIAM FAIRLIE, M.A., M.D., Southborough, Tunbridge Wells. (C. 1873-5.)

1875 CLARKSON, JOHN, Surgeon in the India Department, Bombay Presidency, India.

1875 CLUTTON, HENRY HUGH, M.A., Assistant Surgeon, St. Thomas's Hospital, 2, Palace-road, Albert-embankment, S.E.

‡1865 COATES, CHARLES, M.D., Physician to the Bath General and Royal United Hospitals, 10, Circus, Bath.

1856 COCKLE, JOHN, M.D., M.A., Physician to the Royal Free Hospital, 7, Suffolk-place, Pall-mall, S.W.

O.M. COHEN, DANIEL WHITAKER, M.D., South-bank, Northdown-lane, Bideford, Devon.

†1866 COLES, GEORGE CHARLES, Surgeon to the Infirmary for Epilepsy and Paralysis, and Assistant Surgeon to the Royal South London and Central London Ophthalmic Hospitals, 20, Great Coram-street, Russell-square, W.C.

COLLEY, see DAVIES-COLLEY.

1878 COLLYNS, R. T. POOLE, Atkinson Morley Hospital, Wimbledon.

1858 COOKE, ROBERT THOMAS, Surgeon to the Scarborough Dispensary, 15, St. Nicholas-cliff, Scarborough, Yorkshire.

1871 COOKE, THOMAS, Assistant Surgeon to the Westminster Hospital, 16, Woburn-place, W.C.

1866 COOMBS, ROWLAND HILL, Mill-street, Bedford.

*Elected*

1851 COOPER, WILLIAM WHITE, Consulting Ophthalmic Surgeon to St. Mary's Hospital, 19, Berkeley-square, W. (C. 1860-2.)

1853 CORNISH, WILLIAM ROBERT, Surgeon-Major, Madras Army, Sanitary Commissioner for Madras.

1875 CORY, ROBERT, M.D., Assistant Obstetric Physician to St. Thomas's Hospital, 14, Palace-road, Albert-embankment, S.E.

1876 COTTLE, ERNEST WYNDHAM, M.A., Assistant Surgeon, Hospital for Diseases of the Skin, Blackfriars, 3, Savile-row.

1859 COULSON, WALTER J., Surgeon to the Lock Hospital, 17, Harley-street, Cavendish-square, W.

†1861 COUPER, JOHN, Surgeon to the London Hospital, 80, Grosvenor-street, Grosvenor-square, W. (C. 1870-2.)

1873 COUPLAND, SIDNEY, M.D. (C.), Assistant Physician to, and Lecturer on Pathological Anatomy at, the Middlesex Hospital, 7, Nottingham-place, W. (C. 1878-9.)

1873 CRIPPS, WILLIAM HARRISON, Surgical Registrar to St. Bartholomew's Hospital, 6, Stratford-place, Oxford-street, W.

O.M. CRISP, EDWARDS, M.D., 29, Beaufort-street, Chelsea, S.W. (C. 1846-7-V.-P. 1870-2.)

1848 CRITCHETT, GEORGE, Surgeon to the Royal London Ophthalmic Hospital, Moorfields, and Ophthalmic Surgeon to the Middlesex Hospital, 21, Harley-street, W. (S. 1849. C. 1851, 1858-9. V.-P. 1866-7.)

1877 CROCKER, HENRY RADCLIFFE, M.D., Physician to the Skin Department, University College Hospital; Assistant Physician and Pathologist to the East London Hospital for Children, 135, Gower-street, W.C.

1856 CROFT, JOHN, Surgeon to St. Thomas's Hospital, 61, Brook-street, Grosvenor-square, W. (C. 1870-2.)

1861 CROSBY, THOMAS BOOR, M.D., 21, Gordon-square, W.C.

1875 CROSS, FRANCIS RICHARDSON, 5, The Mall, Clifton, Bristol.

1854 CROSS, ROBERT, M.D., 42, Craven-street, Strand, W.C.

1864 CRUCKNELL, HENRY H., M.B., 58, Welbeck-street, W. (C. 1875-76.)

1871 CUMBERBATCH, ELKIN, Demonstrator of Anatomy at St. Bartholomew's Hospital, 17, Queen Anne-street, W.

1858 CUMBERBATCH, LAURENCE T., M.D., 25, Cadogan-place, Sloane-street, S.W.

1855 CURLING, THOMAS BLIZARD, F.R.S., Consulting Surgeon to the London Hospital, 39, Grosvenor-street, W. (C. 1857-60. V.-P. 1866-8.)

1873 CURNOW, JOHN, M.D., Professor of Anatomy at King's College, and Assistant Physician to King's College Hospital, 3, Warwick-street, Cockspur-street, S.W.

‡1865 CURRAN, WILLIAM, M.D., Army Medical Staff. [Agent: Mr. H. K. Lewis, 136, Gower-street, W.C.]

*Elected*

1863 DANE, THOMAS, 86, Finchley-road, N.W.

1873 DAVIDSON, ALEXANDER, M.D., Physician to the Liverpool Royal Infirmary; Lecturer on Pathology at the Liverpool Medical School, 49, Rodney-street, Liverpool.

1869 DAVIES-COLLEY, J. N., M.B., Assistant Surgeon to Guy's Hospital, 36, Harley-street, Cavendish-square.

O.M. DAVIES, HERBERT, M.D., Consulting Physician to the London Hospital, and to the Infirmary for Asthma, 23, Finsbury-square, E.C. (C. 1849-50. V.-P. 1871.)

1847 DAVIS, JOHN HALL, M.D., Physician-Accoucheur to the Middlesex Hospital, and to the Royal Maternity Charity, 24, Harley-street, Cavendish-square, W. (C. 1852-3.)

‡1859 DAVIS, FRANCIS WILLIAM, R.N., Surgeon to the Naval Medical Establishment, Lisbon. [Agents: Messrs. Hallett and Co., 7, St. Martin's-place, Trafalgar-square, W.C.]

1867 DAVY, RICHARD, Surgeon to, and Lecturer on Surgery at, the Westminster Hospital, 33, Welbeck-street, Cavendish-square, W.

1866 DAY, WILLIAM HENRY, M.D., Physician to the Samaritan Free Hospital for Women and Children, 10, Manchester-square, W.

1872 DECASTRO, JAMES C., M.B., Pau, France.

1871 DE LIEFDE TEMPLE, JOHN, M.D. [per Mr. James Nimmo, 7, Red Lion-court, Watling-street, E.C.].

1863 DEVEREUX, DANIEL, Tewkesbury, Gloucestershire.

1856 DICK, H., M.D., 59, Wimpole-street, Cavendish-square, W.

1871 DICKINSON, EDWARD HARRIMAN, M.A. Oxon., M.D., Physician to the Liverpool Northern Hospital, and Lecturer on Comparative Anatomy at the Liverpool School of Medicine, 162, Bedford-street, Liverpool.

1858 DICKINSON, WILLIAM HOWSHIP, M.D., Physician to the Hospital for Sick Children, Physician and Lecturer on Medicine to St. George's Hospital, 9, Chesterfield-street, Mayfair, W. (C. 1866-8. S. 1869-71. V.-P. 1872-4.)

1872 DIVER, EBENEZER, M.D., Kenley, Caterham-valley, Surrey.

O.M. DIXON, JAMES, Consulting Surgeon to the Royal Ophthalmic Hospital, Moorfields; Harrowlands, Dorking, Surrey. (C. 1852-6. V.-P. 1860-2.)

1872 DORAN, ALBAN HENRY GRIFFITHS, Surgeon to Out-Patients, Samaritan Hospital, Pathological Assistant to Museum, Royal College of Surgeons, 51, Seymour-street, Portman-square, W.

†1866 DOWN, JOHN LANGDON H., M.D., Physician to the London Hospital, 39, Welbeck-street, Cavendish-square, W. (C. 1872-4.)

1872 DOWSE, THOMAS STRETCH, M.D., 2, Old Burlington-street, Piccadilly, W., and Tray's-hill Hall, Hornsey-lane, Highgate, N.

*Elected*

1865 DUCKWORTH, DYCE, M.D., Assistant Physician to St. Bartholomew's Hospital, 11, Grafton-street, Bond-street, W. (C. 1877.)

1863 DUDFIELD, THOMAS ORME, M.D., 8, Upper Phillimore-place, Kensington, W.

1847 DUDGEON, ROBERT E., M.D., 53, Montagu-square, W.

1852 DUFF, GEORGE, M.D., High-street, Elgin.

1865 DUFFIN, ALFRED BAYNARD, M.D., Physician to King's College Hospital, 18, Devonshire-street, Portland-place, W. (C. 1872-4.)

1875 DUKA, THEODORE, M.D., Surgeon-Major, H.M.'s Bengal Army; 38, Montagu-square, W.

1868 DUKE, OLIVER THOMAS, M.B., India.

1871 DUKES, CLEMENT, M.D., B.S., Horton-crescent, Rugby.

1877 DUNBAR, J. J. M., Assistant House-Physician to St. George's Hospital, 77, Ladbroke-grove; Kensington, W.

1877 DUNCAN, ANDREW, 8, Henrietta-street, Covent-garden, W.C.

1861 DUNN, ROBERT WILLIAM, 13, Surrey-street, Strand, W.C.

1858 DURHAM, ARTHUR EDWARD, Surgeon to Guy's Hospital, 82, Brook-street, Grosvenor-square, W. (C. 1869-71.)

1867 ELLIS, JAMES, M.D., California.

1847 ELLIS, JAMES. [Messrs. Tweedie, 337, Strand.]

1873 ENGELMANN, GEORGE JULIUS, M.D., A.M., 3002, Locust-street, St. Louis, Miss., U.S.

1846 ERICHSEN, JOHN ERIC, F.R.S., Surgeon to University College Hospital, 6, Cavendish-place, Cavendish-square, W. (C. 1849-51. V.-P. 1863-4.)

1853 EVANS, CONWAY, M.D., 5, Tavistock-street, Covent-garden, W.C. (C. 1867-8.)

1873 EVANS, GEORGE HENRY, M.D.

1875 EVANS, JULIAN, A.M., M.D., Physician to the Victoria Hospital for Sick Children, 123, Finboro'-road, Redcliffe-square, West Brompton, S.W.

1879 EVE, FREDERICK S., 14, Furnival's Inn, Holborn, W.C.

1876 EWART, JAMES COSSAR, M.B., C.M., School of Medicine, Edinburgh.

1877 EWART, WILLIAM, M.B., 33, Curzon-street, Mayfair, W.

‡1859 EWENS, JOHN, Cotham Brow, Bristol.

1864 FAGGE, CHARLES HILTON, M.D., Senior Assistant Physician to, and Lecturer on Pathology at, Guy's Hospital, 11, St. Thomas's-street, Southwark, S.E. (C. 1870-2.)

1862 FARQUHARSON, ROBERT, M.D., Assistant Physician to and Lecturer on Materia Medica at St. Mary's Hospital, 23, Brook-street, Grosvenor-square, W. (C. 1876-7.)

*Elected*

1872 FAYRER, Sir JOSEPH, C.S.I., M.D., F.R.S. Ed., Hon. Physician to the Queen, Surgeon-Major, Bengal Army, Examining Medical Officer to the Secretary of State for India in Council, 16, Granville-place, Portman-square, W.

1872 FENN, EDWARD L., M.B., The Old Palace, Richmond, Surrey.

1872 FENWICK, JOHN C. J., M.D., Physician to the Durham County Hospital; Chilton Hall, Ferry-hill, and 16, Old Elvet, Durham.

1863 FENWICK, SAMUEL, M.D., Physician, with charge of out-patients to, and Lecturer on Medicine at, the London Hospital, 29, Harley-street, W.

1846 FINCHAM, GEORGE T., M.D., Physician to the Westminster Hospital, 13, Belgrave-road, S.W. (C. 1855.)

1876 FINLAY, DAVID W., M.D., Assistant Physician to the Middlesex Hospital, 21, Montagu-street, Portman-square, W.

1870 FISH, JOHN CROCKETT, M.B., 92, Wimpole-street, W.

1859 FISHER, ALEXANDER, M.D., Assistant Surgeon, R.N., Her Majesty's Ship "Endymion."

1855 FLOWER, WILLIAM H., F.R.S., Conservator of the Museum, Royal College of Surgeons, 39, Lincoln's-inn-fields, W.C. (C. 1862-4.)

1872 FORBES, DANIEL MACKAY, L.R.C.P. Ed., Shoreditch Workhouse, Kingsland, E.

1852 FORBES, J. GREGORY, 82, Oxford-terrace, Hyde-park, W. (C. 1860-3.)

†O.M. FORSTER, JOHN COOPER, Surgeon to Guy's Hospital, 29, Upper Grosvenor-street, W. (C. 1857-8. V.-P. 1871-3.)

‡1866 FOSTER, BALTHAZAR WALTER, M.D., Physician to the General Hospital, Birmingham, 16, Temple-row, Birmingham.

1872 FOTHERBY, HENRY J., M.D., Physician to the Metropolitan Free Hospital, 3, Finsbury-square, E.C.

1878 FOX, THOMAS COLCOTT, M.B., B.A., 14, Harley-street, Cavendish-square, W.

1862 FOX, WILSON, M.D., Holme Professor of Clinical Medicine in University College, and Physician to University College Hospital, 67, Grosvenor-street, W. (C. 1868-70. V.-P. 1875-77.)

1858 FRANCIS, CHARLES RICHARD, M.B., Bengal Medical Establishment, Indian Army.

O.M. FRERE, J. C.

1864 FRODSHAM, JOHN MILL, M.D., Streatham, S.W.

‡1858 GAIRDNER, WILLIAM TENNANT, M.D., Professor of Medicine in the University of Glasgow, 225, St. Vincent-street, Glasgow.

1870 GALTON, EDMUND H., Springfield House, Brixton-hill, S.W.

1870 GALTON, JOHN H., M.D., 1, Woodside, Anerley-road, Upper Norwood, S.E.

1855 GAMGEE, JOSEPH SAMPSON, Surgeon to the Queen's Hospital, Birmingham, 20, Broad-street, Birmingham.

*Elected*

1855 GAMGEE, J.

1877 GARLICK, GEORGE, M.D., 33, Great James-street, Bedford-row, W.C.

1846 GARROD, ALFRED BARING, M.D., F.R.S., Consulting Physician to King's College Hospital, 10, Harley-street, Cavendish-square, W. (C. 1851. V.-P. 1863-5.)

1872 GARTON, WILLIAM, Hardshaw-street, St. Helen's, Lancashire.

O.M. GAY, JOHN, Senior Surgeon to the Great Northern Hospital, 10, Finsbury-place South, E.C. (C. 1852-4. V.-P. 1870-2.)

1853 GIBBON, SEPTIMUS, M.D., 39, Oxford-terrace, Hyde-park, W.

1878 GIBBONS, R. A., M.D., 49, Great Ormond-street, W.C.

1876 GILL, JOHN, M.D., Newton Abbot, Devon.

1873 GODLEE, RICKMAN JOHN, M.B., B.S. (C.), Assistant Surgeon to University College Hospital; Demonstrator of Anatomy in University College; 22, Henrietta-street, Cavendish-square, W. (C. 1877-9.)

1875 GODSON, CLEMENT, M.D., Assistant Physician-Accoucheur to St. Bartholomew's Hospital, 8, Upper Brook-street, Grosvenor-square.

1878 GOLDING-BIRD, CUTHBERT H., M.B., Assistant Surgeon to Guy's Hospital, 13, St. Thomas's-street, S.E.

1871 GOODHART, JAMES FREDERICK, M.D., Assistant Physician to, and Teacher of Clinical Medicine at, Guy's Hospital, 27, Weymouth-street, Portland-place, W. (C. 1876-8.)

1875 GOULD, ALFRED PEARCE, M.S., Assistant Surgeon to, and Lecturer on Anatomy at, the Westminster Hospital, 16, Queen Anne-street, W.

1870 GOWERS, WILLIAM RICHARD, M.D. (C.), Assistant Physician to University College Hospital, 50, Queen Anne-street, W. (C. 1878-9.)

1858 GOWLLAND, PETER Y., Surgeon to St. Mark's Hospital, 34, Finsbury-square, E.C.

1867 GREEN, T. HENRY, M.D. (C.), Physician to Charing Cross Hospital, Assistant Physician to the Hospital for Consumption, Brompton, 74, Wimpole-street, W. (C. 1871-3, 1878-9. S. 1875-6.)

1873 GREENFIELD, WILLIAM SMITH, M.D., B.S. (C.), Assistant Physician to, and Lecturer on Morbid Anatomy at, St. Thomas's Hospital, 15, Palace-road, Albert Embankment, S.E. (C. 1877-9.)

1856 GREENHALGH, ROBERT, M.D., 72, Grosvenor-street, W.

‡1855 GREENHILL, WILLIAM ALEXANDER, M.D., Carlisle-parade, Hastings.

1863 GREENHOW, EDWARD HEADLAM, M.D., F.R.S., Physician to the Middlesex Hospital, 14a, Manchester-square, W. (C. 1867-9. V.-P. 1877-8.)

1876 GRIFFITHS, THOMAS D., M.D., Hearne Lodge, Swansea.

1861 GUERNEAU DE MUSSY, HENRI, M.D., 15, Rue du Cirque, Paris.

1863 GULL, SIR WILLIAM WITHEY, Bart., M.D., D.C.L., F.R.S., Consulting Physician to Guy's Hospital, 74, Brook-street, Grosvenor-square, W.

1876 GWYTHER, JAMES, M.B. Lond., St. Mary Church, Torquay.

*Elected*

1849-59 HABERSHON, SAMUEL OSBORNE, M.D., Physician to Guy's Hospital, 70, Brook-street, Grosvenor-square, W. (Re-elected 1874.) (C. 1855-6.)

1851 HACON, E. DENNIS, 269, Mare-street, Hackney, N.E. (C. 1872.)

1877 HALLOWES, FREDERICK BLACKWOOD, Redhill, Surrey.

1848 HARE, CHARLES JOHN, M.D., late Physician to University College Hospital, 57, Brook-street, Grosvenor-square, W. (C. 1852-4. V.-P. 1874-7.)

†1856 HARLEY, GEORGE, M.D., F.R.S. (V.-P.), 25, Harley-street, Cavendish-square, W. (C. 1862-5. V.-P. 1878-9.)

1872 HARRIS, HENRY, M.D., Trengweath-place, Redruth, Cornwall.

1879 HARRIS, VINCENT DORMER, M.D., 23, Upper Berkeley-street, Portman-square, W.

†1858 HART, ERNEST, 38, Wimpole-street, Cavendish-square, W. (C. 1867-8.)

1870 HAWARD, JOHN WARRINGTON (C.), Assistant Surgeon to St. George's Hospital, 5, Montagu-street, Portman-square, W. (C. 1879.)

O.M. HAWKINS, CÆSAR H., F.R.S., Consulting Surgeon to St. George's Hospital, 26, Grosvenor-street, W. (V.-P. 1846-51. *Pres.* 1852-3.)

1857 HAWKSLEY, THOMAS, M.D., Physician to the Margaret-street Dispensary for Consumption, 31, Grosvenor-street, W.

1869 HAY, THOMAS BELL, L.R.C.P. Ed., Christchurch, New Zealand.

1856 HEATH, CHRISTOPHER (V.-P.), Holme Professor of Clinical Surgery in University College, and Surgeon to University College Hospital, 36, Cavendish-square, W. (C. 1866-7. V.-P. 1879.)

1878 HELLIER, JOHN B., M.B., Headingley, Leeds.

1869 HENSLEY, PHILIP J., M.D., Assistant Physician to St. Bartholomew's Hospital, 4, Henrietta-street, Cavendish-square, W.

‡1868 HESLOP, THOMAS P., M.D., Physician to the Children's Hospital, Birmingham.

O.M. HEWETT, PRESCOTT G., F.R.S., Consulting Surgeon to St. George's Hospital, 1, Chesterfield-street, Mayfair, W. (C. 1846-52. V.-P. 1854-7. *Pres.* 1863-4. V.-P. 1865-8.)

1855 HEWITT, GRAILY, M.D., Obstetric Physician to University College Hospital, 36, Berkeley-square, W. (C. 1865-7.)

1864 HICKMAN, WILLIAM, M.B., Surgeon to the Samaritan Free Hospital, 1, Dorset-square, N.W.

1860 HILL, M. BERKELEY, M.B., Surgeon to University College Hospital, and Surgeon for Out-Patients to the Lock Hospital, 55, Wimpole-street, Cavendish-square, W. (C. 1874-5.)

1875 HITCHCOCK, HARRY KNIGHT, M.D., 1, Cliftonville, Bournemouth, Hants.

1874 HOGGAN, GEORGE, M.B., 7, Trevor-terrace, Rutland-gate, S.W.

1847 HOLMAN, H. MARTIN, M.D., Hurstpierpoint, Sussex.

1854 HOLMES, TIMOTHY, Surgeon-in-Chief to the Metropolitan Police, Surgeon to St. George's Hospital, 18, Great Cumberland-place, Hyde-park, W. (C. 1862-3. S. 1864-7. C. 1868. V.-P. 1869-71.)

*Elected*

1850 Holt, Barnard Wight, Consulting Surgeon to the Westminster Hospital, 14, Savile-row, W. (C. 1853.)

O.M. Holthouse, Carsten [26, Guilford-street, Russell-square, W.C.] (C. 1852-4, V.-P. 1874-5.)

1878 Hood, Donald William Charles, M.D., 43, Green-street, Park Lane.

1864 Hood, Wharton P., M.D., 65, Upper Berkeley-street, Portman-square, W.

1870 Hope, William, M.D., 56, Curzon-street, Mayfair, W.

1877 Houghton, Walter B., M.D., Assistant Physician to Charing Cross Hospital, 26, Cavendish-square, W.

1866 Howard, Edward, M.D.

1875 Howse, Henry Greenway, M.S. (C.), Surgeon to Guy's Hospital, and to the Evelina Hospital for Sick Children, 10, St. Thomas's-street, S.E. (C. 1878-9.)

†1856 Hudson, John, M.D., 11, Cork-street, Bond-street, W.

1854 Hulke, John Whitaker, F.R.S. (*Treasurer*), Surgeon to the Middlesex Hospital, and Surgeon to the Royal London Ophthalmic Hospital, 10, Old Burlington-street, W. (C. 1863-5. S. 1868-72. V.-P 1873-6, T. 1877-9.)

1854 Hulme, Edward Charles, Woodbridge-road, Guildford.

1853 Humby, Edwin, M.D., 83, Hamilton-terrace, St. John's Wood, N.W.

1874 Humphreys, Henry, M.D., Physician to the Children's Hospital at Pendlebury, 106, Eccles Old-road, Eccles, near Manchester.

1852 Hutchinson, Jonathan (President), Surgeon to the London Hospital, and to the Royal London Ophthalmic Hospital, Moorfields, 15, Cavendish-square, W. (C. 1856-9. V.-P. 1872-3. P. 1879.)

1875 Irvine, J. Pearson, M.D. (C.), 3, Mansfield-street, Cavendish-square, W. (C. 1879.)

1865 Jackson, J. Hughlings, M.D., Physician to the London Hospital, Physician to the National Hospital for the Paralysed and Epileptic, 3, Manchester-square, W. (C. 1872-3.)

1875 Jalland, William Hamerton, St. Leonard's House, Museum-street, York.

‡1858 Jardine, John Lee, Capel, near Dorking, Surrey.

1847 Jay, Edward, 112, Park-street, Grosvenor-square, W.

O.M. Jenner, Sir William, Bart., M.D., D.C.L., K.C.B., F.R.S., Consulting Physician to University College Hospital, 63, Brook-street, Grosvenor-square, W. (C. 1850-3. V.-P. 1862-4, 1875-6. *Pres.* 1873-4.)

1875 Jessett, Frederic Bowreman, Pier-road, Erith, Kent.

1879 Jessop, Charles Moore, Army Medical Department, Glenthorne-villas, Queen's-road, Norbiton, Surrey.

1866 Jessop, Thomas Richard, 31, Park-square, Leeds.

1878 Johnson, Arthur Jukes, Yorkville, Ontario, Canada.

*Elected*

1876 JOHNSON, CHARLES HENRY, late Staff Surgeon, Turkish Contingent, Repton, Burton-on-Trent.

O.M. JOHNSON, GEORGE, M.D., F.R.S., Physician to King's College Hospital, 11, Savile-row, W. (C. 1846-50. V.-P. 1863-4.)

1854 JOHNSTONE, ATHOL A. W., St. Moritz House, 61, Dyke-road, Brighton.

1853 JONES, SYDNEY, M.B., Surgeon to St. Thomas's Hospital, 16, George-street, Hanover-square, W. (C. 1864-6.)

1862 JONES, THOMAS RIDGE, M.D., Physician to the Victoria Hospital for Sick Children, 19, Chapel-street, Belgrave-square, S.W.

1858 JONES, WILLIAM PRICE, M.D., Claremont-road, Surbiton, Kingston.

1867 KELLY, CHARLES, M.D., Professor of Hygiene, King's College, Strand. (C. 1874.)

1846 KENT, THOMAS J., 60, St. James's-street, S.W.

1852 KERSHAW, W. WAYLAND, M.D., Kingston-on-Thames.

1872 KESTEVEN, WILLIAM B., M.D. (C.), 401, Holloway-road, N. (C. 1879.)

1879 KESTEVEN, WILLIAM HENRY, 401, Holloway-road, N.

1859 KIALLMARK, HENRY WALTER, 5, Pembridge-gardens, Bayswater, W. (C. 1875-6.)

1867 KING, EDWIN HOLBOROW, Killcott, Godalming, Surrey.

1871 KING, ROBERT, M.B., Physician to, and Lecturer on Clinical Medicine at, the Middlesex Hospital, 48, Harley-street, W.

1852 KINGDON, J. ABERNETHY, Surgeon to the City Dispensary, and to the City of London Truss Society, 2, New Bank-buildings, Lothbury, E.C.

‡1856 KINGSLEY, HENRY, M.D., Physician to the Stratford Infirmary, Stratford-on-Avon, Warwickshire.

1878 KLEIN, EDWARD EMANUEL, M.D., F.R.S., 5, Longridge-road, Earl's-court, S.W.

1877 KNIGHT, CHARLES FREDERICK, 8, Northampton-square, Clerkenwell, E.C.

1875 LACY, C. S. DE LACY, 5, Ovington-square, Brompton, S.W.

1878 LANCEREAUX, ETIENNE, M.D., 3, Rue St. Arnaud, Paris.

‡1865 LANCHESTER, HENRY THOMAS, M.D., 53, High-street, Croydon.

1877 LANG, ALEXANDER, M.B., 51, Warwick-road, S.W.

1851 LANGMORE, JOHN C., M.B., 20, Oxford-terrace, Hyde-park, W. (C. 1858-61.)

1865 LANGTON, JOHN, Assistant Surgeon to and Lecturer on Anatomy at St. Bartholomew's Hospital, and Surgeon to the City of London Truss Society, 2, Harley-street, Cavendish-square, W.

1869 LARCHER, O., M.D. Par., Laureate of the Institute of France, of the Medical Faculty and Academy of Paris, 97, Rue de Passy, Paris. [M. Kliensieck, Libraire, Rue de Lille, 11, Paris, per Messrs. Longman.]

*Elected*

1873 LATHAM, PETER WALLWORK, M.D., Physician to Addenbrooke Hospital, and Downing Professor of Medicine, Cambridge University, 17, Trumpington-street, Cambridge.

1876 LAW, WILLIAM THOMAS, M.D., Resident Medical Officer, Brompton Consumption Hospital.

1853 LAWRENCE, HENRY JOHN HUGHES, Surgeon, Grenadier Guards' Hospital, Rochester-row, Westminster, S.W. (C. 1873-5.)

1859 LAWSON, GEORGE, Surgeon to the Middlesex Hospital, and Surgeon to the Royal London Ophthalmic Hospital, Moorfields, 12, Harley-street, Cavendish-square, W. (C. 1870-1.)

1857 LEARED, ARTHUR, M.D., Physician to the Great Northern Hospital, 12, Old Burlington-street, W. (C. 1874-5.)

1875 LEDIARD, HENRY AMBROSE, M.D., Medical Superintendent to Cleveland-street Asylum, 42, Cleveland-street, Fitzroy-square.

1852 LEE, HENRY, Consulting Surgeon to St. George's Hospital, 9, Savile-row, W. (C. 1860-2. V.-P. 1875-6.)

1879 LEECH, DANIEL JOHN, M.D., 96, Mosley-street, Manchester.

1877 LEES, DAVID B., M.D., Assistant Physician to Charing Cross Hospital, and to the Hospital for Sick Children, 2, Thurloe Houses, Thurloe-square, S.W.

1867 LEES, JOSEPH, M.D., 21, Brixton-road, S.W.

1877 LEESON, ARTHUR EDMUND. M.A., M.D., 45, Devonshire-street, Portland-place, W.

1877 LEESON, JOHN RUDD, M.B., C.M., Bushey-park Cottage, Teddington.

1868 LEGG, JOHN WICKHAM, M.D., Assistant Physician to, and Lecturer on Pathological Anatomy at, St. Bartholomew's Hospital, 47, Green-street, Park-lane, W. (C. 1874-5.)

1852 LEGGATT, ALFRED, 13, William-street, Lowndes-square, S.W. (C. 1866-7.)

‡1867 LEUDET, T. EMILE, M.D. Par., Professor of Clinical Medicine, 49, Boulevard Cauchoise, Rouen, France. [M. Kliensieck, Libraire, Rue de Lille 11, Paris, per Messrs. Longman.]

1861 LICHTENBERG, GEORGE, M.D., 47, Finsbury-square, E.C.

1875 LINGARD, ALFRED, 2, Strand-terrace, Derby.

1877 LISTER, JOSEPH, F.R.S., Professor of Clinical Surgery at King's College and Surgeon to King's College Hospital, 12, Park Crescent, Regent's Park, W.

1878 LITTLEJOHN, SALTER G., M.B., C.M., Central London District Schools, Hanwell.

1848 LITTLE, WILLIAM JOHN, M.D., 18, Park-street, Grosvenor-square, W. (C. 1851-2. V.-P. 1856-9.)

†1862 LITTLE, LOUIS S., China. [18, Park-street.]

1874 LIVEING, EDWARD, M.D., 52, Queen Anne-street, Cavendish-square, W.

*Elected*

1863 LIVEING, ROBERT, M.D., Physician to the Skin Department and Lecturer on Dermatology at the Middlesex Hospital, 11, Manchester-square, W. (C. 1876.)

1876 LONGHURST, ARTHUR EDWIN TEMPLE, M.D., 22, Wilton-street, Grosvenor-place, S.W.

1873 LUCAS, R. CLEMENT, M.B., M.S., Assistant Surgeon to Guy's Hospital, 4, St. Thomas's-street, S.E.

1873 LUCEY, WILLIAM C., M.D., Lisle Cottage, Doddington, Cambridgeshire.

1876 LYELL, ROBERT WISHART, M.D., Assistant Surgeon to the Middlesex Hospital, 26, Harley-street, Cavendish-square, W.

1877 LYNCH, GILBERT, M.B., 239, Vauxhall-bridge-road, S.W.

1871 MCCARTHY, JEREMIAH, M.A. (C.), Surgeon to the London Hospital, 26, Finsbury-square, E.C. (C. 1878-9.)

1873 MCCONNELL, J. F., Professor of Pathology, Medical College, Calcutta. [Per Grindlay & Co., Parliament-street.]

1871 MAC CORMAC, WILLIAM (C.), Surgeon to St. Thomas's Hospital, 13, Harley-street, W. (C. 1878-9.)

1876 MACGRATH, W. M., L.Q.K.C.P.I., 32, Colville-terrace, Bayswater, W.

1875 MACKELLAR, ALEXANDER OBERLIN, Assistant Surgeon, St. Thomas's Hospital, Albert Embankment, S.E.

1873 MACKELLAR, PETER H., M.B., Medical Officer, Fever Hospital, Stockwell, S.W.

1870 MACKENZIE, GEORGE WELLAND, 15, Hans-place, Sloane-street, S.W.

1870 MACKENZIE, JOHN T., Bombay, India. [East India United Service Club, 14, St. James's-square.]

1864 MACKENZIE, MORELL, M.D., Physician to the Hospital for Diseases of the Throat, and Lecturer on Diseases of the Throat at the London Hospital, 19, Harley-street, Cavendish-square, W.

1878 MACKENZIE, STEPHEN, M.D., Assistant Physician to, and Joint Lecturer on Pathology at, the London Hospital, 26, Finsbury-square, E.C.

1879 MACLAGAN, THOMAS JOHN, M.D., 9, Cadogan-place, Belgrave-square, S.W.

1865 MACLAURIN, H. N., M.D.

1876 MACLEAN, THOMAS EDWIN, M.B., B.S.

1879 MACMAHON, JAMES THOMAS, L.K.Q.C.P.I., Beaumont Lodge, Howard-road, South Norwood, S.E.

1876 MACNAMARA, CHARLES, Surgeon to the Westminster Hospital, 13, Grosvenor-street, W.

1879 MACREADY, JONATHAN FORSTER, 8, Guilford-street, Russell-square, W.C.

1875 MAHOMED, FREDERICK AKBAR, M.D., Medical Registrar, Guy's Hospital, 12, St. Thomas's-street, S.E.

1877 MAKINS, GEORGE HENRY, St. Thomas's Hospital, Albert Embankment, S.E.

1876 MALLAM, BENJAMIN, Meadow Side, Leacroft-road, Staines.

1876 MAPLES, REGINALD, Spalding, Lincolnshire.

1857 MARCET, WILLIAM, M.D., F.R.S., Villa Bianca, Cannes. (C. 1869-71.)

*Elected*

1868 MARSH, F. HOWARD, Assistant Surgeon to the Hospital for Sick Children, Assistant Surgeon to St. Bartholomew's Hospital, 36, Bruton-street, Berkeley-square. (C. 1876-7.)

1876 MARSHALL, FRANCIS JOHN, St. George's Hospital.

1846 MARSHALL, JOHN, F.R.S., Surgeon to University College Hospital, 10, Savile-row, W. (C. 1861.)

1856 MARTIN, ROBERT, M.D., Consulting Physician to St. Bartholomew's Hospital, 51, Queen Anne-street, Cavendish-square, W. (C. 1871-2.)

1860 MASON, FRANCIS, Surgeon to St. Thomas's Hospital, 5, Brook-street, Grosvenor-square, W. (C. 1873-5.)

1867 MASON, PHILIP BROOKES, Burton-on-Trent.

†1858 MAUNDER, CHARLES F., Surgeon to the London Hospital, 16, Queen Anne-street, Cavendish-square, W. (C. 1869-71.)

†1852 MAY, GEORGE, Jun., M.B., Surgeon, Royal Berkshire Hospital, Reading.

1874 MEREDITH, WILLIAM APPLETON, M.B., 14, Old Burlington-street, W.

1859 MESSER, JOHN COCKBURN, M.D., Assistant Surgeon, R.N., Her Majesty's Ship "Edinburgh," Queensferry, N.B.

‡1867 MICKLEY, ARTHUR GEORGE, M.B., Derby-road, Nottingham.

1866 MICKLEY, GEORGE, M.A., M.B., St. Luke's Hospital, Old-street, E.C.

1877 MILNER, EDWARD, Surgeon to the Lock Hospital, 32, New Cavendish-street, Portland-place, W.

†1859 MONTEFIORE, NATHANIEL, 18, Portman-square, W.

1879 MOORE, NORMAN, M.D., Demonstrator of Morbid Anatomy and Warden of the College; the College, St. Bartholomew's Hospital.

1861 MORKHEAD, CHARLES, M.D., 11, North Manor-place, Edinburgh.

1847 MORGAN, JOHN, 3, Sussex-place, Hyde-park-gardens, W. (C. 1856-8.)

1875 MORGAN, JOHN H., 12, Chapel-street, Grosvenor-square, W.

1874 MORISON, ALEXANDER, M.B., C.M., 7, The Terrace, Green Lanes, N.

1869 MORRIS, HENRY, M.A., M.B. (C.), Surgeon to, and Lecturer on Anatomy and Practical Surgery at, the Middlesex Hospital, 2, Mansfield-street, Portland-place, W. (C. 1877-9.)

1879 MORRIS, MALCOLM ALEXANDER, Joint Lecturer on Skin Diseases at St. Mary's Hospital, 63, Montagu-square

1875 MORTON, JOHN, M.B., Guildford.

1860 MOXON, WALTER, M.D., Physician to Guy's Hospital, 6, Finsbury-circus, E.C. (C. 1868-70, V.P. 1876-8.)

1878 MUMFORD, WILLIAM LUGAR, M.D., 1, Bartlett's-passage, Holborn-circus, E.C.

1876 MUNRO, WILLIAM, M.D., C.M., 102, Carl-street, Lower Broughton-road, Manchester.

1872 MURRAY, J. JARDINE, 99, Montpellier-road, Brighton.

1864 MYERS, ARTHUR B. R., Surgeon to 1st Battalion Coldstream Guards, Hospital, Vincent-square, Westminster, S.W. (C. 1872-3.)

*Elected*

1874 NANKIVELL, ARTHUR WOLCOT, St. Bartholomew's Hospital, Chatham.

1873 NETTLESHIP, EDWARD, 4, Wimpole-street, Cavendish-square, W.

1875 NEWBY, CHARLES HENRY, Surgical Registrar, St. Thomas's Hospital, 87, Adelaide-road, N.W.

1865 NEWMAN, WILLIAM, M.D., Stamford, Lincolnshire.

1868 NICHOLLS, JAMES, M.D., Chelmsford, Essex.

1876 NICHOLSON, JOHN FRANCIS, 10, Storey-street, Hull.

1878 NOOTT, W. M., 8, Kensington-park-road, W.

1864 NORTON, ARTHUR T. (C.), Surgeon to St. Mary's Hospital, 6, Wimpole-street, Cavendish-square, W. (C. 1877-9.)

1856 NUNN, THOMAS WILLIAM (V.-P.), Consulting Surgeon to the Middlesex Hospital, 8, Stratford-place, Oxford-street, W. (C. 1864-6. V.-P. 1878-9.)

1871 NUNNELEY, REV. FREDERICK BARHAM, M.D.

1873 O'FARRELL, GEORGE PLUNKETT, M.B., Tangier House, Boyle, Ireland.

1850 OGLE, JOHN W., M.D., Consulting Physician to St. George's Hospital, 30, Cavendish-square, W. (C. 1855-6. S. 1857-60. C. 1861-3. V.-P. 1865-8.)

1876 OLIVER, JOHN FERENS, M.D., 12, Old Elvet, Durham.

1860 ORANGE, WILLIAM, M.D., Broadmoor, Wokingham, Berkshire.

1875 ORD, WILLIAM MILLER, M.D., Physician to, and Lecturer on Medicine at St. Thomas's Hospital, 7, Brook-street, Hanover-square, W.

1878 ORLEBAR, HOTHAM GEORGE, M.D., House Physician, City of London Hospital for Diseases of the Chest, Victoria Park, E.

1879 ORMEROD, J. A., M.B., Casualty Physician to St. Bartholomew's Hospital, 25, Upper Wimpole-street, W.

1875 OSBORN, SAMUEL, 10, Maddox-street, Bond-street, W.

1876 OTTLEY, WALTER, M.B., 18, Weymouth-street, Portland-place, W.

1865 OWLES, JAMES ALLDEN, M.D., 204, Burlington-street, Liverpool.

1875 PAGE, HERBERT WILLIAM, M.A., M.C. Cantab., Assistant Surgeon to and Lecturer on Operative and Practical Surgery at St. Mary's Hospital, 28, New Cavendish-street, W.

1870 PAGET, SIR JAMES, Bart., D.C.L., F.R.S., Consulting Surgeon to St. Bartholomew's Hospital, 1, Harewood-place, Hanover-square, W.

1872 PARKER, ROBERT WILLIAM, Assistant Surgeon to the East London Children's Hospital, 8, Old Cavendish-street, W.

1874 PARKER, RUSHTON, M.B., B.S., 69, Rodney-street, Liverpool.

1853 PARKINSON, GEORGE, 50, Brook-street, Grosvenor-square, W.

1865 PAVY, FREDERICK WILLIAM, M.D., F.R.S., Physician to, and Lecturer on Medicine at, Guy's Hospital, 35, Grosvenor-street, W. (C. 1872-4.)

*Elected*

1868 PAYNE, JOSEPH FRANK, B.A., M.B., Assistant Physician to, and Lecturer on Forensic Medicine at, St. Thomas's Hospital, 78, Wimpole-street, W. (C. 1873-5.)

O.M. PEACOCK, THOMAS BEVILL, M.D. (TRUSTEE), Physician to St. Thomas's Hospital, and Physician to the City of London Hospital for Diseases of the Chest, 20, Finsbury-circus, E.C. (C. 1846-9. S. 1850-1. V.-P. 1852-6. C. 1858-61. P. 1865-6. V.-P. 1867-70.)

1872 PEARCE, JOSEPH CHANING, M.B., C.M., The Manor House, Brixton-rise, S.W.

1878 PEARSE, THOMAS FREDERICK, M.D., 141, Finborough-road, S.W.

1863 PEARSON, DAVID R., M.D., 23, Upper Phillimore-place, Kensington, W.

1878 PHILIPPS, SUTHERLAND REES, M.D., 3, Berkeley-place, Cheltenham.

1871 PHILLIPS, CHARLES DOUGLAS F., M.D., 2, Grosvenor-square, W.

1878 PHILLIPS, JOHN WALTER, 30, Stanley-street, West Melbourne, Victoria.

1877 PHILLIPS, RICHARD, 27, Leinster-square, Bayswater, W.

1875 PHILPOT, HARVEY JOHN, Dyer-street, Cirencester.

1863 PICK, THOMAS PICKERING, Surgeon to, and Lecturer on Anatomy at, St. George's Hospital, 13, South Eaton-place, S.W. (C. 1870-1.)

1878 PINK, THOMAS, Stratford St. Mary, near Colchester, Essex.

1875 PITMAN, HENRY A., M.D., Consulting Physician to St. George's Hospital, 28, Gordon-square, W.C.

1867 PITT, EDWARD G., M.D.

1876 PITTS, BERNARD, M.A., M.B., Tharning Rectory, Oundle, Huntingdonshire.

1862 POLLOCK, ARTHUR JULIUS, M.D., Physician to Charing Cross Hospital, 85, Harley-street, Cavendish-square, W. (C. 1874-5.)

1846 POLLOCK, GEORGE D. (TRUSTEE), Surgeon to St. George's Hospital, 36, Grosvenor-street, W. (S. 1850-3. C. 1854-6. V.-P. 1863-5. P. 1875-6.)

1850 POLLOCK, JAMES EDWARD, M.D. (V.-P.), Physician to the Hospital for Consumption and Diseases of the Chest, Brompton, 52, Upper Brook-street, W. (C. 1862-4. V.-P. 1879.)

1870 POORE, GEORGE VIVIAN, M.B., Assistant Physician to University College Hospital, 30, Wimpole-street, W.

1876 POST, HEINRICH, M.D., 48, Finsbury-square, E.C.

1879 POTTER, HENRY PERCY, St. Thomas's Hospital.

1854 POTTS, WILLIAM, 2, Albert-terrace, Regent's-park, N.W. (C. 1870-2.)

1866 POWELL, RICHARD DOUGLAS, M.D. (HON. SECRETARY), Physician to the Hospital for Consumption and Diseases of the Chest, Brompton, 15, Henrietta-street, Cavendish-square, W. (C. 1873-5. S. 1877-9.)

1865 POWER, HENRY, Ophthalmic Surgeon to St. Bartholomew's Hospital, 37A, Great Cumberland-place, Hyde-park, W. (C. 1876-7.)

1856 PRIESTLEY, WILLIAM OVEREND, M.D., Consulting Physician-Accoucheur to King's College Hospital, and to the St. Marylebone Infirmary, 17, Hertford-street, Mayfair, W.

*Elected*

†1848 PURNELL, JOHN JAMES, Surgeon to the Royal General Dispensary, Woodlands, Streatham-hill, S.W. (C. 1858-61.)

1865 PYE-SMITH, PHILIP HENRY, M.D., Assistant Physician to, and Lecturer on Physiology at, Guy's Hospital, 56, Harley-street, Cavendish-square, W. (C. 1874-7.)

O.M. QUAIN, RICHARD, M.D., F.R.S. (TRUSTEE), Consulting Physician to the Hospital for Consumption and Diseases of the Chest, Brompton, 67, Harley-street, Cavendish-square, W. (C. 1846-51. S. 1852-6. T. 1857-68. *Pres.* 1869-70. V.-P. 1871-3.)

1859 RADCLIFFE, CHARLES BLAND, M.D., Physician to the Westminster Hospital, 25, Cavendish-square, W.

1872 RALFE, CHARLES HENRY, M.D., M.A. (C.), Physician to the Seamen's Hospital, Lecturer on Physiological Chemistry at St. George's Hospital, 26, Queen Anne-street, W. (C. 1877-9.)

1857 RAMSKILL, J. SPENCE, M.D., Physician to the London Hospital, Physician to the National Hospital for the Paralysed and Epileptic, 5, St. Helen's-place, Bishopsgate-street, E.C.

1848 RANDALL, JOHN, M.D., Medical Officer, St. Marylebone Infirmary, 35, Nottingham-place, W. (C. 1864-6.)

1875 RANGER, W. G., 4, Finsbury-square, E.C.

1857 RANKE, HENRY, M.D., Munich.

1865 RASCH, ADOLPHUS A., M.D., Physician for Diseases of Women to the German Hospital, 7, South-street, Finsbury-square, E.C.

1870 RAY, EDWARD REYNOLDS, Dulwich, S.E.

1871 RAYNER, HENRY, M.D., Lecturer on Mental Diseases at St. Thomas' Hospital, Medical Superintendent, Middlesex County Lunatic Asylum, Hanwell, W.

1858 REED, FREDERICK GEORGE, M.D., 46, Hertford-street, Mayfair, W.

1866 REEVES, HENRY ALBERT, Assistant Surgeon to the London Hospital, 6, Grosvenor Street, W.

1875 REID, ROBERT WILLIAM, M.D., C.M., Senior Demonstrator of Anatomy and Joint Administrator of Morbid Anatomy at St. Thomas's Hospital, 10, Nottingham-place, W.

1854 REYNOLDS, J. RUSSELL, M.D., F.R.S., Consulting Physician to University College Hospital, 38, Grosvenor-street, W. (C. 1868-9.)

1871 RICHARDS, J. PEEKE, Medical Superintendent, Middlesex County Lunatic Asylum, Hanwell, W.

1866 RIVINGTON, WALTER, M.S. Lond., Surgeon to the London Hospital, 22, Finsbury-square, E.C.

‡1865 ROBERTS, DAVID LLOYD, M.D., Physician to St. Mary's Hospital, Manchester, 23, St. John's-street, Manchester.

*Elected*

1871 ROBERTS, FREDERICK THOMAS, M.D., Professor of Materia Medica at University College, Assistant Physician, University College Hospital, and to the Hospital for Consumption, &c., Brompton, 53, Harley-street, Cavendish-square, W.

1876 ROBERTS, WILLIAM HOWLAND, M.D., Surgeon, Madras Army, Madras, [East India United Service Club, St. James's Square].

1859 ROBINSON, FREDERICK, M.D., Surgeon-Major, Scots Fusilier Guards 47, Claverton-terrace, St. George's-road, S.W. (C. 1871-3.)

1856 ROBINSON, THOMAS, M.D., 5, Woburn-square, W.C.

1858 ROLLESTON, GEORGE, M.D., F.R.S., Linacre Professor of Anatomy, University of Oxford, Park Grange, Oxford.

1876 ROPER, ARTHUR, 17, Granville Park, Blackheath, S.E.

1858 ROSE, HENRY COOPER, M.D., Surgeon to the Hampstead Dispensary, High-street, Hampstead, N.W. (C. 1873-4.)

1876 ROSE, WILLIAM, M.B., B.S., Assistant Surgeon to King's College, 21, Welbeck Street, Cavendish-square, W.

1879 ROSS, JAMES, M.D., C.M., 335, Oxford-street, Manchester.

1875 ROSSITER, GEORGE FREDERICK, 14, Melina-crescent, Weston-super-Mare.

1877 ROTH, BERNARD, M.S., 48, Wimpole Street, Cavendish-square, W., and 18, Grand Parade, Brighton.

1858 ROUSE, JAMES, Surgeon to St. George's Hospital, 2, Wilton-street, Grosvenor-place, S.W.

1869 RUTHERFORD, WILLIAM, M.D., F.R.S., Professor of Physiology in the University of Edinburgh, 14, Douglas Crescent, Edinburgh.

1853 SALTER, JAMES A., M.B., F.R.S., Dental Surgeon to Guy's Hospital, 17, New Broad-street, City, E.C. (C. 1861-3.)

1852 SANDERSON, HUGH JAMES, M.D., 26, Upper Berkeley-street, Portman-square, W.

1854 SANDERSON, JOHN BURDON, M.D., F.R.S., Jodrell Professor of Human Physiology at University College (C. 1864-7. V.-P. 1873-4.), 26, Gordon-square, W.C.

1877 SANGSTER, ALFRED, M.B., B.A., 7, Old Burlington-street, W.

1875 SANGSTER, CHARLES, 148, Lambeth-road, S.E.

1877 SANKEY, H. R. O., Sandywell-park, near Cheltenham.

‡1847 SANKEY, W. H. OCTAVIUS, M.D., Sandywell-park, near Cheltenham. (C. 1855.)

1871 SAUNDERS, CHARLES EDWARD, M.D., 21, Lower Seymour-street, Portman-square, W.

1873 SAVAGE, GEORGE HENRY, M.D., Bethlem Royal Hospital, St. George's-road, S.E.

1854 SCOTT, JOHN, 10, Tavistock-square, W.C.

‡1847 SEATON, EDWARD C., M.D., Medical Officer of the Local Government Board, 14, Gordon-street, Gordon-square, W.C. (C. 1859-61.)

*Elected*

1877 SEMON, FÉLIX, M.D., 6, Chandos-street, Cavendish-square.

1852 SEMPLE, ROBERT HUNTER, M.D., Physician to the Bloomsbury Dispensary, 8, Torrington-square, W.C. (C. 1859-61.)

1872 SERGEANT, EDWARD, Medical Officer of Health, Bolton, Yorkshire.

1876 SHARKEY, SEYMOUR, M.D., St. Thomas's Hospital, S.E.

1877 SHEPPARD, CHARLES E., 7, Addison-gardens, W.

1856 SHILLITOE, BUXTON, Surgeon to the Great Northern Hospital, and to the Lock Hospital, 2, Frederick's-place, Old Jewry, E.C.

1855 SIBLEY, SEPTIMUS W. (V.-P.), 7, Harley-street, Cavendish-square, W. (C. 1863-5. V.-P. 1879.)

1875 SIDDALL, JOSEPH BOWER, M.D., C.M., 24, The Mall, Clifton, Bristol.

1847 SIEVEKING, EDWARD H., M.D., Physician to St. Mary's Hospital, 17, Manchester-square, W. (C. 1854-7. V.-P. 1864-5.)

O.M. SIMON, JOHN, C.B., D.C.L., F.R.S., Consulting Surgeon to St. Thomas's Hospital, 40, Kensington-square, W. (C. 1846-8. V.-P. 1855-9. *Pres.* 1867-8. V.-P. 1869-71.)

1866 SIMS, FRANCIS MANLEY BOLDERO, Assistant Surgeon to the Hospital for Diseases of the Skin, and Surgeon to the St. George's Dispensary, 12, Hertford-street, May-fair, W.

1865 SIMS, J. MARION, M.D., 267, Madison-avenue, New York.

1877 SKINNER, WILLIAM A., 45, Upper Belgrave-street, S.W.

1875 SMEE, ALFRED HUTCHINSON, 7, Finsbury-circus, E.C.

1872 SMITH, GILBART, M.B., Assistant Physician to the London Hospital, Physician to the Royal Hospital for Diseases of the Chest, City-road, Visiting Physician to the Margaret-street Infirmary for Consumption, 68, Harley-street, Cavendish-square, W.

1875 SMITH, GEORGE JOHN MALCOLM, M.B., Hurstpierpoint, Sussex.

1863 SMITH, HENRY, Surgeon to, and Professor of Surgery at, King's College Hospital, 82, Wimpole-street, Cavendish-square, W. (C. 1873-4.)

1866 SMITH, HEYWOOD, M.D., Physician to the Hospital for Women, 2, Portugal-street, Grosvenor-square, W.

SMITH (P. H. PYE), see PYE-SMITH.

1846 SMITH, PROTHEROE, M.D., Physician to the Hospital for Women, 42, Park-street, Grosvenor-square, W.

1873 SMITH, RICHARD T., M.D., Physician to the St. Pancras Dispensary, 53, Haverstock-hill, N.W.

1869 SMITH, ROBERT SHINGLETON, M.D., Lecturer on Physiology, Bristol Medical School, 9, Richmond-hill, Clifton, Bristol.

1878 SMITH, HERBERT URMSON, M.B., St. Thomas's Hospital.

1879 SMITH, ROBERT, M.A., M.B., Medical Registrar, Charing Cross Hospital, W.C.

1856 SMITH, SPENCER, Consulting Surgeon to St. Mary's Hospital, 92, Oxford-terrace, W.

*Elected*

1856 Smith, Thomas, Surgeon to St. Bartholomew's Hospital, 5, Stratford-place, Oxford-street, W. (C. 1867-9. V.-P. 1877-8.)

1866 Smith, William, Melbourne, Australia.

1870 Smith, William Johnson (C.), Surgeon, Seamen's Hospital, Greenwich, S.E. (C. 1879.)

1869 Smith, William Wilberforce, M.D., 2, Eastbourne-terrace, Bishop's-road, W.

1870 Snow, William Vicary, M.D., Richmond Gardens, Bournemouth.

1868 Southey, Reginald, M.D., Physician to St. Bartholomew's Hospital, 6, Harley-street, Cavendish-square, W.

1873 Sparks, Edward Isaac, M.B. [abroad].

1868 Spry, G. Frederick Hume, M.D., 2nd Life Guards, Army and Navy Club, Pall-mall, S.W.

1855 Squire, William, M.D., 6, Orchard-street, Portman-square, W. (C. 1870-2.)

1861 Squire, Alexander Balmanno, 24, Weymouth-street, Portland-place, W.

1876 Startin, James, 17, Sackville-street, Piccadilly, W.

1854 Stewart, William Edward, 16, Harley-street, Cavendish-square, W.

1879 Stirling, Edward Charles, Assistant Surgeon to St. George's Hospital, 60, Great Cumberland-place, Hyde-park, W.

†1853 Streatfeild, J. F., Surgeon to the Royal London Ophthalmic Hospital, Moorfields, and Ophthalmic Surgeon to University College Hospital, 15, Upper Brook-street. W.

1875 Sturge, W. A., M.D., Assistant Physician to the Royal Free Hospital, 9, Wimpole-street, Cavendish-square, W.

1863 Sturges, Octavius, M.D., Physician to the Westminster Hospital, 85, Wimpole-street, Cavendish-square, W.

1871 Sutherland, Henry, M.D., 6, Richmond-terrace, Whitehall, S.W.

1876 Sutro, Sigismund, M.D., Senior Physician to the German Hospital, 37A, Finsbury-square, E.C.

1864 Sutton, Henry G., M.B., Physician to, and Lecturer on Medicine at, the London Hospital, Physician to the City of London Hospital for Diseases of the Chest, 9, Finsbury-square, E.C. (C. 1875-6.)

‡1867 Swain, William Paul, 20, Ker-street, Devonport.

‡1857 Symonds, Frederick, Surgeon to the Radcliffe Infirmary, 35, Beaumont-street, Oxford.

1870 Tait, Robert Lawson, Surgeon to the Birmingham and Midland Hospital for Women, 7, Great Charles-street, Birmingham.

‡1856 Tapp, W. Denning, Hillside-house, Hatherley-road, Cheltenham.

1864 Tatham, John, M.D., Physician to the Hospital for Consumption and Diseases of the Chest, Brompton, 12, George-street, Hanover-square, W.

*Elected*

1870 TAY, WARREN, Surgeon to, and Demonstrator of Practical Anatomy at, the London Hospital, 4, Finsbury-square, E.C.

1871 TAYLOR, FREDERICK, M.D. (C.), Assistant Physician to Guy's Hospital, 15, St. Thomas's-street, S.E. (C. 1879.)

1861 TEEVAN, WILLIAM FREDERIC, Surgeon to the West London Hospital, 10, Portman-square, W.

1879 THIN, GEORGE, M.D., 22, Queen Anne-street, Cavendish-square, W.

1870 THOMAS, JOHN DAVIES, M.B., University College Hospital (India).

1852 THOMPSON, SIR HENRY, Knt., Emeritus Professor of Clinical Surgery in University College, 35, Wimpole-street, Cavendish-square, W. (S. 1859-63. C. 1865-67. V.-P. 1868-70.)

1874 THORNTON, JOHN KNOWSLEY, M.B., Surgeon to the Samaritan Free Hospital for Women and Children, 83, Park-street, Grosvenor-square.

1872 THORNTON, WILLIAM PUGIN, Surgeon to the Hospital for Diseases of the Throat, and to the St. Marylebone General Dispensary, 42, Devonshire-street, Portland-place, W.

1865 THOROWGOOD, J. C., M.D., Lecturer on Materia Medica at the Middlesex Hospital, Physician to the City of London Hospital for Diseases of the Chest, 61, Welbeck-street, W. (C. 1876-78.)

1877 TIBBITS, HERBERT, F.R.C.P. Ed., Medical Superintendent of the National Hospital for the Paralysed and Epileptic, 30, New Cavendish-street, W.

1856 TOMES, J., F.R.S., Consulting Dental Surgeon to the Middlesex Hospital, 37, Cavendish-square, W. (C. 1867-9.)

1864 TONGE, MORRIS, M.D., Harrow-on-the-hill, Middlesex.

1872 TOWNSEND, THOMAS SUTTON, 68, Queen's Gate, South Kensington.

1851 TROTTER, JOHN W., Surgeon-Major, Coldstream Guards, Bossall Vicarage, York. (C. 1865-9.)

1859 TRUMAN, EDWIN THOMAS, Surgeon-Dentist in Ordinary to Her Majesty's Household, 23, Old Burlington-street, W.

1867 TUCKWELL, HENRY MATTHEWS, M.D., Physician to the Radcliffe Infirmary, 64, High-street, Oxford.

1858 TUDOR, JOHN, Dorchester, Dorset.

†1875 TURNER, FRANCIS CHARLEWOOD, M.D., Physician to the London Hospital, 15, Finsbury-square, E.C.

1863 TURNER, JAMES SMITH, Dental Surgeon to the Middlesex Hospital, 12, George-street, Hanover-square, W.

1858 TURTLE, FREDERICK, Clifton Lodge, Woodford, Essex.

1878 TYRRELL, WALTER, St. Thomas's Hospital.

1854 VASEY, CHARLES, 5, Cavendish-place, Cavendish-square, W.

1867 VENNING, EDGCOMBE, late Surgeon, 1st Life Guards, 87, Sloane-street.

1868 VINCENT, OSMAN, Surgeon to the National Orthopædic Hospital, 45, Seymour-street, Portman-square, W.

*Elected*

†1867 WAGSTAFFE, WILLIAM WARWICK (C.), B.A., Assistant Surgeon to St. Thomas's Hospital, 2, Palace-road, Albert Embankment, S.E. (C. 1874, C. 1878-9. S. 1875-7.)

O.M. WAITE, CHARLES D., M.D., Senior Physician to the Westminster General Dispensary, 3, Old Burlington-street, W.

1873 WALSHAM, WILLIAM J., M.B., C.M., Demonstrator of Anatomy and Operative Surgery at St. Bartholomew's Hospital, Surgeon to the Metropolitan Free Hospital and to the Royal Hospital for Diseases of the Chest, 27, Weymouth-street, Portland-place.

1859 WALTERS, JOHN, M.B., Reigate, Surrey.

1847 WARD, T. OGIER, M.D., 12, Place de la Mare, Caen. (C. 1851-3.)

1858 WARDELL, JOHN RICHARD, M.D., Calverley-park, Tunbridge Wells.

1877 WARNER, FRANCIS, M.D., 15, Finsbury-square, E.C.

1878 WATNEY, HERBERT, M.D., Lecturer on Materia Medica at St. George's Hospital, 1, Wilton-crescent, S.W.

1877 WATERHOUSE, CHARLES, M.B., M.C., Aigburth, Liverpool.

1855 WATSON, SIR THOMAS, Bart., M.D., F.R.S., 16, Henrietta-street, Cavendish-square, W. (*Pres.* 1857-8. V.-P. 1859-63.)

1865 WATSON, W. SPENCER, Surgeon to the Great Northern Hospital, Surgeon to the Royal South London Ophthalmic Hospital, 7, Henrietta-street, Cavendish-square, W. (C. 1875-6.)

1860 WAY, JOHN, M.D., 4, Eaton-square, S.W. (C. 1873-4.)

†1858 WEBER, HERMANN, M.D. (V.-P.), Physician to the German Hospital, 10, Grosvenor-street, Grosvenor-square, W. (C. 1867-70. V.-P. 1878-9.)

1876 WEIR, ARCHIBALD, M.D., St. Mungho's, Great Malvern.

1864 WELCH, THOMAS DAVIES, M.D., Wilton Lodge, Queen's-road, Weybridge, Surrey.

1861 WELLS, JOHN SOELBERG, Ophthalmic Surgeon to King's College Hospital, and Surgeon to the Royal London Ophthalmic Hospital, 16, Savile-row, W.

1853 WELLS, THOMAS SPENCER, Surgeon to the Samaritan Free Hospital for Women and Children, 3, Upper Grosvenor-street, W. (C. 1865-8. V.-P. 1876-7.)

†1851 WEST, CHARLES, M.D., Consulting Physician to the Hospital for Sick Children, 61, Wimpole-street, Cavendish-square, W. (C. 1856-7.)

1877 WEST, SAMUEL, M.B., Assistant Physician to the City of London Hospital for Diseases of the Chest, Victoria-park, Casualty Physician to St. Bartholomew's Hospital, 8, Guilford-street, Russell-square, W.C.

1878 WHARTON, HENRY THORNTON, M.A., 39, St. George's-road, Kilburn.

1867 WHIPHAM, THOMAS TILLYER, M.B., Physician to, and Lecturer on Clinical Medicine at, St. George's Hospital, 37, Green-street, Grosvenor-square, W.

1869 WHIPPLE, JOHN H. C., M.D., Assistant Surgeon, 1st Battalion Coldstream Guards, Hospital, Vincent-square, Westminster, S.W.

1877 WHITE, CHARLES HAYDON, Brathay House, Tufnell-park, N.

*Elected*

‡1868 WHITEHEAD, WALTER, 248, Oxford-road, Manchester.

1877 WHITMORE, WILLIAM TICKLE, 7, Arlington-street, S.W.

1870 WICKSTEED, FRANCIS WILLIAM, Chester House, Weston-super-Mare.

1879 WILCOX, HENRY, M.B., Hurst-villa, Lewisham High-road, S.E.

1867 WILCOX, RICHARD WILSON, Temple-square, Aylesbury, Bucks.

1869 WILKIN, JOHN F., M.D., M.C., New Beckenham, Kent.

1871 WILKINSON, J. SEBASTIAN, Surgeon to the Central London Ophthalmic Hospital, 83, Wimpole-street, W.

1864 WILKS, ALFRED G. P., M.A., M.B., Charlemont House, Spencer-road, Ryde, Isle of Wight.

1855 WILKS, SAMUEL, M.D., F.R.S., Physician to Guy's Hospital, 77, Grosvenor-street, W. (C. 1857-60. V.-P. 1869-72.)

1869 WILLIAMS, ALBERT, M.D., 60, Kirkdale, Sydenham, S.E.

O.M. WILLIAMS, C. J. B., M.D., F.R.S., Consulting Physician to the Hospital for Consumption and Diseases of the Chest, Brompton [47, Upper Brook-street, Grosvenor-square, W.]. (*Pres.* 1846-7. V.-P. 1848-52. C. 1853-5. V.-P. 1858-61.)

‡1858 WILLIAMS, CHARLES, Surgeon to the Norfolk and Norwich Hospital, 9, Prince of Wales-road, Norwich.

1866 WILLIAMS, CHARLES THEODORE, M.B., Physician to the Hospital for Consumption and Diseases of the Chest, Brompton, 47, Upper Brook-street, Grosvenor-square, W. (C. 1875-8.)

1872 WILLIAMS, JOHN, M.D. (C.), Assistant Obstetric Physician to University College Hospital, 28, Harley-street, Cavendish-square, W. (C. 1878-9.)

1864 WILLIAMS, W. RHYS, M.D., Commissioner in Lunacy, 19, Whitehall-place, S.W.

1876 WILLIAMSON, JAMES MANN, M.D., Ventnor, Isle of Wight.

1863 WILLIS, FRANCIS, M.D., Braceborough, Stamford.

1859 WILSON, EDWARD THOMAS, M.B., Montpelier-terrace, Cheltenham.

1859 WILSON, ROBERT JAMES, F.R.C.P. Ed., 7, Warrior-square, St. Leonard's-on-Sea.

1863 WILTSHIRE, ALFRED, M.D., Joint Lecturer on Midwifery at St. Mary's Hospital, 57, Wimpole-street, Cavendish-square, W.

‡1861 WINDSOR, THOMAS, Surgeon to the Salford Royal Hospital, 44, Ardwick-green, Manchester.

1874 WISEMAN, JOHN GREAVES, Dearden-street, Ossett, Yorkshire.

1865 WITHERBY, WILLIAM H., M.D., Pitt-place, Coombe, Croydon.

1850 WOOD, JOHN, F.R.S., Surgeon to, and Professor of Clinical Surgery at, King's College Hospital, 68, Wimpole-street, W. (C. 1857-9. V.-P. 1872-4.)

1854 WOOD, WILLIAM, M.D., Physician to St. Luke's Hospital, 99, Harley-street, W.

*Elected*

1876 Wood, William Edward Ramsden, M.A., M.B. Cantab., Bethlem Royal Hospital, St. George's-road, S.E.

1877 Woodhouse, Thomas James, M.D., Ranelagh Lodge, Bridge-street, Fulham, S.W.

1865 Workman, Charles John, M.D., Titherley, Teignmouth, Devon.

1863 Worley, William Charles, 43, De Beauvoir-road, N.

1859 Wotton, William Gordon, King's Langley, Herts.

1869 Wyman, W. S., M.D., Westlands, Upper Richmond-road, Putney, S.W.

1869 Yeo, J. Burney, M.D., Physician with Charge of Out-Patients to King's College Hospital, and Assistant Physician to the Brompton Hospital for Consumption, 44, Hertford-street, Mayfair, W.

1872 Young, Henry, M.B., Monte Video, South America.

# ANNUAL REPORT OF COUNCIL.

## 1878-9.

In presenting their Annual Report to the members of the Pathological Society the Council are able to congratulate them on the continuance of the Society's prosperity, and on the work done during the past year.

The total number of the members is now 594, thirty-eight having been elected in the session 1877—78.

The Society has to regret the loss of six members by death:—Dr. Allan Douglas Mackay, Dr. William M. Tredennick, Mr. W. Pattison Cromarty, Mr. Charles Hunter, Mr. T. Carr Jackson, and Mr. John Hilton; and, from among the honorary members, Karl Rokitansky.

Mr. Hilton was formerly President of the Society, and for many years surgeon to Guy's Hospital, where he was a distinguished clinical teacher. He was great both as a pathologist and as a surgeon; and both as a clinical teacher and as President of this Society he displayed a singular ability in turning his pathological inquiries into directions of usefulness in surgical practice.

Karl Rokitansky, for more than forty years Professor of Pathological Anatomy in the University of Vienna, was best known in this country and throughout the medical world as the author of his great work on pathological anatomy, the materials for which were derived from upwards of 30,000 *post-mortem* examinations, and which may be said to have established a new era in pathological research. It did as much for pathological anatomy as Morgagni's

great work, 'De Sedibus et Causis Morborum,' had done a century before. Its translation into English made it familiar to English pathologists and physicians, and thus did much to stimulate pathological inquiry, and improve clinical diagnosis in this country. For many years Rokitansky's lectures and demonstrations attracted to Vienna numbers of medical men from all nations, who were witnesses of his untiring industry, sound judgment, and candid research. In July, 1875, he resigned his professorship, and died in July, 1878.

Five members of the Society have resigned.

The special subject of debate, illustrated by specimens, in the latter part of the past session, was formed by 'Diseases of the Lymphatic System, including Lymphadenoma and Leukæmia,' and the Council feel that the Society is much indebted to Dr. Wilks, who introduced the subject, and to those gentlemen who exhibited illustrative specimens and took part in the discussion which followed. A valuable and permanent record of the present state of knowledge of this subject has been thus obtained, and will be found in the current volume of the 'Transactions.' The other pathological records contained in the same volume are not inferior, the Council believe, to those of its predecessors; and they would refer to the number and beauty of the illustrations as a fair subject also for congratulation.

As the special subject for illustration by specimens, and for debate during the present session, the Council have decided to adopt that of 'Lardaceous Disease in reference to its Anatomical Distribution and Pathological Relations.' Dr. Dickinson has consented to introduce the subject at the second meeting of the Society in March.

A preliminary report of the committee appointed to investigate the subject of 'Pyæmia, Septicæmia, and allied Diseases' has been received, signed by Charles Henry Ralfe, W. Smith Greenfield, Marcus Beck, and Jeremiah McCarthy; and a copy has been forwarded to the Local Government Board, which, it will be remembered, has contributed £350 towards the cost of the inquiry.*

It has been decided by the Council to increase and, at the same time, to limit the number of Honorary Members of the Society to eighteen; and, to fill up the vacancies in the list, they have recommended nine gentlemen, since elected by the Society, who, they

* In the Treasurer's account for the past year the sum of only £300 appears; £50 having been advanced in a previous year to the Committee.

believe, are well worthy of the honour conferred on them. (See List of Honorary Members.)

The income of the Society during the past year has amounted to £583 6s. 4d., and the expenditure to £529 17s. 8d., of which the sum of £360 6s. 1d. represents the cost (to the Society) of the volume of 'Transactions.'

The sum invested in Consols remains the same as last year, viz. £1067 15s. 1d.

C. MURCHISON.

---

In order to facilitate the Exhibition of Specimens, and to save the time of the Society's meetings, it was decided by the Council during the past Session that arrangements should be made under which Preparations, Drawings, &c., may be shown without any *oral* communication.

The following are the conditions under which such Exhibitions may be made:—

*a.* The Specimens or Drawings must be ready for inspection in the Society's Rooms not later than 8 p.m., and must remain on the table until ten minutes after the close of the meeting.

*b.* A card, provided by the Society, must be placed with the Specimen, and on it must be clearly written a short account of the Specimen, comprising all the particulars intended for publication. The Exhibitor (or his representative) must be present at the meeting, and be willing to furnish additional details if asked for.

*c.* At every meeting of the Society the Rooms will be open for the inspection of Specimens, &c., at 8 o'clock; the Chair will be taken as usual at 8.30 p.m.

*d.* The list of Specimens exhibited by card will be read to the meeting by the President; and such Specimens will be taken for consideration and discussion in the course of the meeting, alternately with other Specimens, at the discretion of the President.

# THE PATHOLOGICAL SOCIETY,

**Dr.** *In Account with the Treasurer*, J. W. Hulke, Esq., *32nd Session*, 1877–78. **Cr.**

| | £ | s. | d. | £ | s. | d. |
|---|---|---|---|---|---|---|
| By *Balance* at Union Bank of London, 1st January, 1878 | 11 | 14 | 0 | 11 | 14 | 0 |
| *Subscriptions:* | | | | | | |
| 385 Annual Subscriptions for 1877-78 at £1 1*s.* | 404 | 5 | 0 | | | |
| 3 Arrears, 1868-70 | 3 | 3 | 0 | | | |
| 37 Admission Fees | 38 | 17 | 0 | | | |
| 1 Non-Resident's Fee | 2 | 2 | 0 | | | |
| | | | | 448 | 7 | 0 |
| *Transactions, Sales of:* May | 61 | 18 | 6 | | | |
| September | 29 | 17 | 0 | | | |
| | | | | 91 | 15 | 6 |
| *Dividends* on £1067 15*s.* 1*d.* Consols, January | 15 | 16 | 3 | | | |
| July | 15 | 13 | 7 | | | |
| | | | | 31 | 9 | 10 |
| Total ordinary income | 583 | 6 | 4 | 583 | 6 | 4 |

| | Dr. | | | Cr. | | |
|---|---|---|---|---|---|---|
| Dr. *Government Grant towards investigation of Pyæmia*, placed in Union Bank of London (see Report, p. xxxvi) | 300 | 0 | 0 | | | |
| Cr. Repaid advance by Hon. Sec. of Society | | | | 1 | 8 | 0 |
| | 300 | 0 | 0 | 1 | 8 | 0 |
| Balance | | | | 298 | 12 | 0 |
| | | | | £300 | 0 | 0 |

| | £ | s. | d. | £ | s. | d. |
|---|---|---|---|---|---|---|
| To *Meetings:* | | | | | | |
| Payment to Royal Medical and Chirurgical Society for use of Rooms, Gas, &c. | 63 | 0 | 0 | | | |
| Refreshments, Waiters, &c. | 36 | 15 | 0 | | | |
| Richard Coldry, Management | 5 | 0 | 0 | | | |
| Microscopes and Lamps (Pillischer) | 12 | 2 | 6 | | | |
| | | | | 116 | 17 | 6 |
| *Transactions:* Vol. XXIX (750 copies): | | | | | | |
| Printing, Binding, and Distributing (Adlard) | 198 | 4 | 6 | | | |
| Lithography (Mintern Bros.) | 71 | 19 | 0 | | | |
| Chromolithography (Burgess) | 50 | 5 | 7 | | | |
| Ditto and Cuts (Lister) | 15 | 0 | 0 | | | |
| Woodcuts (Butterworth) | 21 | 14 | 0 | | | |
| Index (Wheatley) | 3 | 3 | 0 | | | |
| | | | | 360 | 6 | 1 |
| *Stationery* (Wodderspoon) | 8 | 16 | 10 | | | |
| (Odell and Ives) | 5 | 17 | 6 | | | |
| | | | | 14 | 14 | 4 |
| *Secretariat and Treasury:* | | | | | | |
| Assistance to Honorary Secretary (Mr. Wheatley) | 7 | 7 | 0 | | | |
| Posting Ledgers (Mr. McDermott) | 1 | 10 | 0 | | | |
| Collecting Subscriptions (Mr. Wheatley) | 15 | 18 | 6 | | | |
| Petty Cash (Hon. Secretaries) | 4 | 8 | 7 | | | |
| (Mr. Wheatley) | 7 | 3 | 6 | | | |
| | | | | 36 | 7 | 7 |
| *A new Cheque-Book* | 0 | 4 | 2 | 0 | 4 | 2 |
| *Pyæmia Committee* | 1 | 8 | 0 | 1 | 8 | 0 |
| Total Expenditure | 529 | 17 | 8 | 529 | 17 | 8 |
| Balance | 53 | 8 | 8 | 53 | 8 | 8 |
| | £583 | 6 | 4 | 583 | 6 | 4 |

Audited and compared with the Vouchers and found correct.

*Auditors* { J. PEARSON IRVINE, M.D.
RICKMAN J. GODLEE.

## LIST OF SPECIMENS AND REPORTS

BROUGHT BEFORE THE SOCIETY DURING THE SESSION 1878-79.

---

PAGE

REPORT OF THE COMMITTEE appointed by the Pathological Society of London to investigate the nature and causes of those infective diseases known as PYÆMIA, SEPTICÆMIA, AND PURULENT INFECTION By CHARLES H. RALFE, M.D., W. S. GREENFIELD, M.D., MARCUS BECK, and JEREMIAH MCCARTHY 1

---

### I.—DISEASES, ETC., OF THE NERVOUS SYSTEM.

1. Diffuse punctiform hæmorrhages in substance of cerebral hemispheres, in an instance of extreme congestion of brain due to obstructed pulmonary circulation By SIDNEY COUPLAND, M.D. 189
2. Hæmorrhage into the cerebellum; rupturing into the fourth ventricle By W. ALLEN STURGE, M.D. 194
3. Dermoid cyst of the brain By J. PEARSON IRVINE, M.D. 195
4. Spinal cord from a case of infantile paralysis By FREDERICK TAYLOR, M.D. 197
5. A portion of the spinal cord, with drawings and microscopical specimens, from a case of acute anterior poliomyelitis in a child, fatal within six weeks from the onset By F. CHARLEWOOD TURNER, M.D. 202

PAGE

6. Case of infantile paralysis
By HENRY HUMPHREYS, M.D. 211
7. On the pathology of tetanus and hydrophobia
By JAMES ROSS, M.D. 215

---

## II.—DISEASES, ETC., OF THE ORGANS OF RESPIRATION.

1. A peculiar degeneration of the lung of uncertain nature
By SAMUEL WEST, M.B. 220
2. Chronic lobar pneumonia; grey induration; gangrene and secondary suppuration in lower lobe of lung
By SIDNEY COUPLAND, M.D. 224
3. Nodular fibroid phthisis, ? syphilitic
By JAMES F. GOODHART, M.D. 232
4. Two cases of tubercle of the lung, spreading from yellow elastic nodules in the lung (? gummata)
By JAMES F. GOODHART, M.D. 233
5. Two cases of pneumothorax of the right side
By SAMUEL WEST, M.B. 236
6. Cases illustrating the lung changes caused by compression of the large bronchial tubes
By J. PEARSON IRVINE, M.D. 238
7. Mediastinal tumour invading the right lung and occluding its bronchi By R. DOUGLAS POWELL, M.D. 249
8. Specimens of bronchial gland disease
By THOMAS BARLOW, M.D. 254

---

## III.—DISEASES, ETC., OF THE ORGANS OF CIRCULATION.

1. Case of stenosis of the pulmonary artery from disease of the valves, probably of congenital origin
By T. B. PEACOCK, M.D. 258

PAGE

2. Malformation of the heart; stenosis of the pulmonary valve, with dilatation of the pulmonary artery and hypertrophy of the right ventricle; patency of the foramen ovale, with a cribriform opening in the septum of the auricles (ductus arteriosus closed)
By DAVID W. FINLAY, M.D. 262

3. Defect in the ventricular septum of the heart, probably congenital; unusual site of aperture
By SIDNEY COUPLAND, M.D. 266

4. Congenital heart disease; pulmonary stenosis, with dilated pulmonary artery above the stenosis
By THOMAS BARLOW, M.D. 272

5. Case of congenital malformation of the heart
By H. RADCLIFFE CROCKER, M.D. 273

6. Case of congenital malformation of the heart
By H. RADCLIFFE CROCKER, M.D. 275

7. Case of congenital malformation of the heart
By H. RADCLIFFE CROCKER, M.D. 276

8. Disease of the aortic valves originating in congenital defect By T. B. PEACOCK, M.D. 277

9. Penetrating wound of the heart, involving the transfixion of both ventricles, but not causing death for several minutes By J. P. H. BOILEAU, M.D. 278

10. Case of rapid enlargement of the heart
By JAMES F. GOODHART, M.D. 279

11. Case of warty growth on tricuspid valves
By H. RADCLIFFE CROCKER, M.D. 281

12. Rupture of the aorta within the pericardium
By NORMAN MOORE, M.D. 283

13. Unusually large aneurysm of the ascending portion of the arch of the aorta which burst externally
By HENRY A. LEDIARD, M.D., F.R.C.S. 284

14. A case of three aneurysms arising from the descending aorta By HOTHAM G. ORLEBAR, M.B. 286

15. Aneurysm of the abdominal aorta associated with disease of the aortic valves; death from uræmia
By HENRY A. LEDIARD, M.D., F.R.C.S. 288

16. Cured subclavian aneurysm By SYDNEY JONES, M.B. 292

PAGE

17. Progressive thrombosis of the veins of one lower extremity, with consecutive embolism of the pulmonary artery, from a case which had previously undergone an operation By ROBERT LYELL, M.D. 294

---

## IV. DISEASES, ETC., OF THE ORGANS OF DIGESTION.

1. Case of poisoning by sulphuric acid By NORMAN MOORE, M.D. 297
2. Perforating ulcers of the ileum from obstruction after ovariotomy By ALBAN DORAN 298
4. Note on the morbid anatomy of hypertrophic cirrhosis of the liver By ROBERT SAUNDBY, M.D. 301
5. Cases of abscess of liver By NORMAN MOORE, M.D. 306

---

## V. DISEASES, ETC., OF THE GENITO-URINARY ORGANS.

1. Protrusion of orifice of ureter through meatus urinarius in a female child By N. DAVIES-COLLEY 310
2. Cases of spontaneous disruption of vesical calculi. By Dr. KRAUS, of Carlsbad (Communicated by WILLIAM M. ORD, M.D.) 314
3. Report on specimens of spontaneous fracture of calculi within the bladder, exhibited by Mr. Croft By WILLIAM M. ORD, M.D. 318
4. Suppurative phlebitis of the vesical, iliac, and femoral veins of the left side following cystitis By W. J. WALSHAM 321
5. Gangrene of the entire corpora cavernosa and spongiosum penis, probably from thrombosis of the iliac vein consequent upon rheumatic phlebitis By JOHN GAY 323
6. Recto-vesical fistula, septicæmia; terminating fatally By ALEXANDER MORISON, M.D. 326

## VI. DISEASES, ETC., OF THE OSSEOUS SYSTEM.

PAGE

1. Specimens of craniotabes By THOMAS BARLOW, M.D. 332
2. Specimens of disease of skull in congenital syphilis By THOMAS BARLOW, M.D. 333
3. Les lésions osseuses de la syphilis héréditaire By M. JULES PARROT (Introduced by Dr. THOMAS BARLOW) 339
4. On lesions of the cranial bones in congenital syphilis (illustrated by three living cases) By T. BARLOW, M.D., and D. B. LEES, M.D. 350
5. Incipient synovitis in hip-joint By ARTHUR E. BARKER 353
6. Acute disease of the hip-joint By JOHN H. MORGAN 354
7. Osseous tumour of superior maxilla By JAMES F. GOODHART, M.D., for BRANFORD EDWARDS . . . . . 358

---

## VII. MORBID GROWTHS.

1. Rodent ulcer By W. TILBURY FOX, M.D., and T. COLCOTT FOX, M.B. . . . . 360
2. Cancerous ulcer of the face By EDWARD BELLAMY and ALFRED SANGSTER, M.B. 371
   Report. By J. F. GOODHART and H. T. BUTLIN for *Committee on Morbid Growths* 373
3. Further illustrations of the histology of rodent ulcers By GEORGE THIN, M.D. 373
4. A case of multiple (lymphoid ?) tumours, some of which disappeared under observation. By JAMES GAIRDNER, M.D., and JOSEPH COATS, M.D. (Introduced by the President) 387
   Report. By J. F. GOODHART and H. T. BUTLIN for *Committee on Morbid Growths* 394

PAGE

5. Sequel of a case of multiple round-celled sarcoma in a boy (lympho-sarcoma) By HENRY T. BUTLIN 396
6. Sarcoma of the scapula in an infant, followed by multiple sarcomata in various organs and tissues By JOHN H. MORGAN 399
7. Subperiosteal sarcoma of femur By JOHN H. MORGAN 403
8. Recurrent fibroid tumour of the scapula By CHRISTOPHER HEATH 405
   Report By MARCUS BECK and R. J. GODLEE for *Committee on Morbid Growths* 406
9. Primary epithelioma of tonsil (living specimen) By LENNOX BROWNE 407
10. Small round-celled sarcoma of the upper jaw By W. J. WALSHAM 410
11. A specimen of melanotic sarcoma of the eyeball. By W. SPENCER WATSON 410
12. Case of unilateral cancer By P. M. BRAIDWOOD, M.D. (Introduced by the President) 413
13. Colloid cancer of the breast By RICKMAN JOHN GODLEE 416
14. Lymphadenomatous tumours of scalp and neck By W. MORRANT BAKER 417
15. Primary sarcoma of the suprarenal capsule, with secondary growth in the lung By SAMUEL WEST, M.B. 419
16. On the changes in the sweat-glands in cancer and leprosy as illustrating the extremes of atrophic and hypertrophic pathology By GEORGE HOGGAN, M.B. 421
16. Blood cyst removed from the neck By JOHN GAY 435

---

## VIII. DISEASES OF THE SKIN.

1. Specimen of the affection of the hair which has been described as Piedra, and as Trichoclasia or Trichorrhexia nodosa By P. H. PYE-SMITH, M.D. 439
2. Piedra—a new disease of the hair By MALCOLM MORRIS 441

PAGE

3. The growth of the fungi in ringworm and favus comparatively studied By George Hoggan, M.B. 444
4. Disseminated clavus of the hands and feet By N. Davies-Colley, M.A., M.C. 451
Report. By H. G. Howse and C. Hilton Fagge, M.D. 453
5. Eczema squamosum (vr. hystrix) of leg, associated with elephantiasis, from long-continued congestion due to backward dislocation of the knee-joint By H. G. Howse, M.S. 454
6. Molluscum fibrosum By John Wood. (Communicated by Royes Bell) 458
7. The histology of molluscum contagiosum (Bateman) By Tilbury Fox, M.D., and T. Colcott Fox, M.B. 460
8. On a case of lymphangiectodes, with an account of the histology of the growth By Tilbury Fox, M.D., and T. Colcott Fox, M.B. 470
9. Microscopical examination of some pustules removed from the back of the hand in a case of iodide of potassium eruption. By Dice Duckworth, M.D., and Vincent Harris, M.D. 476

---

## IX. DISEASES, ETC., OF THE DUCTLESS GLANDS AND LYMPHATIC SYSTEM.

1. Addison's disease with peculiar pigmentation By D. J. Leech, M.D. 478
2. Two cases of early disease of the supra-renal capsules (Addison's disease) By James F. Goodhart, M.D. 486
3. Elephantiasis arabum By Sir J. Fayrer, M.D., F.R.S., and D'Arcy Power, B.A. 488
Report By Henry Power and D'Arcy Power 499
4. On the condition of the lymphatics in Eastern leprosy By George Hoggan, M.B. 504
Report. By J. F. Goodhart and H. T. Butlin for *Committee on Morbid Growths* 510

## X. SPECIAL COMMUNICATIONS.

PAGE

1. Address on lardaceous disease in reference to its anatomical seats and pathological relations
By W. Howship Dickinson, M.D. 511
Discussion on ditto 517
2. Thoughts on the nature of certain observed relations between diphtheria and milk
By W. H. Power, per G. Buchanan, M.D. 546
3. Garget or ropy milk By A. H. Smee 551
4. On the relation of organisms to antiseptic dressings
By W. Watson Cheyne, M.B. 557

---

## XI. MISCELLANEOUS SPECIMENS.

1. Foot with nine toes By Francis Mason 583
2. Rabies of the dog By Edwards Crisp, M.D. 584
3. Skin diseases in the horse By George Thin, M.D. 588

## REPORTS OF THE COMMITTEE ON MORBID GROWTHS.

---

PAGE

1. On E. Bellamy and A. Sangster's specimen of cancerous ulcer of the face and nose (J. F. Goodhart and H. T. Butlin) . . . . 373
2. On James Gairdner's specimen of multiple tumours (J. F. Goodhart and H. T. Butlin) . . 394
3. On Christopher Heath's case of removal of the scapula (M. Beck and R. J. Godlee) . . . 406
4. On George Hoggan's microscopic specimens of the skin in leprosy (J. F. Goodhart and H. T. Butlin) . 510

## LIST OF PLATES.


| | | PAGE |
|---|---|---|
| I. | Fig. 1. Bacteria found in the Blood during life<br>Fig. 2. Section of Heart of case of Myositis .<br>Fig. 3. Arteriole in the Heart of ditto .<br>Fig. 4. Capillary Venule in the Tissues beneath an operative wound containing Micrococci .<br>Fig. 5. Microccoci in Spleen . .<br>Fig. 6. Mass of Micrococci in Inflamed Muscle. (W. S. Greenfield) . . . | 60 |
| II. | Fig. 1. Inflamed Muscle from Forearm in Myositis<br>Fig. 2. Fibrinous Exudation in Pericarditis containing Micrococci. (Ditto) . . | 60 |
| III. | Fig. 1. Micrococci in Pericarditis . .<br>Fig. 2. Arteriole in Tissues beneath a wound<br>Fig. 3. Arteriole in the Skin, adjacent to a minute Abscess in Chronic Pyæmia . .<br>Fig. 4. Plug of Leucocytes in Vein in Lung. (Ditto) . . . . | 60 |
| IV. | Fig. 1. Abscess in Subcutaneous Tissue, in Chronic Pyæmia . . . .<br>Fig. 2. Kidney in Septicæmia. (Ditto) . | 60 |
| V. | Figs. 1, 2. Liver in Septicæmia . .<br>Figs. 3, 4. Ditto, Centre of Lobule .<br>Fig. 5. Minute Abscess in the Brain. (Ditto) | 60 |
| VI. | Figs. 1, 2. Sections of a Lymphatic Gland showing groups of Micrococci. (J. McCarthy) . . | 60 |
| VII. | Figs. 1, 2. Sections of a Lymphatic Gland showing Giant Cells, commencing changes in Sustentacular Tissue, &c. (Ditto). . . . | 60 |
| VIII. | Figs. 1, 2, 3. Sections of Heart, showing Superficial Rupture of Muscle Fibres, and Vessels plugged with Micrococci . . .<br>Fig. 4. Transverse Section of a Blood-vessel in the Mitral Valve. (Ditto) . . | 60 |

PAGE

IX. Fig. 1—4. Sections of Kidney, showing Vessel plugged with Micrococci, relation of Basement Membrane of Collecting Renal Tubules to Epithelium, and similar condition in the Cortical Part. (Ditto) 60

X. Fig. 1. Malpighian Body; Swelling of Walls of Vessels of Glomerulus, one plugged with Bacteria . . . .
Fig. 2. Section of Kidney: increase of Nuclei in Glomerulus . . . 60
Figs. 3, 4. Sections of Liver: Vessel plugged with Micrococci, and Fatty Degeneration of Cells. (Ditto) . . .

XI. Fig. 1. Section of Lung, showing a large Vein filled with Coagulated Blood, Micrococci, &c.
Fig. 2. Section of Kidney: Obliteration of Lumen of Renal Tubules . . . 60
Fig. 3. Section of Lung, showing a Small Vessel of Varicose Appearance from Irregular Distension with Micrococci. (Ditto) .

XII. Case of Diseased Spinal Cord in Infantile Paralysis. (F. Taylor) . .
Fig. 1. Transverse Section of the Lumbar Enlargement of the Spinal Cord .
Figs. 2, 3. Ditto, magnified 180 and 160 diameters: Dense Felt-like Structure of Grey Matter with scattered Nuclei; absence of Nerve-cells and Cylinders, &c. 200

XIII. Case of Acute Anterior Poliomyelitis in a Child (F. C. Turner) . . .
Fig. 1. Section through Lumbar Enlargement, showing Left Anterior Cornu and Region adjacent . . 204
Fig. 2. Portion of the Area of Disorganisation of the centre of the Left Anterior Cornu . . .

XIV. Pathology of Tetanus and Hydrophobia. (James Ross) . . . . . 216

XV. Chronic Lobar Pneumonia; Grey Induration; Gangrene in Lower Lobe of Lung. (Sidney Coupland) . . . . . 230

XVI. Tubercle of the Lung spreading from Yellow Elastic Nodules in the Lung. (Jas. F. Goodhart) . 234

XVIa. Figs. 1, 3. Tubercle of Lung from Yellow Elastic Nodules. (Jas. F. Goodhart) . . 234
Figs. 2, 4. Nodular Fibroid Phthisis (Syphilitic?). (Jas. F. Goodhart) . . . 234

PAGE

XVIB. Fig. 1. Congenital Malformation of the Heart, p. 273. (H. R. CROCKER) . . 264
Fig. 2. Ditto, p. 262. (D. W. FINLAY) .
Fig. 3. Congenital Disease of Aortic Valves, p. 277. (T. B. PEACOCK) . . .

XVII. Figs. 1, 2. Hypertrophic Cirrhosis of the Liver. (ROBERT SAUNDBY) . . . 304

XVIII. Case of Calvaria from a Child the subject of Congenital Syphilis. (THO. BARLOW) . 334

XIX. Ditto. (Ditto) . . . . 334
Internal surface; osteophytes.

XX. Rodent Ulcer. (TILBURY FOX and T. C. FOX) 370
Figs. 1, 2. Section of Nodules removed from the Recurrent Growth at the edge of the red cicatrix in Case 1 . .

XXI. Ditto. (Ditto) . . . 370
Figs. 3, 4. Sections from a Nodule in Case 1

XXII. Ditto. (Ditto) . . . 370
Fig. 5. Section of the earliest stage of Rodent Ulcer in Case 4 . . .
Fig. 6. Section from a Recurrent Nodule in Case 2 . . .

XXIII. Case of Cancerous Ulcer of the Face. (E. BELLAMY and A. SANGSTER) . . 372
Fig. 1. Vertical section through the advancing edge of the Growth . .
Fig. 2. The new growth highly magnified, showing Cells and Nuclei in the meshes of fibrous trabeculæ . . .

XXIV. Histology of Rodent Ulcers. (GEO. THIN) 374
Figs. 1, 2. From a section through the Nodule on the Lip in Mr. Lister's Case .
Fig. 3. From the border of a large Cell-mass
Fig. 4. From the submucous tissue of the Lip (Rodent Ulcer of the Nose) .
Fig. 5. Rodent Ulcer of the Cheek; tubular variety . . .

XXV. Figs. 1, 2. Colloid Cancer of the Breast (R. J. GODLEE) . . . . 416

XXVI. Figs. 1—4. Condition of the Lymphatics in Eastern Leprosy, p. 504. (GEO. HOGGAN) . 428
Figs. 5, 6. Changes in the Sweat-glands in Cancer and Leprosy, p. 421. (Ditto) . .

PAGE

XXVII. Addison's Disease with peculiar Pigmentation. (D. J. LEECH) . . . . 484

XXVIII. Specimens of Piedra
Figs. 1—4. (MALCOLM MORRIS) . . } 440
Fig. 5. (P. H. PYE-SMITH) . . }

XXIX. Histology of Molluscum Contagiosum. (TILBURY FOX and T. C. FOX) . . . 462

## WOODCUTS.

PAGE

1. Infantile paralysis; section from the lower lumbar region of cord (H. Humphreys, M.D.) . . 213
2. Ditto; section from the middle lumbar region (H. Humphreys, M.D.). . . . 213
3. Stenosis of the pulmonary artery from disease of the valves; right ventricle, trunk, and orifice of the pulmonary artery, showing the diaphragm formed by the united valves (T. B. Peacock, M.D.) . 260
4. Defect in the ventricular septum of the heart. Fig. 1. Aorta and left ventricle laid open. Fig. 2. Pulmonary artery and infundibulum laid open (S. Coupland, M.D.) . . . . 267
5. Protrusion of orifice of ureter through meatus urinarius in a female child (N. Davies-Colley) . . 311
6. Histology of rodent ulcers; from the nodule in the upper lip (George Thin, M.D.) . . . 378
7. Ditto; cell mass from a rodent ulcer of the cheek (George Thin, M.D.) . . . 379
8. Ditto; from rodent ulcer of the nose (George Thin, (M.D.) . . . . . 382
9. Changes in the sweat-glands in cancer and leprosy; section through the lower portion of the glomerulus of a sweat gland showing different stages of cancerous infection of the lining epithelium (Geo. Hoggan, M.B.) . . . . 423
10. Ditto; a section across the tubule of a sweat gland in which all the lining cells have become cancerous (Geo. Hoggan, M.B.) . . . 424
11. Ditto; from an oblique section of the skin of the finger, showing the stages of attenuation and absorption of the sweat glands in the atrophic stage of degeneration (Geo. Hoggan, M.B.) . . 433
12. Ditto; showing a gland duct about to disappear (Geo. Hoggan, M.B.) . . . . 434

PAGE

13. Disseminated clavus of the hands and feet; microscopic section showing great thickening of the horny layer of the epithelium (N. Davies-Colley) . 452
14. Molluscum contagiosum; section of a tumour from the confined situation on the scalp, showing no implication of the rete (Tilbury Fox, M.D., and T. C. Fox, M.D.) . . . . 464
15. Ditto; changes that occur in the cell contents of the tumours (Tilbury Fox, M.D., and T. C. Fox, M.D.) 465
16. Ditto; magnified portion of Woodcut 14 (Tilbury Fox, M.D., and T. C. Fox, M.D.) . . . 467
17. Addison's disease with peculiar pigmentation (D. J. Leech, M.D.) . . . . 481
18. Micrococci, from a wound treated antiseptically, and growing in cucumber infusion and forms of bacteria, causing death, and forms of bacteria from wounds treated antiseptically and non-antiseptically (W. W. Cheyne, M.B.) . . 563

# REPORT OF THE COMMITTEE

## APPOINTED BY THE PATHOLOGICAL SOCIETY OF LONDON

TO INVESTIGATE

## THE NATURE AND CAUSES

OF THOSE INFECTIVE DISEASES KNOWN AS

# PYÆMIA, SEPTICÆMIA, AND PURULENT INFECTION.

---

*To the* PRESIDENT *and* MEMBERS *of the* PATHOLOGICAL SOCIETY *of* LONDON.

GENTLEMEN,—We beg to lay before you the result of the investigation into the nature and causes of those infective diseases known as pyæmia, septicæmia, and purulent infection, undertaken at the request of this Society in accordance with an engagement entered into by the Society and the Local Government Board.

The plan of investigation followed by your Committee has been:

1. To collect statistical information with respect to the affections in question from nearly all the large London hospitals during the decennial period from 1869 to 1878, with a view of determining the history of the disease in the surgical wards of the metropolitan hospitals during that decennium.

2. The collation of 156 detailed reports of cases, with the object of attempting to classify them according to their clinical and pathological features, and of ascertaining how far these correspond with the diseases produced experimentally in animals.

3. An examination of a considerable number of microscopical preparations of the various organs of the body from typical cases,

together with observations on the blood and urine in some of these cases, made during life, to illustrate the nature of the pathological changes in different stages of the various septic diseases.

---

# PART I.

1. *Sex and Age.*—Out of 321 cases of pyæmia and septicæmia occurring during the last ten years in the London, Middlesex, and St. George's Hospitals,[1] 252 cases were males and 69 females This difference would have been less marked had cases arising from the puerperal state and the deaths from ovariotomy been included.

TABLE I.—*Number of Patients at each Decade.*

| | 1—10 | 10—20 | 20—30 | 30—40 | 40—50 | 50—60 | 60—70 | 70—80 | 80—90 | Total. |
|---|---|---|---|---|---|---|---|---|---|---|
| Males ... | 11 | 37 | 39 | 68 | 50 | 35 | 7 | 5 | 0 | 252 |
| Females | 7 | 6 | 16 | 12 | 10 | 9 | 7 | 1 | 1 | 69 |
| Totals... | 18 | 43 | 55 | 80 | 60 | 44 | 14 | 6 | 1 | 321 |

No period of life is exempt from the development of these diseases. Among the youngest observed was that of a child, aged five months, with suppuration of the knee-joint and shoulder, the symptoms arising after vaccination; and the oldest was a woman, in her ninetieth year, with an old pelvic abscess. The decade, however, which furnishes the greatest number of cases is that between thirty and forty, a circumstance that must be attributed to the greater exposure to accidents and injuries at that period of life among the working members of the community.

2. *Influence of season and meteorological condition.*—Table II gives a return of the deaths from pyæmia and septicæmia originating in the surgical wards of eight large London hospitals during the decennium.

[1] Appendix I, pp. 61, 65, and 71.

The average mortality in each year amounted to 92·1. The highest death rate occurred in 1874, when it reached 125, and the lowest in 1869, when it was 64. But as the returns for 1869 do not include those of University College, the mortality of 1878, which does, must be taken as the lowest.

TABLE II.—*Decennial return of deaths from pyæmia and septicæmia in eight London hospitals.*

| Hospital. | 1869 | 1870 | 1871 | 1872 | 1873 | 1874 | 1875 | 1876 | 1877 | 1878 |
|---|---|---|---|---|---|---|---|---|---|---|
| St. Bartholomew's | 10 | 9 | 10 | 8 | 4 | 8 | 9 | 8 | 3 | 9 |
| St. George's | 11 | 15 | 11 | 7 | 11 | 8[1] | 8 | 5 | 5 | 4 |
| Guy's | 21 | 23 | 28 | 19 | 29 | 30 | 38 | 26 | 23 | 13 |
| London | 10 | 7 | 17 | 22 | 19 | 29 | 27 | 16 | 21 | 12 |
| Middlesex | 4 | 6 | 10 | 7 | 8 | 9 | 3 | 5 | 5 | 1 |
| Seamen's | 4 | 5 | 9 | 8 | 5 | 10 | 7 | 6 | 4 | 2 |
| St. Thomas's | 4 | 4 | 7 | 19[2] | 16 | 13 | 16 | 12 | 22 | 12 |
| University | ...[3] | ...[3] | 12 | 8 | 7 | 18 | 11 | 10 | 5 | 14 |
| Totals | 64 | 69 | 104 | 98 | 99 | 125 | 119 | 88 | 88 | 67 |

On referring to this table it is interesting to observe that in the years of low mortality, the death rate is nearly in all cases low at all the hospitals, and in like manner the death rate is high in the years of excessive mortality, pointing to a conclusion that the mortality is due in great measure to general as well as local conditions. The years 1874 and 1875, in which the greatest number of deaths from pyæmia occurred, were ones of comparatively high mortality for all diseases throughout the kingdom;[4] and in the year

[1] Hospital closed for three months, from June to September.

[2] First year in new buildings.

[3] Returns not given.

[4] The deaths registered in England from diphtheria, erysipelas, and puerperal fever, to every 100,000 persons living, were exceptionally high in 1874 and 1875, as is seen by appended tables taken from the Registrar General's returns.

| Disease. | 1870 | 1871 | 1872 | 1873 | 1874 | 1875 | 1876 | 1877 |
|---|---|---|---|---|---|---|---|---|
| Diphtheria | 121 | 112 | 94 | 109 | 152 | 143 | 131 | 112 |
| Erysipelas | 96 | 99 | 78 | 88 | 144 | 128 | 97 | 86 |
| Puerperal fever | 67 | 65 | 61 | 75 | 132 | 105 | 72 | 59 |

1874 the admissions of cases of erysipelas into the London hospitals were especially numerous (*vide* Table IV). Both years were characterised by atmospheric vicissitudes of totally opposite characters. In 1874,[1] there was a remarkable deficiency of rain during the whole year, the total being 5·4 in. below the average. The mean average temperature of January was remarkably high, being 5·4° above the average of 103 years. During February to the 14th of March the temperature was variable, there being eighteen days when the temperature was below, and twenty days when it was above, the average. On the 14th of March a spell of warm weather set in, which lasted to the end of April, the mean temperature for April being 50°, and on referring back 103 years we find that there have been but five Aprils of so high a temperature. On the 1st of May a cold period set in, which continued, without exception, till the 21st.

These three weeks of low temperature were very trying, following so immediately the heat of the preceding seven weeks. The temperatures during the summer and autumn were variable, but the variations were not excessive. On the 20th of November, however, a severe cold period set in, which lasted, with but few exceptions, till the end of the year. Since the year 1771 there have been only seven instances of so low a mean temperature as in December, 1874. Unlike the preceding year, 1875 was characterised by its excessive rainfall. The excess, however, was not spread equably over the whole year, but occurred in its last half, the total fall in six months ending 30th June being 1 in. below the average. In July, however, the fall of rain became excessive, being 2·7 in. above the average; back to 1815 there have only been four Julys with rainfalls so large; October, too, was also an extremely wet month, and the other months of this half of the year, with the exception of August, had more than the average rainfall. Fog, too, prevailed on 152 days this year. The vicissitudes of temperature were considerable. January was a warm month, the daily excess of temperature on twenty-nine days, over the average of sixty years, was 6¾°, but on several days the excess over the average was as large as 10°, 11°, and 12°; then set in bitterly cold weather, lasting all February and March, the wind remaining almost continuously east during this period. April and May were variable, but the summer, from June 11th to August 6th, was cold and damp. September was warm, but October

[1] "Remarks on the Meteorology of 1874 and 1875," 'Thirty-seventh and Thirty-eighth Annual Reports of the Registrar-General.'

generally cold and wet. The weather again became severe from the 20th of November to the 16th of December, with a very long continuance of east wind. The atmospheric vicissitudes of these two years were certainly more severe than in any other year of the decennial period. Table III gives the mortality from pyæmia and septicæmia in each month in each year, taken from the Reports of St. George's, the London, and University College Hospitals.[1]

TABLE III.—*Monthly death rate from pyæmia and septicæmia at three London hospitals during decennial period.*

| | Jan. | Feb. | Mar. | April. | May. | June. | July. | Aug. | Sept. | Oct. | Nov. | Dec. |
|---|---|---|---|---|---|---|---|---|---|---|---|---|
| 1869[2] | 5 | 3 | 0 | 1 | 1 | 4 | 1 | 1 | 2 | 1 | 3 | 2 |
| 1870[2] | 1 | 8 | 1 | 3 | 2 | 1 | 0 | 2 | 1 | 0 | 2 | 1 |
| 1871 | 4 | 8 | 5 | 2 | 2 | 3 | 7 | 1 | 0 | 2 | 3 | 0 |
| 1872 | 2 | 1 | 7 | 2 | 4 | 4 | 4 | 6 | 2 | 2 | 2 | 1 |
| 1873 | 6 | 3 | 7 | 5 | 6 | 0 | 2 | 0 | 1 | 2 | 3 | 1 |
| 1874 | 2 | 10 | 4 | 1 | 6 | 2 | 3 | 2 | 5 | 5 | 4 | 8 |
| 1875 | 0 | 7 | 7 | 3 | 3 | 5 | 2 | 3 | 3 | 3 | 6 | 3 |
| 1876 | 5 | 4 | 1 | 2 | 4 | 1 | 5 | 2 | 2 | 1 | 2 | 1 |
| 1877 | 1 | 4 | 5 | 3 | 2 | 2 | 1 | 1 | 3 | 4 | 3 | 1 |
| 1878 | 1 | 3 | 3 | 3 | 4 | 2 | 4 | 4 | 3 | 1 | 1 | 2 |
| Total | 27 | 51 | 40 | 25 | 34 | 24 | 29 | 22 | 22 | 21 | 29 | 20 |

The average monthly mortality for the decennium stands at 28·5, but for the months of February and March the mortality rises to 51 and 40 respectively, the next most fatal month being May, with a mortality of 34.

The death rate for these months is, therefore, considerably in excess of the other nine months of the year, and the question arises—Does this excess, which seems pretty constant, bear any relationship to sanitary or meteorological conditions, such as the distance from the period of annual hospital cleaning, or to the necessity of having the ward windows closed for longer periods together during the usually prolonged wet and cold weather characteristic of February, and during the east winds which prevail for many days together in March and May? Besides this, the vicissitudes of temperature in

[1] Appendix I, pp. 61, 66, and 75.

[2] The returns of University College Hospital are not included in these years.

these three months are usually great, and a return of cold after a few warm spring days is sure to be felt by the inmates of the hospital, and thus lead to an undue closing of windows and other channels of ventilation.

3. *Relationship of pyæmia and septicæmia to erysipelas.*—Table IV contrasts the deaths from pyæmia and septicæmia originating in the wards of St. Bartholomew's, St. George's, Middlesex, St. Thomas's, and University College Hospitals[1] with the cases of erysipelas under treatment at those Hospitals in each year for nine years of the decennium.

TABLE IV.—*Relationship of pyæmia and septicæmia to erysipelas.*

| | 1869 | 1870 | 1871 | 1872 | 1873 | 1874 | 1875 | 1876 | 1877 | 1878 |
|---|---|---|---|---|---|---|---|---|---|---|
| Pyæmia . | 29 | 34 | 50 | 49 | 46 | 56 | 47 | 40 | 35 | |
| Erysipelas | 219 | 199 | 203 | 365 | 412 | 457 | 352 | 312 | 288 | |

No very certain relationship seems to exist between pyæmia and septicæmia and erysipelas. The year 1874, it is true, was characterised by an excess of both forms of the disease; but 1871, which had the next highest mortality from pyæmia, among these hospitals, suffered comparatively slightly from erysipelas.

4. *Duration of disease and the frequency of its occurrence after various surgical lesions.*—In 142 cases, originating in St. Thomas's, St. George's, and the University College Hospitals, in which the date of invasion was stated, the average stay in hospital from admission to onset of pyæmic symptoms was 20·2 days; and the period intervening between invasion and death in 153 cases, from the same hospitals, was 9·5 days. In 768 cases, taken from the records of St. George's, Guy's, London, Middlesex, St. Thomas's, and University College Hospitals,[2] the disease followed operations in 218; injuries in 120; arose during the progress of surgical diseases in 268; and in 96 cases the diseases either appeared due to a variety of conditions, or else no distinct cause was assigned

[1] Appendix I, pp. 63, 71, 73, and 76. [2] Appendix I, pp. 63, 73, and 75.

for it. The particulars of the nature of the operation, injury, or disease, are given in Table V, arranged as to their occurrence at each of the hospitals from which the cases were taken.

TABLE V.—*Analysis of 768 cases of pyæmia and septicæmia arising in six London hospitals during decennium.*

| Surgical lesion. | St. George's | Guy's | London | Middlesex | St. Thomas' | University College | Total | |
|---|---|---|---|---|---|---|---|---|
| Amputation of limbs | 11 | 54 | 38 | 4 | 27 | 11 | 145 | Operations, 218 |
| „ breast | 1 | ...[1] | 3 | 1 | 3 | ... | 8 | |
| Removal of tumours | 2 | 12 | ... | 1 | 3 | ... | 18 | |
| Herniotomy | 1 | 1 | ... | ... | 2 | ... | 4 | |
| Osteotomy | ... | 1 | ... | ... | 2 | ... | 3 | |
| Lithotomy | ... | ... | ... | 2 | 1 | 4 | 7 | |
| Lithotrity | 1 | ... | ... | ... | ... | ... | 1 | |
| Ligature of arteries and piles | 4 | 2 | 3 | 1 | 2 | ... | 12 | |
| Tapping | ... | ... | ... | 1 | 2 | 2 | 5 | |
| Incisions | ... | ... | ... | 1 | 2 | ... | 3 | |
| Trephining and fracture of skull | 5 | ... | 1 | 1 | ... | 4 | 11 | |
| Galvano-cautery | ... | ... | ... | ... | 1 | ... | 1 | |
| Compound fractures and dislocations | 10 | ... | 23 | 5 | 9 | 3 | 50 | Injuries, 120 |
| Simple fractures | 2 | ...[2] | 12 | ... | 1 | 3 | 18 | |
| Lacerated wounds | 3 | 22 | 16 | 5 | 3 | 1 | 12 | |
| Contused „ | ... | | | ... | 1 | 1 | 30 | |
| Urethral | 7 | 34 | 2 | 2 | 7 | 14 | 66 | Urethral, 66 |
| Diseases of bone | 7 | 34 | 17 | 1 | 5 | 8 | 72 | Surgical disease, 268 |
| „ joints | 6[3] | 41[3] | 17[3] | 5[3] | 24[3] | 11[3] | 104 | |
| Abscess | 10 | 5 | 11 | 6 | 11 | 7 | 50 | |
| Ulcer | 2 | 7 | 4 | 1 | 2 | ... | 16 | |
| Carbuncle | 1 | 7 | 3 | 1 | ... | ... | 12 | |
| Whitlow | ... | ... | ... | ... | ... | 2 | 2 | |
| Scald or burn | ... | 2 | 1 | ... | ... | ... | 3 | |
| Cancer | ... | ... | 3 | 3 | ... | 1 | 7 | |
| Bedsores | ... | ... | ... | 1 | ... | 1 | 2 | |
| Various | 3 | 31[4] | 16 | 2 | 6 | 5 | 63 | Various. |
| No cause stated | 9 | 4 | 10 | ... | 10 | ... | 33 | Not stated. |
| Total | 85 | 257 | 180 | 44 | 124 | 78 | 768 | |

[1] Cases of amputation of the breast classed with removal of tumours.

[2] Diseases of bone also include simple fractures.

[3] Diseases of joints include excisions.

[4] Among this class are 11 cases of idiopathic pyæmia and 1 case of exophthalmic goitre.

5. Before passing from this part of the subject we would observe that, considerable as the number of cases collected in these statistics may be, still, spread as they are over a number of years, they are insufficient to found definite conclusions upon, but may prove useful as suggesting points for future inquiry. They would have been, however, more conclusive than they are had the whole material of the London hospitals been available, but unfortunately, owing to the absence of any uniform system of keeping the registers throughout the metropolitan hospitals, information given in some reports is not mentioned in others. It would be of immense value, especially in determining the etiology of diseases in points relating to their predisposing causes, if a uniform system of registration were adopted for all the metropolitan hospitals.

---

# PART II.

## CLINICAL.

(6.) In this part of the inquiry it has been attempted, by the collection and comparison of a considerable number of cases of septicæmia and pyæmia, to ascertain whether these diseases can be divided into groups sharply defined one from another, and how far these groups correspond in their clinical features and naked-eye pathological appearances to the diseases of the same kind which have been artificially produced in animals. The question as to the presence or absence of bacteria in the blood and tissues, and the part that these organisms play in the causation of these diseases, will be treated of in the next section of the report, and has been as far as possible omitted in this.

(7.) *Septicæmia.*—At the outset of this portion of the inquiry we are met with the difficulty that the term septicæmia is employed by different authors with very different significance. Thus, Dr. Sanderson, speaking of septicæmia in the lectures delivered in connection with the Brown Institution, says,[1] "What I mean by septicæmia is a constitutional disorder of limited duration, produced by the entrance into the blood-stream of a certain quantity of septic mate-

[1] "Lectures on the Infective Processes of Disease," delivered at the University of London, by J. Burdon Sanderson, M.D., LL.D., F.R.S., 'Brit. Med. Journ.,' December 29th, 1877.

rial. It must, therefore, be regarded, not so much as a disease as a complication, differing from pyæmia, not only in the fact that it has no necessary connection with any local process, either primary or secondary, but also in the important particular that it has no development. Pyæmia is a malignant process which goes on and on to its fatal end; but in the case of septicæmia, inasmuch as the poison which produces it has no tendency to multiply in the organism, there is no reason why the morbid process should not come to an end of itself, unless either the original dose is fatal, or a second infection takes place from the same or another source." On the other hand, Davaine, and those who have followed him, describe as septicæmia every case in which death follows the entrance of putrid substances into the blood-stream without the formation of local centres of inflammation or suppuration. Koch[1] has followed Davaine, and includes under the term septicæmia "all those cases of general infection from a wound in which no metastatic changes occur."

*Birch-Hirchfeld* limits the term septicæmia much in the same way as Dr. Sanderson. He describes as septicæmia those cases in which the disease results merely from the absorption of the products of putrefaction, and regards it merely as a process of poisoning, such as might arise from the injection of any other noxious chemical substance into the blood. Pyæmia, on the other hand, he considers a truly infective process, probably due to the entrance of specific organisms into the body. He would, therefore, include many of the cases described by Koch as septicæmia under pyæmia.

*Huster*[2] defines septicæmia as a fever caused by the entrance into the circulation of the products of putrefaction from local centres of decomposition. He draws no clear distinction between an infective and a non-infective form, but the affection he describes as pyæmia simplex, or pyæmia without metastases, seems to include many cases which Davaine, Koch, and others, would include under septicæmia.

*Billroth*[3] defines septicæmia as "a, for the most part, acute general affection, which arises from the taking up of various kinds of putrid substances into the blood, and it is believed that these putrid substances so change the quality of the blood that it can no longer

[1] 'Untersuchungen über die Aetiologie der Wundenfectionskrankheiten,' von Dr. R. Koch, Leipzig, 1878.

[2] 'Handbuch der Allgemeinen und speciellen Chirurgie,' Billroth and Pitha, 1872.

[3] 'Lectures on Surgical Pathology and Therapeutics,' Translation of the Sydenham Society, 1878.

fulfil its physiological functions." Billroth, like Hueter, does not draw any sharp distinction between an infective and a non-infective form. Many other observers have stated that the disease they speak of as septicæmia shows an increasing virulence when transmitted by inoculation from animal to animal, thus indicating a multiplication of the poison in the organism. Observations of this kind have been recorded by Davaine, Coze and Feltz, Hiller, and others.

(8.) Leaving the experimental side of the question and turning to the more purely clinical, we find that many authorities, especially in this country, recognise no essential difference between any forms of septicæmia or between septicæmia and pyæmia. Thus, Mr. Savory, speaking in the debate on pyæmia at the Clinical Society in 1874, classes septicæmia and pyæmia together as but different degrees of effect of the same poison, septicæmia being more acute and terminating fatally before there has been time for the formation of secondary points of suppuration. Mr. Hulke, on the other hand, would clearly distinguish between septicæmia and pyæmia, and thinks a sharp line of definition should be drawn between the two. At the same time he thinks it "may be difficult to do so in practice at the bedside, because these two conditions may coexist in the same patient."

If we refer to three of our chief text-books on surgery, we find that Mr. Erichsen makes some distinction between pyæmia and septicæmia, although not actually treating the two conditions as separate diseases. Mr. Bryant opens the chapter on traumatic fever, septicæmia, and pyæmia, thus:—"Inflammatory fever; surgical, suppurative, or traumatic fever; septicæmia, ichoræmia, puerperal fever, and pyæmia, may all be considered as so many different names for and manifestations of one condition—blood-poisoning." Mr. Holmes also states that septicæmia and pyæmia are identical.

It is needless to quote any further to show that the term septicæmia, as at present used, cannot be said to have any definite meaning. It seems probable that at least two separate and distinct conditions exist, to which the name septicæmia is commonly applied. These two forms of disease cannot be better illustrated than by referring to the observations on artificial infective processes in wounds, by Dr. Robert Koch.[1] His experiments were made upon the common mouse and were as follows:—Five drops of putrid blood or meat

[1] 'Untersuchungen über die Aetiologie der Wundinfectionskrankheiten,' von Robert Koch, Leipzig, 1878.

infusion were injected under the skin of the back. Almost immediately the animal became restless, it ceased to eat, soon its movements became weak and uncertain, the respiration was irregular and gasping, and in from four to eight hours death took place. Microscopic examination of the seat of injection showed no signs of inflammatory reaction. The internal organs were unchanged. No bacteria were to be found in the blood, nor in the viscera, and a drop of blood taken from the heart and injected into another mouse produced no ill effects. It was evident here that no true infective process had been started; the animal died from the chemical poison, just as it might have done from a dose of arsenic.

Further experiments showed that the effect produced by the injection was proportional to the dose, and that when a sufficiently small quantity was used, the animal usually escaped without any ill effects. A certain proportion of the mice experimented on, however, after about twenty-four hours' of apparent immunity, began to show symptoms different from those just described, and quite characteristic. The proportion of mice thus affected varied with the quantity of the putrid fluid injected. If one drop were used about one third of the experiments succeeded; if from $\frac{1}{10}$ to $\frac{1}{20}$ of a drop only about one in ten or twelve. The earliest symptom in the successful cases was in increased secretion from the conjunctiva, which finally stuck the eyelids together. At the same time the animal became weak, and showed but little tendency to move, but sat still with extended legs. It ceased to eat, and the respiration became slower, the debility increased, and finally, death occurred quietly at the end of from forty to sixty hours after the injection. On examining the body after death, a slight œdema was usually found at the seat of injection, and all the internal organs apparently unchanged, with the exception of a considerable swelling of the spleen. The blood from the heart and the effused fluid from the seat of injection were found to possess the most intensely infective properties. In many cases it was sufficient to scratch the ear or the root of the tail of another mouse with a scalpel dipped in the blood of the first, in order to set up the same disease. Here, then, there was an undoubtedly infective disease, of the most virulent character, agreeing in many of its clinical features with what we know as septicæmia in man. Microscopic examination of the blood and internal organs of these mice showed, moreover, a peculiar small bacillus, invariably present in enormous numbers. It is needless to

go into further detail with regard to these most interesting observations. Sufficient has been given to indicate clearly the difference between mere poisoning from the chemical products of decomposition and the establishment of a true infective process. In the one case the poison does not multiply itself in the blood of the animal; the effects are purely proportional to the dose and the size and susceptibility of the animal experimented on, and the blood after the death, merely containing the original dose of poison diluted, is incapable of setting up a similar intoxication in another animal. In the other case the poison increases in the body of the affected animal, and the smallest drop of the blood or of the inflammatory discharges will establish a similar process in another animal. The establishment of a clear distinction between these two conditions may serve to explain many of the apparent contradictions which exist in the multitudinous observations upon experimental septicæmia.

In order clearly to distinguish these two conditions from each other it would perhaps be better to employ the terms used by some of the German writers, and to give to the former the name of septic or putrid intoxication, and to the latter septic or putrid infection.

(9.) With regard to septic intoxication, we owe the chief part of our accurate knowledge to Bergmann and Panum, and Billroth. These authors clearly showed that a substance could be extracted chemically from putrefying animal matter, which, when injected into the blood-stream, caused death with the ordinary symptoms of septicæmia. The exact nature of this substance is not known. Bergmann thought he discovered something definite, to which he gave the name of sepsin, but later observers have not proved the existence of this in putrefying animal fluids.

Our knowledge of septic intoxication, as derived from experiments upon animals, may be briefly summed up thus:

The effect of the dose is proportional to the size and susceptibilty of the animal experimented on. Carnivora are less susceptible than herbivora. Rabbits and guinea-pigs are extremely susceptible; dogs much less so. It is probable that the susceptibility of the human subject is greater than that of dogs; it is certainly much less than that of guinea-pigs or rabbits.

It is probable, also, that the susceptibility of the individual varies with the state of health. The poison does not multiply in the body, and consequently the blood of an animal which has

been killed by pure septic intoxication, containing, as it does, only the original dose diluted, will not set up a similar affection in another animal.

According to the observations of Koch, organisms are not found in the blood of animals suffering from septic intoxication.

The symptoms produced by a fatal dose of the septic poison are restlessness and muscular twitching, gradually increasing muscular weakness, until the animal falls down unable to stand; there are vomiting and profuse diarrhœa, the fæces at first being loose, and whitish-grey in colour, and afterwards blood-stained or containing blood clots. The temperature at first rises some degrees, but before death often falls below normal. The respiration and the heart's action become gradually more and more feeble, until death ensues, sometimes preceded by cramps.

The chief *post-mortem* appearances are as follows:—The blood is dark in colour, and coagulates imperfectly. Petechiæ are found both beneath the pericardium and endocardium, chiefly in the left ventricle, and also beneath the pleura. The mucous membrane of the stomach and intestines is intensely injected, and here and there are patches of extravasated blood. The epithelium has desquamated in patches or entirely. The spleen is dark in colour, engorged with blood, soft, and often pulpy.

Dr. Sanderson summarises the *post-mortem* appearances thus:—"First, there is an obvious tendency to congestion and capillary hæmorrhage; and, secondly, a localised congestion of the gastro-intestinal mucous membrane, which is so intense that we are tempted, with Bergmann, to speak of it as gastro-enteritis."

Microscopic examination of the blood shows that the corpuscles tend to aggregate themselves into clumps instead of rouleaux. The serum is also found to be stained with the blood pigment immediately after death, showing that the disintegration of the corpuscles has commenced during life.

The appearances above briefly noted have been described without any material variation by all authors from the time of Gaspard (1822) onwards. It must, however, be noted that Koch, in his experiments on mice, found the internal organs unaltered after death caused by the injection of ten drops of putrid blood beneath the skin of the back.

If the dose used be not sufficient to cause death, the symptoms gradually subside, and the animal recovers, more or less weakened

by what it has gone through, but apparently without suffering any permanent injury.

As a result of the above observations, the theory has of late years been generally accepted that the fever accompanying large recent wounds, in which decomposing matter is in contact with the raw surface, is in great part or entirely due to the absorption of septic matter, and that this fever continues until the surface becomes covered by healthy granulation tissue, which is believed to prevent further absorption unless the septic fluids are pent up in contact with it at some degree of pressure. Accepting this theory as true, ordinary wound fever is merely septic intoxication in a very mild form, and it is only necessary for the dose absorbed to be sufficient in quantity for fatal consequences to ensue. Septic intoxication is, therefore, of the commonest possible occurrence as a complication of severe surgical injuries, but it is in so mild a form as to bear but little resemblance to that experimentally produced in animals.

(10.) It has been attempted in this part of the inquiry to ascertain, by collecting and comparing fatal cases of so-called septicæmia, if anything at all comparable to experimental septic intoxication ever occurs in the human subject. The conditions under which such an accident can occur are not of frequent occurrence. In the first place, there must be a sufficient quantity of septic matter to furnish the fatal dose; and, secondly, there must be conditions favorable to its rapid absorption. We have no definite knowledge of the quantity of putrid serum necessary to form a fatal dose in the human subject In Mr. Savory's well-known experiments on blood poisoning ('St Bartholomew's Hospital Reports,' 1865) a putrid fluid, obtained by macerating cat's flesh in water, and putrid liquor amnii, were injected directly into the veins of the animals experimented on. The quantity required to prove fatal to a large cat or to a dog of from 12 to 15 pounds seems to have been about two drachms or more. The effects of the poison being proportional to the bulk of the animal; this would correspond to about 2½ oz. in the human subject, but the susceptibility of man being supposed to be greater than that of the dog, the quantity required would be smaller, and, again, the fluids used containing less albumen than serum, would probably not present the poison in so concentrated a form. It must be acknowledged, therefore, that there are no definite data from which we can determine the fatal dose of putrefying serum or pus in the human subject, but the probability is that it would require from one to two

ounces to be absorbed within a comparatively short time to produce anything analogous to the acute experimental septic intoxication of animals. In children a smaller quantity would be required. The conditions necessary for its rapid absorption would be found in all recent wounds, the raw surfaces of which, before they are covered by healthy granulation-tissue, forms one of the most active absorbing surfaces conceivable. The absorbing power of the wound would, of course, vary with its extent. Absorption also takes place with great rapidity from serous or synovial cavities. From the cavities of acute abscesses absorption does not take place readily through the granulation-tissue forming the wall unless the septic matter is pent up at some degree of pressure.

The conditions, therefore, under which it is theoretically probable that acute septic intoxication might occur in the human subject, are large and irregular wounds, such as those resulting from compound fracture of the bones of a limb; hollow wounds, such as those left after the removal of tumours; wounds of joints; wounds involving the pleura or peritoneum; and large abscesses opening externally by an insufficient aperture. The accumulation of septic matter in the uterus after labour, in contact with the raw surface left by the separation of the placenta, would also present the conditions favorable to acute septic intoxication. In the present day, when the necessity of thorough drainage of wounds is so fully understood, and the means at the surgeon's command for carrying it out are so efficient, it can only be under peculiar circumstances that a sufficient quantity of putrid serum or pus to yield the fatal dose of the septic poison is allowed to accumulate in a wound. Moreover, the antiseptic treatment of wounds now so largely adopted, by preventing decomposition, of course renders septic intoxication impossible. Ovariotomy would seem to furnish conditions most favorable to septic intoxication, and a large proportion of the deaths occurring in the first forty-eight hours have always been attributed to it. The proportion of fatal cases from this cause has, however, of late, been greatly diminished by drainage, and more especially by the employment of the antiseptic treatment. The evidence, therefore, to be looked for as indications of fatal acute septic intoxication in the human subject would be—

1. The presence of a sufficient quantity of septic matter to yield the necessary dose of the septic poison.

2. The invasion of the symptom at a time when decomposition of

the discharges has commenced, and before the surface of the wound has been covered by granulations.

3. High fever rapidly followed by great depression.

4. *Post-mortem* appearances indicative of a "tendency to congestion and capillary hæmorrhage."

5. Accepting Koch's observations as correct, organisms would not be found in the blood during life, or immediately after death.

(11.) Of the 156* cases collected, twenty-eight died without the formation of secondary centres of inflammation, and consequently would be classed by most authors as cases of septicæmia. In the great majority of these cases the conditions were such that it was possible for a fatal dose of septic matter to accumulate in the wound. Of these twenty-eight cases, the available notes only enabled us to ascertain with any degree of accuracy the time at which the secondary symptoms commenced in fourteen. In seven of these fourteen, or exactly one half, the symptoms commenced on the second day (Cases 1, 3, 5, 12, 16, 18, 19, in Appendix II, Table I). In two they commenced on the third day (Cases 6 and 10), and in the rest at various periods up to three weeks. Of the seven cases in which the symptoms commenced on the second day, one (Case 5) presented features quite distinct from the rest. The patient had repeated rigors, and died on the twenty-second day. The remaining six died within four days of the commencement of the symptoms. In four of these six cases (Cases 3, 12, 16, and 19), there was diffuse cellulitis spreading from the local injury, and consequently the suspicion is raised that some specific infective inflammation might have attacked the wound. In one of these (Case 3) bacteria were observed in the blood during life, and there was strong suspicion of infection from another case. In another (Case 12) the wound was treated antiseptically, and there was no odour of decomposition in the discharges at the time of death. These cases must, therefore, be excluded as being probably due to a true infective process, and not to pure septic intoxication. Only two cases, therefore, are left in which there is presumptive evidence that the patient died directly from the toxic effects of the products of decomposition. In the first (Case 1) a large tumour was removed from below the lower jaw, and the cavity, apparently from want of efficient drainage, became distended with foul discharges. The patient lost but little blood at the operation. On the second day she was very weak and

* For the classification of the 156 cases refer to Appendix II.

ill, with an intermittent pulse. On the third day the distension of the wound was discovered and relieved, but on the afternoon of the same day there was severe dyspnœa, and she died the same evening. There were no rigors, nor vomiting or diarrhœa. The patient was seventy-four years of age, and consequently might be supposed to be not very capable of withstanding the effects of the poison. There was no record of the temperature. At the *post-mortem* examination marked *post-mortem* staining of the endocardium was observed. The liver and spleen were pale and soft. In the second case (No. 19), the patient was admitted into the hospital with a large abscess of the bursa patellæ. This was opened. The next day she became feverish and delirious, and rapidly sank and died two days afterwards. The temperature rose to 104·4° on the first day, pulse 150. The *post-mortem* examination showed congestion of the lungs and kidneys. Liver soft and oily. Nothing abnormal noted with regard to the spleen. Neither of these cases occurred during the course of the present inquiry, and consequently we are not able to report any examination of the blood for bacteria. It must be confessed the evidence is by no means conclusive as to the nature of the affection. The cases collected being from general hospitals they include none of ovariotomy or perhaps more specimens of unmistakable septic intoxication might have been obtained.

(12.) *Septic infection without metastatic inflammations.*—By this is meant a true infective process started in the organism by the introduction, through a wound, of some virus developed in decomposing organic matter. The poison multiplies itself in the organism and its effects are not directly proportional to the dose. Of the exact nature of the poison nothing is as yet definitely known. The observations of Koch, before quoted, would favour the view that the poison is, in reality, a microscopic organism which multiplies in the blood, and that this organism is essential to the production of the disease, just as the *Bacillus anthracis* has been proved to be essential to the production of splenic fever. On the other hand, Hiller asserts that, by the injection of a putrid fluid which had been proved to be free from bacteria, he succeeded in inducing a fatal disease, in which the blood of the affected animal was capable of communicating a similar affection, and that by transference from one individual to another the poison showed a progressively increasing virulence, thus indicating a multiplication of the poison in the blood

of the affected animal. If this be true it would suggest that the poison was of the nature of an unorganised ferment.

(13.) As most authors have at present drawn no clear distinction between the purely chemical poisoning by septic fluids and the infective process, it is somewhat difficult to gather what are the morbid appearances seen after death in the latter condition. They seem, however, to be chiefly congestions of internal organs, especially of the spleen, with subserous and submucous petechiæ. The symptoms during life are fever with progressive emaciation and exhaustion. The development of the disease is slower and its course less rapid than in acute septic intoxication.

The conditions which in man would lead to the suspicion that the fatal result was due to the development of a poison multiplying in the blood, and not to the simple toxic effects of the products of decomposition, would be the following:

1st. The wound being of such a size as to render it impossible for the necessary fatal dose of septic matter to be formed in it.

2ndly. Evidence of infection from one patient to another; and

3rdly. If Koch's observations are correct, the presence of large numbers of bacteria in the blood during life or immediately after death.

Of course, septic infection could originate from a large wound as well as from a small one, but such cases would, in all probability, be complicated by more or less septic intoxication, and the evidence as to the nature of the affection would therefore be correspondingly confused. It is also possible to suppose that a poison of such intense virulence might be developed in the decomposing discharges of a wound that an infinitesimal dose might be sufficient, if absorbed, to cause death without any process of multiplication in the body of the affected animal. If so, however, the poison would become more and more feeble by inoculation of the blood of one animal to another, a condition the reverse of what has been observed in experimental observations on septic infection in animals.

As to the evidence of infection from patient to patient, this cannot be considered necessary for every case of true septic infection, for the observations of all experimenters have shown that a truly infective process can be originated in an animal by the subcutaneous injection of putrid blood or other organic matter, but it is, to a certain extent, an accidental occurrence, or rather, depends upon conditions not as yet accurately determined. When, however, the

infective process is once started it may be transmitted from animal to animal with certainty. Evidence of infection, therefore, from patient to patient would indicate the existence of a true infective process, but a want of such evidence would not prove the contrary.

With regard to the necessary existence of microscopic organisms in the blood in septic infection we have the evidence of Koch, Davaine, Burdon-Sanderson, Birch-Hirschfeld, and many others, that such is the case; and on the opposite side we have that of A. Hiller, which is supported by the great authority of Billroth.

(14.) Of the twenty-eight cases collected, in which death occurred without the formation of secondary inflammations, only two arose from wounds so small as to exclude the possibility of sufficient septic matter being present to yield a directly fatal dose. The first of these (No. 10) occurred in an old woman. A small epithelioma of the tongue was ligatured. The whole area included was not larger than a shilling. On the third day there was some elevation of temperature. This continued, and on the sixth day there was slight hæmorrhage from the raw surface. On the following day she was unconscious, and patches of congestion appeared on the skin. The skin was sallow in tint, and there was some inflammation of the conjunctiva on one side. There was great prostration. She died nine days after the operation, and five after the commencement of the symptoms. The *post-mortem* examination showed a foul sloughy wound. Subserous petechiæ in pericardium and pleura. Swollen, almost diffluent spleen. Swollen and blood-stained liver and kidneys. Great congestion of the lungs. The second case (No. 23) arose in a dissecting-room porter. The primary affection was merely a little suppuration beneath the nails of the thumb and middle finger. The clinical features of the case could not be obtained. He was only one day in hospital. The blood was dark and fluid; there was congestion of the lungs; slightly soft and greasy spleen; swollen liver and kidneys; no petechiæ. The blood is stated to have contained no bacteria.

In two of the remaining cases (Nos. 3 and 4) bacteria were observed in the blood during life. (See Observations on the blood and pathological histology, in a later part of the report.) One case (No. 12) of great interest unfortunately occurred during the absence from town of the member of the committee whose duty it would have been to make a detailed inquiry into its symptoms and

nature. It was one of excision of the knee performed with all antiseptic precautions, and to the time of death there was no odour of decomposition in the discharges. (For details see Appendix II, Table I, Case 12.) This case is the only one of the twenty-eight in which it is not certain that there was decomposing animal matter in contact with the raw surface of the wound.

(15.) To sum up therefore the results of the comparison of the clinical and coarse pathological conditions noted in the twenty-eight cases of so-called septicæmia, it may be said that in two there is strong presumptive evidence that death resulted directly from the toxic action of the products of decomposition developed at the primary seat of disease; and in two more, of the existence of a true infective process. In the remaining twenty-four the evidence is not sufficient to form any definite conclusion as to the nature of the process. Death may have resulted from the prolonged absorption of the septic poison leading to gradual exhaustion, or to the effects of a true infective process, or to both conditions combined.

The evidence of infection from patient to patient was not sufficiently definite in any case to form any conclusion from it.

(16.) Taking this group of cases as a whole, *i.e.* those cases in which the *post-mortem* examination revealed no secondary or metastatic inflammations, the following were the chief symptoms and pathological appearances observed. The clinical history was only obtainable in twenty-one cases.

As it has been stated by some authorities that "septicæmia" differs from pyæmia only in time, and that if the patient survived sufficiently long, secondary centres of inflammation would ultimately form, the duration of the cases has been calculated out wherever the period of invasion was sufficiently accurately marked, with the following results:—

| | |
|---|---|
| About 2 days | 2 cases. |
| „ 3 „ | 1 case. |
| „ 4 „ | 7 cases. |
| „ 5 „ | 1 case. |
| „ 7 „ | 2 cases. |
| „ 8 „ | 2 „ |
| „ 10 „ | 1 case. |
| „ 14 „ | 1 „ |
| „ 19 „ | 1 „ |
| „ 22 „ | 1 „ |
| | 19 |

Some of these certainly survived sufficiently long for abscesses to form if it was in the nature of the case that such a thing should happen.

In eight of the cases in which the clinical history was obtainable, rigors occurred, and in all but two of these they were repeated more than once. In one case (No. 5), in which the rigors were repeated no less than nine times, the patient survived to the twenty-second day. It is evident, therefore, that nothing can be predicted as to the occurrence of internal inflammations or suppurations from the presence or absence of rigors, and also that the theory, that the rigors are due to the commencement of fresh centres of secondary inflammation is untenable.

| | |
|---|---|
| Delirium is noted in . . . . . | 11 cases. |
| Vomiting „ „ . . . . . | 4 „ |
| Diarrhœa „ „ . . . . . | 3 „ |
| Dyspnœa „ „ . . . . . | 4 „ |
| Icteric tint of skin is noted in . . . . | 6 „ |

In the *post-mortem* examination of the twenty cases the following pathological appearances are noted.

| | |
|---|---|
| Congestion of lungs in . . . . . | 23 cases. |
| Swollen liver . . . . . | 14 „ |
| Swollen spleen . . . . . | 23 „ |
| Congested and swollen kidneys . . . . | „ |
| Congestion of mucous membrane of intestines . . | 1 „ |
| Subserous petechiæ . . . . . | 2 „ |
| Early decomposition . . . . . | 3 „ |
| Fluid blood . . . . . | 2 „ |
| Marked *post-mortem* staining . . . . | 7 „ |

The result of the whole of this part of the clinical inquiry cannot be said to do much more than show the necessity of further investigation, in order to ascertain whether any distinct separation can be made clinically, as well as experimentally, between septic intoxication and septic infection. Septic intoxication is a condition which may occur whenever the discharges from a wound are allowed to accumulate in sufficient quantity and to decompose. Theoretically, it should be absolutely preventable, and when it does occur it does not necessarily give rise to anything which may be communicated from patient to patient. In septic infection, on the other hand, if we can draw any conclusion from the experiments upon animals, a virulent poison is produced, which may be communicated from patient

to patient with the most fatal consequences. It is, therefore, of the utmost importance to be able, if possible, to distinguish these conditions from each other.

(17.) *Pyæmia.*—The same difficulty arises with respect to pyæmia as was noted at the commencement of the part of this report referring to septicæmia.

The term pyæmia is used by different authors with very different meaning. We have before alluded, in speaking of septicæmia, to some of the various uses of the term.

The most common definition of pyæmia is, no doubt, that adopted by the College of Physicians in the nomenclature of diseases. It is as follows:—"A febrile affection resulting in the formation of abscesses in the viscera and other parts." This definition excludes all those cases which have just been described under septic infection. Birch-Hirschfeld includes under the name pyæmia all cases in which any general infective process is set up as a secondary consequence of a wound. Other authors seem still to be more or less wedded to the theory from which the word was originally derived. Thus Hueter says, "Pyæmic fever is developed by the absorption of the constituents of pus into the blood; the absorption may be direct into the circulation of the fluids of the body (blood or lymph), or it may take place after the previous absorption of the constituents of the pus into venous thrombi, pieces of which enter the circulation, serving as carriers of the pus-constituents."

Billroth, in almost the same words, says, "Pyæmia is a disease which we believe to arise from the taking up of pus, or of the constituent parts of pus, into the blood. It stands in the same relation to simple inflammatory fever and secondary fever as septicæmia does so simple, primary wound-fever."

Koch, as before stated, uses the term pyæmia merely to denote a general affection accompanied by metastatic inflammation and suppurations. He says, "The names pyæmia and septicæmia no longer express what were originally designated by them, for pyæmia does not arise, as was formerly supposed, from the entrance of pus into the blood-vessels, and septicæmia is not a putrefaction of the living blood. They have finally only remained in use as general names for a number of symptoms which most probably belong to a series of different diseases."

It is needless to quote further in illustration of the various ways in which the term pyæmia is used. Although it would be much

better if the word was entirely discarded and some other found in its place, it is very difficult to suggest any that would be free from objection; and as, in the sense in which it is defined in the nomenclature of diseases of the College of Physicians, its clinical meaning is fully understood, no error is likely to arise from continuing to employ it.

The chief experiments with reference to pyæmia may be very briefly summed up as follows:

It has been clearly shown by Dupuytren, Boyer, Günther, Sedillot, Virchow, O. Weber, Billroth, and many others, that the injection of healthy pus, free from solid particles visible to the naked eye, does not cause symptoms resembling pyæmia in any respect. Febrile disturbance of short duration is the only effect produced. If the pus be putrid, and at the same time free from solid particles of any size, a fatal affection, unaccompanied by metastatic inflammation or suppuration results from its injection into the blood-stream.

No observer has as yet succeeded in inducing in animals a fatal infective process, accompanied by metastatic inflammations and suppurations, by inoculation or injection of the blood or discharges obtained from a case of pyæmia in the human subject.

It has been demonstrated by Virchow, Sedillot, and by many others, that the introduction into the blood-stream of solid particles, which are themselves of an irritating nature, or impregnated with the products of decomposition, or of unhealthy inflammation, will cause the formation of metastatic abscesses; and O. Weber has shown that these solid particles may pass through lungs and lodge in other organs, causing similar results wherever they are arrested.

The nearest approach to the artificial production in animals of a disease resembling pyæmia in man, has been made by Koch in some experiments recorded in the pamphlet before alluded to. The animals experimented on were rabbits. After failing several times to induce a general infective process with putrid blood, Koch tried other fluids with the same intention. The one with which he succeeded, was prepared by macerating a piece of the skin of a mouse, one centimètre square, for two days in thirty grammes of distilled water. Ten drops of this fluid were injected beneath the skin of the back. The animal at first seemed to suffer but little; after 105 hours, however, it died. The examination after death showed a diffuse, suppurative inflammation of the subcutaneous tissue extending from the haunch to the linea alba. In the belly the inflam-

mation extended through the abdominal walls to the peritoneum. There was some peritonitis. The liver was mottled with grey patches, wedge-shaped on section. In the lungs were numerous dark-red, airless patches. Beyond these there were no other changes. The blood of the animal injected into others produced an essentially similar condition. Microscopic examination of the organs showed large numbers of micrococci, mostly single or in pairs. They measured about 0·25 $\mu$ in diameter. In many parts they were seen in masses, adhering to the walls of the capillaries, and enclosing some red corpuscles amongst them. Koch thinks that these accumulations lead to capillary thrombosis; in fact, he observed complete thrombosis in many places, especially in the glomeruli of the kidney. He suggests that such thrombi may possibly get washed on into the blood-stream, and set up secondary abscesses. These observations have not, so far as we know, been at present confirmed. They are quoted here at length because of their novelty, and because if confirmed they will go far towards explaining the occurrence of the secondary abscesses in those cases of pyæmia in which no source of embolism can be detected by the naked eye.

(18.) For the purpose of grouping and comparing the cases of pyæmia which have been collected, the following classification has been adopted.

I. Cases of pyæmia, secondary to an open wound, in which there is no evidence that the secondary inflammations are due to embolism.

(*a.*) Cases in which visceral abscesses are wanting.

(*b.*) Cases in which visceral abscesses are present, but no softening thrombus is found at the primary seat of disease.

II. Cases in which venous thrombosis has occurred apparently as one of the secondary affections.

III. Cases in which venous thrombosis and softening of the thrombus occur without giving rise to embolisms or secondary abscesses.

IV. Cases in which venous thrombosis and softening of the thrombus have occurred with scondary abscesses in other viscera, but not in the lungs.

V. Cases in which venous thrombosis with softening of the thrombus has occurred with abscesses in the lungs and in other viscera.

VI. Cases in which venous thrombosis and softening of the thrombus occur with embolic abscesses in the lungs only.
VII. Cases of "pyæmia" secondary to infective periostitis.
VIII. Cases of "pyæmia" secondary to infective endocarditis.
XI. Infective myositis.
X. Spontaneous septicæmia and pyæmia.

(19.) I. CASES OF PYÆMIA IN WHICH THERE IS NO EVIDENCE OF EMBOLISM.

(*a.*) *Without visceral abscesses* (Appendix II, Table II).—Twenty-four of the hundred and fifty-five cases collected belong to this group. The local inflammations were distributed as follows:

| | |
|---|---|
| Joints only | 8 |
| Joints and subcutaneous tissue | 3 |
| Subcutaneous or intermuscular tissue only | 4 |
| Inflammation of serous membranes only— | |
| Pleurisy | 2 |
| Peritonitis | 1 |
| Meningitis | 2 |
| Meningitis and pericarditis | 1 |
| Muscular substance of heart (diffuse) | 1 |
| Muscular substance of heart (diffuse) and areolar tissue beneath fascia lata | 1 |
| Suppuration of simple fractures and bruises | 1 |
| | 24 |

The primary diseases and injuries may be classed as follows.

| | |
|---|---|
| Injuries or diseases affecting the genito-urinary tract | 7 |
| Diseases or injuries affecting the soft parts other than urinary organs | 6 |
| Amputations | 5 |
| Diseases of joints | 3 |
| Compound fractures | 3 |

In nineteen of the cases, the clinical history was obtainable, as well as the *post-mortem* appearances. In fifteen of these, the time of invasion after the commencement of the primary disease, or injury, could be ascertained with tolerable certainty. Ten commenced in the first week, two in the second, and the remaining three on the twentieth, twenty-third, and thirty-first day. (Table II, Nos. 1, 6, 3).

The duration of the cases before the fatal termination was very various. It is tolerably accurately recorded in eighteen cases, of these five died in the first week, five in the second, four in the third, and the remaining four survived to the thirtieth, forty-ninth,

fifty-second, and sixty-second days. (Appendix II, Table II, Cases 12, 5, 18, and 10).

The following were the most prominent symptoms, amongst the nineteen cases, fully reported. Rigors occurred in eleven, and were absent in eight. They were present in all the cases arising from diseases of the genito-urinary organs. They were present only three times amongst the nine cases which terminated fatally during the first two weeks, but amongst the eight which exceeded that period they were only wanting once. Profuse sweating without the occurrence of rigors, was noted in four cases. The temperature in every case was high, and when not complicated by rigors, was tolerably regular. Diarrhœa was found a prominent symptom in five cases (Cases 3, 4, 5, 10, 19). Vomiting in six (Cases 1, 9, 11, 12, 13, 19). In only one case (No. 19) are vomiting and diarrhœa noted as occurring together. Delirium was marked in eight cases.

The *post-mortem* appearances in addition to the local secondary inflammations before noted, were in many cases those changes common to all forms of blood-poisoning. Out of the twenty-four cases, the following are noted.

| | |
|---|---|
| Swollen spleen . . . . . | 9 times. |
| Congestion of the lungs . . . . . | 10 „ |
| Swollen liver . . . . . | 6 „ |
| Cloudy swelling of kidney . . . . | 14 „ |

On comparing these figures with those given for septic intoxication and septic infection without metastasis, it will be observed that internal congestions are of much less frequent occurrence than in those affections.

In three of these cases the blood was examined during life for bacteria, but nothing was found (Cases 5, 13, 14). The viscera were microscopically examined in four cases (Cases 5, 13, 14, 19), and in only one were any micrococci observed, and then only one colony was found, after very prolonged searching, in the lymphatic glands nearest to the lithotomy wound.

Case 18 has been included in this group although in some respects it differs from the rest. The blood-poisoning arose from a compound fracture of the lower jaw, but the suppurations which followed occurred exclusively at the seats of various subcutaneous injuries which at first seemed progressing favorably. This case is especially interesting in connection with the experiments of Professor Chaveau ("Étude experimentale sur les phénomènes de mortification et de

putréfaction qui se passent dans l'organisme animal vivant," 'Bull. de l'Acad. de Med.,' 1873), quoted by Dr. Sanderson in his lectures, "On the Infective Processes of Disease." These showed that a diffuse inflammation could be started in the seat of a subcutaneous injury by the injection into the blood-stream of a dose of septic matter shortly after the occurrence of the injury. This suppuration occurring at the seat of subcutaneous injuries is also illustrated by Case 9, Group III, Appendix II.

The two cases of myocarditis (Cases 16 and 17) were included in this group because the inflammation was general and diffuse, and nowhere had it given rise to localised collections of pus.

The comparatively large proportion of these cases that arise from affections of the genito-urinary system is a point of considerable interest, but the number of cases is so small that it may be merely the result of chance.

As a general summary of these 24 cases it may be said that the disease set up is a condition of blood-poisoning leading to a tendency to suppurative inflammation of serous and synovial cavities, and diffuse inflammation of tissues, unconnected in any way with embolism. The extremely chronic course of some of the cases is accounted for by the secondary inflammations not attacking vital organs.

In all, except some of the urinary cases, in which it was impossible from the nature of the wound to ascertain its exact condition, the discharges from the primary source of infection were in a state of putrefaction.

The cases collected being only those which terminated fatally there is no evidence here given as to the mortality from this form of pyæmia, but it is a well-known fact that recovery is by no means uncommon.

(20.) Group I (*b*).—*Cases in which visceral abscesses are present but in which no evidence exists of thombosis and of disintegration of the thrombus with embolism* (Appendix II, Table III).

Of this form 28 cases have been collected, 16 with the clinical features and history, 12 with the post-mortem examination only. The secondary inflammation and suppurations were distributed as follows:

| | |
|---|---|
| Lungs and subcutaneous tissue | 3 |
| Lungs and joints | 2 |
| Lungs, liver, joints, and subcutaneous tissue | 1 |
| Lungs and liver | 3 |

| | |
|---|---|
| Lungs, liver, and spleen | 1 |
| Lungs, liver, and kidney | 1 |
| Lung on one side, pleura on the other | 1 |
| Lungs only | 8 |
| Lungs and brain | 2 |
| Liver and parotid gland | 1 |
| Spleen and kidney | 1 |
| Spleen only | 1 |
| Brain only | 1 |
| Liver, spleen, kidney, heart, pericardium, pleura, joints | 1 |
| Subcutaneous tissue and pericardium | 1 |
| | 28 |

The primary diseases may be classed as follows:

| | |
|---|---|
| Injuries or diseases of urinary organs | 4 |
| Diseases of other soft parts | 10 |
| Amputations | 4 |
| Diseases and operations on joints | 5 |
| Compound fractures | 1 |
| Diseases of bones | 2 |
| Ulceration of intestines | 1 |
| Doubtful | 1 |
| | 28 |

The date of the invasion of the secondary disease after the commencement of the primary affection could not be ascertained accurately in more than 10 cases. In 7 it was under five days. In the remaining 3 cases on the eighth, fourteenth, and twenty-first day.

The duration of the cases after the invasion could be tolerably accurately ascertained in 13. Four died in the first week, 6 in the second, and the remaining 3 in the third. In none was the case prolonged as in the last group.

The chief symptoms are tolerably accurately reported in 15 cases. Rigors occurred in 12 of these, and were absent in 3. In both the urinary cases they were present. As in the previous group, the cases in which they were absent were amongst the most acute. The temperature was high and irregular. Profuse sweating is mentioned as a prominent symptom in 3; diarrhœa in 4; vomiting in 8; delirium in 5; jaundice in 3, in all of which the liver was the seat of secondary abscesses. Rapid respiration is noted in 2 cases. A pustular eruption on the skin in 1 (Case 12).

In addition to the metastatic inflammations before mentioned, the

following *post-mortem* appearances were noted. Congestion of the lungs in 8; swollen liver in 5; swollen spleen in 19; swollen kidneys in 13.

Although in all these cases no softening thrombus was detected in the veins which would suggest embolism as a cause for the secondary suppurations, it is quite possible that in some it may have existed and escaped observation. Thus, for example, of the 8 cases in which abscesses were found in the lungs only 2 were urinary cases, in which it is always difficult to trace the veins, 1 arose from diffuse cellulitis and incisions in the neck, 1 from a foul wound in the thigh, 1 from a sloughy abscess in the forearm and above the knee, and 1 from a foul abscess round the rectum, and in 1 the limb was amputated after the first rigor, and no record is given of the veins in the part removed, and in 1 the disease followed castration for tubercular testicle. The post-mortem notes state that the cut section of the cord exuded pus from minute abscesses. Possibly these were connected with the veins. In all these cases thrombosis might have been overlooked.

A comparison of the *post-mortem* appearances of this group of cases with those in which thrombosis was noted will be made after the summary of the latter.

(21.) Group II (Appendix II, Table IV).—These six cases are separated from the rest, not on account of any supposed difference in nature, but because they show that thrombosis of the veins at a part of the body distant from the primary disease, with softening of the thrombus and embolism, may occur as a part of the secondary manifestations of pyæmia. They suggest that if this may occur at a distance from the primary affection, possibly when the same changes are found at the primary seat of disease, they may in some cases be due to an antecedent condition of blood-poisoning. The six cases were as follows:—

Case 1. Thombosis with softening of the clot and suppuration round the popliteal vein following amputation of the hand. One embolic abscess in the lung. Spleen pulpy; duration of case fifteen days.

Case 2. Thrombosis and softening of the clot in the veins of the leg, secondary to an old empyema with an external opening. Secondary abscess in lungs, and liver, and brain. Duration of case seven days.

Case 3. Thrombosis and softening of the clot in the veins of the arm and forearm, five days after a compound fracture of the lower

jaw. One small infarct in lung; a little lymph on the surface of brain. Duration of case five days.

CASE 4. Thrombosis and softening of the clot in the veins of the leg after removal of a small tumour from the tongue. Swelling of spleen, liver, and kidneys, and congestion of lungs. Duration of case about sixteen days.

CASE 5. Thrombosis without softening of the clot in the veins of the leg after external urethotomy. Congestion of lungs, and pulpy spleen. Duration of case eleven days.

CASE 6. Scirrhus of the breast, with a foul abscess in the axilla. The short saphenous vein was full of purulent fluid. Pus in the joints.

In Case 3, a microscopic examination was made of the organs after death (see Microscopic Notes). Micrococci were found in great abundance in the various organs. In the supra-renal capsules the blood-vessels in the medullary part were plugged with coagula containing groups of micrococci. This observation is of great interest when taken in conjunction with Koch's experiments on artificial pyæmia in rabbits, before quoted, in which he is led to the conclusion that accumulations of micrococci in the capillaries may lead to thrombosis.

(22.) GROUP III (Appendix II, Table V).—*Cases in which, although venous thrombosis and softening of the thrombus occurred, death took place without the occurrence of embolism.*—This small group of four cases has been separated from the others as illustrating the fact that, though thrombosis and softening of the thrombus may be present, they may take no immediate part in the production of the fatal result.

CASE 1 was a large psoas and iliac abscess opening on the thigh. The femoral vein was plugged with softening clot.

CASE 2. The symptoms commenced four days after an amputation of the thigh. The veins were swollen and filled with very friable clot.

CASE 3 arose after excision of a large part of a varicose vein in the leg. The vein above the part removed contained a softening clot.

CASE 4 followed retention of the placenta after abortion. The veins of the pelvis contained puriform clot.

In each of these cases the *post-mortem* appearances were those of "septicæmia." In all four, the patient died within a short time

of the invasion of the secondary disease. Had they lived longer, in all probability embolism would have occurred, and the cases would then have presented the ordinary *post-mortem* appearances of embolic pyæmia. The last group of cases apparently showed that venous thrombosis and softening of the thrombus may be a result of the condition of blood-poisoning. In the present group the blood-poisoning seems to have preceded the thrombosis, and may possibly have been a cause of it. On the other hand, the coexistence of venous thrombosis and blood-poisoning in the same case may have been merely accidental. There is no evidence definitely to prove the relation of the two conditions to each other, one explanation being as plausible as the other.

GROUP IV (Appendix II, Table VI).—*Cases in which thrombosis occurred in the veins of the primary seat of diseases, with no secondary abscesses in the lungs, but inflammations and suppurations in various other parts.*—Of the forty-seven cases collected in which venous thrombosis was observed at the primary seat of disease, abscesses were not found in the lungs in nine. In these the secondary inflammations were distributed as follows:

| | |
|---|---|
| Joints and muscles | 2 |
| Joints only | 4 |
| Liver, spleen, and endocardium | 1 |
| Liver only | 1 |
| Liver and spleen | 1 |
| | 9 |

In the case in which the liver and spleen and endocardium were affected, the primary disease was ulceration of the gall-bladder and phlebitis of the portal vein (Case 6). In the one in which the liver only was affected the primary disease was pericæcal abscess (Case 5). These two may, therefore, be looked upon as embolism affecting the portal system of veins. In four more (Cases 1, 3, 8, 9) the absence of embolism can be accounted for by the fact that the softened thrombus was shut off from the blood-stream by a barrier of unsoftened clot. In each of these cases the joints were suppurating and visceral abscesses were wanting. In one there was also pneumonia, but no signs of embolism. These would, therefore, seem to resemble closely the last group of cases, the thrombosis, although occurring at the seat of the primary disease, being possibly determined by the blood condition which killed the patient. On the other hand,

they might be explained as an accidental coexistence in the same case of a blood condition similar to that occurring in the cases included in group I (*a*), with thrombosis. In the three remaining cases (Nos. 2, 4, 7,) the joints only were affected in one, joints and muscles in one, and the liver and spleen in the other. In the two first it is difficult to understand how the patient escaped embolism, as there seems to have been no barrier of clot, as in the four cases just mentioned, with which they must be grouped. In Case 7, it is probable that the detritus of the clot was so fine that (as O. Weber has shown to be possible) it passed the lungs and lodged in other parts, as distinct infarcts were found both in the liver and spleen. In this group, as in the others, the tendency of "pyæmia" secondary to diseases of the urinary organs to affect the joints is well shown. In each of the three urinary cases (Nos. 2, 3 and 4) the joints were implicated.

(23.) Group V (Appendix II, Table VII).—*Cases in which venous thrombosis and softening of the clot occurred, with abscesses in the lungs and in other viscera and tissues.*—In thirteen of the forty-seven cases in which there was thrombosis of the veins leading from the primary seat of disease, the abscesses occurred in the lungs, but were not limited to them. The secondary abscesses were distributed as follows:

| | |
|---|---|
| Lungs and spleen | 3 |
| Lungs and liver | 2 |
| Lungs, kidney, and heart | 1 |
| Lungs, spleen, and kidney | 1 |
| Lungs and joints | 1 |
| Lungs and subcutaneous tissue | 1 |
| Lungs and brain | 2 |
| Lungs, spleen, brain, kidney, heart, and subcutaneous tissue | 1 |
| Lungs and various parts injured subcutaneously | 1 |
| | 13 |

The primary affections in these cases may be subdivided thus:

| | |
|---|---|
| Compound fracture | 1 |
| Amputations | 5 |
| Diseases of bone | 2 |
| Diseases of joints | 1 |
| Intestinal canal | 1 |
| Urinary organs | 2 |
| Subcutaneous tissue | 1 |
| | 13 |

The time of invasion of the symptoms after the commencement of the primary disease could only be ascertained in five cases. In four it began in the second week, and in one in the fourth. The duration of the case after invasion is recorded accurately in nine cases. In one it was two days, one four days, one five days, three seven days, one eleven days, one twelve days, and one twenty days. In these nine cases, rigors were wanting in three, and in only two (Nos. 7 and 9) were they repeated more than once. In one case (No. 7) the patient apparently recovered from an attack of blood-poisoning secondary to an amputation, and died from pyæmia coming on sometime after from a bed-sore. The veins leading from the stump were healthy, while those from the bed-sore contained softening clot.

The other symptoms noted amongst these nine cases were: jaundice in one, in which there were abscesses in the liver; diarrhœa in three, vomiting in none, sudden dyspnœa in one, delirium in six, rapid emaciation in four. In the thirteen cases in which the *post-mortem* notes are recorded; petechiæ were noted in three, swollen kidney in six, swollen liver in seven, swollen spleen in seven, and congestion of the lungs in four.

(24.) Group VI (Appendix II, Table VIII).—*Cases in which, with thrombosis and softening of the thrombus, secondary abscesses were found only in the lungs.*—Under this heading come twenty-four cases of which the clinical record has been obtained in twenty-one and the *post-mortem* notes in all.

The primary affections in these cases were as follows:

| | |
|---|---|
| Amputations | 9 |
| Compound fractures | 6 |
| Joints, excisions and diseases of | 3 |
| Diseases of bone | 2 |
| Affection of urinary organs | 1 |
| Affection of other soft parts | 3 |
| | 24 |

The proportion of cases in this group arising from affection of the bones contrasts strongly with that in the table of primary disease for Group I *a* and *b*. In this group, twenty out of twenty-four arose from diseases affecting the bones and joints. In the first group, only twenty-three out of fifty.

The time of invasion after the commencement of the primary disease could be ascertained only in fourteen cases. In five the invasion occurred before the end of the third day; in four more before the end of the first week, and the rest at varying times up to the thirty-ninth day.

The duration of the case after the first distinct symptoms was ascertained in nineteen cases with the following results.

| | | | |
|---|---|---|---|
| 1st week | 2 days | 1 case. | 11 cases. |
| | 3 days | 4 cases. | |
| | 5 days | 2 cases. | |
| | 6 days | 3 cases. | |
| | 7 days | 1 case. | |
| 2nd week | 8 days | 1 case. | 5 cases. |
| | 9 days | 1 case. | |
| | 10 days | 1 case. | |
| | 12 days | 2 cases. | |
| | 18 days | 1 case. | |
| | 19 days | 1 case. | |
| | 32 days | 1 case. | |

On comparing this table with that for cases of "septicæmia," it will be seen that the difference in duration is not sufficient to justify the assertion sometimes made that those cases which die without secondary abscesses would have developed them had they lived longer.

Amongst the chief symptoms in the twenty-one cases of which the clinical record was obtained were the following:

Rigors in fifteen. Three of the six in which they were wanting were young children. Diarrhœa in one case; delirium in five; jaundice in one; marked emaciation in five: petechiæ on the skin in one; profuse sweating apart from rigors in one. Convulsions occurred in one child. The temperature was such as has been frequently recorded and no comment is needed upon it.

Of the *post-mortem* appearances beyond the abscesses in the lung, the following were recorded: Swollen spleen in twelve, swollen kidney in 13, subserous petechiæ in three. In a large proportion of the cases the *post-mortem* examination revealed nothing abnormal beyond the primary affection, the thromboses, and the softening infarcts and abscesses in the lungs, or at most the swelling of the spleen and kidneys was such as might be expected from the febrile condition preceding death. The pulpy spleen of septicæmia is

rarely met with in this form of pyæmia. The want of these signs of general blood-poisoning suggests that in many cases it may really be absent, and that the disease may be merely a local process of thrombosis followed by decomposition and breaking down of the clot commencing from the part of the vein implicated in a foul and unhealthy wound. The putrid embolisms from this source lodging in the lungs would set up local processes of inflammation, suppuration and gangrene, which might readily be conceived to prove fatal without the induction of any general infective process in the body.

It has been part of the object of the inquiry to attempt to obtain evidence on this point by microscopic examination of all the organs in such cases, even when, to the naked eye, they appeared healthy.

On the other hand, it can hardly be doubted that the cases grouped in the first two classes do in reality depend on a general infective process, as also probably do many of those included in Groups III, IV, and V; either wholly or in part. It is interesting with regard to this question to compare the *post-mortem* appearances of those cases in which thrombosis with disintegration of the thrombus is known to have been present, with those in which it is not. Of the latter out of fifty-one cases in only eight were the secondary affections limited to the lungs, and possibly in some of these eight, a more careful examination might have lead to the detection of a softening thrombus. In the forty-seven cases in which thrombosis was known to be present the secondary mischief was limited to the lungs in twenty-four, or almost one half. This would seem to indicate the difference in nature between the two classes of cases. There seems no reason why if they are merely modifications of one disease, that the occurrence of thrombosis should diminish the likelihood of secondary abscesses occurring elsewhere than in the lungs, and yet if we hold them to be the same affection we are driven to the hypothesis that because the veins and lungs are affected the other tissues escape. The more rational explanation would seem to be that just as before pointed out with regard to "septicæmia." We have classed under that name two affections, one which is not infective and in which the poison does not multiply in the organism, and another in which a true general infective process is established; so it may be with the diseases grouped under the name of pyæmia. There may be a local thrombosis, with decomposition and disintegration of the thrombus followed by embolism causing local abscesses in the viscera only,

which cause the death of the patient, or there may be a true general infective process, the local manifestations of which are congestions, inflammations and suppurations disseminated through the body both in the viscera and elsewhere. At the same time there is nothing improbable in both these conditions co-existing in one patient. Experiments on animals have shown (see Koch's observation quoted before) that an affection of this kind can be artificially induced, and that when it is once started it can be communicated from animal to animal by inoculation. No experiments, so far as we know have shown that the fatal affection caused by septic embolisms, artificially produced, is communicable by means of the blood from one animal to another. It is possible, therefore, that in the human subject there may exist a specific infective process, having the symptoms of the affection we know as pyæmia, which is communicable from patient to patient, and again that in other cases the disease may consist merely of local visceral inflammations, suppurations, and necroses arising as a result of the lodgment of septic emboli, but yet may be non-specific and non-communicable, and unconnected with any general infective process.

Finally, with regard to the whole of the foregoing cases, both of "septicæmia" and "pyæmia," it is to be noted that with the exception of three arising from diseases of the abdominal viscera, and possibly some of the urinary cases and one of "septic infection" arising after an excision of the knee dressed antiseptically and in which the discharges were free from any odour of decomposition, the secondary disease arose in every case in connection with decomposing discharges.

(25.) Group VII (Appendix II, Table IX). *Infective periostitis; acute necrosis.*—The cases of pyæmia secondary to acute necrosis should, from a clinical and pathological point of view be separated from those arising from external wounds, &c. No doubt the poison, whatever it may be, is disseminated in the same way as in some of the cases classed in the previous groups, but we have no evidence that it is the same in nature. Acute necrosis commences with all the characteristic signs of a fever, thus suggesting the idea of something specific in its nature. That the exudation beneath the periosteum possesses the most intensely infective properties before it can have been contaminated by the entrance of air from without is shown by the frequency with which metastatic inflammations, usually of

embolic origin, occur before the subperiosteal abscess has been opened. This is illustrated by Cases 1 and 2. Case 4 occurred during the present inquiry. There was extensive thrombosis of the veins of leg on admission. The tibia was surrounded by a large collection of pus. The patient died on the sixth day with well-marked "pyæmic" symptoms and *post-mortem* appearances. The blood and pus were examined during life, but no organisms were detected. Five and a half hours after death jointed moving bacteria were seen in the blood from the right auricle. Microscopic examination of the organs showed micrococci in the thrombosed vein and in various other parts of the body. The urine of this case was analysed quantitatively and qualitatively.

Cases 3 and 7 were also examined microscopically. Case 8 has been included amongst those of acute necrosis from its close resemblance, clinically, to Case 7.

(26.) Group VIII (Appendix II, Table X). *Infective endocarditis; ulcerative endocarditis.*—This disease should also be kept distinct for the same reasons as acute necrosis. We know that the secondary abscesses are due in these cases to a great extent, if not entirely, to embolism; but of what it is that renders the embolus infective we have no certain knowledge. The fact that organisms (bacteria) have been found in the vegetations attached to the valves is well known, but the part they play in the process is not certain. Only two cases of this affection came under the observation of the committee during the present inquiry, for one of which they are indebted to the kindness of Dr. Greenhow, of the Middlesex Hospital.

(27.) Group IX. *Infective myositis.*—The name of infective or malignant myositis has been given by Dr. Nicaise ('Revue Mensuelle de Médécine et de Chirurgie,' 1877) to a peculiar form of disease, consisting of acute, diffuse, suppurative inflammation of various parts of the muscular system with grave general symptoms, terminating rapidly in death. One case of this rare affection occurred at St. Thomas's Hospital during the present inquiry, the clinical and pathological notes and the microscopical examination of which will be found in Appendix IV, Case 2.

(28.) Group X (Appendix II, Table XI). *Spontaneous septicæmia and spontaneous pyæmia.*—Under these names have been described

certain rare and obscure cases in which symptoms analogous to those of septic infection and pyæmia have arisen without any discoverable local source of infection. Four such cases are briefly summarised in the appendix (Table XI). None of these occurred during the course of the present inquiry. They are merely appended as illustrations of the disease in question. They are not sufficient in number to justify any conclusions being drawn from them.

(29.) SUMMARY.—It would seem from a careful study of the cases here collected that it is probable that the diseases commonly known clinically (Appendix II, Table XI) as pyæmia and septicæmia may be grouped as follows:—

1. *Septic intoxication.*—The effects of poisoning by the chemical products of putrefaction. A non-infective disease.

2. *Septic infection.*—A general infective process arising from the introduction of some peculiar constituent of putrid matter into the blood-stream. It is supposed by some to be due to the multiplication of living organisms in the blood, and by others to the effect of a non-organised ferment. It terminates fatally without secondary inflammations.

3. *Pyæmia* (for want of a better name).—An infective process probably similar in nature to septic infection, but differing from it in giving rise to local inflammations and suppurations, often complicated by thrombosis and embolism, possibly due to the blood condition.

4. Thrombosis with softening and decomposition of the thrombus and embolism, causing local abscesses in the viscera wherever the septic emboli lodge, but without the development of any general infective process.

5. Various combinations of one or more of the foregoing conditions in the same subject.

6. Infective periostitis or acute necrosis.

7. Infective endocarditis or ulcerative endocarditis.

8. Infective myositis.

9. A group of obscure cases in which it is impossible to form any idea as to their exact nature, often called spontaneous septicæmia or pyæmia.

It is not intended to assert that all these varieties are proved to exist as distinct diseases, but that such a classification as the above

may serve as a basis for further clinical and pathological investigation. It is quite certain that our knowledge is not yet sufficiently advanced to justify the assertion that all these various forms are only modifications of one disease. If such an assertion can ever be proved to be true it can only be when the exact nature of every form is perfectly understood, a time which we venture to predict is still far distant. The apparent merging of one form of "septicæmia" or "pyæmia" into another, which has led some observers to such a belief, may equally well be explained by supposing the co-existence of two or even more of the foregoing conditions in the same case. Thus, a patient suffering from the effects of septic embolism may at the same time be poisoned by the absorption of the chemical products of putrefaction from the wound. On this point Billroth says:—"It is, in fact, scarcely possible to find a name for every combination which occurs between sepsis, purulent infection, diffused metastatic processes, thrombosis, embolism, &c. We see, for instance, sepsis without any trace of metastasis, sepsis with diffused metastasis, sepsis with thrombosis and embolism. We see purulent infection with diffused metastasis and thrombosis, with thrombosis alone, with thrombosis and embolism. We have thrombosis with consequent local phenomena without embolisms, with embolisms, with hæmorrhagic effusions, with apoplexies, &c."

---

# PART III.

## MICROSCOPICAL EXAMINATION OF BLOOD, AND CHEMICAL EXAMINATION OF THE URINE MADE DURING LIFE.

(30.) Blood.—The examination of the *blood* in cases of pyæmia and septicæmia had for its main object the determination of the presence or absence of micrococci and bacteria. At the same time any other salient features were noted, and the relative proportion of the red and white corpuscles estimated in a series of cases. It had been observed that in many instances a very large increase of leucocytes occurred, both proportionally to the red corpuscles and to the total

mass of blood, and it was desired to ascertain whether this was a constant feature, whether the number had any special relation of time to the rigors, and also in what way this change might be related to the local symptoms.

The enumeration of the red corpuscles was not attempted in any continuous series of cases, for it was found that the length of time required in any given case for the thorough examination for bacteria precluded any consecutive observations on other points. Each examination of the blood usually occupied from one to one and a half hours, or even longer, when any considerable number of observations were made.

(31.) *Method of examination.*—In order to ensure as complete uniformity as possible, the method was in nearly all cases the same. The examination was made with a Hartnack No. 10 immersion objective, a low micrometer eyepiece, and a graduated drawtube. In many cases other powers were also employed, especially in the examination of bacteria, but all the results here recorded may be understood to be from examinations made in this way, unless other powers are mentioned. The warm stage was used in some cases, but the practical difficulty of carrying it about constantly, and having it always ready for use when required, led to its disuse in the majority, in order to secure more uniform results.

The blood examined was obtained either from the finger or the lobe of the ear. After washing the part and cleansing with absolute alcohol, it was punctured with a common sewing needle, or a broad-pointed, double-edged needle, a drop of blood taken in a large cover-slip, and the latter dropped on to a slide, which was then immediately examined. It was found that with some practice great uniformity could be attained in the thickness of the layer of blood thus examined, a single layer of corpuscles being found in every field. Every precaution was taken to ensure cleanliness, and also uniformity in the mode of examination.

The enumeration of the red and white corpuscles was effected by means of the oculaire carrée of M. Malassez. The drawtube of the microscope having been graduated, and the same lens, &c., used, it was found, after a long series of observations on blood from persons in health and those suffering from various diseases, that the number of red corpuscles in a given square of similarly-prepared slides was almost uniform, and that only a very small difference was found if they were counted individually, or by squares, each of which con-

tained an average of sixteen. It thus became comparatively easy to count, in a number of fields, the red and white corpuscles, and to arrive at a pretty accurate estimate of their relative proportions.

Everyone who has been engaged in similar observations knows the many difficulties resulting from aggregation of leucocytes, currents in the fluid, and the like, but the great uniformity in the results in a given case on repeated examinations gives the observations a definite value.

(32.) In the record of these observations[1] the precise features of the blood are noted, whether they deviate from the normal or not. This course has been followed in order that there may be no misconception of the meaning of the terms employed. The mere statement that bacteria or micrococci have been found in the blood is always open to a doubt as to what are the grounds on which the bodies in question have been so called. Hence, although it involves much repetition of normal characters, it has been thought desirable to give the notes in detail in the Appendix.

It should also be stated that, in order to check the observations on the blood in pyæmia, a large number of similarly conducted observations were made upon the blood of patients suffering from other fevers and from long-continued suppuration. Scarlet fever, enteric fever, acute rheumatism, and other cases with high temperature were especially selected. These observations have not been given in detail, as they did not reveal any new facts.

(33.) *General characters of the blood.*—The blood was examined in eighteen cases. Other observations were made, but they were not so minute, and only confirmed the results derived from these more exact ones. Only the general results are here summarised.

The general characters of the blood varied considerably. In some few cases it presented the characters of anæmic blood, very scanty proportion of red corpuscles, and consequent slow or imperfect formation of rouleaux, &c. In the rest only a less degree of these characters was noted.

In none of the cases were there any strikingly abnormal characters of the red blood-corpuscles, such as have been stated to occur in septic diseases. The red corpuscles were not abnormally crenated, they usually formed natural rouleaux, and where measured they did not diverge from the normal size. Microcytes were rarely seen.

[1] Appendix III.

The proportional richness in red blood-corpuscles was not estimated in any series of cases, owing to the length of time necessary for the other observations on the presence or absence of bacteria, and on the proportion of white corpuscles.

The white corpuscles were in nearly all the cases (14 out of 16) greatly in excess, both absolutely and relatively to the red. In most cases this increase in number was not attended with any marked change in their characters. The usual variations in size were observed, but there was no sign of fatty degeneration, or of abnormal nucleation, such as is seen in leucocythæmia. The amœboid movements were natural and active, in some cases unusually so.

(34.) *Proportional increase of white corpuscles.*—The estimation of the number of white corpuscles was made by actual counting of white and red in a number of fields and taking the average. The constancy of the results in repeated observations is a guarantee of the approximate accuracy of this method. Of the sixteen cases thus examined, in only ten were the observations sufficiently extensive and exact to allow of a precise estimate being given. Of the remaining six cases, in which circumstances forbade such exact estimation, in two there was no apparent increase, in one they appeared to be equal in number to the red (it is not intended to assert that they were so, or even nearly so, as the mere appearance is highly fallacious), in two they were very greatly increased, and in one other case examined shortly before death there was enormous increase.

In the ten cases exactly estimated, the proportional increase was very various. Taking the average of the total number of estimations in each case on different days, it is found that the lowest proportion of white to red observed was 1 to 100, the highest 5·6 to 100, that is, from 1 white to 100 red, to 1 white to 18 red. But in eight out of ten cases no lower proportion than 1 to 50 was at any time observed, in five of these it was 1 to 25, or higher.

Variations in the proportion were also observed in the same case at different periods, often at short intervals. Thus in one case observed on seven successive days; the proportions were—

| | |
|---|---|
| 1st day . . . . . | 1 to 50 |
| 2nd „ . . . . . | 1 to 40 |
| 3rd „ . . . . . | 1 to 140 |
| 4th „ . . . . . | 1 to 45 |
| 5th „ . . . . . | 1 to 100 |

| | |
|---|---|
| 6th day . . . . . | 1 to 50 |
| 7th „ . . . . . | 1 to 100 |

These variations were not accurately paralleled by any change in temperature or symptoms, but it was observed that the lowest proportion succeeded the occurrence of severe and repeated rigors, and that it soon returned to the previous proportion. (It should be stated that a very large abscess existed in the pelvis).

The increase in the number of white corpuscles did not appear to depend upon the size of the wound or the amount of suppuration. Thus, it was very high in cases of perineal section with only general blood-poisoning, in cases of excision of elbow, and of amputations of arm and shoulder-joint; but proportionately low in two cases of thigh amputation, high in another, apparently wanting in another. It was also high in a case of ulcerating endocarditis in which there was no abscess properly so called, but puriform exudation in the pleuræ and peritoneum.

The proportion was not ascertained in any case of septicæmia proper. Nor was there any special relation to the presence or absence of a softening thrombus discharging itself into the blood-stream.

(35.) *Absolute increase of white blood-corpuscles.*—The increase of white corpuscles cannot be so exactly estimated. The evident diminution of red corpuscles in nearly all cases makes the proportional increase relatively to the red a lower percentage than that to normal. But as all the observations were made under similar conditions and with the same power, and a large number of other observations were made under, as nearly as possible, similar conditions on healthy blood and blood in various diseases, an approximately accurate estimate may be made. The number of white corpuscles in the field averages 2·5 in healthy blood thus examined.

In the observations in pyæmia the lowest average in a field was 12; 20 to 30 were of frequent occurrence, and even 60 to 70 in a field were counted. Higher numbers were sometimes seen. If we take 1 white to 300 red as the highest normal average in health, the calculations based on the number observed, the average of fields would give nearly the same results as those which were actually obtained by counting.

(36.) *Bacteria in the blood during life.*—It appears from our observations,[1] that although bacteria of various forms were found in

[1] Recorded in Appendix III.

the blood in a number of cases, they could not be found in all the cases, nor were they discovered constantly in those cases where at one or other time they were present. Moreover, in the same case several forms might be seen together, and the form varied considerably in different cases. It may be gathered from this, that one examination of the blood could not be sufficient to exclude the possibility of the presence of bacteria, for it was found that at one time a large number presenting certain very definite characters were to be seen, and a few hours later the most careful search failed to detect any.

The discovery of bacteria of any form in the blood is of so much importance in the light of recent investigations on putrid infection, that before discussing any of the points here raised, it will be well to summarise the results of the observations in these cases, mentioning briefly the several forms observed. In some of the cases only one form was noticed, in others two or three. It will be a question for future consideration whether these several forms are distinct, or whether they are merely stages in the development of one and the same organism. At present they may be described according to their appearance, as micrococci and bacteria.

(37.) *Micrococci in the blood.*—Although it may be presumed from the results of the microscopical examination of the tissues, that micrococci were probably present in the blood during life in nearly all cases, yet their recognition is a matter of the greatest difficulty, whether they are isolated or in masses. For although it might be possible by the aid of reagents or by cultivation to identify them, it is practically impossible by means of the microscope to distinguish them from other granules of similar size in blood examined by the ordinary methods. It is quite possible that some of the bodies described as jointed bacteria may have been linked micrococci, or micrococcus chains—zooglœa masses of micrococci distinctly recognizable as such were not observed.

In some observations which have been made upon the blood, micrococci have been stated to exist in the white corpuscles in large quantity. Such a condition was not recognised in any of the cases examined.

(38.) *Bacteria in the blood during life.*—The smallest bodies observed had the form of jointed filaments of extreme tenuity, composed of 2, 3, to 8 or more minute elements, which, so far as they could be resolved, were themselves of ovoid or rod-shape. The

jointed filaments themselves measured from ·75 $\mu$ to 3· $\mu$,[1] and the length of the individual elements (estimated by division of the length of the chain by the number of such elements), about ·15 to ·25 (Plate I, fig. 1 *a*).

These bodies differ greatly in their appearance from the ordinary *Bacterium termo*, not only in size, &c., but in the apparently far lower refractive index, so that they do not stand out with so clear a definition from the surrounding fluid, and require more attentive search, even when very high powers are used. That this is not due solely to their tenuity is shown by the fact that granules of no larger size appear much more distinctly.

Unfortunately, at the time when these were being especially investigated, the methylaniline fluid had not been tried, and they were not therefore stained. But the subsequent examination of other bodies similar in appearance in the blood of the guinea-pig in artificial septicæmia showed that these stained very readily, and were very clearly brought out by this reagent.

Do these filaments possess independent movements? Upon this point a somewhat doubtful opinion must be expressed. For, although the earlier observations convinced the observer that such movements occurred, it is open to question whether the movements seen were not due to currents in the fluid. Both in blood and pus, in which they were also found, such movements continued some time after coagulation had occurred; but considering that there must have been fluid in the interstices of the fibrine filaments to allow of their movements at all, and that they could readily pass through these spaces owing to their minute size, it is at least doubtful how far the movements observed were not produced by such currents. The extreme minuteness of the bodies was such as to render impossible any observation such as can be made on bacterium termo.

Although these organisms were not observed in all cases, in four cases they were carefully watched and measured; in one case[2] they were very minutely observed at three different periods in the blood, and that not only with one specimen, but with several specimens from different parts (ear and finger), and they were also found at one time in the exudation from the granulations of the stump.

[1] The now commonly used micromillimètre, designated by the sign $\mu$, equalling $\frac{1}{1000}$ millimètre, is here employed as the unit of measurement.

[2] Appendix III, fig. Case 4.

It is uncertain whether these bacteria are mere micrococcus chains, or whether they consist of jointed filaments, the latter seems most probable.

2. Ovoid bodies, measuring about from ·3 $\mu$ to ·8 $\mu$, were found to be of pretty frequent occurrence. These possess no special characters. In some cases two similar spores were seen joined together, and presented doubtful locomotive movements.

3. Other larger spherical or ovoid granules, often seen in association with the preceding, measured 1·5 $\mu$ to 2 $\mu$. These were rarely or never seen forming chains or linked together, but in some cases[1] clumps of similar granules, forming zooglœa-like masses, were observed in considerable number. It is noteworthy that this was the only form observed in case of recovery, in which a severe rigor had occurred, and amputation was at once performed.

4. "Dumb-bell" bacteria were observed in only a few cases, not by any means frequently. In a case of myositis and cellulitis[2] they were seen in the blood in large quantities by Mr. Wagstaffe. The bacteria usually described as dumb-bells are, properly speaking, micrococci joined in pairs. But it is probable that other forms are occasionally spoken of as dumb-bells, either short rods in active oscillatory movement, or ordinary bacteria undergoing division. If the bodies observed in this case were really micrococci, the results of the microscopic examination of the heart would be very remarkable, only rod-shaped bacteria having been found there.

5. Rod-shaped bacteria (Plate I, fig. 1 *b*) were seen in the majority of cases in which any form was observed. But even where present most repeatedly and in the greatest number, they were not constantly observed, perhaps owing to want of a sufficient number of observations. These bacteria measure from 1·5 $\mu$ to 2 $\mu$ on an average, but some are 3 $\mu$ or 4·5 $\mu$ in length, and about ·4 or diameter. They move freely with the usual well recognised characters, swimming straight forwards with an oscillatory motion. (In many observations they may be seen to have a great tendency to attach themselves endwise to the coverslip, so that only one end is for a time seen. This may, perhaps, be due to the electric condition induced by rubbing the coverslip with a silk handkerchief kept for the purpose.)

Still bacteria were very seldom seen, had they been present they

[1] Appendix III, Cases 1, 14, 17.

[2] Appendix III, Case 6.

might very probably have been overlooked unless present in large quantity, as the blood was not in the majority of cases stained.

6. In one or two cases other bodies were observed, which did not correspond to any of the ordinary forms of bacteria and may possibly be of an infusorial nature. These were protoplasmic masses measuring about 6 $\mu$ to 8 $\mu$ or rather more in length, and 3 $\mu$ to 4 $\mu$ at the widest part. The extremities taper to a point, one extremity being usually more filiform and curved to one side. They sometimes presented two or three bright dots arranged in a line in the centre. They appeared to move about freely, giving out amæboid processes, but not swimming in the same way as bacteria.

These bodies were observed in three cases, one of which was a case of perineal abscess. Only very few were seen in either case.

As to their nature, much doubt must exist until they have been more frequently observed, they would seem to be rather of amæboid than of bacterial nature.

(39.) If we now classify the eight cases in which bacteria were observed we find that in three the form of bacteria present is not mentioned. In one case only dumb-bells were seen in large numbers. In one case only isolated granules corresponding with large micrococci or spores in their size and appearance were seen. In another case similar spores, isolated or in clusters were found. In four cases not only were there bacteria, but they presented the most varied forms. In one of these (Case 3[1]) both the globular form (micrococci) and rod-shaped bacteria were found, and on one occasion still smaller rods, but not so small as were seen in some other cases. In the rest, globular forms in pairs and chains, and also both very minute and ordinary rod-shaped forms were seen, often side by side.

It would thus appear that so far as these observations go there is no one form of bacterium peculiar to any one kind of disease. These four cases were very distinct in their clinical and pathological facts. One was a case of acute necrosis with multiple suppuration; another of amputation followed by osteomyelitis, with typical symptoms of pyæmia, but in which no secondary abscesses were found after death; a third was a very chronic case of punctured wound, with ultimate formation of an abscess of the brain only; and the last, one clinically of pyæmia, following amputation of the thigh, but without secondary pyæmic abscesses.

[1] Appendix III, Case 6.

(40.) *Examination of the urine.*—The urine was examined in ten cases, and in two a complete quantitative estimation of its constituents was made. No special chemical characteristic was observed in any case to distinguish the urine from that of any acute form of pyrexia.[1] The urinary water was about normal in quantity in the majority of cases, but there were frequent variations from day to day with a tendency, however, to fall below, the standard being evidently maintained by the ingestion of large quantities of beef tea, milk, &c. The reaction of the urine, when opportunity afforded for testing immediately after emission, was generally acid, but it speedily became ammoniacal. The total urinary solids were below the normal except in those cases in which albumen, or pus, or mucus derived from the urinary passage was present to any great extent. The organic solids were rather above the normal, owing to the increase in the excretion of urea and uric acid. In the cases observed the increase of the former was about a fourth, and of the latter double the average normal excretion. Albumen was present in all cases except two; the quantity was never excessive. Owing to the intense alkaline reaction of the urine, which so soon developes after its emission in these cases, its presence is often masked till the urine has been neutralised by the careful addition of dilute acetic acid. Blood was present in one case,[2] and bile pigment was also found in two.[3] The inorganic constituents were diminished in quantity. This was notably the case with the earthy phosphates. The phosphoric acid in combination with the earthy bases in a case of ulcerative endocarditis being 0·362 grm. compared with 1·74 grm. of phosphoric acid combined with the alkaline oxides. In a case of acute necrosis it was 0·381 grm. compared with 3·6 grm., and in a case of pyæmia following castration 0·12 grm. as compared with 1·25 grm. Chlorine was also formed in lessened quantities, the highest amount observed being 2·4 grm. It has been thought probable that owing to the destruction or diminution of the red blood-corpuscles an increase of potash salts would be found in the urine; two estimations in typical cases were made to ascertain this point. In both the potash followed the example of the other inorganic constituent, and was

[1] It should be stated that no rapidly fatal case came under observation.

[2] Appendix II, Table III, Case 16; also Appendix IV, Case 20.

[3] Appendix II, Table X, Case 1. The second case is not included in the tables as the patient recovered; it was one of septicæmia at the Seamen's Hospital.

found below the normal average excretion, the amounts respectively being 1·6 grm. and 1·1 grm. In this respect there is an analogy between pyæmia and scurvy, for in both there is a diminution in the number of red blood-corpuscles and a diminished excretion of potash in the urine. In scurvy it is probable that the potash is retained in the blood to maintain the alkalinity of the blood lessened by the withdrawal of the alkaline carbonates of the food;[1] whilst in pyæmia the increase in the number of white corpuscles may account for its not being present in greater quantity in the urine after the destruction of the red corpuscles. Moreover, it will be of interest for future inquiry to note if the reduction of the earthy phosphates occur constantly in this class of disease, and also to inquire if the general reduction of the inorganic constituents of the urine was due to lessened ingestion in food or drink, or to a retention in the system of these substances owing to a change in the chemical composition of the tissues and the furnishing the requisite material for the growth and nutrition of organisms within the body.

---

# PART IV.

## MICROSCOPIC EXAMINATION OF ORGANS.

(41.) The microscopic examinations were conducted as follows: —Of cases alleged to have died from pyæmia portions of brain, spinal cord, thyroid gland, heart and large vessels, lungs, liver, spleen, intestine, suprarenal capsule, kidney, bladder, prostate, testicle, lymphatic glands, blood-clot from heart and veins, the tissues of the wound and adjacent fleshy parts, periosteum and the vessels leading from the wound, also, in other cases, locally inflamed parts not due to operation, but apparently the source of infection, muscles in parts distant from the primary lesion, the skin and subcutaneous tissue, were placed as soon after death as possible in a preservative fluid composed of two parts of one sixth per cent. chromic acid and one part of methylated spirit. In all cases parts were taken which seemed to the naked eye

[1] 'Inquiry into the General Pathology of Scurvy.' Chas. H. Ralfe, M.D., 1877. Lewis: London.

normal, as well as parts which were evidently diseased. The fluid was changed at intervals of about three days, and, after about three weeks, replaced by methylated spirit, in which the specimens were kept until ready for section. The sections, for the most part, were stained with hæmatoxylin, and mounted, after the usual treatment with alcohol and oil of cloves, in a solution of Canada balsam, in turpentine and chloroform—others in glycerine. Koch's[1] method of treating the section was employed in a few of the cases examined. The results may be classified as follows:

(42.) 1st. *Micrococci.*—In a large number of cases these organisms were found in all or some of the following parts: thyroid gland, heart, lung, liver, kidney, suprarenal capsule, spleen, lymphatic glands, and blood-clot. They were nearly always in blood-vessels, and chiefly in capillaries. They occur as dense aggregations of very minute spherical bodies, imbedded in a homogeneous substance which takes a deep violet stain with hæmatoxylin, very similar to that taken by albuminous casts in uriniferous tubules. In capillaries these masses completely plug the vessel, and frequently present irregular bulgings, producing a varicose condition of the containing vessel. In some instances the vessel appears to have been ruptured or partly absorbed, so that the micrococci extend for some little distance over the contiguous tissues. It is noteworthy that while sections in which these organisms are found in many parts show great pathological changes, sometimes the immediate surroundings of the micrococci present little, if any, alteration from the normal condition. In larger vessels the micrococci either form a layer of uniform thickness, adherent to the wall of the vessel, and often covered with coagulated blood, or present a somewhat papilliform appearance, projecting into the lumen of the vessel, with a rounded extremity surrounded with blood-corpuscles, and connected with the wall of the vessel by a narrow pedicle. Occasionally they are met with quite detached from the wall of the vessel, and completely surrounded with coagulated blood. Their distribution is most unequal. In some cases every section of the kidneys contains one

[1] Koch's method consists in staining the sections deeply with methylaniline violet, soaking in dilute acetic acid, washing in solution of carbonate of soda, and subsequently mounting by means of alcohol, oil of cloves, and Canada balsam in the usual way. It was found, however, that equally good or even better results were obtained by soaking in acetic acid, washing thoroughly but rapidly in distilled water.

or more groups of micrococci, while none can be discovered in the heart. In other cases, many can be found in the heart, while they are so sparsely present in the kidney as only to be discovered in very small quantities after repeated and careful examination. Similar variations may be observed in other viscera. It is, of course, possible that some other part of a viscus than that taken for examination may have contained micrococci. It seems, however, more probable that some precedent change in the chemical composition of the tissues may be necessary for the growth and multiplication of these organisms, and that thus they may be rather evidences than causes of pyæmia. Germs having got into the system—in traumatic cases by the wound, in non-traumatic cases in some other way—might circulate with the blood, and perish from inanition unless they found, as the result of some change in the tissues, a suitable nidus for propagation. This suggestion would harmonise with their unequal distribution, and their absence from more extensively diseased parts.

(43.) 2nd. *Bacteria* were found in three cases. In one case,[1] in a glomerulus of the kidney, one vessel was distended to about four times the normal size, and filled with rod-like bodies, which also protruded through a rupture in the vessel, and formed an irregular mass in the space between the glomerulus and the Malpighian capsule. In this case no other bacteria were found in sections from other parts of the kidney or of other viscera, although these showed considerable pathological changes. It must be stated, however, that the epithelium of the kidney was much decomposed, so that the bacteria may have been of *post-mortem* origin. In the second case,[2] rod-shaped bacteria were found in a case[3] of acute infective myositis, and that only in the heart in any quantity. When examined with the naked eye, only one or two minute subpericardial ecchymoses were seen. There was no pericarditis. The muscular tissue of the wall of the left ventricle at its upper part was of pale yellowish-white colour, with scattered ecchymoses, and a somewhat mottled appearance; the surface of the section somewhat granular in parts, but no suppuration was visible. No endocarditis was observed. The appearance was similar to that seen in acute myocarditis. On microscopic examination of the affected parts, there were found to be areas extensively infiltrated with bacteria, especially within

[1] Appendix IV, Case 28.
[2] Appendix IV, Case 2.

and around the vessels (Plate I, figs. 2 and 3). In some of the smaller arterioles colonies or zooglœa masses were found, whilst the perivascular spaces around some of the larger arterioles were crowded with bacteria. They extended also, in some places, between the muscular bundles, but hardly any were seen within the sarcolemma. The muscles in the most infiltrated parts were degenerated in such a way as to become very deeply stained with methyl violet, the striæ less distinct, and the muscle appeared as if undergoing a sort of liquefaction, but there was no sign of granular disintegration. This condition of the muscle was seen only in some parts, especially where the bacterial infiltration was most advanced; and in some other parts, where fewer bacteria were present, the muscular fibre appeared quite healthy. The remainder of the muscular tissue appeared absolutely healthy. These bacteria differed in no important respect from ordinary bacterium termo. The majority of them were rods of lengths varying from 1·5 $\mu$ to 3 $\mu$; some isolated, others joined in pairs, end to end. A few formed more elongated filaments, with or without traces of division; and in some of these spores were visible with high powers. It must be added that micrococci were also seen in the heart, one or two zooglœa masses only being found. It has been suggested that these bacteria were merely the result of *post-mortem* decomposition. But this seems improbable, for these reasons:—They were not found in any of the other organs similarly examined, even in the muscular abscesses in the arm. There was no evidence of decomposition of the heart elsewhere, either as seen with the naked eye or the microscope, and in the organs which appeared more decomposed bacteria were not found. Moreover, there were ecchymoses scattered through the part.[1] The change may therefore be regarded as occurring during life, but whether under the influence of the bacteria must be doubtful. Notes of the third case in which bacteria were found are recorded in Appendix IV, Case 30.

(44.) 3. *Changes in blood-vessels.*—In almost all the tissues the

[1] Rindfleisch has described a similar change in the heart, which, he says, is met with in pyæmic, puerperal, and glandrous infections. The "vibrios" are at first crowded together between the muscular bundles and later penetrate into their interior, and the muscular fibres become dissolved. He states also that they never lead to actual suppuration owing to the rapidly fatal issue of the disease in which they occur ('Handbuch der Pathol. Geweb.,' 2nd edition, section 245.

endothelium of blood-vessels has been found detached to a greater or less extent from the walls of the vessels. In some cases this detachment had taken place *en masse*, so that the collapsed tube of endothelium lay in the lumen of the vessel. In other cases the separate endothelial cells were found intermixed with blood-corpuscles in such a manner as to show that the detachment had occurred while the circulation still existed. Frequently the deeper layers of the intima were much hypertrophied, and this change involved in some cases the entire circumference of the vessel equally, in other cases irregularly. This hypertrophy produced corresponding diminution of the lumen of the vessels in varying degrees, even to complete obliteration (Plate III, figs. 2 and 3). Again, this hypertrophy was sometimes followed by degeneration so that the intima appeared as a thick homogeneous layer which stained violet with hæmatoxylin. This change was especially noticeable in the glomeruli of the kidney, in the description of which organ reference will be again made to them. In other cases, the external coat of the vessels was hypertrophied, and this again was frequently degenerated like the intima, the fibres being swollen and homogeneous in appearance, and staining similarly with hæmatoxylin. The hypertrophy sometimes encroached on the other parts of the vessel, sometimes on the surrounding tissues, or on both, so that masses of degenerated fibrous tissue would remain with either no indication of their vascular origin or only a narrow cleft lined with endothelium (Plate VI, fig. 2) to mark the track of the vessel.

In the *venules* no change like the obliterative endo-arteritis was seen. Thrombi were very common. Inflammatory processes, resulting in ulceration of the vein wall, were also seen in some parts. The veins which contained softening thrombi did not give at all satisfactory results, owing to the softness and ready separation of the contents during the process of preparation. A certain number of sections of the femoral and of the portal veins in cases of suppurative phlebitis were, however, examined, both by Koch's method and with logwood, but nothing special observed. The walls of the vein were much thickened, the endothelium completely detached, and often also the inner coat was entirely destroyed, the vessel containing only a mass of altered blood, in which, in some cases micrococci were found. No special change in the walls of the veins were observed, except such as were associated with inflammation. Thrombosis of minute venules not connected with any visible

change in their walls or around them was observed in a large number of organs. It was found in the brain, lung, heart, liver, kidney, and skin. The thrombi were mainly composed of leucocytes with fibrin, sometimes they occupied the entire channel, occasionally only a part leaving a passage on one side. These thrombi, as a rule, appeared to be recent, but in some parts they seemed to be undergoing organisation. Connected with these thrombi must be mentioned minute abscesses which were found in various organs, and appeared to be dependent on this thrombosis. They varied in stage and size from the slight exudations around the vessels seen in the brain, and pin-point abscesses in several organs, to the minute pustules in the skin reaching two or three millim. in diameter. In some of these, when in an early stage the wall of the vein could still be distinguished in the centre of the abscess; in others it was completely destroyed, but the position of the vessel was indicated by the anatomical situation. The corresponding artery could be seen lying alongside the abscess (Plate IV, fig. 1), its walls often having undergone obliterative changes.

(45.) 4. *Connective tissue.*—This in all organs had undergone changes, in some parts merely an increase of nuclei, in others considerable hypertrophy, and in others miliary abscesses. In some places, especially in the fibrous layer of the corium, the periosteum and the fibrous coat of the vessels, there appeared a swollen condition of the fibrous bundles limited to comparatively small tracts; the affected parts stained very deeply, and had a granular appearance.

(46.) 5. *General changes* may be briefly summarised as consisting of granular and fatty degeneration of epithelium, excessive pigmentation of epithelium and nuclei, and congestion of blood-vessels with extravasations of blood.

(47.) *The liver.*—In this organ micrococci were frequently found, but not so frequently as in the kidney. They were mostly in capillaries but sometimes in larger vessels. In addition to changes such as have before been described in the vessels and connective tissue, it is to be observed that frequently single acini will have undergone excessive degeneration, while the surrounding acini present little if any change. Thus in a section an acinus would be seen with the hepatic cells shrivelled and granular and the sustentacular structure swollen, while the surrounding acini presented no other change than perhaps some swelling of the hepatic cells and an increased quantity of pigment. Such a condition is possibly of

embolic origin. Again, hepatic cells are often to be found with their substance almost entirely replaced by fat, and this change may either have involved all the cells of an acinus or cells in different acini. In the latter case, the section, after treatment with alcohol and oil of cloves, appears as if riddled with holes, which, on examination, prove to be hepatic cells with their protoplasm forced to the periphery, and the fat which had filled the cell dissolved out. Sometimes plumose crystals of tyrosin were seen in veins. In only three out of thirty livers examined were abscesses visible with the naked eye; a part of the wall of one of these abscesses contained micrococcus clumps, these were cultivated in aqueous humour at a temperature of 36° C., and produced in two generations only micrococci. Nothing else of a special nature was seen in these abscesses.

In all the livers examined some exudation in the portal spaces was discovered; in one case of acute septicæmia it reached an extreme degree. In this case there was also a very remarkable condition of the hepatic cells, their protoplasm appeared to have undergone a sort of fragmentation, and had a glassy look, but the cells had not become broken down (Plate V, figs. 1 to 4). In the other cases there was only some slight swelling of the liver cells here and there. Fatty degeneration, seen in some cases, from the state of the other organs, was judged to be due to antecedent conditions. Thrombi were found in small vessels here and there, just as in the kidney. In some cases the intra-lobular vein was also compressed, with thickened connective tissue.

(48.) *Kidney.*—This organ was more generally affected than any other in the cases examined. Micrococci were almost always found, but, as before stated, in very unequal quantities. The capillaries surrounding the straight tubules in the upper part of the Malpighian pyramids appear to be a favourite position for them; but they are also to be met with in those of the cortical substance, and sometimes in some of the vessels of a glomerulus. In addition to the changes in blood-vessels before described the glomeruli are often greatly altered. In some an increase of nuclei is chiefly noticeable, and this often reached such a degree as to obscure the capillaries, and in two cases there was also extensive exudation in the surrounding tissues similar to that seen in scarlatinal nephritis. In others the walls of the component vessels were much thickened and stained deeply with hæmatoxylin. In others this

thickening has resulted in complete obliteration of the lumen of the vessels, and this change may either be limited to a part of the glomerulus or involve it all uniformly. A glomerulus thus changed appears to be welded into a homogeneous mass which in later stages of degeneration is much shrunken and no longer colours with hæmatoxylin. Laminated fibrin is sometimes found between the glomerulus and the Malpighian capsule. A somewhat similar change was often observed in the afferent arterioles. Their walls appeared to be infiltrated, whether with leucocytes or by proliferation of their own cells could not always be determined; but in some cases the endothelium was swollen and projected into the lumen so as nearly to close it. In one case the space between the glomerulus and capsule was in many Malpighian bodies filled up with a granular exudation which did not appear to consist of or contain micrococci. Changes in the capsule and its endothelium were rarely observed; where they existed there was evidence that they were chronic, and therefore independent of the disease under consideration. A marked change, seen in all cases, consisted in swelling of the epithelium of the convoluted tubes, with various degrees of degeneration. In some this was only moderate, the outline of the swollen epithelial cells being still distinctly visible. In others the tubes were filled with degenerated epithelium or a granular mass, which in one or two was of fibrinous appearance. The most extreme degree of change was seen in a case of acute septicæmia. In this the epithelium was swollen so as completely to close the tubule, the cells appeared to have undergone a fragmentation of their protoplasm, especially where in contact with the basement membrane (Plate IV, fig. 2), whilst the more superficial parts were fused together into a granular mass which occupied the centre of the tubules. Thrombi were occasionally found in the veins, especially in the venulæ rectæ near the base of the pyramids. In some cases the basement membrane of the uriniferous tubules has undergone a change similar to that described in the intima of blood-vessels. In the collecting tubes the basement membrane sends in processes between the epithelial cells, which are to be most distinctly seen where the loosened epithelium has fallen out (Plate IX, fig. 2). When this has occurred the wall of the tube, seen in profile, presents a crenated margin towards the lumen of the tube; but when the section has exposed the surface of a tube these processes appear as lines, passing completely across the tube, like the rungs of a ladder.

This arrangement has not, so far as we know, been hitherto described; but since our attention was accidentally directed to it we have observed it more or less distinctly in all the specimens examined. Normally these processes are colourless, like the membrane of which they are a part, but occasionally they are to be found much thickened and of a deep violet colour (Plate IX, figs. 3 and 4). Some of the collecting tubes are often plugged with masses composed of small spherical bodies, colourless in the centre and stained violet at the periphery. These dissolve without effervescence on addition of dilute hydrochloric acid. The remaining changes observed in the pyæmic kidneys may be summed up as follows:—1. Considerable engorgement of superficial blood-vessels. 2. Extravasations of blood into and between uriniferous tubules. 3. Fibrinous plugs in tubules. 4. Granular changes in, loosening and complete detachment of epithelium. 5. Abundant deposit (?) of yellow pigment in epithelium.

(49.) *Heart and pericardium.*—In two cases of ulcerative endocarditis micrococci were found in the substance of the valves and in the vegetations adherent thereto. In one case of pyæmia of traumatic origin the heart was found with numerous colonies of micrococci in the capillaries. The connective tissue showed greatly increased cell growth, and in many places miliary abscesses. The muscular fibres were in some parts quite normal. In others, the fibres presented transverse bands, with thick well-marked borders, suggesting an exaggerated form of the normal junction of cardiac muscle fibres. On closer examination these bands seemed to be the result of rupture of the more superficial part of the fibres. The pale band was thus formed by the unruptured portion of the fibre, and the well-defined borders by the retraction of the ruptured superficial part (Plate VIII, figs. 1 and 2). In other places this change was found in a later stage, the bands much broader, and the mode of origin more evident. In other parts again the fibres were found completely transformed into granular matter. The changes in the heart in one case have already been described (§ 43). In another case of acute necrosis, with commencing pericarditis, the changes observed were limited to the surface of the heart and the pericardium. The muscular fibres were separated by fibrinous exudation; thrombi, mainly composed of leucocytes, were found in the small vessels both of the heart and the subpericardial fat. Scattered through the more superficial layers of the pericardium, were

seen masses of micrococci, which preserved an intense staining after treatment with methylaniline and acetic acid. Some of these were distinctly in vessels, others did not appear to be surrounded by any vessel wall. Small clumps and layers of micrococci were also scattered near the surface (Plate II, fig. 2, and Plate III, fig. 1).

(50.) *Lungs.*—In the lung vessels were often found plugged with coagulum and extravasted blood in surrounding structures. Broncho pneumonia in varying stages was also of frequent occurrence. Micrococci were found either in capillaries surrounding an alveolus, or in large vessels in the subpleural tissue; sometimes they were found in groups outside blood-vessels, and one specimen showed very clearly the origin of this (Plate IX, fig. 1). A large vein gave off a small branch, which at one part had undergone partial absorption of its wall; through this micrococci had escaped, pushing the adventitious tissue before them, and grown in large masses in the spaces filled with extravasated blood. The pleural surface was, in many cases, much thickened, and this had either occurred uniformly, or else at certain points, which thus on section presented a papillary appearance. This latter was the result, probably, of distension of the pleural lymphatics.

(51.) *Lymphatic Glands.*—These, in some cases, contained micrococci in the blood-vessels. Many of the blood-vessels showed marked hypertrophy and swelling of the adventitia. In one gland were large numbers of giant cells, and Hassell's corpuscles, such as Lang found in glands in cases of lupus.

(52.) *Spleen, thyroid glands, suprarenal capsules.*—Plugs of micrococci were found in the spleen in some of the cases (Plate I, fig. 5). In others considerable changes had occurred in the blood-vessels similar to those noticed in other viscera to which reference has already been made. Micrococci were also found in the thyroid gland and suprarenal capsules. In nearly all cases where they were examined there was considerably increased cell growth in the connective tissue. In one case the thyroid was full of minute abscesses.

(53.) *Brain and spinal cord.*—The noticeable features were the presence in large quantities of so-called amyloid bodies, and in one case minute abscesses were found scattered through the cortical substance of the brain.

(54.) *Skin.*—In two cases the skin presented scattered minute abscesses and pustules; some of which were deep, others superficial,

They varied from 1 to 3 or 4 millimètres in diameter. The arterioles showed in a very marked degree the proliferation of the inner coat (see Plate III, fig. 3). The abscesses contained broken-down pus, with many ovoid or rounded bodies measuring 2 or 3 $\mu$ in diameter (Plate IV, fig. 1), staining deeply with reagents; and also micrococci, in links or chains, but no zooglœa masses were observed.

(55.) *Muscles* (other than the heart).—The muscular tissue showed no special changes in parts where no inflammatory or suppurative lesions existed. Abscesses of sizes varying from that of pin-head upwards, and tracts of scattered inflammation in their vicinity were examined. In the latter, exudation, mainly consisting of fibrinous material, was found separating the muscular bundles; leucocytes and granules were also present in varying quantity. In other parts the muscular fibres were separated by masses of leucocytes, as in ordinary suppurative inflammation. Small hæmorrhages were also not infrequent (Plate II, fig. 1).

Micrococci were found in the vessels as in other parts, but only in very small numbers. In the exudations were often seen isolated pairs of micrococci, but no rod bacteria. Zooglœa masses were found in one case in the inflamed muscle (Plate I, fig. 6).

The muscular fibres in the affected tracts were found in various stages of degeneration, such as are usually seen in myositis; the striation being first lost, and the fibre being converted into a homogeneous mass in which clear spaces occurred, followed by a gradual breaking down of the muscular tissue. The peculiar transverse markings similar to those observed in the muscular tissue of the heart were also seen in some places; the change appeared due to a rupture of the degenerated fibre within the sarcolemma.

MARCUS BECK.
W. S. GREENFIELD.
JEREMIAH MCCARTHY.
CHARLES HENRY RALFE, *Secretary.*

## DESCRIPTION OF PLATE I.

Plates I—V illustrate Dr. Greenfield's observations in the Report on Pyæmia. From drawings by himself and Mr. F. T. Blight.

FIG. 1. Forms of bacteria found in the blood during life. Drawn to scale, with the same magnifying power.

*a*. Extremely minute jointed filaments.

*b*. Rod-shaped moving bacteria.

*c*. Ovoid spore-like bodies.

*d*. Clusters of similar ovoid bodies.

*e*. Micrococci.

FIG. 2. Section of heart of case of myositis (Appendix iv, Case 2) after staining with methylaniline and treatment with acetic acid. About 300 diam.

*a*. Muscular fibres.

*b*. Intermuscular connective tissue distended with exudation containing bacteria (only the bacteria are seen, the tissues being rendered transparent by the acetic acid).

FIG. 3. Arteriole in the heart from same case. Under the same magnifying power.

*m*. Muscular coat.

*i*. Intima. Swollen probably by action of reagents.

*b*. Colony of bacteria in vessel.

FIG. 4. Capillary venule in the tissues beneath an operation wound containing masses of micrococci. (The surrounding tissues are not represented.)

*a*, *a'*, *a''*. Masses of micrococci deeply stained with methylaniline violet.

*a*. Masses more or less loose in channel.

*a'*. Masses closely adherent to the wall.

*a''*. Mass mingled with blood-corpuscles. Magnified about 200 diam.

FIG. 5. Micrococci in spleen.

*a*. Mass of micrococci deeply stained.

FIG. 6. Mass of micrococci in inflamed muscle (see also in Plate II, fig. 1).

*a*. Fibrinous exudation containing leucocytes.

*b*. Mass of micrococci deeply stained. 350 diam.




Fig 1.

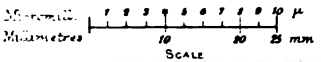


Fig. 2.

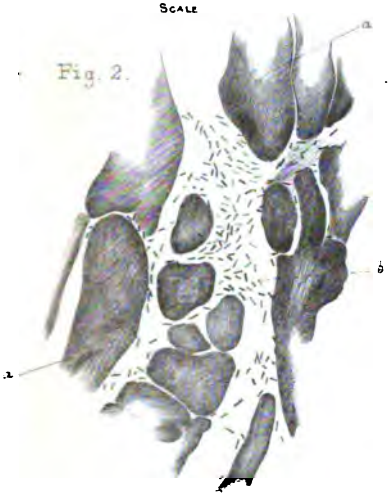


Fig. 3.

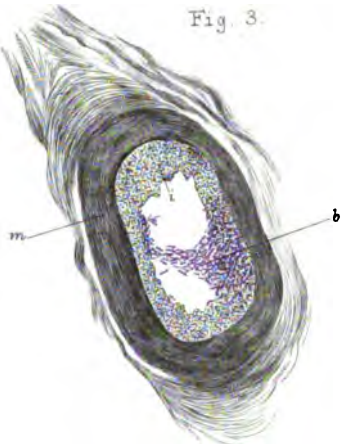


Fig. 4.

Fig. 5.

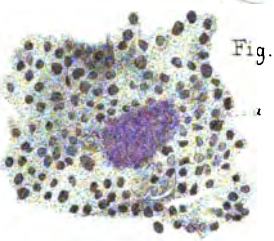


Fig. 6.

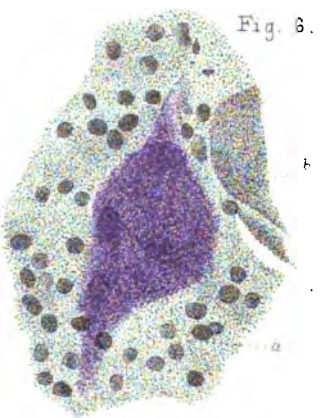


F. Bhohr & W. S. G. ad nat. del.

E. Noble Smith exc. ad lit.

## DESCRIPTION OF PLATE II.

FIG. 1. Inflamed muscle from forearm in myositis. 80 diam.

*a*. Muscular fibres.

*b*. Fibrinous exudation separating muscular fibres.

*c*. Exudation consisting in great measure of leucocytes.

*d*. Mass of micrococci (more highly magnified in Plate I, fig 6).

FIG. 2. Fibrinous exudation in pericarditis, containing micrococci (treated with acetic acid). 180 diam.

*a a*. Layer of fibrinous exudation on surface, containing masses of micrococci (*m*).

*b b*. Superficial layers of pericardium, containing masses of micrococci, some in vessels (*m'*).

*m m'*. Masses of micrococci deeply stained.

Fig. 1.

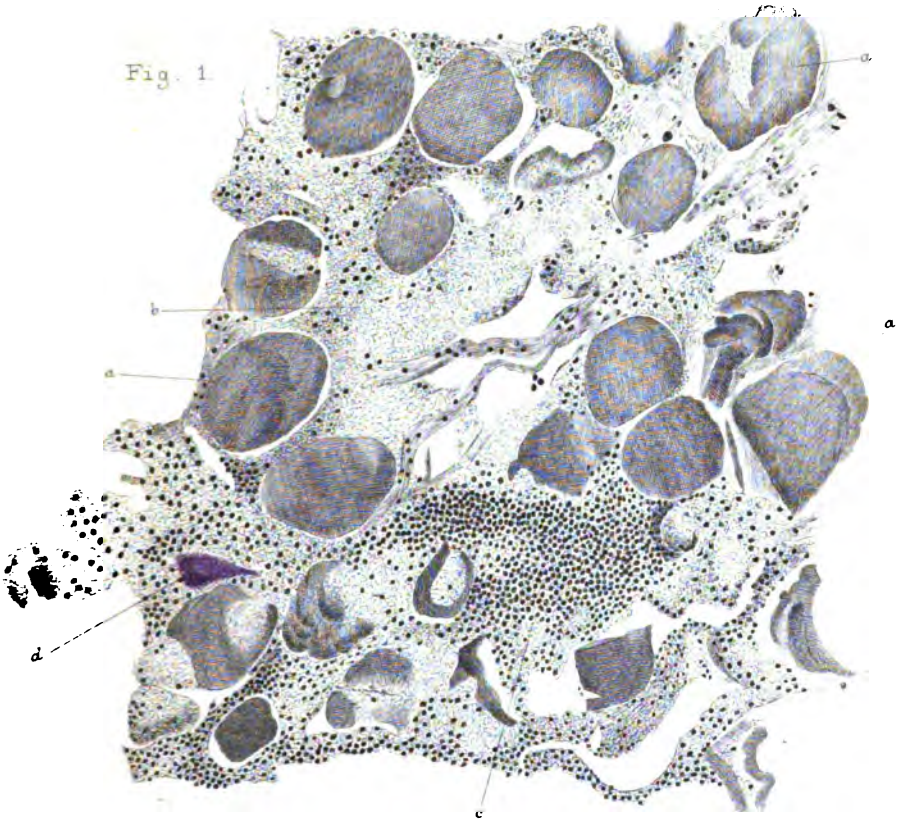


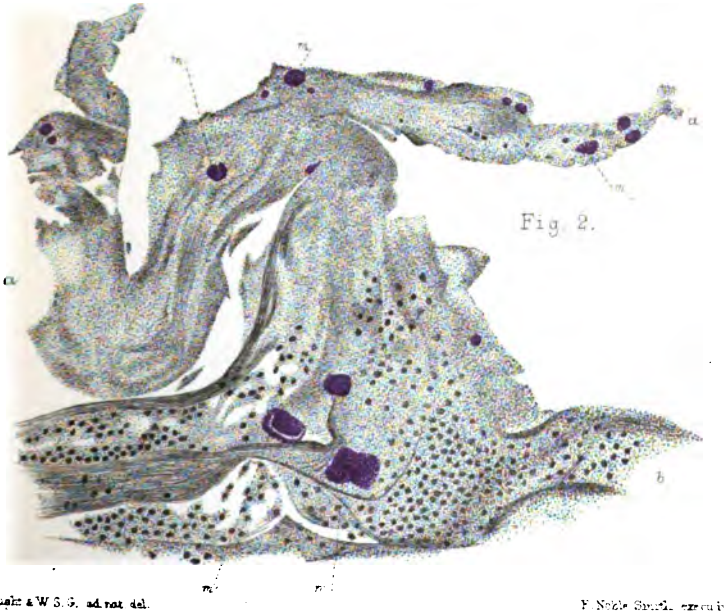


Fig. 2.

F. J. Black & W. S. G. ad nat. del.

F. Noble Smith, sculp.

## DESCRIPTION OF PLATE III.

FIG. 1.—Micrococci in pericarditis (from same case as Pl. II, fig. 2, but under lower power). Treated with acetic acid after staining. 45 diam.

*a a.* Swollen superficial layers of pericardium.

*b b.* Masses of micrococci.

*c.* Venule containing commencing thrombus.

FIG. 2.—Arteriole in tissues beneath a wound, showing swelling of inner coat. 45 diam.

*a.* Outer coat.

*b.* Middle coat.

*c.* Inner coat, much swollen.

FIG. 3.—Arteriole in the skin adjacent to a minute abscess in a case of chronic pyæmia. 120 diam.

*a.* Outer coat.

*b.* Muscular coat.

*c.* Intima swollen considerably.

FIG. 4.—Plug of leucocytes in vein in lung.

*a.* Arteriole filled with blood.

*b.* Wall of vein.

*c.* Mass of leucocytes and fibrin.

Fig. 1




Fig. 2.

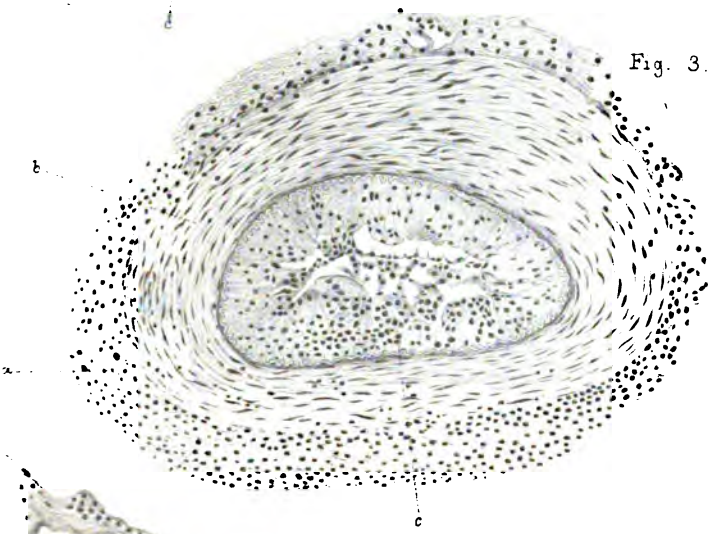


Fig. 3.




Fig. 4.

F. Bright & W. S. Gladstone del.

E. Noble Smith exc.

## DESCRIPTION OF PLATE IV.

FIG. 1. Part of an abscess in subcutaneous tissue in a case of chronic pyæmia. 60 diam.

*a.* Arteriole. *m.* Its muscular coat. *i.* Intima.

*v.* Venule, almost entirely destroyed.

*c.* Contents of abscess.

FIG. 2. Kidney in septicæmia. 200 diam.

*a.* Artery.

*g.* A Malpighian body.

*t t'.* Convoluted tubules, the epithelium of which is swollen, with a sort of vacuolation in the superficial part and fragmentation in some parts, *t'*.

Fig 1.

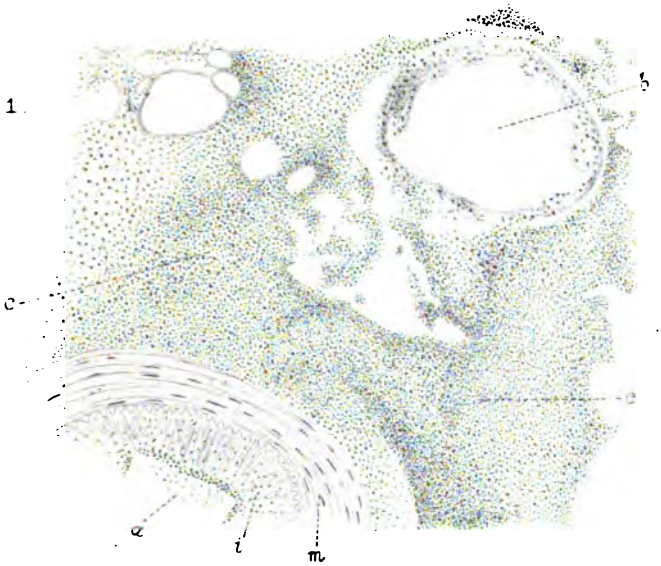


Fig. 2.

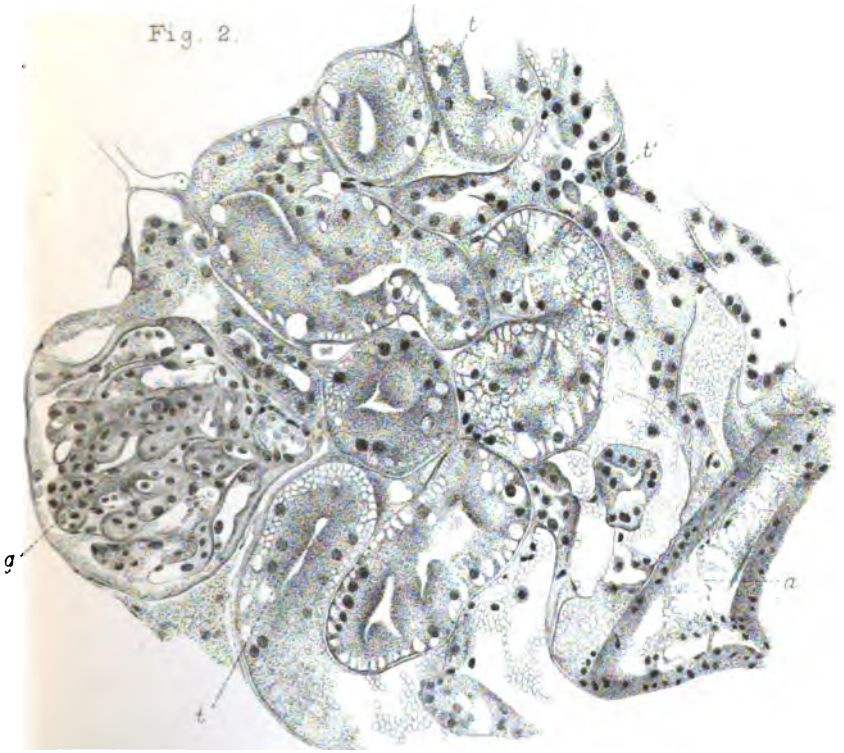


E. J. Elliott & W. Sowerby del.

E. Noble Smith exc. et lith.

## DESCRIPTION OF PLATE V.

FIG. 1. Liver in septicæmia (seen with low power). 25 diam.

*v c.* Central veins of lobules.

*p v.* Portal venule in portal space, with artery and bile-duct.

*i.* Interstitial exudation at periphery of lobules.

FIG. 2. Liver in septicæmia (same as fig. 1). Part of lobule near periphery, seen under a higher power. 350 diam. Hepatic cells swollen, fused together, and either segmented or breaking down.

FIG. 3. From the same, near centre of lobule. Hepatic cells swollen, nearly obliterating capillary network, each cell having an appearance of segmentation of the protoplasm, which in some is clear, in others cloudy, as in the normal condition. The network in the nuclei is also well seen.

FIG. 4. From the same; showing somewhat similar appearances.

FIG. 5. Minute abscess in the brain. 45 diam.

Fig. 1.

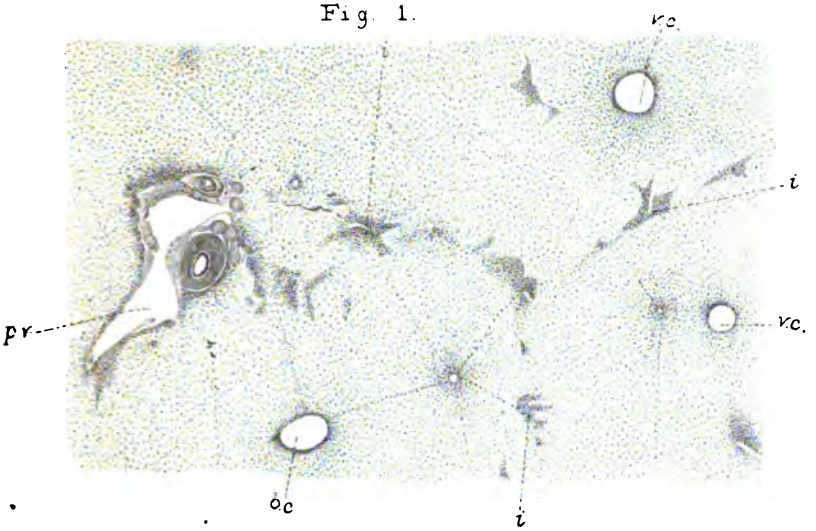


Fig 2.

Fig. 3.



Fig. 4

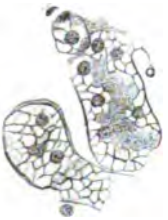

Fig. 5.



F. J. Hughes & W. S. Lockhart del.

E. Noble Smith lith.

## DESCRIPTION OF PLATE VI.

Plates VI—XI illustrate Mr. McCarthy's observations in the Report on Pyæmia, &c. From drawings by Mr. F. Treves.

FIG. 1. From Case 22, App. IV. Hartnack, ob. 7, oc. 3. Part of section of a lymphatic gland. The large vessel to the left contains a large mass of micrococci. The nuclei of the endothelial cells are swollen and granular; the lymph corpuscles round the vessel are cloudy and indistinct, from swelling of sustentacular tissue. The vessel to the right and lower part of field shows considerable hyaline changes in its walls.

FIG. 2. From same case. Hartnack, ob. 7, oc. 3. Section of a lymphatic gland, showing two groups of micrococci. That to the left completely fills a vessel and its branches; that to the right has a limiting wall only at the lower part, having elsewhere spread beyond the vessel into surrounding tissues. At the upper part the gland-substance has been replaced by a mass of fibrous tissue, with numerous clefts lined by endothelial cells. Many of the blood-vessels show great thickening of their walls, with hyaline and fibrous changes.

Fig. 1

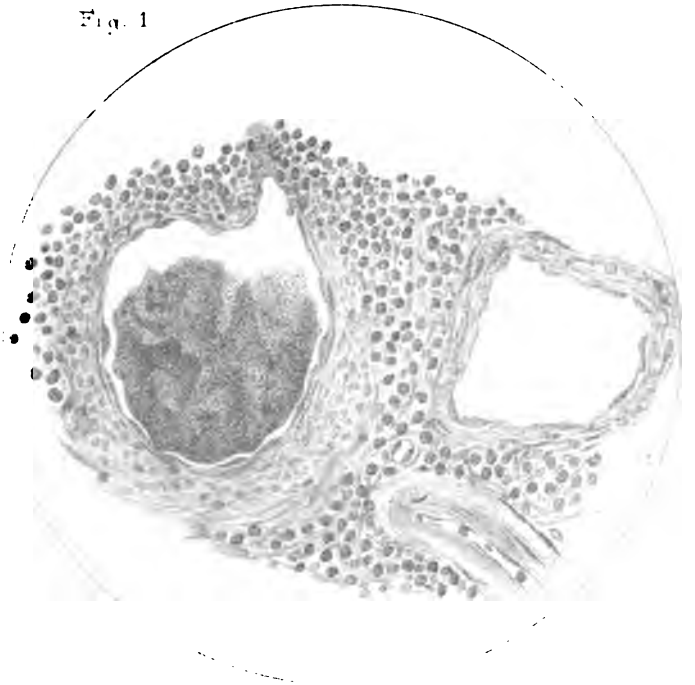

Fig. 2.

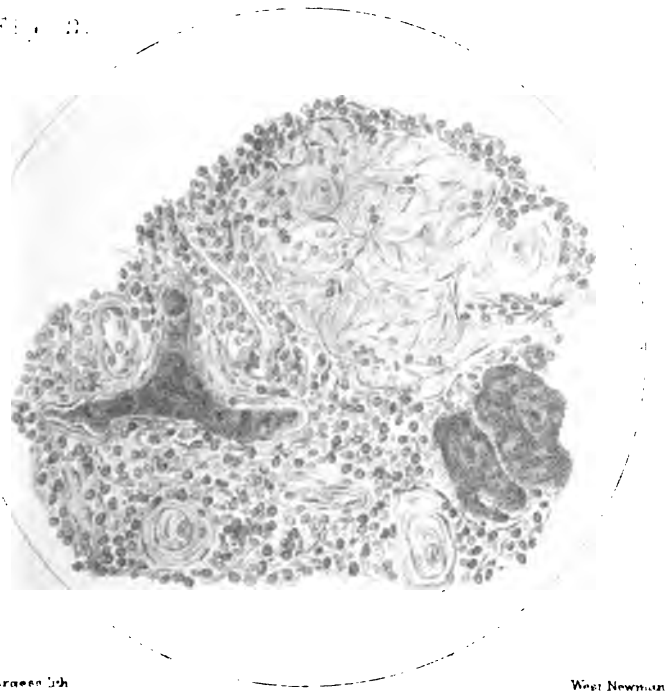

Drawn by F. Burgess lith

West Newman & Co imp

## DESCRIPTION OF PLATE VII.

FIG. 1. From Case 22, Appendix iv. Hartnack, ob. 7, oc. 3. Section of lymphatic gland, showing giant-cells, swelling of sustentacular tissue, thickening of walls of vessels, and at the lower part a blood-vessel filled with micrococci.

FIG. 2. From same case. Hartnack, ob. 7, oc. 3. Section of lymphatic gland, showing commencing changes in sustentacular tissue. Swelling, with hyaline change in walls of vessels, and two groups of micrococci at upper part of field.

FIG. 3. From Case 16, App. IV. Hartnack, ob. 7, oc. 3. A small renal artery plugged at point of bifurcation by an embolus, chiefly composed of fibrin.

Fig. 1

Fig. 2

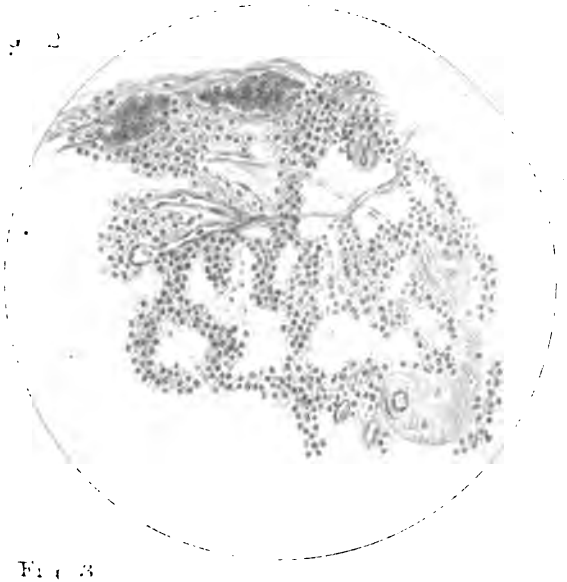

Fig. 3



F. Treves del. E. Burgess lith.

West Newman & Co. imp.

## DESCRIPTION OF PLATE VIII.

FIGS. 1, 2. From Case 21, App. IV. Hartnack, ob. 7, oc. 3. Sections of heart showing superficial rupture of muscle fibres. Fig. 1 represents a more advanced stage, and at the lower part the fibres are much disintegrated.

FIG. 3. From same case. Hartnack, ob. 7, oc. 3. Section of heart showing a vessel plugged with micrococci, which above have spread beyond the vessel over adjacent parts. The muscle fibres are quite normal.

FIG. 4. From Case 18, App. IV. Hartnack, ob. 9, oc. 3. A transverse section of a blood-vessel in the mitral valve, in which the lumen is considerably encroached upon by what is probably an irregular hypertrophy of, and change in, the *tunica intima*.

Fig. 1

Fig. 2

Fig. 3

Fig. 4

F. [illegible] del. E. Burgess lith.

[illegible]

## DESCRIPTION OF PLATE IX.

FIG. 1. From Case 15, App. IV. Hartnack, ob. 4, oc. 3. Section of kidney, showing a vessel and its branches plugged with micrococci and the surrounding structures infiltrated with pus corpuscles.

FIG. 2. From Case 20, App. IV. Hartnack, ob. 9, oc. 3. Section of kidney, showing relation of basement membrane of collecting renal tubules to epithelium. At the upper part is seen in profile the wall of a tubule from which the epithelium has completely disappeared, leaving the processes of the membrane which project between them distinctly visible. Below is a surface view of a similar tubule in which these processes pass completely across tubule. To the left are many stellate cells in the wall of the tubule.

FIG. 3. From Case 24, App. IV. Hartnack, ob. 8, oc. 3. Section of kidney, showing similar condition. The processes, however, are much swollen, fibrous, and stain deeply with hæmatoxylon.

FIG. 4. From Case 28, App. IV. Hartnack, ob. 8, oc. 3. Section of kidney, showing similar condition of the basement membrane in the cortical part. From two convoluted tubules the epithelium has disappeared, leaving visible these processes of basement membrane which are greatly swollen.

Fig 1

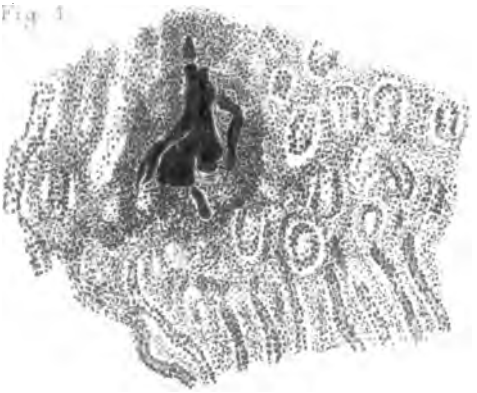

Fig 2

Fig 3

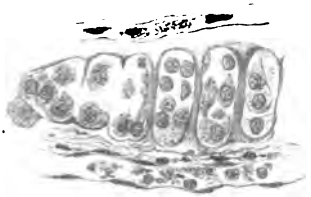

Fig 4

West Newman & Co. imp.

## DESCRIPTION OF PLATE X.

FIG. 1.—From Case 28, App. IV. Hartnack, ob. 9, oc. 3. Part of a Malpighian body, showing much swelling of the walls of the component vessels of glomerulus, one of which is plugged with Bacteria which have escaped through a rupture of the vessel, and spread in an irregular mass within the capsule.

FIG. 2.—From Case 20, App. IV. Hartnack, ob. 5, oc. 3. Section of kidney, showing great increase of nuclei in glomerulus and thickening of afferent vessel, with cloudy swelling of the epithelium of surrounding tubules to such an extent as to completely obliterate lumen of tubules.

FIG. 3.—From Case 20, App. IV. Hartnack, ob. 7, oc. 3. Section of liver, showing a vessel plugged with micrococci and fatty degeneration of the liver-cells.

FIG. 4.—From Case 16, App. IV. Hartnack, ob. 7, oc. 3. Section of liver, showing a vessel and its branches plugged with micrococci. The lymph spaces between the cells and blood-vessels are unusually distinct in some parts, otherwise the section appeared normal.

Fig. 1.

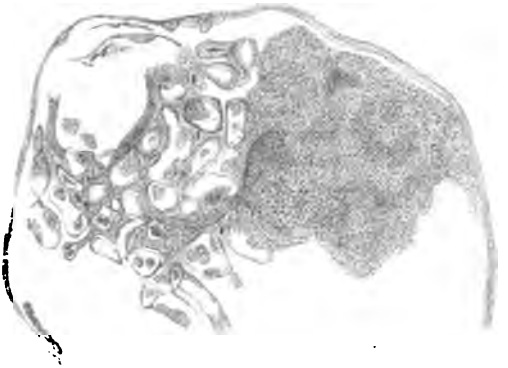

Fig. 2.

Fig. 3.

Fig. 4.

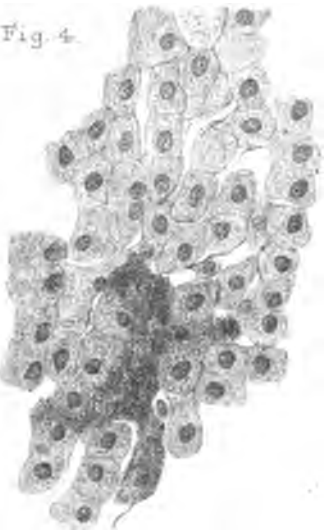

F. Greve del. F. Borge sc. lith.

West Newman & Co. imp.

## DESCRIPTION OF PLATE XI.

FIG. 1.—From Case 16, App. IV. Hartnack, ob. 7, oc. 3. Part of section of lung, showing a large vein from which a branch is given off to the left. Both vessels are filled with coagulated blood, and through a rupture in the wall of the smaller vein blood had become extravasated into surrounding structures. In this extravasated blood are numerous masses of micrococci.

FIG. 2.—From Case 19, App. IV. Hartnack, ob. 5, oc. 3. Section of kidney, showing complete obliteration of lumen of renal tubules from cloudy swelling of epithelium.

FIG. 3.—From Case 23, App. IV. Hartnack, ob. 8, oc. 3. Section of lung in neighbourhood of a patch of pneumonia, showing a small vessel of varicose appearance from irregular distension with micrococci.

Fig. 1

Fig. 2

Fig. 3

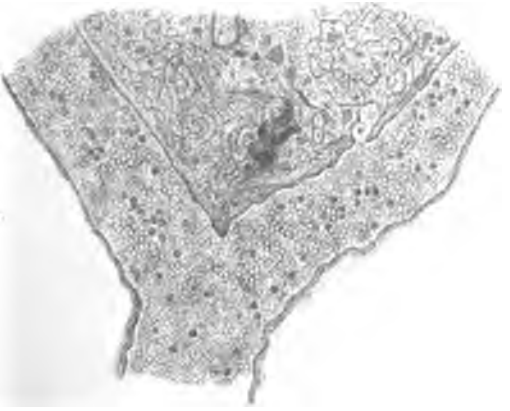

J. Crewes del. E. Burgess lith.

West, Newman & Co. imp.

# APPENDIX I.

## St. George's Hospital.—*Fatal Cases of Pyæmia*, 1869—78.*

*Total number of Cases.*

| | |
|---|---|
| Males ... ... ... ... ... ... ... ... | 64 |
| Females ... ... ... ... ... ... ... | 21 |
| | 85 |

| | 1869 | 1870 | 1871 | 1872 | 1873 | 1874† | 1875 | 1876 | 1877 | 1878 |
|---|---|---|---|---|---|---|---|---|---|---|
| Males ..... | 7 | 14 | 7 | 6 | 10 | 5 | 6 | 3 | 3 | 3 |
| Females ..... | 4 | 1 | 4 | 1 | 1 | 3 | 2 | 2 | 2 | 1 |
| | 11 | 15 | 11 | 7 | 11 | 8 | 8 | 5 | 5 | 4 |

| Year. | Jan. | | Feb. | | Mar. | | Apr. | | May. | | June. | | July. | | Aug. | | Sept. | | Oct. | | Nov. | | Dec. | |
|---|---|---|---|---|---|---|---|---|---|---|---|---|---|---|---|---|---|---|---|---|---|---|---|---|
| | M. | F. | M. | F. | M. | F. | M. | F. | M. | F. | M. | F. | M. | F. | M. | F. | M. | F. | M. | F. | M. | F. | M | F |
| 1869 ..... | 2 | ... | 2 | ... | ... | ... | 1 | ... | ... | ... | ... | ... | ... | ... | ... | 1 | ... | 1 | ... | 1 | 1 | 1 | 1 | ... |
| 1870 ..... | 1 | ... | 3 | 1 | 1 | ... | ... | ... | 2 | ... | 1 | ... | ... | ... | 2 | ... | 1 | ... | ... | ... | 2 | ... | 1 | ... |
| 1871 ..... | ... | ... | 1 | 1 | 1 | ... | ... | ... | 2 | ... | 1 | ... | 1 | 2 | ... | ... | ... | ... | ... | ... | ... | 1 | ... | ... |
| 1872 ..... | 1 | ... | ... | ... | 1 | ... | ... | ... | 1 | ... | 1 | ... | 2 | ... | ... | ... | ... | 1 | ... | ... | ... | ... | ... | ... |
| 1873 ..... | ... | 1 | 2 | ... | 1 | ... | 2 | ... | 1 | ... | ... | ... | 2 | ... | ... | ... | ... | ... | ... | ... | 1 | ... | 1 | ... |
| 1874 ..... | ... | 2 | ... | ... | 1 | ... | ... | ... | 2 | ... | † | † | † | † | † | † | ... | 1 | 1 | ... | ... | ... | 1 | ... |
| 1875 ..... | ... | ... | ... | ... | 1 | ... | 1 | ... | ... | ... | ... | ... | 1 | ... | 1 | 1 | ... | ... | ... | ... | 2 | ... | ... | 1 |
| 1876 ..... | 1 | ... | ... | ... | ... | ... | ... | ... | ... | 1 | ... | 1 | 2 | ... | ... | ... | ... | ... | ... | ... | ... | ... | ... | ... |
| 1877 ..... | ... | ... | 2 | ... | ... | 1 | ... | ... | ... | 1 | ... | ... | ... | ... | 1 | ... | ... | ... | ... | ... | ... | ... | ... | ... |
| 1878 ..... | ... | ... | ... | ... | ... | ... | ... | 1 | ... | ... | 1 | ... | 2 | ... | ... | ... | ... | ... | ... | ... | ... | ... | ... | ... |
| Total ..... | 8 | | 12 | | 7 | | 5 | | 10 | | 5 | | 12 | | 6 | | 4 | | 2 | | 8 | | 5 | |

* Compiled from the post-mortem book, St. George's Hospital. (C. H. R.)

† Hospital closed for repairs and alteration of system of drainage.

## *Details of the* 85 *Cases.*

| | Compound fractures or dislocations, lower extremity. | Compound fractures or dislocations, upper extremity. | Amputations of lower limb. | Amputations of upper limb. | Simple fractures of lower limb. | Simple fractures of upper limb. |
|---|---|---|---|---|---|---|
| Male ... | 9 | ... | 8 | 2 | ... | 1 |
| Female... | 1 | ... | 1 | ... | ... | ... |
| Total ... | 10 | ... | 9 | 2 | ... | 1 |

| | Joint disease of lower limb. | Lacerated wounds of upper extremity. | Abscess of upper segment. | Abscess of lower segment. | Caries of vertebræ, or psoas abscess. | Anthrax. |
|---|---|---|---|---|---|---|
| Male ... | 3 | 1 | 3 | 3 | 3 | ... |
| Female... | 2 | ... | 1 | ... | ... | 1 |
| Total ... | 5 | 1 | 4 | 3 | 3 | 1 |

| | Bone diseases, lower limb. | Bone diseases, upper limb. | Lacerated scalp. | Fractured skull with or without trephining. | Fractured ribs. | Osteo-myelitis. |
|---|---|---|---|---|---|---|
| Male ... | 2 | 1 | 1 | 3 | 1 | 1 |
| Female... | 3 | ... | 1 | 2 | ... | 1 |
| Total ... | 5 | 1 | 2 | 5 | 1 | 1 |

| | Amputation of breast. | Lithotrity. | Ulcers. | Ligature of arteries. | Removal of simple tumour. | Urethral. |
|---|---|---|---|---|---|---|
| Male ... | ... | 1 | 1 | 1 | 1 | 7 |
| Female... | 1 | ... | 1 | ... | 1 | ... |
| Total ... | 1 | 1 | 2 | 1 | 2 | 7 |

| | Piles, removal. | Excision of joint. | Various. | No cause. | Herniotomy. |
|---|---|---|---|---|---|
| Male ..... | 2 | 1 | 3 | 9 | 1 |
| Female..... | 1 | ... | ... | ... | ... |
| Total ..... | 3 | 1 | 3 | 9 | 1 |

*Number of Patients at each Age.*

Ages in years.

| | 1-10 | 10-20 | 20-30 | 30-40 | 40-50 | 50-60 | 60-70 | 70-80 | 80-90 | Not stated. | Totals. |
|---|---|---|---|---|---|---|---|---|---|---|---|
| Males ..... | 1 | 7 | 10 | 12 | 18 | 10 | 3 | ... | ... | 3 | 64 |
| Females ..... | 1 | 2 | 6 | 4 | 3 | 3 | 1 | ... | 1 | ... | 21 |
| Total ..... | 2 | 9 | 16 | 16 | 21 | 13 | 4 | ... | 1 | 3 | 85 |

In the 85 cases pyæmia followed—

| | | |
|---|---|---|
| Operation in ... ... ... ... ... ... | 21 | cases. |
| Injury " ... ... ... ... ... ... | 20 | " |
| Urethral " ... ... ... ... ... ... | 7 | " |
| Disease " ... ... ... ... ... ... | 28 | " |
| Uncertain " ... ... ... ... ... ... | 9 | " |

In 42 cases the average stay in hospital of patient before development of disease was ... ... 12 days.

In 48 cases the average duration of the disease from invasion to death was ... ... ... ... 12·1 "

*Relation between the Cases of Erysipelas and the Cases of Pyæmia.*

| | 1869 | 1870 | 1871 | 1872 | 1873 | 1874 | 1875 | 1876 | 1877 | 1878 |
|---|---|---|---|---|---|---|---|---|---|---|
| Pyæmia ..... | 11 | 15 | 11 | 7 | 11 | 8† | 8 | 5 | 5 | 4 |
| Erysipelas* ..... | 35 | 20 | 38 | 18 | 23 | 61† | 42 | 60 | 60 | ... |

* Cutaneous erysipelas, phlegmonous erysipelas, diffuse cellulitis.

† Hospital closed for three months from June.

*Tables of Deaths from Pyæmia and Septicæmia entered as such in the Death-book of* GUY'S HOSPITAL *in the years* 1869—1879.*

| | 1869 | 1870 | 1871 | 1872 | 1873 | 1874 | 1875 | 1876 | 1877 | 1878 | Total. |
|---|---|---|---|---|---|---|---|---|---|---|---|
| Primary amputation and compound fracture | 1 | 6 | 4 | 3 | 2 | 1 | 2 | 1 | 2 | 2 | 24 |
| Secondary amputation for disease | 2 | 2 | 3 | 2 | 4 | 3 | 5 | 2 | 4 | 2 | 29 |
| Urinary diseases | 2 | 5 | 3 | 4 | 5 | 4 | 5 | 4 | ... | 2 | 34 |
| Diseases of bone, including fractures (simple) ... | 2 | 1 | 5 | 3 | 5 | 9 | 2 | 4 | 9 | 1 | 41 |
| Diseases of joints, including excisions ..... | 1 | 2 | 2 | 1 | 5 | 3 | 4 | 2 | ... | 2 | 23 |
| Osteotomy..... | ... | ... | ... | ... | ... | ... | ... | 1 | ... | ... | 1 |
| Carbuncle ..... | 1 | ... | 1 | 2 | ... | ... | 2 | 1 | ... | ... | 7 |
| Hernia operations | 1 | ... | ... | ... | ... | ... | ... | ... | ... | ... | 1 |
| Ulcers ..... | 1 | ... | 1 | ... | ... | ... | ... | ... | ... | ... | 2 |
| Gangrene ..... | 3 | ... | ... | ... | ... | ... | 1 | ... | ... | 1 | 5 |
| No cause ..... | 2 | 1 | 1 | ... | ... | ... | ... | ... | ... | ... | 4 |
| Cellulitis ..... | 2 | 1 | ... | ... | ... | ... | 1 | 1 | ... | ... | 5 |
| †Erysipelas..... | ... | ... | ... | ... | 2 | ... | 3 | 1 | 1 | 1 | 8 |
| †Puerperal and uterine..... | 2 | 2 | 1 | 2 | 1 | 2 | 1 | 1 | 3 | ... | 15 |
| Wounds..... | 1 | 1 | 4 | 3 | 2 | 2 | 4 | 2 | 3 | ... | 22 |
| Ulcer of rectum... | ... | ... | ... | ... | ... | ... | 1 | 1 | ... | ... | 2 |
| " " pharynx | 1 | ... | ... | ... | ... | ... | ... | ... | ... | ... | 1 |
| " " colon ... | ... | 1 | ... | ... | ... | ... | ... | ... | ... | ... | 1 |
| " " duodenum | ... | ... | ... | ... | ... | ... | 1 | ... | ... | ... | 1 |
| †Scarlatinal dropsy | ... | 1 | ... | 1 | ... | ... | ... | ... | ... | ... | 2 |
| Idiopathic..... | 1 | 2 | ... | 1 | 2 | ... | 4 | 1 | ... | ... | 11 |
| Operation for epithelioma of face, &c. ..... | ... | ... | ... | ... | 1 | 3 | ... | ... | ... | ... | 4 |
| Operation for cancer of breast and other parts ..... | ... | ... | 1 | ... | ... | 1 | 1 | 2 | ... | 1 | 6 |
| Operation for nasal polypus ... | ... | ... | ... | ... | ... | ... | ... | 1 | ... | ... | 1 |
| Suppurating eyeball ..... | ... | ... | ... | ... | ... | 1 | ... | ... | ... | ... | 1 |
| Abscesses in various parts ..... | ... | ... | 1 | ... | ... | 1 | ... | 2 | 1 | ... | 5 |

* Compiled by Mr. G. A. Wright, Surgical Registrar.

| | 1869 | 1870 | 1871 | 1872 | 1873 | 1874 | 1875 | 1876 | 1877 | 1878 | Total. |
|---|---|---|---|---|---|---|---|---|---|---|---|
| †Heart disease ... | ... | ... | 1 | ... | ... | ... | 1 | ... | ... | ... | 2 |
| †Typhoid..... | ... | ... | ... | ... | ... | ... | ... | ... | ... | 1 | 1 |
| Exophthalmic goître ..... | ... | ... | ... | ... | ... | ... | ... | ... | 1 | ... | 1 |
| Ligature of arteries for aneurism | ... | ... | 1 | ... | ... | ... | ... | ... | 1 | ... | 2 |
| †Burn ..... | ... | ... | 1 | ... | 1 | ... | ... | ... | ... | ... | 2 |
| Thrombosis of portal vein ..... | ... | ... | ... | ... | ... | ... | 1 | ... | ... | ... | 1 |
| Excision of nævus | ... | ... | ... | ... | ... | ... | ... | ... | 1 | ... | 1 |
| †Paraplegia and renal disease ... | ... | ... | ... | ... | ... | ... | 2 | ... | ... | ... | 2 |
| Total ..... | 23 | 25 | 30 | 22 | 30 | 32 | 39 | 27 | 26 | 13 | 267 |

† These cases are not included in Tables II and V of Report.

---

## London Hospital.—*Fatal Cases of Pyæmia,* 1869—1878.

### *Total number of Cases.*

| | |
|---|---|
| Males ... ... ... ... ... ... ... | 149 |
| Females ... ... ... ... ... ... ... | 31 |
| | 180 |

### *Total number in each Year.*

| | 1869 | 1870 | 1871 | 1872 | 1873 | 1874 | 1875 | 1876 | 1877 | 1878 |
|---|---|---|---|---|---|---|---|---|---|---|
| Males ..... | 7 | 7 | 13 | 18 | 14 | 28 | 23 | 12 | 18 | 9 |
| Females ..... | 3 | ... | 4 | 4 | 5 | 1 | 4 | 4 | 3 | 3 |
| | 10 | 7 | 17 | 22 | 19 | 29 | 27 | 16 | 21 | 12 |

| Year. | Jan. | | Feb. | | Mar. | | Apr. | | May. | | June. | | July. | | Aug. | | Sept. | | Oct. | | Nov. | | Dec. | |
|---|---|---|---|---|---|---|---|---|---|---|---|---|---|---|---|---|---|---|---|---|---|---|---|---|
| | M. | F. | M. | F. | M. | F. | M. | F. | M. | F. | M. | F. | M. | F. | M. | F. | M. | F. | M. | F. | M. | F. | M. | F. |
| 1869 ..... | 1 | ... | 1 | ... | ... | ... | ... | ... | ... | 1 | 3 | 1 | 1 | ... | ... | ... | ... | 1 | ... | ... | 1 | ... | ... | ... |
| 1870 ..... | ... | ... | 4 | ... | ... | ... | 3 | ... | ... | ... | ... | ... | ... | ... | ... | ... | ... | ... | ... | ... | ... | ... | ... | ... |
| 1871 ..... | 3 | ... | 3 | 2 | ... | 1 | 1 | ... | ... | ... | 1 | ... | 3 | 1 | ... | ... | ... | ... | ... | ... | 2 | ... | ... | ... |
| 1872 ..... | ... | ... | ... | 1 | 3 | ... | 1 | ... | 3 | ... | 1 | 1 | 1 | 1 | 3 | 2 | ... | ... | 2 | ... | 1 | 1 | 1 | ... |
| 1873 ..... | 3 | ... | 1 | ... | 3 | 2 | 1 | 1 | 4 | 1 | ... | ... | ... | ... | ... | ... | ... | 1 | 1 | ... | 1 | ... | ... | ... |
| 1874 ..... | ... | ... | 6 | ... | 3 | ... | 1 | ... | 3 | ... | 1 | 1 | 3 | ... | 1 | ... | 3 | ... | 2 | ... | 2 | ... | 3 | .. |
| 1875 ..... | ... | ... | 4 | 1 | 3 | ... | ... | ... | 2 | ... | 4 | 1 | ... | ... | ... | 1 | 3 | ... | 3 | ... | 2 | 1 | 2 | ... |
| 1876 ..... | 2 | 2 | 2 | 1 | 1 | ... | ... | 1 | 2 | ... | ... | ... | ... | ... | 1 | ... | 1 | ... | 1 | ... | 2 | ... | ... | ... |
| 1877 ..... | 1 | ... | 1 | ... | 4 | ... | 2 | ... | 1 | ... | 2 | ... | 1 | ... | ... | ... | 2 | 1 | 3 | ... | 1 | 1 | ... | 1 |
| 1878 ..... | ... | ... | 1 | ... | 1 | ... | ... | ... | 1 | 2 | ... | ... | 1 | 1 | ... | ... | 2 | ... | 1 | ... | 1 | ... | ... | 1 |
| Total ... | 12 | | 28 | | 21 | | 11 | | 20 | | 16 | | 13 | | 8 | | 14 | | 13 | | 16 | | 8 | |

*Details of the* 180 *Cases.*

| | Compound fractures or dislocations of lower limb. | Compound fractures or dislocations of upper limb. | Amputations of lower limb. | Amputations of upper limb. | Simple fractures of lower limb. | Simple fractures of upper limb. | Erysipelas, no injury mentioned. |
|---|---|---|---|---|---|---|---|
| Male... | 16 | 7 | 23 | 8 | 5 | 1 | 7 |
| Female | ... | ... | 6 | 1 | ... | ... | ... |
| Total | 16 | 7 | 29 | 9 | 5 | 1 | 7 |

| | Joint disease, mostly suppurating, lower limb. | Joint disease, mostly suppurating, upper limb. | Wounds mostly lacerated, lower limb. | Wounds, mostly lacerated, upper limb. | Abscess, upper segment of body. | Abscess, lower segment of body. | Psoas abscess. |
|---|---|---|---|---|---|---|---|
| Male... | 10 | 3 | 7 | 5 | ... | 6 | 1 |
| Female | 3 | 1 | 2 | 1 | 2 | 1 | 1 |
| Total | 13 | 4 | 9 | 6 | 2 | 7 | 2 |

| | Bone disease, lower limb. | Bone disease, upper limb. | Lacerated scalp. | Trephining. | Fractured ribs. | Cancer. | Amputation of breast. |
|---|---|---|---|---|---|---|---|
| Male... | 9 | 4 | 3 | 1 | 2 | 2 | ... |
| Female | 3 | 1 | ... | ... | ... | 1 | 3 |
| Total | 12 | 5 | 3 | 1 | 2 | 3 | 3 |

| | Anthrax. | Wounds, &c., of perineum. | Lithotomy. | Ulcers. | Scald. | Gangrene. | Rupture of urethra. |
|---|---|---|---|---|---|---|---|
| Male... | 3 | 3 | 2 | 2 | 1 | 1 | 1 |
| Female | ... | 2 | ... | ... | ... | 1 | ... |
| Total | 3 | 5 | 2 | 2 | 1 | 2 | 1 |

| | Ulcer of rectum. | Ligature of piles. | Various. | No cause stated. |
|---|---|---|---|---|
| Male..... | 1 | 2 | 3 | 10 |
| Female..... | 1 | 1 | ... | ... |
| Total ..... | 2 | 3 | 3 | 10 |

## *Number of Patients at each Age.*

Ages in years.

| | 1–4 | 5–9 | 10–15 | 16–20 | 21–25 | 26–30 | 31–35 | 36–40 | 41–45 | 46–50 | 51–55 | 56–60 | 61–65 | 66–70 | 71–75 | 76–80 |
|---|---|---|---|---|---|---|---|---|---|---|---|---|---|---|---|---|
| Male ..... ... | 2 | 8 | 13 | 13 | 10 | 14 | 27 | 15 | 11 | 13 | 7 | 10 | 2 | 1 | 3 | ... |
| Female ..... | ... | 5 | 2 | 2 | 1 | 6 | 3 | 4 | 2 | 1 | 1 | 3 | ... | 1 | ... | 1 |
| Total ..... | 2 | 13 | 15 | 15 | 11 | 20 | 30 | 19 | 13 | 14 | 8 | 13 | 2 | 2 | 3 | 1 |

The youngest patients, 4 months; 1½ years. The oldest, 76 years.

## *Post-mortem Notes.*

| No. and Date. | | Sex and Age. | Nature of case. | Notes of autopsy. |
|---|---|---|---|---|
| 2353 | 1876 | M. 27 | Wound of thigh | Osteo-myelitis; clot in femoral vein; pneumonia; hæmorrhages in spleen and liver. |
| 68 | „ | M. 41 | Wound of knee | Pyæmic pneumonia; pus in bronchi. |
| 2354 | „ | M. 60 | Cellulitis of leg | Pus in pericardium; abscesses in heart. |
| 219 | „ | M. 1½ | Scald, abscess in axilla | Pyæmic pleurisy and pneumonia. |
| 743 | „ | M. 57 | Gangrene, erysipelas | Pleurisy; spleen very soft. |
| 713 | „ | M. 23 | Laceration of foot | Abscesses in heart, lungs, liver, and kidney; pleurisy. |
| 1189 | „ | M. 55 | Amputation through knee | Pneumonia; abscess in lungs; secondary abscesses in arm; nephritis. |
| 1853 | „ | M. 11 | Compound fracture of leg | Osteo-myelitis; pneumonia. |
| 2079 | „ | M. 45 | Erysipelas of leg | Thrombosis; pyæmia. |
| 1021 | „ | F. 15 | Acute periostitis of tibia | Pus in knee-joint; embolisms in lungs; pus in shoulder-joint; spleen large and soft; liver very soft. |
| 8 | „ | F. 38 | Amputation of right leg | Abscess in kidneys; infarcts in spleen and base of one lung; phlebitis. |
| 215 | „ | F. 43 | Cancer of breast, amputation | Pus in joints and lungs. |
| 19 | 1870 | M. 22 | Amputation of leg | Phlebitis; pleuritic effusion; abscesses in lungs; clot (adherent) in branch of pulmonary artery. |
| 22 | „ | M. 27 | Fracture of leg | Pus in ankle-joint and joints of finger; pleurisy; congested lungs. |
| 26 | „ | M. 11 | Periostitis of tibia | Pus in knee, ankle, and elbow; pericarditis; pleurisy; infarcts in kidney. |
| 39 | „ | M. 50 | Carbuncle of back | Infarcts in heart and base of lungs; congestion of kidneys. |
| 74 | „ | M. 23 | Suppuration of knee-joint | Abscesses in lungs and in joints of fingers and hand; other viscera free. |
| 79 | „ | M. 62 | Perineal section | Abscess in both lungs and one kidney; pleurisy; liver normal. |
| 6 | 1871 | M. 31 | Lacerated thigh | Abscesses in lungs; pleurisy; pericarditis; emboli in kidney and liver; spleen healthy. |
| 21 | „ | M. 27 | Compound fracture of leg | Infarcts on posterior aspect of heart; abscesses in liver. |
| 35 | „ | F. 16 | Disorganisation of shoulder-joint | Extravasation on pericardium; abscesses in lungs, spleen, and kidneys; disintegrated clot in iliac and femoral veins; pus in elbow-joint. |

| No. and Date. | | Sex and Age. | Nature of case. | Notes of autopsy. |
|---|---|---|---|---|
| 44, | 1871 | M. 19 | Amputation of arm | Abscesses in lungs; extravasations on anterior and posterior surfaces of heart. |
| 45 | " | M. 66 | Lithotomy | Pus in knee-joints, &c. |
| 72 | " | M. 12 | Disease of shoulder-joint | Pericarditis; pleurisy. |
| 107 | " | F. 58 | Abscess of hand | Lungs congested; sub-pleural hæmorrhages; infarcts in spleen; abscess of brain. |
| 115 | " | M. 31 | Compound fracture of humerus | Pyæmic deposits in lungs and pericarditis. |
| 128 | " | M. 57 | Ulcers of rectum | Pericarditis; pyæmic pneumonia; abscess in front of thyroid cartilage. |
| 167 | " | F. 22 | Abscess over knee | Pleurisy; abscesses in lungs; pyæmic deposits in spleen; local peritonitis. |
| 183 | 1872 | M. 54 | Fractured ribs | Pleurisy; infarcts and abscess in lungs; other viscera healthy. |
| 192 | " | M. 31 | Lacerated leg | Pleurisy; lobular pneumonia; abscesses. |
| 36 | 1874 | M. 32 | Amputation of leg | Ditto. |
| 40 | " | M. 39 | Compound fracture of leg | Abscesses in liver and lungs; jaundice. |
| 54 | " | M. 39 | Ditto | Deposits in spleen, but in no other organ. |
| 72 | " | M. 10 | Disease of ankle-joint | Abscesses in heart; in intercostal muscles; pericarditis. |
| 98 | " | M. 50 | Amputation for popliteal aneurism | Lobular pneumonia; pleurisy, congested kidneys. |
| 107 | " | M. 14 | Compound fracture of forearm | Multiple abscesses in lungs and liver. |
| 133 | " | M. 60 | Compound fracture of leg | Ditto. |
| 143 | " | M. 43 | Abscess in thigh | Pus in hip- and knee-joint; pleurisy; abscesses in liver, spleen, kidneys, and lungs. |
| 210 | " | M. 33 | Amputation of fore-arm | Pleurisy; abscesses in lungs and liver. |
| 42 | 1875 | M. 33 | Laceration of knee-joint suppuration | Pleurisy; abscesses in lungs and liver. |
| 45 | " | M. 33 | Severe laceration of hand, secondary amputation | Multiple abscess in lungs. |
| 75 | " | M. 5 | Acute disease of knee-joint | "Suppurative meningitis; pyæmic abscesses." |
| 155 | " | M. 7 | Trephining | Abscesses in liver. |
| 221 | " | M. 32 | Old ulcer of leg, erysipelas | Pleurisy; abscesses in lungs. |
| 269 | " | M. 18 | Suppuration of knee | Abscesses in lungs. |
| 512 | " | M. 13 | Acute periostitis of femur | Pus in sterno-clavicle and knee-joints. |
| 525 | " | M. 9 | Hip disease | Pneumonia and pyæmic abscesses. |

| No. and Date. | | Sex and Age. | Nature of case. | Notes of autopsy. |
|---|---|---|---|---|
| 596 | 1875 | M. 15 | Compound fracture of leg | Pus in right shoulder and left knee. |
| 718 | „ | M. 25 | Psoas abscess | Pus in hip; pyæmic pneumonia. |
| 878 | „ | M. 4 mos. | Fractured femur | Abscess in joints. |
| 897 | „ | M. 21 | Amputation of legs | |
| 1064 | „ | M. 17 | Disease of knee | Osteo-myelitis; abscesses in lungs. |
| 1434 | „ | M. 33 | Crush of hand | Pleurisy; abscesses in lungs and kidney. |
| 1618 | „ | M. 47 | Laceration of hand | Pus in joints. |
| 1693 | „ | M. 46 | Amputation at shoulder-joint | Abscess in knee-joint, &c. |
| 1718 | „ | M. 71 | Amputation of thigh | Abscesses in liver. |
| 1758 | „ | M. 33 | Erysipelas | Pus in joints, pleura, and lungs. |
| 1809 | „ | M. 38 | Fractures of ribs and sternum. | Abscesses in lungs; pleurisy. |
| 1992 | „ | M. 23 | Compound fracture of leg | Pus in elbow-joint. |
| 2140 | „ | M. 30 | Injury to knee | Osteo-myelitis; pleurisy, and abscesses in lungs. |
| 88 | „ | F. 26 | Suppuration of knee | |
| 261 | „ | F. 7 | Amputation of thigh | Osteo-myelitis; pus in pleura; lungs congested; pyæmic abscesses in one lung. |
| 639 | „ | F. 37 | Gangrène of forearm | Pus in joints; soft spleen. |
| 935 | „ | F. 7 | Acute periostitis of tibia | Pleurisy; pericarditis; abscess in heart, in kidney, and about uterus. |
| 223 | 1874 | M. 17 | Amputation of arm | Osteo-myelitis; effusion in pleura; lung partly collapsed, partly solidified (lobular pneumonia). |
| 259 | „ | M. 31 | Compound fracture into ankle-joint | Pleurisy; pus in wrist, ankle, and elbow-joints. |
| 16 | 1869 | M. 50 | Disease of elbow-joint | Pleurisy; lobular pneumonia. |
| 36 | „ | M. 44 | Lacerated scalp, osteitis of bone | Thrombosis of superior longitudinal sinus; deposits in lungs and liver; gall-bladder full of clear glairy fluid. |
| 77 | „ | M. 52 | Ligature for piles | Abscesses in lungs; fluid in knee-joint. |
| 91 | „ | F. 35 | Amputation of leg | Pus in wrist-joint; congested lungs; deposits in spleen. |
| 183 | „ | M. 35 | Disease of lower jaw | Pleuritic effusion; abscesses in lungs and kidney. |

Full details of each of the above cases can be obtained by quoting the number and date, and of any of the cases in the years 1873, 1877, 1878.

Compiled by Frederick Treves,
*Surgical Registrar London Hospital.*

*Analysis of Deaths from Pyæmia and Septicæmia occurring in* MIDDLESEX HOSPITAL *from* 1869—1878.*

| | | |
|---|---|---|
| Cases admitted | Males ... ... | 8 |
| | Females ... ... | 6 |
| Cases originating | Males ... ... | 34 |
| | Females ... ... | 10 |
| | Total ... ... | 58 |

*Table showing the relation between Cases originating in Hospital and those admitted Pyæmic, the number of Operations, and Cases of Erysipelas.*

| | 1869 | 1870 | 1871 | 1872 | 1873 | 1874 | 1875 | 1876 | 1877 | 1878 | Total. |
|---|---|---|---|---|---|---|---|---|---|---|---|
| Cases originating . | 4 | 5 | 10 | 5 | 7 | 5 | ...† | 2 | 5 | 1 | 44 |
| Cases admitted . . | ... | 1 | ... | 2 | 1 | 4 | 3 | 3 | ... | ... | 14 |
| Number of operations | 184 | 187 | 214 | 216 | 275 | 247 | 287 | 259 | ‡ | ‡ | ‡ |
| Erysipelas admitted . | 10 | 13 | 11 | 38 | 50 | 46 | 31 | 18 | ‡ | ‡ | ‡ |
| Erysipelas originating | 12 | 6 | 13 | 11 | 19 | 31 | 23 | 7 | ‡ | ‡ | ‡ |

*Ages of the* 58 *Cases.*

| Sex. | 1—10 | 10—20 | 20—30 | 30—40 | 40—50 | 50—60 | 60—70 | 70—80 | Total. |
|---|---|---|---|---|---|---|---|---|---|
| Males . | ... | 4 | 5 | 14 | 8 | 8 | 1 | 2 | 44 |
| Females . | 1 | ... | 3 | 1 | 4 | 2 | 5 | ... | 16 |
| Total . | 1 | 4 | 8 | 15 | 12 | 10 | 6 | 2 | 58 |

* From Annual Report of Registrars.—C. H. R.

† Only one case occurred, which recovered.

‡ Detailed report for years not yet published.

*Details of the 44 Cases occurring in Hospital.*

| | 1869 | 1870 | 1871 | 1872 | 1873 | 1874 | 1875 | 1876 | 1877 | 1878 | Total. | |
|---|---|---|---|---|---|---|---|---|---|---|---|---|
| Amputation of limbs | 1 | ... | ... | ... | 2 | ... | ... | ... | 1 | ... | 4 | Operations 10. |
| Amputation of breast | ... | ... | 1 | ... | ... | ... | ... | ... | ... | ... | 1 | |
| Removal of tumour | ... | ... | ... | ... | ... | ... | ... | ... | 1 | ... | 1 | |
| Excision of joints | 1 | ... | ... | ... | ... | ... | ... | ... | ... | ... | 1 | |
| Lithotomy | ... | ... | 2 | ... | ... | ... | ... | ... | ... | ... | 2 | |
| Trephining | 1 | ... | ... | ... | ... | ... | ... | ... | ... | ... | 1 | |
| Compound fractures | ... | 1 | ... | 1 | 1 | 1 | ... | ... | 1 | ... | 5 | Injuries 13. |
| Incised wounds | ... | ... | ... | ... | ... | 1 | ... | ... | ... | ... | 1 | |
| Punctured wounds | ... | ... | ... | ... | 1 | ... | ... | ... | ... | ... | 1 | |
| Lacerated wounds | ... | 2 | 1 | 1 | 1 | ... | ... | ... | ... | ... | 5 | |
| Ruptured vein | ... | ... | 1 | ... | ... | ... | ... | ... | ... | ... | 1 | |
| Urethral | ... | ... | ... | ... | ... | 1 | ... | ... | 1 | ... | 2 | |
| Disease of bones | ... | 1 | ... | ... | ... | ... | ... | ... | ... | ... | 1 | Diseases 19. |
| Disease of joint | ... | 1 | 3 | ... | ... | ... | ... | ... | ... | ... | 4 | |
| Abscess | ... | ... | ... | ... | 1 | 1 | ... | 2 | 1 | 1 | 6 | |
| Ulcer | ... | ... | 1 | ... | ... | ... | ... | ... | ... | ... | 1 | |
| Carbuncle | ... | ... | ... | 1 | ... | ... | ... | ... | ... | ... | 1 | |
| Gangrene | ... | ... | ... | ... | 1 | ... | ... | ... | ... | ... | 1 | |
| Bedsore | 1 | ... | ... | ... | ... | ... | ... | ... | ... | ... | 1 | |
| Piles | ... | ... | 1 | ... | ... | ... | ... | ... | ... | ... | 1 | |
| Cancer | ... | ... | ... | 2 | ... | 1 | ... | ... | ... | ... | 3 | |
| Total | 4 | 5 | 10 | 5 | 7 | 5 | ... | 2 | 5 | 1 | 44 | |

| | |
|---|---|
| After operations ... ... ... | 10 |
| „ injuries ... ... ... ... | 13 |
| „ diseases ... ... ... ... | 19 |
| „ urethral ... ... ... ... | 2 |
| | 44 |

## *Cases of Pyæmia and Septicæmia in* St. Thomas's Hospital, 1869—1878.*

Table I.

| | |
|---|---|
| Males ... ... ... ... ... ... ... | 58 |
| Females ... ... ... ... ... ... ... | 23 |
| Sex not stated ... ... ... ... ... ... | 44 |
| | 125 |

Table II.—*Relation between the number of Cases of Pyæmia and the Cases of Erysipelas in each year.*

| | 1869 | 1870 | 1871 | 1872 | 1873 | 1874 | 1875 | 1876 | 1877 | 1878 | Total. |
|---|---|---|---|---|---|---|---|---|---|---|---|
| Pyæmia admitted ... | 2 | 2 | ... | 2 | ... | ... | 1 | 1 | 2 | ... | 10 |
| Pyæmia originating | 2 | 2 | 7 | 17 | 16 | 13 | 15 | 11 | 20 | 12 | 115 |
| Erysipelas admitted | † | 1 | 1 | 37 | 60 | † | † | 25 | 29 | † | 153 |
| Erysipelas originating | 16 | 21 | 22 | 45 | 51 | 75 | 40 | 21 | 41 | † | 332 |

Table III.—*Age in* 117 *Cases.*

| 1—10 | 10—20 | 20—30 | 30—40 | 40—50 | 50—60 | 60—70 | Total. |
|---|---|---|---|---|---|---|---|
| 13 | 23 | 15 | 31 | 17 | 11 | 6 | 117 |

Table IV.—*Average duration of Disease in* 45 *Cases.*

| | Days. |
|---|---|
| From admission to invasion ... ... ... | 25·8 |
| From invasion to death ... ... ... ... | 6·2 |

* From 'Hospital Reports.'—C. H. R.

† Not stated.

## TABLE V.—*Details of the 124 Cases.*

| | 1869 | 1870 | 1871 | 1872 | 1873 | 1874 | 1875 | 1876 | 1877 | 1878 | Total. |
|---|---|---|---|---|---|---|---|---|---|---|---|
| Amputation of limbs | ... | ... | 2 | 1 | 3 | 4 | 4 | 5 | 7 | 1 | 27 |
| Amputation of breast | ... | ... | 1 | 1 | 1 | ... | ... | ... | ... | ... | 3 |
| Removal of tumours | ... | ... | ... | 1 | 1 | 1 | ... | ... | ... | ... | 3 |
| Herniotomy | 1 | ... | ... | 1 | ... | ... | ... | ... | ... | ... | 2 |
| Osteotomy | ... | ... | 1 | ... | ... | ... | ... | ... | 1 | ... | 2 |
| Excision of joint | ... | ... | ... | 5 | 4 | 1 | 1 | ... | 2 | 4 | 17 |
| Incision into joint | ... | ... | 1 | ... | ... | 1 | 1 | ... | ... | ... | 3 |
| Lithotomy | ... | ... | ... | ... | ... | ... | ... | 1 | ... | ... | 1 |
| Ligature | ... | ... | ... | 1 | 1 | ... | ... | ... | ... | ... | 2 |
| Tapping | ... | ... | ... | ... | ... | ... | 2 | ... | ... | ... | 2 |
| Incisions | ... | ... | ... | ... | ... | ... | 1 | ... | 1 | ... | 2 |
| Galvano Cautery | ... | ... | ... | ... | ... | ... | ... | ... | 1 | ... | 1 |
| Compound fractures and dislocations | ... | ... | 1 | 1 | 2 | 2 | 1 | 1 | 1 | ... | 9 |
| Simple fractures | ... | ... | ... | ... | ... | 1 | ... | ... | ... | ... | 1 |
| Lacerated wounds | ... | 1 | ... | ... | 1 | ... | ... | ... | 1 | ... | 3 |
| Contused wounds | ... | ... | ... | ... | 1 | ... | ... | ... | ... | ... | 1 |
| Urethral | 1 | ... | ... | 1 | ... | ... | 3 | ... | 2 | ... | 7 |
| Diseased bone | ... | ... | ... | ... | ... | 1 | ... | 1 | 1 | 2 | 5 |
| Diseased joints | ... | 1 | ... | 1 | ... | 1 | ... | ... | ... | 1 | 4 |
| Abscess | ... | ... | ... | 4 | ... | 1 | ... | 1 | 1 | 3 | 10 |
| Ulcer | ... | ... | ... | ... | ... | ... | ... | ... | 2 | ... | 2 |
| Fistula in ano | ... | ... | 1 | ... | ... | ... | ... | ... | ... | ... | 1 |
| Various | ... | ... | ... | ... | 2 | ... | 2 | 1 | ... | 1 | 6 |
| Admitted pyæmic | 2 | 2 | ... | 2 | ... | ... | 1 | 1 | 2 | ... | 10 |
| Total | 4 | 4 | 7 | 19 | 16 | 13 | 16 | 11 | 22 | 12 | 124 |

| | | | |
|---|---|---|---|
| Pyæmia following operation | ... | ... | ... | 65 |
| " " injuries ... | ... | ... | ... | 14 |
| " " urethral ... | ... | ... | ... | 7 |
| " " diseases ... | ... | ... | ... | 29 |
| " " admitted | ... | ... | ... | 10 |

## *Details of Fatal Cases of Pyæmia and Septicæmia originating in* University College Hospital, 1870—1878.*

### Table 1.

| | |
|---|---|
| Males ... ... ... ... ... | 57 |
| Females ... ... ... ... ... | 21 |
| Total ... ... | 78 |

### Table 2.

| Year. | Jan. | | Feb. | | Mar. | | Apr. | | May. | | June. | | July. | | Aug. | | Sept. | | Oct. | | Nov. | | Dec. | | Total. |
|---|---|---|---|---|---|---|---|---|---|---|---|---|---|---|---|---|---|---|---|---|---|---|---|---|---|
| | M. | F. | M. | F. | M. | F. | M. | F. | M. | F. | M. | F. | M. | F. | M. | F. | M. | F. | M. | F. | M. | F. | M. | F. | |
| 1871 ... | 1 | ... | 1 | ... | 3 | ... | ... | 1 | ... | ... | ... | 1 | ... | ... | ... | ... | ... | ... | ... | 2 | ... | ... | 1 | ... | 10 |
| 1872 ... | ... | 1 | ... | ... | 1 | 2 | 1 | ... | ... | ... | 1 | ... | ... | ... | 1 | ... | ... | 1 | ... | ... | ... | ... | ... | ... | 8 |
| 1873 ... | 1 | 1 | ... | ... | 1 | ... | 1 | ... | ... | ... | ... | ... | ... | ... | ... | ... | ... | ... | 1 | ... | 1 | ... | ... | ... | 6 |
| 1874 ... | ... | ... | 4 | ... | ... | ... | ... | ... | ... | 1 | ... | ... | ... | ... | 1 | ... | 1 | ... | 2 | ... | 2 | ... | 2 | 2 | 15 |
| 1875 ... | ... | ... | 1 | 1 | 2 | 1 | 1 | 1 | 1 | ... | ... | ... | 1 | ... | ... | ... | ... | ... | ... | ... | 1 | ... | ... | ... | 10 |
| 1876 ... | ... | ... | 1 | ... | ... | ... | ... | 1 | 1 | ... | ... | ... | 3 | ... | 2 | ... | 1 | ... | ... | ... | ... | ... | 1 | ... | 10 |
| 1877 ... | ... | ... | 1 | ... | 1 | ... | 1 | ... | ... | ... | ... | ... | ... | ... | ... | ... | ... | ... | 1 | ... | ... | 1 | ... | ... | 5 |
| 1878 ... | ... | 1 | 2 | ... | 1 | ... | 2 | ... | 1 | ... | 1 | ... | ... | ... | 2 | 2 | 1 | ... | ... | ... | ... | ... | ... | 1 | 14 |
| Total... | 5 | | 11 | | 12 | | 9 | | 4 | | 3 | | 4 | | 8 | | 4 | | 6 | | 5 | | 7 | | 78 |

### Table 3.

| | Days. |
|---|---|
| Average period of stay in hospital before development of disease in 55 cases ... ... ... ... | 22·7 |
| Average duration of disease from invasion to death in 60 cases ... ... ... ... ... ... | 16·2 |

### Table 4.—*Details of* 78 *cases.*

After operations (23).

| Amputations. | Excisions. | Lithotomy. | Trephining. |
|---|---|---|---|
| 11 | 6 | 4 | 2 |

After injuries (10).

| Compound fractures or dislocations. | Fractured skull. | Simple fractures. | Wounds. |
|---|---|---|---|
| 3 | 2 | 3 | 2 |

* From Annual Report of Registrars.—C. H. R.

During progress of disease (31).

| Abscess. | Ulcer. | Whitlows. | Buboes. | Bedsores. | Cancer. |
|---|---|---|---|---|---|
| 7 | 0 | 2 | 1 | 1 | 1 |

| Empyema. | Dis. of bone. | Dis. of joints. | Aneurysm. | Various. | Urethral. |
|---|---|---|---|---|---|
| 1 | 8 | 5 | 1 | 4 | 14 |

| | |
|---|---|
| Pyæmia arising after operations ... ... ... | 23 |
| " " injuries ... ... ... ... | 10 |
| " " diseases ... ... ... ... | 31 |
| " " urethral ... ... ... ... | 14 |
| | 78 |

TABLE 5.—*Relation between the Cases of Pyæmia occurring in the Hospital and the Cases admitted, and the Cases of Erysipelas admitted and originating in each Year.*

| | 1871 | 1872 | 1873 | 1874 | 1875 | 1876 | 1877 | 1878 |
|---|---|---|---|---|---|---|---|---|
| Pyæmia originating ... ... ... | 10 | 8 | 6 | 15 | 10 | 9 | 5 | 14 |
| Pyæmia admitted ... ... ... | 2 | ... | 1 | 3 | 1 | 1 | ... | ... |
| Erysipelas originating ... ... | 28 | 9 | 19 | 35 | 16 | 45 | 13 | * |
| Erysipelas admitted ... ... ... | 7 | 20 | 7 | 24 | 13 | 4 | 6 | * |

---

*Cases of Deaths of Pyæmia and Septicæmia occurring in* ST. BARTHOLOMEW'S HOSPITAL *from* 1869—1878.†

Total number ... ... ... 50

*Relation between Cases of Pyæmia admitted and Cases occurring in Hospital and the Cases of Erysipelas.*

| | 1869 | 1870 | 1871 | 1872 | 1873 | 1874 | 1875 | 1876 | 1877 | 1878 |
|---|---|---|---|---|---|---|---|---|---|---|
| Pyæmia admitted ..... | 3 | 2 | 5 | 2 | 2 | 3 | 4 | 4 | 1 | 2 |
| Pyæmia occurring..... | 7 | 7 | 5 | 6 | 2 | 5 | 5 | 4 | 2 | 7 |
| Erysipelas admitted..... | 79 | 92 | 64 | 145 | 109 | 131 | 143 | 69 | 59 | 58 |
| Erysipelas occurring..... | 67 | 47 | 19 | 42 | 41 | 64 | 44 | 39 | 20 | 30 |

* Not ascertained.

† The Annual Hospital Reports.

## *Deaths from Pyæmia and Septicæmia in the* SEAMEN'S HOSPITAL (DREADNOUGHT), *Greenwich*, 1869—1878.*

TABLE I.

| | |
|---|---|
| Admitted with disease ... ... ... ... ... | 7 |
| Poisoning in hospital ... ... ... ... ... | 53 |
| Total ... ... ... ... ... | 60 |

TABLE II.—*Relation between Cases admitted and those arising in Hospital.*

| | 1869 | 1870 | 1871 | 1872 | 1873 | 1874 | 1875 | 1876 | 1877 | 1878 | Total. |
|---|---|---|---|---|---|---|---|---|---|---|---|
| Cases admitted ..... | ... | 1 | 1 | ... | ... | 1 | 1 | 3 | ... | ... | 7 |
| " arising in hospital..... | 4 | 4 | 8 | 8 | 5 | 9 | 6 | 3 | 4 | 2 | 53 |
| Total ... | 4 | 5 | 9 | 8 | 5 | 10 | 7 | 6 | 4 | 2 | 60 |

TABLE III.

Pyæmia, septicæmia—arising after

| | |
|---|---|
| Operation in ... ... ... ... ... ... | 21 cases. |
| Injury " ... ... ... ... ... ... | 8 " |
| Disease " ... ... ... ... ... ... | 29 " |
| Urethral affections ... ... ... ... ... | 2 " |
| | 60 |

* Compiled by W. J. Smith, Resident Surgeon, Seamen's Hospital.

CHARLES HENRY RALFE.

# APPENDIX II.

TABLE I.—*Cases of death from blood-poisoning without the occurrence of secondary inflammations,—septic intoxication and septic infection.*

| No. | Sex. | Age. | Primary disease. | Date of invasion. | Date of death. | Duration of case. | Symptoms. | Post-mortem appearances. |
|---|---|---|---|---|---|---|---|---|
| 1 | F. | 74 | Extirpation of a large tumour from beneath the jaw (adenoma) | April 4 | April 6 | 2 days | Admitted March 31st. Two days after operation she was very weak and ill. She had lost some blood, but not much, at the operation. Pulse intermittent. On the third day the dressings were removed; the wound was distended with offensive pus. In the afternoon there was dyspnœa, and she died in the evening. No rigors. No vomiting or diarrhœa | Post-mortem twenty-four hours after death. Marked post-mortem staining of the endocardium. *Liver* and *spleen* pale and soft. |
| 2 | F. | 36 | Pelvic abscess after labour; varicose ulcer on leg; labour 5 weeks before admission | Admitted Jan. 10, 1870 | Jan. 15, 1870 | ? | After labour the ulcer inflamed and extended. On admission ulcer very foul. Diarrhœa; sallow tint of skin; sweet smell of body and breath; delirium. Temperature not recorded. No history of rigors | Post-mortem twenty-four hours after death. Extensive pelvic abscess; dark clots in pelvic veins. Marked post-mortem staining of endocardium. *Lungs* congested at bases. *Spleen* soft. *Liver* natural. *Kidneys* congested. |
| 3 | F. | 6 | Excision of ankle-joint | Feb. 17, 1878 ? | Feb. 19, 1878 | 2 days ? | Patient admitted December 17th, 1877. Joint excised Feb. 16th. Became delirious at 2·30 p.m. on 18th. At 8·30 p.m. vomited. Temp. 96°. At midnight temp. 98°. Feb. 19th.—At 2.30 temp. 100·4°; 3.50 died. Temperature half an hour after death 98·5° | Yellowish tint of skin. *Wound.*—Edges deep red; swelling of leg as high as knee; diffuse suppuration for one inch around the wound. Bones healthy. *Veins* healthy. *Glands* in groin swollen and commencing to suppurate. *Heart* healthy; no petechiæ. *Lungs.*—"Fluid like unaltered blood in the bronchi." Air- |

| | | | | | | | | |
|---|---|---|---|---|---|---|---|---|
| | | | | | | | | vesicles in some places filled with similar fluid. Ecchymoses in submucous tissue of larger bronchi. Fauces and posterior nares contain altered blood. *Liver* firm. On section centre of lobules canary yellow; middle zone brick red; outer zone "translucent greyish colour." *Kidneys* swollen. *Spleen* small and firm. *Stomach* contains altered blood and mucus. |
| 4 | M. | 65 | Burn of arm; secondary amputation of arm | Nov. 12, 1877 | Nov. 16, 1877 | 4 days | Admitted October 17th, 1877. Whole of left arm severely burnt. 24th.—Amputation in middle of arm. The wound sloughed, and the discharge was very offensive. By November 6th the sloughs were separating and the stump cleaning. Temperature steady, about 100° to 101°. On the 12th he had a violent rigor. Temp. 105·2°. 13th.—Two rigors. The end of humerus could be felt bare. 14th.—Amputation at shoulder-joint. 15th.—Two rigors. 16th.—One rigor. Temp. 103°. Bacteria were observed in the blood during life | *Wound* somewhat foul. *Veins* healthy. *Lungs* healthy. *Heart* healthy. *Spleen* soft and swollen. *Liver* friable and swollen. No other abnormal appearances noted. |
| 5 | M. | 17 | Exostosis of femur; operation | May 21, 1876 | June 12, 1876 | 22 days | Tumour growing from condyle of femur. Removed may 20th. Rigor next day. Rigors repeated June 6th (2), 7th, 8th, 9th, 10th, 11th (2). Temperature irregular in the extreme; highest 106·8°; lowest 97·8°. Rising at time of death; 105·8°. Delirium | *Wound* open. *Bone* bare, stripped of periosteum for lower two inches. *Knee-joint* full of pus, opening into wound. *Heart* flabby; 5 oz. of clear fluid in pericardium. *Lungs* congested. *Kidneys* congested. *Liver* normal. *Spleen* large and congested. No secondary inflammation anywhere. |

| No. | Sex. | Age. | Primary disease. | Date of invasion. | Date of death. | Duration of case. | Symptoms. | Post-mortem appearances. |
|---|---|---|---|---|---|---|---|---|
| 6 | F. | 47 | Injury to knee; chronic disease of joint; amputation | May 14, 1876 | June 2, 1876 | 19 days | Old disease of knee, resulting from injury. Open sinuses. Admitted April 24th. Knee removed by amputation, May 10th. 13th.—Temp. 102°. 14th.—104°; vomiting. 18th.—Sweats profusely; discharge healthy and abundant. 30th.—Severe rigor; not repeated. June 2nd she died | Marked post-mortem staining. *Lungs* congested. *Kidney* fatty. *Spleen* soft and friable. No secondary abscesses anywhere. |
| 7 | M. | 41 | Disease of ankle-joint; amputation of foot | ? | July 13, 1876 | ? | Admitted April 26th for disease of ankle. Amputation of right foot on June 22nd. High fever on 23rd. Severe rigor on July 12th. Died on 13th | *Lungs* congested; areas of grey colour. *Liver* oily. *Kidneys* fatty. *Veins* in thigh and leg above amputation were found full of firm coagulum, non-adherent. |
| 8 | M. | 29 | Lacerated and contused wound of forearm; compound fracture of radius | ? | July 21, 1876 | Probably about 2 weeks | Admitted June 30th, 1876. Sloughing of wound; much swelling, requiring incisions; discharges decomposing. No rigors. Prolonged elevation of temperature; no great variations; highest temp. 104°; tongue gradually becoming dry; jaundiced tint of skin; no vomiting or diarrhœa. Respirations quick; 38 before death | No secondary inflammations. *Lungs* congested; a little bloody fluid in one pleura. Nothing else noteworthy except that the *intestines* were greatly distended with gas. |
| 9 | M. | 46 | Compound fracture into ankle-joint; secondary amputation. Diffuse inflammation up leg; secondary amputation 14th | ? | July 26, 1876 | Probably about 10 days | Sloughy condition of flaps; œdematous swelling of limb; foul discharge. Delirium; dry tongue; no marked vomiting or diarrhœa; no rigors; steady high temperature, about 104° to 105°. Respirations 42 before death. Admitted July 6th, | No secondary inflammations. Hypostatic congestion of *lungs*. Marked post-mortem staining; ℥vj of blood-stained fluid in the *pleura*. *Spleen* pulpy. *Liver* soft; 60 oz. *Kidneys* slightly contracted. (This case was in the same hospital, but not in the same ward or under the |

| | | | | | | | | |
|---|---|---|---|---|---|---|---|---|
| | | | | | | | exhausted and died, Temperature moderately steady; about 103°. *Rigors* March 5th, April 24th (3). Occasional diarrhœa | |
| 11 | M. | 36 | Stricture of urethra; internal urethrotomy | Oct. 12, 1874 ? | Oct. 23, 1874 | 11 days | Admitted October 9th. Retention. Internal urethrotomy 12th. *Rigor* soon after. During the next few days he had vomiting, headache, and thirst. Another rigor on 17th. 21st.—Very weak; delirious. 22nd.—A patch somewhat resembling phlegmonous erysipelas, appeared on right forearm, and a similar patch on dorsum of right foot. Œdema and swelling of left arm. 23rd.—He died. Temperature steady, high, averaging 103° | *Urethra.*—False passages; sloughy track. *Veins* healthy. *Kidneys.*—Acute interstitial nephritis of right kidney; cloudy swelling of left. *Other organs* healthy. Extensive patch of diffuse cellulitis in right arm; almost gangrenous. |
| 12 | M | 47 | Stricture of urethra; internal urethrotomy | May 14, 1878 | June 13, 1878 | 30 days | Stricture of many years' standing. Admitted April 3rd, 1878. In good general health. Internal urethrotomy, May 11th. Rigor on the 13th. Rigors repeated frequently during this day; after that none recorded. There were frequent vomiting, progressive emaciation, and much cough. On the 23rd a large abscess formed on right side of chest. 27th.—Swelling of right knee. June 3rd.—Large superficial abscess at back of arm; tongue foul and dry; occasional profuse sweating. *Temperature.*—Highest recorded 103·6°; during the whole later period there was a marked evening rise; morning temperature nearly normal | *Wound.*—Opening in the floor of urethra communicating with large perineal abscess. Prostate swollen. Contained many abscesses. *Lungs.*—Broncho-pneumonia of lower part of each lung, with slight pleurisy. *Spleen* 11 oz. *Liver* normal. *Kidneys* pale, and swollen surface of each kidney marked by a few small abscesses. *Joints.*—Much pus in right knee, pus in left sterno-clavicular articulation. *Subcutaneous tissue.*—Large abscess in posterior surface of right forearm. Diffuse suppuration on right side of chest extending down to latissimus dorsi. The abscesses in the kidney were probably due to extension of the disease from the bladder, and were not "pyæmic." |

| No. | Sex. | Age. | Primary disease. | Date of invasion. | Date of death. | Duration of case. | Symptoms. | Post-mortem appearances. |
|---|---|---|---|---|---|---|---|---|
| 13 | M. | 21 | Lithotomy | Mar. 9, 1878 | Mar. 18, 1878 | 9 days | Admitted March 4th. Had suffered from stone some years; apparently in good health. Lithotomy (lateral) 6th; free bleeding. 9th.—A rigor; tongue furred; slight vomiting. Rigor not repeated. Temp. high, moderately regular, 102° to 103·5°. 11th.—Pain in back and loins. 12th.—Delirious. 13th.—Excessive delirium. 14th.—Subcutaneous, brawny, inflammation patch over elbow. 17th.—This has extended some inches; similar patch over malleolus; tongue dry; no diarrhœa; no vomiting. *Blood* examined, nothing abnormal found | *Slight emaciation. Wound* sloughy. *Veins* healthy. *Glands* slightly swollen. *Spleen* soft, one softening infarct. *Kidneys* swollen. *Other organs* healthy. Over right elbow, on left forearm, and over right internal malleolus, and dorsum of foot are patches of diffuse suppuration in the subcutaneous tissue. Diffuse cellulitis in front of larynx, beneath deep fascia. *Blood* imperfectly coagulated; no organisms recognised in it. |
| 14 | M. | 18 | Lithotomy | Sept. 13, 1877 | Oct. 2, 1877 | 19 days | Admitted August 22nd. Tight traumatic stricture with medium-sized phosphatic calculus in bladder. Lateral lithotomy September 4th. Considerable hæmorrhage; wound of rectum. Went on tolerably well till the 12th; secondary hæmorrhage. 13th.—A violent rigor. 16th.—Acute pleuritic pain on left side. Effusion abundant by the 19th. 20th.—Signs of hydro-pneumothorax; only one rigor; persistent high temperature, somewhat irregular, varying from 100° to 104°; no diarrhœa; no vomiting; rapid emaciation; complained of pain for a few days (19th to 22nd) in acromio-clavicular joint | *Wound* foul and sloughy. *Veins* healthy. *Glands* at brim of pelvis swollen. *Heart* healthy, no post-mortem staining. *Left pleura* contained 48 oz. of offensive pus and some gas, the pus teeming with bacteria (17 hours after death). *Lung* compressed, but otherwise healthy. *Right lung* healthy. *Liver* and *Spleen* perfectly normal. *Kidney*.-Slight pyelitis on both sides; slightly swollen. *Blood*. — Rouleaux imperfect; excess of white corpuscles, no bacteria seen. |

| | | | | | | | | |
|---|---|---|---|---|---|---|---|---|
| | | | | | | | | 68. *Kidneys* large and pale. *Forearm.* — Subcutaneous tissue soaked in purulent serum. Red discoloration of outer side of leg. *Veins* healthy. *Lungs* congested. *Spleen* pale and soft. *Kidneys* pale, swollen. *No secondary inflammation anywhere.* Marked post-mortem staining. *Blood* fluid. |
| 16 | M. | 36 | Injury to arm; diffuse cellulitis; incisions | ? | Jan. 12, 1870 | ? | Fell in a fit on January 8th and injured arm; followed by diffuse cellulitis. Admitted January 11th. Arm much swelled; blebs. Died next day | |
| 17 | M. | 54 | Compound fracture of arm | Mar. 18, 1875 ? | Mar. 21, 1875 | 3 days ? | Admitted March 17th. Restless. Violent delirium on the 18th. Died on the 21st | *Lungs* œdematous; bronchitis. *Heart* uncontracted; marked blood staining. *Blood* fluid. *Liver* fatty. *Spleen* pulpy. *Kidneys* granular. |
| 18 | F. | 26 | Suppurating bursa patellæ | April 27, 1876 | May 1, 1876 | 4 days | Admitted April 26th. Abscess opened. Next day became feverish and delirious. Temp. 104·4°; pulse 150. Died rapidly | *Lungs* congested. No secondary abscesses. *Liver* granular, tissue light yellow, soft, and oily. *Kidneys* greatly congested. *Spleen* not mentioned. |
| 19 | M. | 53 | Lacerated wound of wrist | Jan. 7, 1878 | Jan. 11, 1878 | 4 days | Admitted January 7th. Diffuse spreading inflammation commenced same day. The chief symptom noted was delirium. Notes imperfect | Body well nourished. Extensive cellulitis extending up arm to axilla. *Veins* healthy. *Large* ante-mortem clot in right side of breast. *Liver* fatty. *Spleen* enlarged. *Lungs* congested. No petechiæ. *Other organs* healthy. |
| 20 | M. | 38 | Extravasation of urine (cause not mentioned) | Sept. 20, 1877 | Sept. 24, 1877 | 4 days | Admitted on September 6th, 1877, with great extravasation of urine. Free incisions. On September 20th had a rigor; temp. 105°. Rigor repeated daily till day of death. Temperature high, irregular, never falling below 102°; highest 106°. Sweated profusely. Had some pain in calves and in one joint of little finger | Extensive sloughy wound in perinæum. *Bladder* inflamed; "diphtheritic-like membrane" on mucous membrane. *Pelvis of kidney* slight recent inflammation; kidney swollen, pale streaks reaching to cortex; some points on the verge of suppuration. *Lungs* intensely congested. *Liver* fatty. *Spleen* 9½ oz., large, soft, and swollen. |

| No. | Sex. | Age. | Primary disease. | Date of invasion. | Date of death. | Duration of case. | Symptoms. | Post-mortem appearances. |
|---|---|---|---|---|---|---|---|---|
| 21 | F. | 46 | Abscess in calf of leg | Sept. 19, 1872 | Sept. 27, 1872 | 8 days | Admitted September 16th, 1872, with a large abscess in calf; cause uncertain. Opened antiseptically. Dressing failed. Discharge offensive. Leg had been swelled for five weeks before admission. Old cured hip disease of opposite side. Unhealthy woman. Severe rigor on the 19th; temp. 105°. After that temperature persistently high, about 103°. Occasional vomiting; dry tongue; sallow tint of skin; gradually became weaker, and died; no diarrhœa | Diffuse suppuration spreading from seat of primary abscess amongst muscles and subcutaneous cellular tissue as high as groin. *Knee* of same side full of pus. *Veins* healthy. *Lungs* congested. *Liver* large and soft. *Spleen* swollen and soft. *Kidneys* swollen and soft. No marked post-mortem staining. |
| | | | | Date of admission. | Date of death. | | | |
| 22 | F. | 26 | Pin operation for varicose veins | April 6, 1875 | April 30, 1875 | Dark adherent clot in the veins operated on. *Lungs* congested. *Liver* large and very soft. *Spleen* 9¾ oz., large, and soft. *Kidneys* pale. | | |
| 23 | M. | 35 | Suppuration beneath nail of r. thumb and middle finger (dissecting porter) | Jan. 18, 1875 | Jan. 19, 1875 | No cellulitis anywhere. No enlarged glands. Veins healthy. Blood dark and fluid. No bacteria seen in it. *Lungs.*—Some congestion and œdema. *Liver* soft. *Spleen* 9 oz., not particularly soft; greasy. *Kidneys* cloudy swelling; pale, and flabby. *Brain.*—Excessive vascularity of pia mater. No *petechiæ* anywhere. | |
| 24 | M. | 75 | Extravasation of urine | April 19, 1877 | April 26, 1877 | Perineal section had been performed. *Lungs.*—Marked hypostatic congestion. *Heart* large and flabby. *Liver* normal. *Spleen* 18 oz., swollen, soft, decomposed. *Kidneys* enlarged and soft, cortex swollen. | | |
| 25 | F. | 34 | Fibroid tumour of uterus; operation | April 4, 1877 | April 29, 1877 | Post mortem twenty-eight hours after death. Yellowish tint of skin. *Uterus* enlarged. Free recent incisions in os. Sloughy mass of tumour in cavity of uterus. *Veins* healthy. All organs *decomposing*; bubbles of gas, &c. *Spleen* 11 oz., much enlarged. *Lungs* congested in dependent parts. Great post-mortem staining from decomposition. | |
| 26 | F. | 40 | Cellulitis of arm from poisoned wound, recent | Dec. 24, 1876 | Dec. 26, 1876 | Extensive cellulitis of arm. Lungs much congested; œdematous. Slight broncho-pneumonia of lower lobes. *Heart* flabby. *Liver* pale and soft. *Spleen* 9½ oz., soft, and pulpy, almost diffluent. *Kidneys* large and soft; cortex | | |

| | | | | | | | | |
|---|---|---|---|---|---|---|---|---|
| | | | | | | | Rib fracture suppurating also; great emaciation; continuous delirium. Temp. record imperfect, but after November 1st it was scarcely above normal. He gradually became weaker, and died on the 21st exhausted | |
| 19 | M. | 46 | Stricture of urethra; perineal section | July 17 | July 27 | 10 days | Admitted July 12th. Stricture took No. 8. Perineal abscess opened on the 12th. 17th.—A rigor. 21st.—Perineal section. 22nd.—Slight shivers. 23rd.—Slight shivers; hiccough; delirium. 24th.—Tongue dry; slight shivers; vomiting; hiccough. 25th.—Vomiting; diarrhœa. 26th.—Diarrhœa; red blush on right middle finger; delirium; hiccough; vomiting. 27th.—Similar erysipelatous blush on left arm and forehead; constant hiccough and diarrhœa. He died. Temperature moderately regular, highest 105°; 103° at death | *Wound* apparently healthy; numerous extravasation in sub-mucous tissue of bladder. Some small abscesses in the prostate. *Superficial ecchymosis* on left foot, left leg and thigh, and back of hand. *Kidney.*—Cortex swollen, red colour. *Spleen* very large and red. *Liver* very large. *Heart.*—Marked staining. *Lungs.*—Some broncho-pneumonia; old cavity at apex; some sub-pleural petechiæ. The swelling on the forehead when cut into looked as if infiltrated with pus, but there was no actual abscess. The viscera were examined microscopically, see Appendix IV. |
| | | | | Date of admission. | Date of death. | | Post-mortem appearances. | |
| 20 | M. | 43 | Disease of wrist; extensive suppuration up arm | Mar. 24, 1875 | May 13, 1875 | | Eight incised wounds in arm. *Right pleura*, 2½ pints of semi-purulent fluid; *left*, 3 pints. *Lungs* healthy. *Liver* large, fatty. *Spleen* 4 oz., dark and soft. *Right knee-joint* contained a large quantity of pus and flakes of lymph. *Veins* healthy. | |
| 21 | M. | 8 | Primary amputation of right thigh; secondary hæmorrhage; ligature of common femoral | April 4, 1876 | April 23, 1876 | | Emaciated. *Wound* foul, sloughy. End of bone exposed, necrosed, with "appearance of osteo-myelitis." *Glands* in groin swollen. *Veins* healthy. *Joints.*—Left knee full of pus, apparently from an abscess which had commenced outside it. Effusion about left ankle; no pus. *Lungs.*—Grey granulations in pleuræ and lungs; some caseous patches; some small pyæmic infarcts. *Spleen* small and firm. No tubercle or other pathological changes in any other organ. (The infarcts in the lung seem to have been somewhat doubtful.) | |

| No. | Sex. | Age. | Primary disease. | Date of invasion. | Date of death. | Duration of case. | Symptoms. | Post-mortem appearances. |
|---|---|---|---|---|---|---|---|---|
| 3 | F. | 24 | Strumous disease of ankle-joint; amputation of leg (left) | Feb. 27, 1875 | Mar. 14, 1875 | 15 days | Disease of ankle about two and a half years. Admitted January 22nd, 1875. Amputation of leg, 27th. Stump slow in healing. Some diffuse inflammation. February 22nd.—It is described as granulating healthily. 27th.—A rigor; rigors repeated March 2nd. Pain in joints. Abscesses. Diarrhœa. Highest temp. recorded, 103°; moderately regular | Emaciation. *Stump* unhealed. *Veins* healthy. Right knee full of pus; left knee excess of synovia. Right upper tibio-fibular articulation destroyed. *Lungs.*—Pneumonia at base of right lung. *Spleen* small and firm. *Liver* congested and soft. *Kidneys* large and fatty. *Other viscera* healthy. |
| 4 | M. | 6 | Disease of hip | Dec. 2, 1876 | Dec. 17, 1876 | 15 days | Admitted for abscess forming over trochanter. Abscess opened and bone gouged away. Profuse suppuration. Steady high temperature. On December 2nd right shoulder, wrist, and ankle became swollen and painful. 4th.—Left ankle and sterno-clavicular joint. 13th.—Left knee. One slight rigor. 8th to 12th.—Profuse diarrhœa. Steady high temperature till death, averaging 103° | *Right hip.*—Head of femur necrosed; acetabulum carious; sinuses in all directions. *Joints.*—Left knee and ankle, right wrist, and both sterno-clavicular joints full of pus. *Veins* healthy. *Glands* under sterno-mastoids suppurating. *Spleen* healthy and firm. *Kidneys* swollen. *Other organs* healthy. |
| 5 | M. | 26 | Compound fracture of skull | July 30, 1878 | Sept. 18, 1878 | 49 days | Four days before admission cut his head. At first treated as an out-patient. Admitted July 30th, with wound very foul; slightly delirious. Urine free from albumen. Temp. varied from 102° to 104°. First rigor on August 3rd; repeated 4th. After this, although the temperature remained irregular and high (103° to 99°), he had | Wound unhealed. A small sequestrum partly separated at posterior part of occipital bone. A fracture about ¾ inch in length but united in the inner table. No burrowing of pus. Diplöe healthy. *Joints.*—A very small quantity of viscid puriform fluid in the right acromio-clavicular and left wrist-joints. In the viscera, nothing |

| | | | | | | | | |
|---|---|---|---|---|---|---|---|---|
| | | | | | | | no further rigor till 14th (2), 15th (2), 16th, 18th, 19th. After this there was no rigor till Sept. 10th; repeated 15th and 17th. Temperature always remained slightly above normal; varying from 99° to 102°. On August 21st the right acromio-clavicular joint swelled; and on 24th the left wrist. Beyond this and the progressive emaciation there were no marked symptoms. On 29th profuse diarrhœa commenced, which lasted till death. Tongue became dry and brown. Emaciation excessive; he gradually died. Blood examined at various times, nothing found but granules of various sizes, and a gradually increasing deficiency of red and excess of white corpuscles. The wound granulated feebly | was found except slight congestion of the intestinal mucous membrane. Slight swelling of the *spleen* and *kidneys*. *Other organs* perfectly healthy. Body extremely emaciated. |
| 6 | M. | 47 | Femoral aneurism; ligature of external iliac | May 7, 18 ? | May 12 | 5 days | Aneurism ten months. Admitted April 13th. On 14th the external iliac was tied. 21st.—Greater part of wound closed by first intention. May 7th.—Became restless and uncomfortable. 9th.—Still restless, temp. 104°; tongue dry. 10th.—Delirious; pain in shoulder. 11th.—A rigor; pain in shoulder | *Artery* healthily occluded. *Lungs* congested. *Liver* fatty. *Spleen* firm. *Kidneys* pale; tubules choked with epithelium. *Joints.*—Right hip and shoulder full of pus. *Blood*-fluid twenty-five hours after *death*. |
| 7 | M. | 50 | Fracture of base of skull | May 17, 1874 | May 21, 1874 | 4 days | Admitted May 7th. Well, and to sit up 15th. Pain in left knee 17th; temp. 104. Exact line of fracture not stated. No rigor noted | *Brain* healthy. *Viscera* normal. Left knee and right ankle full of pus. Serous effusion in intermuscular tissue of the arm and calf. |

| No. | Sex. | Age. | Primary disease. | Date of invasion. | Date of death. | Duration of case. | Symptoms. | Post-mortem appearances. |
|---|---|---|---|---|---|---|---|---|
| 8 | F. | 53 | Chronic ulcer of leg | Sept. 10, 1874 | Sept. 22, 1874 | 12 days | Admitted September 9th. 10th.—Great pain over inner condyle of left femur. 15th.—Temp. 103°. Pain in the knee and right elbow. 22nd.—Temp 105. Stupor. *Pustular* eruption on body | Organs presented no particular abnormal appearance. *Veins* healthy, Both knee-joints contained excess of fluid. No pus. |
| 9 | M. | 63 | Stricture of urethra; simple dilatation | July 23, 1876 | Aug. 8, 1876 | 16 days | Stricture five years. Admitted July 19th, with retention. Simple dilatation. Rigors, July 23rd (2). Normal temperature for two days. Rigor July 27, 28, August 3rd, 4th (3), 5th. Tongue dry and brown. Occasional vomiting. Highest temp. 105°; temperature irregular. Began to complain of pain in joints on August 6th | Stricture at bulb. A membranous layer of lymph on the mucous membrane. Cystitis. No pyelitis. *Veins* healthy. *Joints.*—Left elbow and right knee contain pus. Some diffuse suppuration around flexor carpi radialis on right side. Great staining of viscera; early decomposition. *Liver* large and soft. *Spleen* 16 oz., very soft. *Kidneys* deeply congested. Some small hæmorrhagic spots. |
| 10 | M. | 27 | Removal of displaced cuboid bone; Syme's amputation | July 25, 1875 | April 27, 1875 | 62 days | Admitted December 29th, 1874. First operation set up general synovial disease of tarsus. Syme's amputation performed July 18th, 1875. 25th.—Temp. 104°. Stump sloughing; delirious. 27th.—Swelling appeared over right elbow; not connected with the joint. March 4th.—Abscess forming over right great trochanter. 16th.—Large abscess over external condyle of humerus. 30th.—Abscess forming on back of right shoulder. No fresh abscesses formed. He gradually became | Body greatly emaciated. *The abscess* over the elbow had burst into the joint, but it had evidently commenced outside. The other abscesses were situated superficially. No post-mortem staining. No early decomposition. *Veins* healthy. *Liver* and *Spleen* albuminoid; *Spleen* not swollen. Cloudy swelling of *Kidney*. Other viscera healthy. |

| | | | | | | | | |
|---|---|---|---|---|---|---|---|---|
| | | | | | | | diarrhœa or vomiting; no jaundice. Temp. irregular, highest 106° | healthy and yellow. *Spleen* large and soft. *Kidneys* swollen. |
| 8 | M. | 37 | Operation for piles | Oct. 6 | Oct. 17 | 11 days | Admitted September 23rd. Operation 28th. Rigor October 6th; frequently repeated; pain in chest; vomiting. Highest temp. 106°, on the day before death | Slight jaundice. Empyema. *Lungs* congested. Secondary deposits. *Heart* uncontracted. Walls blood-stained. *Liver.*—Numerous pyæmic abscesses. *Veins* of lower part of rectum slightly dilated, containing dark red clot. No softened clot found. |
| 9 | M. | 19 | Disease of metatarsus; amputation; Lisfranc's | Nov. 27 | Dec. 9 | 12 days | Admitted November 23rd. Amputation 24th. Rigor 27th, repeated 28th. Stump red, swollen. December 2nd.—Redness has extended up leg; lymphatic streaks; small abscess in line of lymphatics; jaundice; vomiting. Rapid respiration. Death | *Wound.*—Inner half nearly healed. Outer half foul and sloughy. Numerous small abscesses in skin of leg. *Veins.*—Dark healthy clot. *Lungs.*—Numerous secondary abscesses. *Liver.*—100 oz. One or two abscesses. Tissue pale. *Spleen* soft and pale. One large abscess. *Kidneys* flabby, smooth; cloudy swelling. *Blood* fluid thirty-one hours after death. |
| 10 | F. | 9 | Disease of hip-joint | May 20 | May 31, 1874 | 10 days | Admitted August 20th, 1873, with sinuses leading into hip-joint. Various incisions were made from time to time, and gouging operations performed, last on May 7th. On the 10th a diffuse inflammation, resembling erysipelas, attacked the wound, with great œdema. This subsided somewhat by the 19th. On the 20th the leg began to swell greatly; temperature rose; swelling also in opposite leg; delirium; diarrhœa; much albumen in urine. One rigor on the 28th. Temperature fell before death | The tissues for a considerable distance round the diseased hip are infiltrated with serum. *Veins* healthy. *Lungs.*—Numerous "pyæmic abscesses." *Liver.*—Several small abscesses. Glands in hilus swollen. *Kidney.*—Right, two abscesses. All abdominal organs present signs of very advanced albumenoid degeneration. |

| No. | Sex. | Age. | Primary disease. | Date of invasion. | Date of death. | Duration of case. | Symptoms. | Post-mortem appearances. |
|---|---|---|---|---|---|---|---|---|
| 11 | M. | 54 | Disease of ankle-joint; incision into abscess, &c. | Feb. 12, 1877 | Feb. 22, 1877 | 10 days | General health feeble; great swelling of ankle; incision made into joint. Admitted January 31st. Some further operation February 8th. Feb. 12th.—Temp. 103·4°; delirium; temperature continued high; tongue brown and dry; no attempt at union; great quantities of pus; sweating profusely | Considerable emaciation. Imperfect union of soft parts. Bones bathed in pus. *Heart.*—Much blood staining. Fatty. *Lungs.*—Several recent deposits in lung-substance in both lungs. *Liver* congested. *Spleen* 10 oz., pulpy. *Kidneys* granular. *Brain.*—Two purulent deposits in right hemisphere, a patch of intense congestion in left. *Blood* very fluid twenty-seven hours after death. |
| 12 | M. | 33 | Abscess in chest walls | July 22, ? | July 29, 1876 | About a week | July 13th.—Was feverish. 17th.—pain in middle of chest; swelling formed. 25th.—It was lanced. 26th.—Admitted into hospital; abundant pustular eruption over body and limbs; skin in epigastrium, livid and mottled. Gaping wound over seventh and eighth ribs; foul and sloughy; dusky red; boggy. Swelling in right fore-arm, and another near right elbow. Pneumonia. Temp. 104°. Diarrhœa; delirium; increased prostration. Death three days after admission. Temperature persistently high till death. | *Wound* foul. No post-mortem staining. *Lungs* intensely congested. In anterior edge of each lower lobe is one recent infarct. *Liver* tough, not congested. *Spleen* soft and swollen, pulpy. *Kidney.*—Cloudy swelling. *Veins* healthy. |
| 13 | M. | 16 | Disease of ankle-joint | Feb. 19 | Feb. 24 | 5 days | Old disease of ankle. General health good. Various gouging operations. Admitted January 14th. Four days after last operation; on February 19th had a rigor. Abscess formed over elbow. Pneumonia; delirium. Death on the 24th | *Wound* sloughy. Joint extensively diseased. Tibia inflamed as far as medullary canal. *Heart.*—Blood staining. *Lungs.*—Secondary abscesses. *Liver, spleen,* and *kidney* contained throughout substance bubbles of gas of decomposition. Abscesses in thoracic walls on left |

| | | | | | | | | |
|---|---|---|---|---|---|---|---|---|
| | | | | | | | | side, under tendon of triceps of arm. Diffuse cellulitis of upper two thirds of forearm. Post mortem fourteen hours after death. Weather cold. |
| 14 | M. | 21 | Diffuse cellulitis of arm | July 25 | Aug. 9 | 15 days | Admitted August 1st. A week before had pain in axilla. There had been a small sore on left forefinger. Pain increased; rigors; swelling of axillary glands. On admission tongue brown and dry. pulse 100; respiration rapid; œdema and redness at inner side of left arm below the left elbow. 3rd.—Pneumonia. 4th.—Worse, both arm and lung. 7th.—Joints swelled. 8th.—Dyspnœa | Post-mortem sixteen hours and a half after death. Advanced decomposition. Extensive diffuse cellulitis of forearm. No wound. *Heart.*—Much blood staining. *Lungs.*—One small patch of secondary pneumonia, suppurating. Pneumonia of both bases. *Joints.*—Pus in right hip and knee. *Blood* very fluid. |
| 15 | M. | 58 | Stricture of urethra | Jan. 20 | Feb. 8 | 19 days | Stricture twenty years. Admitted January 5th. 19th.—Forcible dilatation, followed by rigors and vomiting. Small abscess formed in front of scrotum, and was opened. 31st.—Rigors and constant vomiting continued. February 4th.—Hypogastric pain; swelling over right elbow; pain in shoulder | *Urethra* showed several false passages. Jaundiced tint of skin. Great emaciation. *Lungs.*—Secondary abscesses in both lower lobes. *Liver.*—Large secondary abscess. *Spleen* soft and pulpy. *Kidneys* large and flabby. Pyramids congested. *Joint* not opened after death. |
| 16 | M. | 50 | Tubercular disease of testicle; castration | Nov. 4, 1878 | Nov. 11, 1878 | 5 days | Admitted October 22nd. Testicle enlarged six months. Castration November 2nd. Wound nearly healed by the 4th; in the evening a severe rigor. 5th.—A rigor. 7th.—Hæmorrhage from wound; cough; another rigor. 11th.—Died. Temperature during rigors 105·8°; at death 101°; morning before death 98·2° | *Wound* dry and sloughy. Cut section of cord swollen, hard, nodular. Exudes pus from minute abscesses. *Heart.*—Numerous subpericardial petechiæ. *Lungs.*—Left pleura, half a pint of pus. Yellow lymph. Left lung, lower lobe studded with minute abscesses. On section lower lobe dark red colour, solid, flabby, non-crepitant; large, old cavity at base. Right lung, numerous small abscesses. One or two dark patches near surface. Other organs healthy. Nothing abnormal in other organs. |

| No. | Sex. | Age. | Primary disease. | Date of invasion. | Date of death. | Duration of case. | Symptoms. | Post-mortem appearances. |
|---|---|---|---|---|---|---|---|---|
| 17 | M. | 30 | Whitlow | Dec. 1 | Dec. 6, 1873 | 5 days | Cut his finger, November 21st. Swelling and pain, on the 22nd. On the 27th an incision was made at the root of the second finger; hand swelled, but patient did not seem particularly ill. Went out walking, December 1st, and found he had pain in right thigh. 3rd. Very weak and ill; restless; temp. 101°; pulse 80; tongue dry. Middle finger swollen; discharge very offensive; great swelling and œdema of right thigh; glands in groin enlarged. Admitted into hospital. 4th.—Temp. 103°. 5th.—Temp. 104°. 6th.—Temp. 101°; furred, dry tongue; very ill; no rigors; no diarrhœa. 6th.—Pericardial friction; dyspnœa; large abscess opened in thigh. Died | *Finger.*—Suppuration in sheath of tendon; meta carpo-phalangeal joint open. *Veins* and *glands* healthy. *Thigh.*—Large foul abscess beneath deep fascia, no sharp limit to it. *Heart.*—Pericardium contains 2 oz. of turbid fluid. Serous surfaces roughened, but not much lymph. Valves reddened, chiefly from post mortem staining. Vascular injection of aortic and mitral. Muscular substance dirty muddy colour throughout; in many parts broken down into a pulp. Hæmorrhages everywhere scattered. Microscopic examination showed abundant cell infiltration; fibres breaking down. *Lungs* gorged with blood. *Spleen* large and soft. *Kidneys* swollen. |
| 18 | M. | 25 | Fracture of lower jaw; compound fracture of three ribs, left clavicle, left femur, and left humerus; contused wound of hand | About Oct. 1, 1872 | Nov. 21, 1872 | 52 days | Admitted September 26th. October 1st.—High temperature and delirium. Delirium continued more or less till death; tongue dry. 9th.—Profuse sweating; sudamina; offensive breath. Suppuration round the simple fracture of the thigh on the 20th. Pus drawn off on the 24th; not offensive; no organisms recognised in it. 29th. — Simple fracture of humerus suppurative. 30th.— | Body greatly emaciated. Beyond the suppuration round the fracture nothing abnormal was found. All the viscera were perfectly healthy. No suppuration in *joints*. *Veins* healthy. Large bed sore over sacrum. |

| | | | | | | | | |
|---|---|---|---|---|---|---|---|---|
| | | | | | | | [illegible] continuous delirium. Temp. record imperfect, but after November 1st it was scarcely above normal. He gradually became weaker, and died on the 21st exhausted | |
| 19 | M. | 46 | Stricture of urethra; perineal section | July 17 | July 27 | 10 days | Admitted July 12th. Stricture took No. 8. Perineal abscess opened on the 12th. 17th.—A rigor. 21st.—Perineal section. 22nd.—Slight shivers. 23rd.—Slight shivers; hiccough; delirium. 24th.—Tongue dry; slight shivers; vomiting; hiccough. 25th.—Vomiting; diarrhœa. 26th.—Diarrhœa; red blush on right middle finger; delirium; hiccough; vomiting. 27th.—Similar erysipelatous blush on left arm and forehead; constant hiccough and diarrhœa. He died. Temperature moderately regular, highest 105°; 103° at death | *Wound* apparently healthy; numerous extravasation in sub-mucous tissue of bladder. Some small abscesses in the prostate. *Superficial ecchymosis* on left foot, left leg and thigh, and back of hand. *Kidney.*—Cortex swollen, red colour. *Spleen* very large and red. *Liver* very large. *Heart.*—Marked staining. *Lungs.*—Some broncho-pneumonia; old cavity at apex; some sub-pleural petechiæ. The swelling on the forehead when cut into looked as if infiltrated with pus, but there was no actual abscess. The viscera were examined microscopically, see Appendix IV. |
| | | | | Date of admission. | Date of death. | | Post-mortem appearances. | |
| 20 | M. | 43 | Disease of wrist; extensive suppuration up arm | Mar. 24, 1875 | May 13, 1875 | | Eight incised wounds in arm. *Right pleura*, 2½ pints of semi-purulent fluid; *left*, 3 pints. *Lungs* healthy. *Liver* large, fatty. *Spleen* 4 oz., dark and soft. *Right knee-joint* contained a large quantity of pus and flakes of lymph. *Veins* healthy. | |
| 21 | M. | 8 | Primary amputation of right thigh; secondary hæmorrhage; ligature of common femoral | April 4, 1876 | April 23, 1876 | | Emaciated. *Wound* foul, sloughy. End of bone exposed, necrosed, with "appearance of osteo-myelitis." *Glands* in groin swollen. *Veins* healthy. *Joints.*—Left knee full of pus, apparently from an abscess which had commenced outside it. Effusion about left ankle; no pus. *Lungs.*—Grey granulations in pleuræ and lungs; some caseous patches; some small pyæmic infarcts. *Spleen* small and firm. No tubercle or other pathological changes in any other organ. (The infarcts in the lung seem to have been somewhat doubtful.) | |

| No. | Sex. | Age. | Primary disease. | Date of admission | Date of death. | Post-mortem appearances. |
|---|---|---|---|---|---|---|
| 28 | M. | 36 | Disease of hip-joint | Feb. 27, 1877 | Mar. 18, 1877 | Great emaciation. Large, foul, suppurating cavity where the head had been excised. Upper two inches of shaft necrosed. Periosteum separated from bone to within three inches of knee. Medulla infiltrated with pus. Abscesses burrowing into pelvis and gluteal region. *Pleuræ.*—Recent pleurisy over lower lobes of left lung. *Lungs.*—Numerous infarcts breaking down in centre. Numerous grey granulations. These are entirely free from opacity, and are uniform in size. *Liver.*—One grey granulation in capsule. *Spleen* 2½ oz., slightly enlarged. *Kidneys.*—Cortex pale. *Brain.*—On surface, beneath pia mater, are numerous yellowish patches, rounded mostly, not prominent, varying in size from a millet seed to a pea. On section containing puriform fluid. Each hemisphere contains a large caseous mass size of walnut. |

TABLE IV.—*Pyæmia.* GROUP II. *Cases in which thromboses occurred apparently as a secondary effect of blood poisoning.*

| | | | | Date of invasion. | Date of death. | Duration of case. | Symptoms. | Post-mortem appearances. |
|---|---|---|---|---|---|---|---|---|
| 1 | M. | 66 | Primary amputation at wrist | June 16, 1875 | July 1, 1875 | 15 days | Amputation April 29th. May 10th.—All going on well. 22nd.—Suppuration; pus squeezed from between flaps; swollen up to elbow. 24th.—Swelling continues. 30th.—Incisions; abundant suppuration; end of radius protruded from stump. June 16th.—First rigor. Rigors June 17th, 18th, 19th, 23rd, 25th, 26th, 30th (2). Irregular temperature, highest recorded 104°. Progressive emaciation and weakness only symptoms noted. Notes imperfect | Considerable emaciation; œdema of both legs. *Stump.*—End of radius sticks out; abscess amongst muscles of forearm. Both *bones* more or less extensively necrosed. *Veins* healthy in forearm and arm. *Large abscess* in and under right soleus; popliteal vein opened into abscess, and was distended with pus; this reached as high as Poupart's ligament, where there was a small, firmly adherent, laminated clot. Pus in small veins opening into femoral and popliteal. *Lungs.*— |

| | | | | | | | | |
|---|---|---|---|---|---|---|---|---|
| | | | | | | | | One embolic abscess. *Liver* pale. *Spleen* soft, pulpy. *Kidneys* pale. |
| 2 | M. | 28 | Empyema; drainage tube inserted | Mar. 10, 1871 | Mar. 17, 1871 | 7 days | Had had two openings made into pleura some months before. Admitted February 20th. Openings enlarged, and a drainage tube put in. *Rigor*. March 10th and 15th temperature irregular. Highest recorded 103°. Vomiting. Much pain in side. No jaundice. Œdema of one leg. (Notes not perfect) | Cavity of right pleura almost obliterated. Small cavity containing foul pus. Lungs opposite the wound soaked in pus. *Veins*.—Nothing abnormal noticed. *Lungs*.—Both contain numerous secondary abscesses. *Liver*.—More than a dozen pyæmic abscesses. *Spleen* firm, medium size. *Kidneys* pale and fatty. *Brain*.—Three pyæmic abscesses on surface. *Veins of leg* plugged from about middle of thigh to iliacs. In femoral and saphenous the clot was broken down into a creamy fluid. Internal iliac vein in same state. No local cause found. No bedsore. |
| 3 | M. | 2 | Fracture of lower jaw (compound), cut lip | Oct. 15, 1877 | Oct. 20, 1877 | 5 days | No history of any previous ill-health. Fat and healthy. Admitted October 10th. 15th.—Temperature rose to 104° from 100°. 17th.—Some pustules were noticed on the arm, and a patch of brawny cellulitis on forearm. 18th.—Swelling increased; general œdema of arm. Became semi-comatose, and died on the 20th. No diarrhœa or vomiting. No rigors or convulsions. Temperature irregular; highest 105·5°. *Blood* examined on the 18th; nothing abnormal | *Wound* on face foul and sloughy. *Veins* of face healthy. *Glands* below jaw inflamed. *Lungs*.—One small infarct in left lung. *Brain* congested, a little lymph on surface of pons. *Other organs* perfectly healthy. *Arm*.—Brawny swelling; serous infiltration; no pus. Median vein full of grumous broken-down clot. Axillary closed by a firm thrombus. Chains of granules with independent movement found in serum from arm and in broken-down clot. Post-mortem twenty-five hours after death. Body kept in ice. |

| No. | Sex. | Age. | Primary disease. | Date of invasion. | Date of death. | Duration of case. | Symptoms. | Post-mortem appearances. |
|---|---|---|---|---|---|---|---|---|
| 5 | M. | 66 | Stricture of urethra; cystitis | ? | Aug. 8, 1878 | ? | Patient stupid, and could give no account of himself. Notes imperfect | Stricture about three inches down urethra. Short false passage. *Lungs.*—Right contains numerous collections of pus. Right *pleura* contains thin puriform fluid. *Spleen* pulpy. *Liver* fatty. *Bladder.*—Recent cystitis. Blood fluid forty-one hours after death. |
| 6 | M. | 5 | Disease of hip; old excision | ? | Jan. 29, 1878 | ? | Sinuses about hip enlarged. January 16th.—No bone removed. 25th.—Child much weaker. 29th.—Died. Notes imperfect | Numerous sinuses leading to extensive caries of the pelvic bones. Foul pus. *Veins* healthy. *Lungs.*—Numerous "pyæmic abscesses" in both lungs. Some pleurisy over them. *Liver.*—Several pyæmic abscesses on surface. Peritonitis over them. Branches of the hepatic vein were found filled with softened clot. In the area from which these veins came were scattered points of suppuration. *Spleen* not enlarged. Other organs healthy, with the exception of a slight degree of lardaceous degeneration. |
| 7 | F. | 54 | Phlegmonous erysipelas of arm | Nov. 29 | Dec. 4, 1874 | 5 days | Admitted November 20th, 1874. Cut her arm with glass some few days before. Pus burrowing amongst the muscles. Great swelling. 29th.—Free incisions. Rigor the same day. Rigor repeated November 30th, 31st, and December 1st and 2nd, not after. Discharge from wound offensive; [illegible] | Sinuses burrowing in various directions. Discharge foul. *Veins* healthy. *Lungs.*—Right pleura contains recent lymph. Right lung, about fifteen "abscesses." Left side healthy. *Liver* contained innumerable abscesses, varying from a few minims to one ounce in capacity, surrounded by a zone of hyperæmia. Pus |

| | | | | | | | | |
|---|---|---|---|---|---|---|---|---|
| | | | | | | | diarrhœa or vomiting; no jaundice. Temp. irregular, highest 106° | healthy and yellow. *Spleen* large and soft. *Kidneys* swollen. |
| 8 | M. | 37 | Operation for piles | Oct. 6 | Oct. 17 | 11 days | Admitted September 23rd. Operation 28th. Rigor October 6th; frequently repeated; pain in chest; vomiting. Highest temp. 106°, on the day before death | Slight jaundice. Empyema. *Lungs* congested. Secondary deposits. *Heart* uncontracted. Walls blood-stained. *Liver.*—Numerous pyæmic abscesses. *Veins* of lower part of rectum slightly dilated, containing dark red clot. No softened clot found. |
| 9 | M. | 19 | Disease of metatarsus; amputation; Lisfranc's | Nov. 27 | Dec. 9 | 12 days | Admitted November 23rd. Amputation 24th. Rigor 27th, repeated 28th. Stump red, swollen. December 2nd.—Redness has extended up leg; lymphatic streaks; small abscess in line of lymphatics; jaundice; vomiting. Rapid respiration. Death | *Wound.*—Inner half nearly healed. Outer half foul and sloughy. Numerous small abscesses in skin of leg. *Veins.*—Dark healthy clot. *Lungs.*—Numerous secondary abscesses. *Liver.*—100 oz. One or two abscesses. Tissue pale. *Spleen* soft and pale. One large abscess. *Kidneys* flabby, smooth; cloudy swelling. *Blood* fluid thirty-one hours after death. |
| 10 | F. | 9 | Disease of hip-joint | May 20 | May 31, 1874 | 10 days | Admitted August 20th, 1873, with sinuses leading into hip-joint. Various incisions were made from time to time, and gouging operations performed, last on May 7th. On the 10th a diffuse inflammation, resembling erysipelas, attacked the wound, with great œdema. This subsided somewhat by the 19th. On the 20th the leg began to swell greatly; temperature rose; swelling also in opposite leg; delirium; diarrhœa; much albumen in urine. One rigor on the 28th. Temperature fell before death | The tissues for a considerable distance round the diseased hip are infiltrated with serum. *Veins* healthy. *Lungs.*—Numerous "pyæmic abscesses." *Liver.*—Several small abscesses. Glands in hilus swollen. *Kidney.*—Right, two abscesses. All abdominal organs present signs of very advanced albumenoid degeneration. |

| No. | Sex. | Age. | Primary disease. | Date of invasion. | Date of death. | Duration of case. | Symptoms. | Post-mortem appearances. |
|---|---|---|---|---|---|---|---|---|
| 3 | F. | 50 | Excision of varicose veins; dressing at first antiseptic, but this was discontinued | Feb. 13, 1875 | Feb. 18, 1875 | 5 days | Admitted February 6th, 1875. A diffused blush of redness round the wounds, extending for some distance; surfaces of wound unhealthy; discharges decomposing. Some chilliness, but no actual rigors. Temperature not very high, about 101° to 102°; two sudden rises to 105°. Tongue dry and foul; no marked diarrhœa or vomiting; dyspnœa. Resp. 42 day before death; muscular tremors and clonic spasm of left arm | The *veins* in both legs above the points operated on contained unhealthy clots, but higher still they were filled with firm adherent coagula; there was much blood-staining of endocardium. *Blood* coagulated as usual. *Lungs* congested at lower lobes. *Spleen* large and pale, but not particularly soft. *Liver* healthy. *Kidneys* small and granular. Post mortem 11 hours after death. |
| 4 | F. | 48 | Abortion; retention of part of placenta | Sept. 23, 1876 | Oct. 10, 1876 | Uterus enlarged; inky-coloured patch seen outside at posterior and upper part; inside, corresponding to this, was a shreddy mass of black colour, apparently a retained piece of placenta, stained by perchloride of iron. *Veins.*—Left ovarian contained clot reaching nearly to vena cava; at highest part firm, pale, and non-adherent; lower down firm and adherent; lower still puriform and diffluent at a spot at which a vein from the uterus joined it. *Lungs.*—Congestion and œdema at posterior parts. *Heart* pale and flabby. *Liver* contained bubbles of gas of decomposition; pale and flabby. *Spleen* large and soft; bubbles of gas. *Kidneys* pale, decomposed; no marked staining of intima of vessels; no petechiæ anywhere. Post-mortem 13 hours after death. | |

| | | | | | | | | |
|---|---|---|---|---|---|---|---|---|
| | | | | | | | | arm. Diffuse cellulitis of upper two thirds of forearm. Post mortem fourteen hours after death. Weather cold. |
| 14 | M. | 21 | Diffuse cellulitis of arm | July 25 | Aug. 9 | 15 days | Admitted August 1st. A week before had pain in axilla. There had been a small sore on left forefinger. Pain increased; rigors; swelling of axillary glands. On admission tongue brown and dry. pulse 100; respiration rapid; œdema and redness at inner side of left arm below the left elbow. 3rd.—Pneumonia. 4th.—Worse, both arm and lung. 7th.—Joints swelled. 8th.—Dyspnœa | Post-mortem sixteen hours and a half after death. Advanced decomposition. Extensive diffuse cellulitis of forearm. No wound. *Heart.*—Much blood staining. *Lungs.*—One small patch of secondary pneumonia, suppurating. Pneumonia of both bases. *Joints.*—Pus in right hip and knee. *Blood* very fluid. |
| 15 | M. | 58 | Stricture of urethra | Jan. 20 | Feb. 8 | 19 days | Stricture twenty years. Admitted January 5th. 19th.—Forcible dilatation, followed by rigors and vomiting. Small abscess formed in front of scrotum, and was opened. 31st.—Rigors and constant vomiting continued. February 4th.—Hypogastric pain; swelling over right elbow; pain in shoulder | *Urethra* showed several false passages. Jaundiced tint of skin. Great emaciation. *Lungs.*—Secondary abscesses in both lower lobes. *Liver.*—Large secondary abscess. *Spleen* soft and pulpy. *Kidneys* large and flabby. Pyramids congested. *Joint* not opened after death. |
| 16 | M. | 50 | Tubercular disease of testicle; castration | Nov. 4, 1878 | Nov. 11, 1878 | 5 days | Admitted October 22nd. Testicle enlarged six months. Castration November 2nd. Wound nearly healed by the 4th; in the evening a severe rigor. 5th.—A rigor. 7th.—Hæmorrhage from wound; cough; another rigor. 11th.—Died. Temperature during rigors 105·8°; at death 101°; morning before death 98·2° | *Wound* dry and sloughy. Cut section of cord swollen, hard, nodular. Exudes pus from minute abscesses. *Heart.*—Numerous subpericardial petechiæ. *Lungs.*—Left pleura, half a pint of pus. Yellow lymph. Left lung, lower lobe studded with minute abscesses. On section lower lobe dark red colour, solid, flabby, non-crepitant; large, old cavity at base. Right lung, numerous small abscesses. One or two dark patches near surface. Other organs healthy. Nothing abnormal in other organs. |

| No. | Sex. | Age. | Primary disease. | Date of admission. | Date of death. | Post-mortem appearances. |
|---|---|---|---|---|---|---|
| 17 | M. | 53 | Disease of finger. Amputation of right index finger | May 12, 1875 | May 16, 1875 | Post mortem twenty-four hours after death. Right epitrochliar *gland* swollen and suppurating. *Veins* normal. *Lungs* œdematous and congested. *Heart* flabby and friable. *Liver* fatty. An abscess, size of walnut, on anterior surface. *Spleen* 10½ oz., soft. *Kidneys* congested, soft, and friable. *Brain.*—Excess of subarachnoid fluid. *Parotid gland* red and swollen, not suppurating. |
| 18 | F. | 50 | Diffuse abscess in thigh. Incisions | Jan. 24, 1876 | Feb. 2, 1876 | *Wounds* and abscess cavity foul. Abscess had recently opened into the knee. *Glands* in groin swelled, not suppurating. *Lungs* deeply congested and œdematous. Bronchi inflamed. *Liver* small, otherwise healthy. *Spleen* 10 oz. Numerous infarcts softening in centre. Substance very soft. *Kidneys.*—Numerous points of intense injection with central suppuration. |
| 19 | M. | 44 | Amputation of left thigh | April 3, 1877 | Apr. 25, 1877 | Wound unhealed. *Veins* healthy. *Pleuræ.*—Recent lymph on both sides. *Lungs.*—Numerous softening infarcts in the lower lobes of both lungs. *Spleen* 8 oz., slightly enlarged, soft. *Liver* soft. *Kidneys* swollen. *Stomach.*—Minute erosions, and patches of hæmorrhage in mucous membrane. Infiltration of pus around pharynx and amongst the muscles at the root of the tongue. |
| 20 | M. | 17 | Diffuse cellulitis of neck and mediastinum, with suppuration. Incisions | Dec. 7, 1875 | Jan. 8, 1876 | *Wounds* foul. Large area of diffuse suppuration extending from lower jaw to mediastinum. *Veins* healthy. *Lungs.*—Lower and middle lobes of right lung solid, and numerous "pyæmic abscesses" scattered through the solid area. Left in the same state. *Liver* pale. *Spleen* 6½ oz., large, pale, soft. Nothing else noticed. |
| 21 | F. | 72 | Spindle-celled sarcoma of thigh. Operation | July 30, 1875 | Mar. 26, 1876 | Large scar in groin, with one part not healed, covered with smooth, glazed granulations. *Lungs.*—A branch of pulmonary artery contains a firm thrombus, with a small abscess in the corresponding part of the lung. *Liver* fatty. *Spleen* 6 oz., swollen, very soft, greasy. |
| 22 | F. | 18 | Chronic abscess of sacral region | April 3, 1877 | April 29, 1877 | Large open abscess over sacrum. Caries of left side of sacrum. *Veins.*—No disease of veins found. *Pleuræ.*—Right, three pints of fluid, sero-purulent. *Lungs.*—Many patches of an irregular triangular form in lower lobe, probably not pyæmic. In left lung one "typical pyæmic abscess." *Liver* pale and soft. *Spleen* 7 oz., soft and swollen. *Kidneys* soft and swollen. |
| 23 | M. | 23 | Disease of right internal ear | May 26, 1877 | May 26, 1877 | Mastoid cells contain thick cheesy matter and pus. Membrana tympani perforated, signs of chronic otitis media. Dura mater over petrous portion of temporal discoloured and thickened, loose. Roof of tympanum rough, pus oozes through on pressing on external meatus. Layer of lymph on arachnoid |

| | | | | | | | |
|---|---|---|---|---|---|---|---|
| | | | | | | 22nd.—Violent rigor and vomiting. Admitted September 25th.—Great pain and tenderness in right iliac fossa; tongue foul; spleen can be felt enlarged. 26th.—A rigor. 27th.—A rigor; vomiting; epigastric pain. 28th.—Three rigors. 29th.—Great tenderness in epigastrium. The symptoms remained much the same till death. Repeated rigors; vomiting; tenderness and pain in abdomen. Distension of abdomen, and ten days before death slight jaundice. Temp. extremely irregular; highest 106°. October 2nd.—During last three days fell to 102, and remained tolerably regular | subperitoneal tissue behind cæcum. Acute diffuse peritonitis, apparently starting from this point. *Cæcum* healthy. Small concretion in vermiform appendix; not impacted. No perforation. Some excess of fluid in pleuræ and pericardium. No petechiæ. *Lungs* congested. *Liver* very large. *Portal vein* contained creamy pink fluid, and about 1½ inches from liver an adherent yellow thrombus. Walls inflamed. Purulent fluid in branches in liver. Liver studded with points of suppuration. *Spleen* 7 oz., soft and greasy. *Kidneys* slightly swollen. *Other organs* healthy. Marked post-mortem staining from early decomposition. |
| | | | | Date of admission. | Date of death. | | |
| 6 | F. | 57 | Cancer of liver; gall-stones ulcerating into portal vein; phlebitis | Feb. 7, 1876 | Feb. 13, 1876 | Emaciation. Slight icteric tint. Recent peritonitis, with localised collections of pus about liver. *Portal vein* opened by ulceration into a cavity containing pus. Branches of vein intensely inflamed, and containing softening clot. Several softening patches in *liver* substance, like early "pyæmic abscesses." *Spleen* soft, several recent infarcts. *Kidneys.*—One or two recent embolic patches. *Lungs* hypostatic congestion. *Heart*, recent endocarditis, vegetations on valves of left side. | |
| 7 | M. | 57 | Secondary amputation of thigh | Feb. 17, 1876 (Amputation Feb. 28) | April 10, 1876 | Emaciated. *Amputation wound* almost healed, only a few sinuses remaining. End of bone bare. Two small abscesses, apparently perfectly circumscribed, were found in the medulla at the lower end. *Veins.*—Femoral above junction of saphenous, and circumflex veins full of "softened puriform clot." This extended into common iliac. Saphenous and circumflex veins filled with similar clot. Superficial femoral below this entrance filled with healthy adherent clot. *Lungs* congested, otherwise normal. *Liver* two or three small softening infarcts in right lobe. *Spleen* very soft and friable. Numerous softening infarcts. *Kidneys.*—Cortex pale. | |

| No. | Sex. | Age. | Primary disease. | Date of admission. | Date of death. | Post-mortem appearances. |
|---|---|---|---|---|---|---|
| 8 | F. | 21 | Tumour of palm of hand; secondary growths in axilla; foul bed-sore | Feb. 22, 1876 | May 11 | Tumour in hand had not been operated on. In the axilla was a sloughy mass of glands. *Pleuræ.*—A little recent lymph in left pleura. *Lungs.*—Grey Hepatisation of lower lobe of left lung. No infarcts. *Pericardium.*—A very little recent lymph. *Liver* fatty. *Spleen* normal size, firm. *Kidneys* pale. *Veins.*—Common iliacs, internal and external iliacs, upper part of femorals and lower end of vena cava filled with adherent decolorised clots softening in the centre to a puriform fluid. Both shoulder *joints* and right elbow disorganised, and filled with offensive pus. Body greatly emaciated. |
| 9 | M. | 36 | Amputation of thigh for suppuration in knee-joint | Nov. 16, 1877 | Nov. 27, 1877 | Wound granulating, flaps deeply undermined. Lower end of shaft of femur bare. Medulla healthy. No general cellulitis of stump. Sheaths of femoral vessels, thickened and infiltrated, but free from pus. Superficial femoral vein firmly plugged by healthy clot at its divided end, above this as far as the first inch of the external iliac vein, the vein is swollen and filled with softened clot, and above this again a solid healthy plug. Internal saphenous and profunda veins also contain partly softened clot as far as the valves, next to the main trunk, beyond this as far as traced empty and healthy. Glands in groin slightly swollen. *Lungs.*—Marked hypostatic congestion, some broncho-pneumonia. *Liver* large, and soft. *Spleen* 8 oz., enlarged, but moderately firm, readily breaking down. *Kidneys* large and pale. *Joints.*—Pus in right shoulder. |

TABLE VII.—GROUP V. *Pyæmia, in which thrombosis and softening of the clot occurred with abscesses in the lungs and in other viscera and tissues.*

| | | | | Date of invasion. | Date of death. | Duration of case. | Symptoms. | Post-mortem appearances. |
|---|---|---|---|---|---|---|---|---|
| 1 | F. | 60 | Compound fracture of radius and ulna | Mar. 23, 1872 | Mar. 30, 1872 | 7 days | An habitual drunkard; bloated. Admitted February 28th, 1872. Had broken the arm the day before. Pus formed and burrowed in all directions. Constitutional symp- | *Stump* unhealed and sloughy. *Veins* deep and superficial, filled with breaking down clots as high as shoulder; no osteo-myelitis. Subserous petechiæ on heart and |

| | | | | | | | | |
|---|---|---|---|---|---|---|---|---|
| | | | | | | | | *Spleen* soft, pulpy. *Kidneys* pale. |
| 2 | M. | 28 | Empyema; drainage tube inserted | Mar. 10, 1871 | Mar. 17, 1871 | 7 days | Had had two openings made into pleura some months before. Admitted February 20th. Openings enlarged, and a drainage tube put in. *Rigor*. March 10th and 15th temperature irregular. Highest recorded 103°. Vomiting. Much pain in side. No jaundice. Œdema of one leg. (Notes not perfect) | Cavity of right pleura almost obliterated. Small cavity containing foul pus. Lungs opposite the wound soaked in pus. *Veins*.—Nothing abnormal noticed. *Lungs*.—Both contain numerous secondary abscesses. *Liver*.—More than a dozen pyæmic abscesses. *Spleen* firm, medium size. *Kidneys* pale and fatty. *Brain*.—Three pyæmic abscesses on surface. *Veins of leg* plugged from about middle of thigh to iliacs. In femoral and saphenous the clot was broken down into a creamy fluid. Internal iliac vein in same state. No local cause found. No bedsore. |
| 3 | M. | 2 | Fracture of lower jaw (compound), cut lip | Oct. 15, 1877 | Oct. 20, 1877 | 5 days | No history of any previous ill-health. Fat and healthy. Admitted October 10th. 15th.—Temperature rose to 104° from 100°. 17th.—Some pustules were noticed on the arm, and a patch of brawny cellulitis on forearm. 18th.—Swelling increased; general œdema of arm. Became semi-comatose, and died on the 20th. No diarrhœa or vomiting. No rigors or convulsions. Temperature irregular; highest 105·5°. *Blood* examined on the 18th; nothing abnormal | *Wound* on face foul and sloughy. *Veins* of face healthy. *Glands* below jaw inflamed. *Lungs*.—One small infarct in left lung. *Brain* congested, a little lymph on surface of pons. *Other organs* perfectly healthy. *Arm*.—Brawny swelling; serous infiltration; no pus. Median vein full of grumous broken-down clot. Axillary closed by a firm thrombus. Chains of granules with independent movement found in serum from arm and in broken-down clot. Post-mortem twenty-five hours after death. Body kept in ice. |

| No. | Sex. | Age. | Primary disease. | Date of invasion. | Date of death. | Duration of case. | Symptoms. | Post-mortem appearances. |
|---|---|---|---|---|---|---|---|---|
| 4 | M. | 45 | Tumour of tongue (found afterwards to be a gumma) removed by ecraseur | Feb. 8, 1875 ? | Feb. 24, 1875 | About 16 days | Patient in good health. Urine normal. Operation February 8th. 12th.—Temp. 103·6°; wound sloughy. 17th.—Temperature still high; sloughs have separated. Much swelling in glands of neck. 18th.—Red patch over left inner condyle of humerus. 19th.—Phlebitis of internal saphenous, which is varicose; swelling of feet; temp. 99·8°; no rigors. 20th.—Temp. 105·5°; vomiting. 21st.—Extension of the inflammation in arm. 22nd.—The same. 23rd.—Three or four ecchymoses on right hand. 24th.—Phlebitis extending; temp. 102·6°. He died July 24th | *Stump of tongue* sloughy. Pus in glands about sterno-mastoid. *The red patch* on the left leg being cut into showed diffuse suppuration in the subcutaneous tissue. Similar condition in forearm. *Veins* of forearm healthy. Veins of leg filled with clot, not softened. *No petechiæ. Heart* large and fatty. *Lungs* congested. *Peritoneum* containing a few ounces of reddish fluid. *Liver* 87 oz., soft. *Spleen* large and pulpy. *Kidneys* cloudy, swelling. |
| 5 | M. | 52 | Stricture of urethra; external urethotomy | Sept. 3, 1876 | Sept. 14, 1876 | 11 days | Admitted September 3rd. Rigor same day. Perinæal section on 4th. Large perinæal abscess found. Temperature fell, and patient at first improved. On the 11th rigors returned with vomiting and hiccough. On the 12th two rigors. 13th.—Swelling and pain in left forearm and right calf. Temperature during rigors 106°; irregular | Incision into membranous part of urethra. *Wound* sloughy. *Lungs* congested. *Spleen* a mere pulp. *Liver* and *kidneys* swollen. No secondary abscesses. Recent antemortem clot in right posterior tibial veins. |
| 6 | F. | 44 | Scirrhus of right mamma; abscess in axilla | Feb. 11, 1878 | Feb. 17, 1878 | Cancerous tumour of right breast, adherent to skin. Right axilla full of offensive pus. Small collection of pus on dorsal surface of lower end of metacarpal bone of right little finger. Joint beneath contains pus. Left short saphenous vein full of purulent fluid. Both sterno-clavicular *joints*, both shoulders, and | | | | |

| | | | | | | | | |
|---|---|---|---|---|---|---|---|---|
| | | | | | | | severe hæmorrhage; ligature of femoral; stump very foul. Complained of pain in right knee on the 20th. 22nd.—A severe rigor; pains all over body and down right leg; no other marked symptoms | healthy. *Joint.*—Right knee full of pus. |
| 6 | M. | 24 | Scalp wound; osteo-myelitis of occipital bone | Aug. 11, 1875 | Aug. 16, 1875 | 5 days | Ten days after the wound he had a severe rigor; not repeated. Was admitted August 11th. Had throbbing pain in head; no paralysis; urine healthy; temp. 104°, steady; had profuse diarrhœa. On the 12th well-marked jaundice; pain in region of liver; bloody expectoration; confusion of intellect. Died comatose | Bare bone on occipital; outer table cut away. Diploë soaked in pus; a little pus between bone and dura mater; yellowish soft clot projecting from small *vein* into longitudinal sinus close to Torcular Herophili. *Brain* healthy. Subpericardial *petechiæ*. *Lungs* congested, three abscesses. *Liver* 99 oz.; innumerable abscesses not limited to surface; pus offensive, but did not blacken lead paper. *Spleen* large and soft. *Kidneys* swollen. |
| 7 | M. | 31 | Compound fracture of leg (bedsore). Primary amputation of right leg | Jan. 19, 1871 or Mar. 1 | Mar. 20, 1871 | ? 20 | Patient was admitted January 16th, 1871, and primary amputation below the knee performed. Three days after, the 19th, he had a rigor. Rigors were repeated frequently till February 11th, then there was a long interval till March 1st; during this time the patient remained very weak, but had no symptoms of any "blood poisoning." On the 1st the veins of opposite leg were found to be plugged. A large *bedsore* had formed. After the rigors were repeated he gradually died (notes not perfect). The patient seems to have recovered from the first attack due to the stump, and died from a second arising from the bedsore | Great *emaciation*. *Petechiæ* on front of chest. On side of amputation *veins* are filled with breaking down clots right up to the vena cava and down to entrance of profunda, thence to the stump they are healthy; veins in left side are also diseased. Left common iliac obliterated for one inch, its walls being in apposition and firmly glued together. *Veins* leading from bedsore to right iliac full of broken-down clot. *Lungs.*—Left, six infarcts, not softened; right, five or six similar infarcts. *Liver* healthy. *Spleen* large and soft, two abscesses. *Kidneys* swollen, one small abscess. The source of infection was evidently the bedsore. The stump was healthy. |

| No. | Sex. | Age. | Primary disease. | Date of invasion. | Date of death. | Duration of case. | Symptoms. | Post-mortem appearances. |
|---|---|---|---|---|---|---|---|---|
| 3 | F. | 50 | Excision of varicose veins; dressing at first antiseptic, but this was discontinued | Feb. 13, 1875 | Feb. 18, 1875 | 5 days | Admitted February 6th, 1875. A diffused blush of redness round the wounds, extending for some distance; surfaces of wound unhealthy; discharges decomposing. Some chilliness, but no actual rigors. Temperature not very high, about 101° to 102°; two sudden rises to 105°. Tongue dry and foul; no marked diarrhœa or vomiting; dyspnœa. Resp. 42 day before death; muscular tremors and clonic spasm of left arm | The *veins* in both legs above the points operated on contained unhealthy clots, but higher still they were filled with firm adherent coagula; there was much blood-staining of endocardium. *Blood* coagulated as usual. *Lungs* congested at lower lobes. *Spleen* large and pale, but not particularly soft. *Liver* healthy. *Kidneys* small and granular. Post mortem 11 hours after death. |
| 4 | F. | 48 | Abortion; retention of part of placenta | Sept. 23, 1876 | Oct. 10, 1876 | Uterus enlarged; inky-coloured patch seen outside at posterior and upper part; inside, corresponding to this, was a shreddy mass of black colour, apparently a retained piece of placenta, stained by perchloride of iron. *Veins.*—Left ovarian contained clot reaching nearly to vena cava; at highest part firm, pale, and non-adherent; lower down firm and adherent; lower still puriform and diffluent at a spot at which a vein from the uterus joined it. *Lungs.*—Congestion and œdema at posterior parts. *Heart* pale and flabby. *Liver* contained bubbles of gas of decomposition; pale and flabby. *Spleen* large and soft; bubbles of gas. *Kidneys* pale, decomposed; no marked staining of intima of vessels; no petechiæ anywhere. Post-mortem 13 hours after death. | |

| | | | | Date of admission. | Date of death. | |
|---|---|---|---|---|---|---|
| | | | | | | of pus. Fracture of left tibia into knee-joint. *Sternum.*—Sloughy condition of fasciæ between pectoralis major and minor; "mousy" odour. Comminuted fracture of sternum bathed in dirty pus. *Heart.*—Petechiæ on left auricle. *Lungs.*—Recent lymph in pleura; sub-pleural petechiæ; small patch of "lobular pneumonia" coated with lymph; central suppuration. *Liver* 97¾ oz., wedge-shaped masses of congestion. *Spleen* soft. *Kidneys* apparently health. |
| 10 | M. | 35 | Amputation of thigh | May 6, 1875 | June 20, 1875 | Abundant breaking-down clot in veins of stump. Both *lungs* contain numerous softening infarcts and "abscesses;" pleura over these inflamed. *Liver* pale and soft. *Spleen* 7½ oz., large, soft, numerous softening infarcts. |
| 11 | F. | 33 | Syphilitic ulceration of rectum | April 1, 1875 | June 14, 1875 | Great emaciation. Extensive ulceration of rectum, sinuses burrowing in all directions. *Veins* of pelvis filled with puriform fluid. *Pleura.*—Some purulent fluid. *Lungs.*—Many pyæmic infarcts, numerous sub-pleural ecchymoses. In right lung the infarcts are softened, and the surface covered with lymph. *Heart.*—Muscular substance soft and mottled, no peri- or endocarditis. *Peritonitis* over spleen. *Spleen* large and soft, numerous infarcts, some softening. *Liver* large and friable. *Kidneys* large and pale. |
| 12 | M. | 23 | Inflammation of corpus spongiosum. Phlebitis, stricture of urethra | Jan. 26, 1876 | Feb. 3, 1875 | Great inflammatory swelling of corpus spongiosum; no suppuration. One of the *veins* about the neck of the bladder full of softening clots, some like grumous pus. *Blood* for the most part fluid, dirty purple colour. *Lungs* congested; in right lung one large and several smaller infarcts. *Pericardium.*—One ounce turbid serum, recent lymph. Surface of *heart* mottled with yellowish softening patches and spots of intense injection. *Liver* soft, friable. *Spleen* 10½ oz., soft. *Kidneys* soft and flabby, a few scattered points of intense redness, with yellow softening centre. |
| 13 | M. | 46 | Perinæal abscess and stricture; incisions | Dec. 26, 1874 | Jan. 17, 1875 | Body much decomposed in 24 hours. Numerous incisions in perineum. *Veins* about neck of bladder contained semi-purulent coagula. *Lungs.*—Infarcts and "one or two abscesses." *Spleen* soft, 7 oz. *Liver* fatty. Recent suppuration on back of hand and about ankle. *Joints* not affected. |

| No. | Sex. | Age. | Primary disease. | Date of invasion. | Date of death. | Duration of case. | Symptoms. | Post-mortem appearances. |
|---|---|---|---|---|---|---|---|---|
| 3 | M. | 42 | Pen-holder in bladder; cystotomy | Nov. 5, 1874 | Nov. 16, 1874 | 11 days | Admitted October 30th, and operated on at once.—Rigor, November 5th, not repeated. A diffuse blush, spreading from the wound to the buttocks, appeared on the 4th. Began to complain of joints on the 7th. Profuse perspirations at first; skin dry at end of case. Profuse diarrhœa. Temp. about 103°, for last week, moderately steady. Icteric tint of skin before death | Median lithotomy wound, surface sloughy. *Veins* dissected out, a large decolorised clot; not breaking down was found in part of the prostatic plexus. *Bladder* inflamed. No pyelitis. *Joints.*—Left elbow, left knee, right knee full of pus. *Muscles.*—Scattered, patches of suppuration in vasti of left thigh, reaching as high as the neck of the femur. The pus had no connection with the veins of the muscle. Pus in the sheaths of the extensor tendons of left arm. *Kidneys* swollen. All *other organs* healthy. No post-mortem staining. No petechiæ |
| 4 | M. | 44 | Stricture of urethra | Mar. 5, 1875 | Mar. 11, 1875 | 6 days | Admitted February 11th, for stricture.—Repeated attempts to pass instruments. 12th.—He had a rigor after the passage of a No. ⅛ silver. March 6th.—Complained of pain over pubes; rigor; sudden rise of temp. to 104·5°; high temp. maintained. Complained of some pain in various joints. Became delirious. Red blush on back of wrist; effusion into joint; same in left wrist | Some false passages. Abscess lying between the triangular ligament and the neck of the bladder. The *prostatic plexus* of veins was implicated in the abscess. Internal iliac contained a softening thrombus. *No visceral abscess. Spleen,* 13 oz., pulpy. *Liver and Kidneys* swollen and pale. Joints not examined after death |
| 5 | M. | 24 | Pericæcal abscess | Sept. 22, 1877 | Oct. 11, 1877 | 19 days | Illness commenced September 21st, with pain, referred to epigastrium, | Slight icteric tint. Early decomposition. Diffuse suppuration in |

| | | | | | | | | |
|---|---|---|---|---|---|---|---|---|
| 3 | M. | 43 | Epithelioma in glands of groin secondary to penis | Feb. 15 (?), 1871 | Feb. 22, 1871 | About one week | Penis amputated November, 1869. Recurrence in glands. Ulceration November, 1870. Had shivering before admission. Right leg swollen. Deep foul ulcers in groin. Six days in hospital. Seven rigors in first four days. None afterwards. Highest temp. recorded 105°. Temp. irregular. High at death, 104°. No other special symptoms noted | Foul sloughy excavation in right groin. *Veins.*—Right femoral inflamed; broken-down reddish débris of clot. No puriform fluid in vein. "Pyæmic abscesses" in both lungs. Left pleura full of offensive pus. *Liver* healthy. *Spleen* swollen and soft. *Kidneys* congested. |
| 4 | M. | 16 | Necrosis of tibia. Amputation of thigh | After Dec. 9 | Dec. 26, 1871 | ? | Admitted for necrosis of tibia, October 13th, 1871. Amputation December 2nd. Discharge offensive after first few days. Did well at first. Afterwards high temperature and rigors. Temp. record lost. Notes imperfect | Emaciated. Skin yellowish, with purple patches. *Stump* swollen. Skin edges of flaps united except opposite bone. Abscess burrowing along bone to small trochanter. Osteo-myelitis and necrosis. Medullary canal putrid. *Veins.*—Profunda full of puriform fluid. Inflamed. Femoral after entrance of the profunda in the same state. *Lungs.*—Numerous softened infarcts. *Other organs* free from infarcts. Albumenoid degeneration. Numerous subserous *petechiæ*. |
| 5 | M. | 36 | Conical stump. Removal of bone from femur | Dec. 19, 1870 | Jan. 1, 1871 | 12 days | Amputation August, 1870. Admitted into hospital November 25th, for unhealed conical stump. December 15.—Stump reopened and two inches of bone cut off. 19th.—A rigor; repeated the same day, and none after that. Temperature high; not very irregular. Osteo-myelitis followed the operation. Pus was let out of the medullary canal by removing some prominent granulations. Notes not perfect | Stump open and unhealed. Bone bare and necrosed; periosteum separated as high as the hip-joint; pus in hip-joint. *Veins.*—Puriform fluid in veins leading from the necrosed bone. Numerous secondary abscesses in *lungs*. *Liver* pale and fatty. Other organs healthy. |

| No. | Sex. | Age. | Primary disease. | Date of admission. | Date of death. | Post-mortem appearances. |
|---|---|---|---|---|---|---|
| 8 | F. | 21 | Tumour of palm of hand; secondary growths in axilla; foul bed-sore | Feb. 22, 1876 | May 11 | Tumour in hand had not been operated on. In the axilla was a sloughy mass of glands. *Pleuræ.*—A little recent lymph in left pleura. *Lungs.*—Grey Hepatisation of lower lobe of left lung. No infarcts. *Pericardium.*—A very little recent lymph. *Liver* fatty. *Spleen* normal size, firm. *Kidneys* pale. *Veins.*—Common iliacs, internal and external iliacs, upper part of femorals and lower end of vena cava filled with adherent decolorised clots softening in the centre to a puriform fluid. Both shoulder *joints* and right elbow disorganised, and filled with offensive pus. Body greatly emaciated. |
| 9 | M. | 36 | Amputation of thigh for suppuration in knee-joint | Nov. 16, 1877 | Nov. 27, 1877 | Wound granulating, flaps deeply undermined. Lower end of shaft of femur bare. Medulla healthy. No general cellulitis of stump. Sheaths of femoral vessels, thickened and infiltrated, but free from pus. Superficial femoral vein firmly plugged by healthy clot at its divided end, above this as far as the first inch of the external iliac vein, the vein is swollen and filled with softened clot, and above this again a solid healthy plug. Internal saphenous and profunda veins also contain partly softened clot as far as the valves, next to the main trunk, beyond this as far as traced empty and healthy. Glands in groin slightly swollen. *Lungs.*—Marked hypostatic congestion, some broncho-pneumonia. *Liver* large, and soft. *Spleen* 8 oz., enlarged, but moderately firm, readily breaking down. *Kidneys* large and pale. *Joints.*—Pus in right shoulder. |

TABLE VII.—GROUP V. *Pyæmia, in which thrombosis and softening of the clot occurred with abscesses in the lungs and in other viscera and tissues.*

| | | | | Date of invasion. | Date of death. | Duration of case. | Symptoms. | Post-mortem appearances. |
|---|---|---|---|---|---|---|---|---|
| 1 | F. | 60 | Compound fracture of radius and ulna | Mar. 23, 1872 | Mar. 30, 1872 | 7 days | An habitual drunkard; bloated. Admitted February 28th, 1872. Had broken the arm the day before. Pus formed and burrowed in all directions. Constitutional symp- | *Stump* unhealed and sloughy. *Veins* deep and superficial, filled with breaking down clots as high as shoulder; no osteo-myelitis. Subserous petechiæ on heart and |

| | | | | | | | | |
|---|---|---|---|---|---|---|---|---|
| | | | | | | | ture little above normal. By March 19th the discharge was very foul; sloughing. Temp. 100°. Dry tongue. Very ill. March 22nd.—Amputation. After the operation there was no improvement. Temp. about 103·5. Tongue dry; drowsy; muttering delirium. Finally diarrhœa and death, March 30th.—No rigors at any time | ing. One secondary abscess in lower lobe of left *lung*. Numerous abscesses in the liver. *Spleen* and *kidneys normal.* |
| 2 | M. | 7 | Disease of hip-joint. Acute necrosis after operation | Oct. 6 | Oct. 27, 1873 | 11 days | Admitted May 27th. Various incisions and gouging operations from time to time. Erysipelas in July. On October 6th the child's temperature rose, and the lips of the wound swelled. 7th.—Whole thigh swelled; temp. 105°; delirium. On 10th, an exploration was made. The whole shaft of the femur was found to be necrosed; periosteum loose everywhere. *Rigor* (the only one) followed this exploration. From this time to death there was a high irregular temperature; delirium; sweet smell of breath; convulsions. 12th.—Discharge very profuse. Progressive loss of strength. 20th.—Jaundice. 27th.—Death | Whole shaft of femur bare; lower epiphysis loose. Knee-joint opened and full of pus. Necrosis quite recent; no new bone under periosteum. *Veins*, one inch from vena cava; a firm red clot. Thin decolorised clot for a little distance. At groin and in upper part of thigh, veins contain puriform fluid. *Lungs.*—Numerous abscesses in both lungs. *Brain.*—Abscess, size of nut in left temporo-sphenoidal lobe. *Other organs* healthy; no petechiæ. No post-mortem staining. |
| 3 | M. | 18 | Wound of knee. Secondary amputation | July 25, 1878 | Aug. 6, 1878 | 12 days | Admitted June 24th. Attempts made to save joint; first by antiseptic treatment; this failed; then by laying the joint freely open on July 8th. Amputation in lower third of thigh, 24th. Boy very weak and emaciated at time. Had had prolonged high fever. On 25th, a rigor which was not re- | Greatly emaciated. *Wound.*—No union, foul, sloughy. *Veins* plugged as high as groin. Puriform fluid in common femoral, in centre of adherent decolorised clot. Veins from bone quite healthy. *Bone.*—Lower inch necrosed; medulla gangrenous for some distance; no general osteo-myelitis. |

| No. | Sex. | Age. | Primary disease. | Date of invasion. | Date of death. | Duration of case. | Symptoms. | Post-mortem appearances. |
|---|---|---|---|---|---|---|---|---|
| 11 | F. | 36 | Strumous arthritis of elbow; amputation | April 5, 1876 | April 8, 1876 | 3 days | Admitted March 29th; inflammation of elbow; patient much emaciated. On April 2nd a free incision was made and much pus let out; patient very ill. Amputation on April 3rd; no rigors; profuse sweating; irregular temperature, highest 104°. Gradually sank and died April 8th | *Stump.*—No union of flaps; basilic vein up to axilla full of green pus; brachial veins healthy. *Lungs.*—Numerous pyæmic abscesses in both lungs. *Liver* pale. *Spleen* large, soft, and swollen. *Kidneys* swollen. Other organs healthy. |
| 12 | M. | 38 | Compound fracture of skull; wound of lateral sinus | Aug. 19, 1876 | Sept. 15, 1876 | 26 days | Admitted August 16th; compound depressed fracture of skull; wound of lateral sinus; depressed fragment removed and sinus plugged; plugs became foul. Violent rigor on 19th, repeated on 20th; plugs removed, bleeding returned; plug replaced. No rigor till 24th. From this time till death there were repeated rigors—39 in all—sometimes three a day; he had also over 100 epileptiform convulsions, chiefly during the early part of the case; no marked symptoms beyond the rigors and gradually increasing emaciation and weakness; temp. very irregular, highest 107°, lowest 95° | *Wound* sloughy; dura mater commencing to slough opposite wound; no general meningitis; large foul abscess in neck. *Veins.*—Lateral sinus full of débris of a putrid, broken-down clot; the plugs had been put actually into the sinus; the phlebitis and suppuration had extended through the mastoid foramen and caused the foul abscess in the neck; jugular healthy. *Lungs.*—Numerous pyæmic abscesses, varying in size from pins' head to filbert, chiefly in lower lobes; slight pleurisy. *Liver* healthy. *Spleen* soft and swollen. *Kidneys* swollen. |
| 13 | M. | 49 | Old buboes | Nov. 3, 1873 | Nov. 8, 1873 | 5 days | Chancre three months ago. Admitted for buboes September 2nd. 3rd.—Laid freely open. 10th.—Incision on right side; apparently doing well. Attacked by erysipelas 30th; left very weak after the erysipelas disappeared; abscesses | The abscesses had burrowed into pelvis and towards hip-joint. *Veins.*—Large softening clot in internal iliac. *Heart* soft and fatty. *Lungs.*—Pyæmic abscesses in right only. *Liver* fatty. *Spleen* large and firm. Other organs healthy. |

| | | | | | | | | |
|---|---|---|---|---|---|---|---|---|
| | | | | | | | burrowed towards pelvis; wounds foul and sloughy. Rigors November 3 (2), not repeated; temp. 106·5°, irregular. Died November 8th; no special symptoms noted | |
| 14 | M. | 7½ | Double hip disease; excision of left hip | ? | Dec. 7, 1874 | — | Admitted October 16th; double hip disease. 17th.—Abscess opened left. 28th.—Excision of left hip; wounds foul; much discharge. November 12th.—Erysipelas; this disappeared. Elevation of temp. 103° November 29th. Bedsores; gradual exhaustion | Excision surface rough and carious; right joint almost destroyed. *Femoral vein* on right side plugged to ham; on left side profunda full of softened clot, femoral plugged with firm clot. *Lungs.*—Lower lobes on both sides contain numerous softening infarcts. Other organs healthy. |
| 15 | M. | 18 | Exostosis of lower end of femur; suppuration of knee; secondary amputation of thigh; bedsore | Feb. 13, 1874 | Feb. 19, 1874 | 6 days | Admitted December 6th, 1873. Exostosis removed on the 10th. Pus found in ham, and somehow got into the knee-joint. Acute destructive inflammation of knee; temperature averaged about 102°, steady; rapid emaciation; discharge abundant. Amputation above knee. February 5th.—Large bedsore. *Rigors.*—On the 13th two, 15th two. Died 19th. No other special symptoms noted | *Stump.*—Slight superficial union. *Bones* and *veins* healthy. *Foul sloughy bedsore* over sacrum; veins leading from this to internal iliac full of puriform fluid. A softening thrombus projected from internal into common iliac. *Lung.*—Five small softening infarcts in left lung; none in right; some subpleural petechiæ. *Other viscera* healthy. |
| 16 | M. | 21 | Old disease of knee; abscess in thigh; amputation at hip | Jan. 16, 1870 | Jan. 26, 1870 | 10 days | Admitted September 29th. Knee injured a year before. Extensive suppuration in thigh; abscesses opened. Had erysipelas in November. Amputation at hip January 10th. Vomiting for several days, but rallied from shock of operation. 20th.—Pain in course of iliac vessels; no repair of wound. 24th.—Slight convulsions; rapid respiration; cough. No rigors recorded | *Wound.*—Little union, surfaces of flaps sloughy in many parts. *Veins.*—Femoral contained "pus," clothing extended up to the common iliac, upper end not breaking down. *Bones.*—Acetabulum rough and eroded. *Lungs.*—Softening infarcts in left lung; none in right. *Liver* fatty. *Spleen* tolerably consistent. *Kidneys* swollen, some small isolated patches of congestion. |

| No. | Sex. | Age. | Primary disease. | Date of invasion. | Date of death. | Duration of case. | Symptoms. | Post-mortem appearances. |
|---|---|---|---|---|---|---|---|---|
| 8 | F. | 34 | Small bony tumour removed from zygoma | Feb. 27, 1877 | Mar. 3, 1877 | 4 days | Small bony tumour in front of right ear, six years growth. Admitted February 7th, 1877. Tumour removed on the 15th; profuse hæmorrhage; great difficulty in securing vessel. Did very well till the 27th; wound almost healed; suddenly seized with dyspnœa; loss of power in legs. 28th.—Complete paralysis of left side; temp. 102·2°. March 1st.—Red swelling on back of right wrist; temp. 103°. 3rd.—Partially comatose; no rigors noted | *Wound* apparently healthy. *Veins.*—Softening clot in facial vein extending into jugular. *Heart* 14 oz., in inter-ventricular septum a small abscess by side of a vessel. Aortic valves "seat of ulcerative disease;" from the apex of two of them depended one clot as large as an almond. The endocardium was ulcerated over an area as large as a sixpence. *Lungs.*—Right, incipient pneumonia of lower lobe; left œdematous; three "pyæmic abscesses." *Liver* soft. *Spleen* 14 oz., one secondary abscess. *Kidneys* 12 oz., yellow infarct in left. *Brain.*—Purulent arachnitis right side; right middle cerebral plugged at division; tissue round softened; small abscess over right corpus striatum. |
| 9 | M. | 39 | Compound fracture of right tibia and fibula. Secondary amputation. Simple fracture of left leg and sternum | Oct. 6, 1877 | Oct. 13, 1877 | 7 days | Admitted September 22nd. Profuse suppuration of fracture; rapid loss of strength. Bed sores on the 30th. October 6th.—Three rigors; temp. 105°. 7th.—Amputation at knee. 8th.—Rigor. 9th.—Rigor; "wound fairly healthy." 11th.—Discharge very offensive; wound not so well. 12th.—Rigor; tongue dry and brown. Died on the 13th | *Wound.*—No union; very foul. *Veins.*—Femoral vein in Hunter's canal plugged, and small vessels in neighbourhood of vein filled with pus. *Inguinal glands* on right side enlarged. In cellular tissue of right iliac fossa, and in that surrounding the psoas muscles as high as the kidney, and in psoas itself, recent extravasations of blood. *Joints.*—Right knee full of pus. *Left saphenous vein* full |

| | | | | | | | | |
|---|---|---|---|---|---|---|---|---|
| 20 | M. | 32 | Compound fracture of tibia and fibula | June 4, 1877 | June 6, 1877 | 2 days | Admitted May 16th. Water dressing. Was a healthy man. Delirious till 20th; then did well till June 24th; sudden rise of temp. to 103·4°; 28th.—Wound unhealthy; œdema of limb. 4th.—Rigor, repeated same day. 5th.—Discharge less, then another *rigor*. Amputation through knee. Posterior tibial vein plugged; popliteal the same. Became drowsy; breathing laboured. Died twenty-eight hours after amputation. Temp. at time of death 104° | Body well nourished. *Wound.*—Flaps ecchymosed. *Veins* plugged up to external iliac. *Glands.*—Swollen in groin. *Heart.*—Slight excess of pericardial fluid; subpericardial petechiæ. A few recent firmly adherent vegetations on mitral valve. *Lungs.*—Large branch of left pulmonary artery plugged with recent clot; numerous subpleural extravasations. In lower lobe of left lung a patch of lobular pneumonia, with vessel plugged. Lung generally œdematous, with numerous small arteries plugged with decolorised clot. *Liver.*—Gorged with blood. *Spleen.*—Large, almost diffluent. *Kidneys.*—Large, smooth, soft. |
| 21 | F. | 3½ | Disease of hip-joint; diphtheria; acute osteomyelitis of femur | Mar. 28, 1871 | April 1, 1871 | 3 days | Admitted January 24th, 1871. Miserable emaciated child. Abscess opened. Continued discharge. (No temperature record.) March 28th.—Child very ill; thick discharge from nose. 29th.—Discharge from nose and ears; sweating; high temperature. 31st.—Large purpuric spots on legs. April 1st.—Died | Post-mortem 8 hours after death. Decomposition commenced; purpuric spots all over body. *Wound.*—Sinuses about hip. Joint disorganised. Whole periosteum of femur loose; medullary canal full of pus. *Veins.*—Femoral up to entrance of profunda full of puriform fluid. *Lungs.*—Three or four recent infarcts. *Kidneys.*—Pale and large. *Pharynx, &c.*—Areolar tissue about pharynx œdematous. Mucous membrane of nose, pharynx, larynx, and trachea covered with typical diphtheritic false membrane. *Uterus.*—Surrounded by clot ⅞ths inch thick. |

TABLE VIII.—*Pyæmia.* GROUP VI. *Cases in which thrombosis and softening of the clot occurred with secondary abscesses only in the lung.*

| No. | Sex. | Age. | Primary disease. | Date of invasion. | Date of death. | Duration of case. | Symptoms. | Post-mortem appearances. |
|---|---|---|---|---|---|---|---|---|
| 1 | M. | 54 | Necrosis of femur | Oct. 6, 1877 | Oct. 12, 1877 | 6 days | Disease of lower end of left femur for thirty-five years. Twenty years ago some necrosed bone was removed. Sinus never healed. Lately discharge and pain increased. Admitted September 17th, 1877. October 3rd.—Operation under chloroform. 5th.—Discharges very foul. 6th.—Temp. rose to 103·8°. 7th.—Rigor, temp. 105·8°. 9th.—Swelling of left calf. 10th.—Two rigors. Irregular temp., 99·2° to 103·2°. Pyæmic odour. Tongue dry. 12th.—He died | Left leg much swollen. No petechiæ. Glands in groin swollen. *Veins.*—Superficial femoral healthy till entrance of veins from bone. Then filled with softening creamy clot. *Lungs.*—Numerous pyæmic infarcts softening. None in left. *Heart.*—Subpericardial petechiæ. *Spleen* large, not soft. *Kidneys* swollen. |
| 2 | M. | 18 | Amputation of thigh for disease of knee | June 12, 1877 | June 20, 1877 | 8 days | Amputation of thigh for disease of knee, May 26th. Severe hæmorrhage on 27th. From the effects of this he gradually recovered, and the stump began to heal. On June 12th he had a severe rigor, and from that time till his death the case followed the ordinary course. Repeated rigors at irregular intervals. High temperature; irregular. Gradual emaciation and exhaustion; sweating; delirium | Amputation of left thigh in lower third. *Stump* swollen. Wound nearly united, only a few sinuses left. End of bone necrosed in lower half inch. Periosteum separated from bone, along whole of shaft, by offensive pus, as high as hip, which is full of pus. Marked osteo-myelitis. *Veins* from bone filled with softening puriform clot; femoral at entrance of profunda contains similar clot; elsewhere healthy. *Glands* in groin swollen. *Lungs.*—Softening infarcts in |

| | | | | | | | | |
|---|---|---|---|---|---|---|---|---|
| 3 | M. | 43 | Epithelioma in glands of groin secondary to penis | Feb. 15 (?), 1871 | Feb. 22, 1871 | About one week | Penis amputated November, 1869. Recurrence in glands. Ulceration November, 1870. Had shivering before admission. Right leg swollen. Deep foul ulcers in groin. Six days in hospital. Seven rigors in first four days. None afterwards. Highest temp. recorded 105°. Temp. irregular. High at death, 104°. No other special symptoms noted | Foul sloughy excavation in right groin. *Veins.*—Right femoral inflamed; broken-down reddish débris of clot. No puriform fluid in vein. "Pyæmic abscesses" in both lungs. Left pleura full of offensive pus. *Liver* healthy. *Spleen* swollen and soft. *Kidneys* congested. |
| 4 | M. | 16 | Necrosis of tibia. Amputation of thigh | After Dec. 9 | Dec. 26, 1871 | ? | Admitted for necrosis of tibia, October 13th, 1871. Amputation December 2nd. Discharge offensive after first few days. Did well at first. Afterwards high temperature and rigors. Temp. record lost. Notes imperfect | Emaciated. Skin yellowish, with purple patches. *Stump* swollen. Skin edges of flaps united except opposite bone. Abscess burrowing along bone to small trochanter. Osteo-myelitis and necrosis. Medullary canal putrid. *Veins.*—Profunda full of puriform fluid. Inflamed. Femoral after entrance of the profunda in the same state. *Lungs.*—Numerous softened infarcts. *Other organs* free from infarcts. Albumenoid degeneration. Numerous subserous *petechiæ*. |
| 5 | M. | 36 | Conical stump. Removal of bone from femur | Dec. 19, 1870 | Jan. 1, 1871 | 12 days | Amputation August, 1870. Admitted into hospital November 25th, for unhealed conical stump. December 15.—Stump reopened and two inches of bone cut off. 19th.—A rigor; repeated the same day, and none after that. Temperature high; not very irregular. Osteo-myelitis followed the operation. Pus was let out of the medullary canal by removing some prominent granulations. Notes not perfect | Stump open and unhealed. Bone bare and necrosed; periosteum separated as high as the hip-joint; pus in hip-joint. *Veins.*—Puriform fluid in veins leading from the necrosed bone. Numerous secondary abscesses in *lungs*. *Liver* pale and fatty. Other organs healthy. |

| No. | Sex. | Age. | Primary disease. | Date of invasion. | Date of death. | Duration of case. | Symptoms. | Post-mortem appearances. |
|---|---|---|---|---|---|---|---|---|
| 6 | M. | 20 | Conical stump. Reamputation through the knee | Dec. 25, 1870 | Dec. 30, 1870 | 5 days | Amputation at knee by long anterior flap. December 22nd.—Intermediary hæmorrhage; flap sloughed on third day. Pus formed in the synovial pouches of knee, and was pent up in them; offensive smell. First rigor 25th. On 28th was delirious. 29th.—Pleurisy diagnosed. 30th he died. Temp. high (104°), irregular | *Stump* sloughy and unhealed. Foul abscess burrowing up thigh. *Veins.*—Femoral opened on face of stump unclosed. It contained yellow pus-like fluid, containing leucocytes and innumerable granules. This extended to two inches below entrance of profunda, where was a soft, slightly adherent clot. Walls of veins inflamed. *Lungs.*—Numerous pyæmic abscesses in both lower lobes. Pint of yellow fluid in left pleura. |
| 7 | M. | 36 | Compound fracture of femur. Fissures into knee-joint | Feb. 11, 1871 | Feb. 23, 1871 | 12 days | Small wound closed with collodion. Admitted January 27th. The wound did not close; there was free suppuration. Temp. rose to 103° on February 11th, with a rigor. Steady high temp., 103° to 104°, till 16th; rigor on 16th; three rigors on 17th; one rigor on 20th. Died on 23rd. Thigh much swollen; tenderness in left groin. Delirium; smell of breath, &c. | Wound open. Pus burrowing amongst the muscles of the thigh. *Veins.*—Popliteal, femoral, and iliacs to vena cava plugged; in the iliacs the clots were recent and non-adherent; lower down adherent and softening; small veins of thigh filled with puriform fluid; coats of veins inflamed. *Bone* healthy. *Knee-joint* opened by the fracture; full of pus. Numerous pyæmic abscesses in both lungs. *Liver* healthy. *Kidneys* swollen. *Spleen* mottled, not unnaturally soft. |
| 8 | M. | 39 | Compound fracture of fibula | Feb. 3, 1871 | Mar. 7, 1871 | 32 days | Admitted January 12th. Wound three inches long on outer side of leg. Fracture of fibula; went on well till February 3rd; slight shiver. Rigors 4th, 5th, 6th, 7th, (2), 16th. Temperature not very | Large abscess between superficial and deep muscles. Pus very offensive. *Bone* ununited; no osteomyelitis. No necrosis. *Veins.*—Femoral immediately below entrance of profunda plugged with |

| | | | | | | | | |
|---|---|---|---|---|---|---|---|---|
| | | | | | | | discharge profuse; some burrowing of pus. Pneumonia was diagnosed on 16th; pleurisy on 11th. Delirium with progressive loss of flesh and strength were the only symptoms noted. Temperature fell before death to normal | fluid. Below, the veins were filled with puriform fluid; this fluid contained numerous leucocytes and granular matter. *Lungs.*—Numerous abscesses in both lungs. Many had burst into pleura. Offensive pus in both pleuræ. Post-mortem twenty-four hours after death. Weather cold. |
| 9 | M. | 37 | Ununited fracture of tibia. Ends of bone excised | Feb. 9, 1874 | Feb. 18, 1874 | 9 days | Admitted January 27th, 1874. Resection of bone February 4th. Erysipelas appeared on 9th, and continued to spread till death. No rigors. Temperature record lost. The erysipelas was apparently simple cutaneous | *Wound* sloughy. *Veins.*—External iliac and femoral as low as profunda filled with adherent, firm, decolorised clot; profunda in same state. Below this in places the clot had broken down into a puriform fluid. *Bones.*—Osteo-myelitis of upper fragment. *Lungs.*—Numerous secondary abscesses. *Liver* pale. *Spleen* large, soft, pale. *Kidneys* swollen and pale. |
| 10 | M. | 9 | Disease of hip-joint. Excision | Nov. 20, 1874 (?) | Nov. 26, 1874 | 6 days | Admitted April 24th, 1874. Deep abscess over hip-joint; aspirated three times; then opened; prolonged suppuration. Temperature above normal, usually about 100·5°. November 19.—Excision of hip. After the operation the temperature rose to 104°. During the following days the temperature was irregular, but no rigors were noticed | *Wound* sloughy and foul. Abscesses burrowing in various directions. *Veins.*—Inflamed from external iliac to knee. The clot in parts breaking down into puriform fluid. This condition extends into the profunda. *Bone.*—The whole shaft of the femur is bare of periosteum; medulla gangrenous. *Lungs.*—In middle of upper lobe of right lung is a "pyæmic abscess." In the lower lobe of the left lung is an area of "diffused pneumonia." *Liver* albuminoid. *Spleen* pale and firm. *Kidneys* pale. |

| No. | Sex. | Age. | Primary disease. | Date of invasion. | Date of death. | Duration of case. | Symptoms. | Post-mortem appearances. |
|---|---|---|---|---|---|---|---|---|
| 11 | F. | 36 | Strumous arthritis of elbow; amputation | April 5, 1876 | April 8, 1876 | 3 days | Admitted March 29th; inflammation of elbow; patient much emaciated. On April 2nd a free incision was made and much pus let out; patient very ill. Amputation on April 3rd; no rigors; profuse sweating; irregular temperature, highest 104°. Gradually sank and died April 8th | *Stump.*—No union of flaps; basilic vein up to axilla full of green pus; brachial veins healthy. *Lungs.*—Numerous pyæmic abscesses in both lungs. *Liver* pale. *Spleen* large, soft, and swollen. *Kidneys* swollen. Other organs healthy. |
| 12 | M. | 38 | Compound fracture of skull; wound of lateral sinus | Aug. 19, 1876 | Sept. 15, 1876 | 26 days | Admitted August 16th; compound depressed fracture of skull; wound of lateral sinus; depressed fragment removed and sinus plugged; plugs became foul. Violent rigor on 19th, repeated on 20th; plugs removed, bleeding returned; plug replaced. No rigor till 24th. From this time till death there were repeated rigors—39 in all—sometimes three a day; he had also over 100 epileptiform convulsions, chiefly during the early part of the case; no marked symptoms beyond the rigors and gradually increasing emaciation and weakness; temp. very irregular, highest 107°, lowest 95° | *Wound* sloughy; dura mater commencing to slough opposite wound; no general meningitis; large foul abscess in neck. *Veins.*—Lateral sinus full of débris of a putrid, broken-down clot; the plugs had been put actually into the sinus; the phlebitis and suppuration had extended through the mastoid foramen and caused the foul abscess in the neck; jugular healthy. *Lungs.*—Numerous pyæmic abscesses, varying in size from pins' head to filbert, chiefly in lower lobes; slight pleurisy. *Liver* healthy. *Spleen* soft and swollen. *Kidneys* swollen. |
| 13 | M. | 49 | Old buboes | Nov. 3, 1873 | Nov. 8, 1873 | 5 days | Chancre three months ago. Admitted for buboes September 2nd. 3rd.—Laid freely open. 10th.—Incision on right side; apparently doing well. Attacked by erysipelas 30th; left very weak after the | The abscesses had burrowed into pelvis and towards hip-joint. *Veins.*—Large softening clot in internal iliac. *Heart* soft and fatty. *Lungs.*—Pyæmic abscesses in right only. *Liver* fatty. *Spleen* large and firm. |

| | | | | | | | | |
|---|---|---|---|---|---|---|---|---|
| | | | | | | | burrowed towards pelvis; wounds foul and sloughy. Rigors November 3 (2), not repeated; temp. 106·5°, irregular. Died November 8th; no special symptoms noted | |
| 14 | M. | 7½ | Double hip disease; excision of left hip | ? | Dec. 7, 1874 | — | Admitted October 16th; double hip disease. 17th.—Abscess opened left. 28th.—Excision of left hip; wounds foul; much discharge. November 12th.—Erysipelas; this disappeared. Elevation of temp. 103° November 29th. Bedsores; gradual exhaustion | Excision surface rough and carious; right joint almost destroyed. *Femoral vein* on right side plugged to ham; on left side profunda full of softened clot, femoral plugged with firm clot. *Lungs.*—Lower lobes on both sides contain numerous softening infarcts. Other organs healthy. |
| 15 | M. | 18 | Exostosis of lower end of femur; suppuration of knee; secondary amputation of thigh; bedsore | Feb. 13, 1874 | Feb. 19, 1874 | 6 days | Admitted December 6th, 1873. Exostosis removed on the 10th. Pus found in ham, and somehow got into the knee-joint. Acute destructive inflammation of knee; temperature averaged about 102°, steady; rapid emaciation; discharge abundant. Amputation above knee. February 5th.—Large bedsore. *Rigors.*—On the 13th two, 15th two. Died 19th. No other special symptoms noted | *Stump.*—Slight superficial union. *Bones* and *veins* healthy. *Foul sloughy bedsore* over sacrum; veins leading from this to internal iliac full of puriform fluid. A softening thrombus projected from internal into common iliac. *Lung.*—Five small softening infarcts in left lung; none in right; some subpleural petechiæ. *Other viscera* healthy. |
| 16 | M. | 21 | Old disease of knee; abscess in thigh; amputation at hip | Jan. 16, 1870 | Jan. 26, 1870 | 10 days | Admitted September 29th. Knee injured a year before. Extensive suppuration in thigh; abscesses opened. Had erysipelas in November. Amputation at hip January 10th. Vomiting for several days, but rallied from shock of operation. 20th.—Pain in course of iliac vessels; no repair of wound. 24th.—Slight convulsions; rapid respiration; cough. No rigors recorded | *Wound.*—Little union, surfaces of flaps sloughy in many parts. *Veins.*—Femoral contained "pus," clothing extended up to the common iliac, upper end not breaking down. *Bones.*—Acetabulum rough and eroded. *Lungs.*—Softening infarcts in left lung; none in right. *Liver* fatty. *Spleen* tolerably consistent. *Kidneys* swollen, some small isolated patches of congestion. |

| No. | Sex. | Age. | Primary disease. | Date of invasion. | Date of death. | Duration of case. | Symptoms. | Post-mortem appearances. |
|---|---|---|---|---|---|---|---|---|
| 17 | M. | 45 | Gonorrhœa; cystitis; diffuse cellulitis of scrotum; suppuration in left spermatic cord; orchitis | May 1, 1874 | May 19, 1874 | 18 days | Admitted April 24th. Extensive suppuration in scrotum and along left spermatic cord. Severe rigor May 1st | *Lungs* congested and œdematous, with pyæmic patches. Abscess in *prostatic plexus of veins*, and in cellular tissue of left iliac region. Grey tubercle in lungs, cheesy matter in left cord. |
| 18 | M. | 13 | Round - celled sarcoma of fore-arm; amputation of arm | Feb. 28, 1872 | Mar. 9, 1872 | 9 days | Admitted Februrary 3rd. Amputation on the 8th. Went on well till the 15th. Secondary hæmorrhage; flaps opened up; then went on well till the 28th, when temperature suddenly rose to 104°; no rigor. Temperature remained high and irregular; highest 106·4° lowest 102°. Tongue dry; sweating freely at intervals, but no rigor till March 8th, not repeated. Pain in chest; friction heard both sides; delirium; emaciation. No diarrhœa; discharge very offensive | *Wound* unhealed, flaps covered by feeble granulations. *Bones.*—Periosteum completely separated, acute osteo-myelitis, suppuration of medulla; pus in shoulder-joint of affected side. *Veins* leading from bone full of broken-down clot; divided end in stump healthy. *Lungs* full of secondary abscesses. *Spleen* and *kidneys* slightly swollen and congested. Other organs healthy. |
| 19 | M. | 54 | Retention of urine; stricture; puncture of bladder by rectum; external urethrotomy | June 26, 1877 | June 29, 1877 | 3 days | Admitted June 21st, 1878. No instrument could be passed. Bladder punctured from rectum. Temperature slowly and steadily rose till 25th, when it reached 103°. Tongue white and moist; bowels relaxed. 26th.—External urethrotomy; *rigor* in the evening. 27th.—Temp. 100°; seemed better. 28th.—Profuse hæmorrhage from rectum. 29th.—Died | A foul sloughy cavity was found between the bladder and rectum. The *veins* were involved in the sloughy mass, but could not be dissected out. *Lungs.*— "Secondary abscesses." All other organs healthy. |

| | | | | | | | | |
|---|---|---|---|---|---|---|---|---|
| 20 | M. | 32 | Compound fracture of tibia and fibula | June 4, 1877 | June 6, 1877 | 2 days | Admitted May 16th. Water dressing. Was a healthy man. Delirious till 20th; then did well till June 24th; sudden rise of temp. to 103·4°; 28th.—Wound unhealthy; œdema of limb. 4th.—Rigor, repeated same day. 5th.—Discharge less, then another *rigor*. Amputation through knee. Posterior tibial vein plugged; popliteal the same. Became drowsy; breathing laboured. Died twenty-eight hours after amputation. Temp. at time of death 104° | Body well nourished. *Wound.*—Flaps ecchymosed. *Veins* plugged up to external iliac. *Glands.*—Swollen in groin. *Heart.*—Slight excess of pericardial fluid; subpericardial petechiæ. A few recent firmly adherent vegetations on mitral valve. *Lungs.*—Large branch of left pulmonary artery plugged with recent clot; numerous subpleural extravasations. In lower lobe of left lung a patch of lobular pneumonia, with vessel plugged. Lung generally œdematous, with numerous small arteries plugged with decolorised clot. *Liver.*—Gorged with blood. *Spleen.*—Large, almost diffluent. *Kidneys.*—Large, smooth, soft. |
| 21 | F. | 3½ | Disease of hip-joint; diphtheria; acute osteomyelitis of femur | Mar. 28, 1871 | April 1, 1871 | 3 days | Admitted January 24th, 1871. Miserable emaciated child. Abscess opened. Continued discharge. (No temperature record.) March 28th.—Child very ill; thick discharge from nose. 29th.—Discharge from nose and ears; sweating; high temperature. 31st.—Large purpuric spots on legs. April 1st.—Died | Post-mortem 8 hours after death. Decomposition commenced; purpuric spots all over body. *Wound.*—Sinuses about hip. Joint disorganised. Whole periosteum of femur loose; medullary canal full of pus. *Veins.*—Femoral up to entrance of profunda full of puriform fluid. *Lungs.*—Three or four recent infarcts. *Kidneys.*—Pale and large. *Pharynx, &c.*—Areolar tissue about pharynx œdematous. Mucous membrane of nose, pharynx, larynx, and trachea covered with typical diphtheritic false membrane. *Uterus.*—Surrounded by clot ¼ths inch thick. |

| No. | Sex. | Age. | Primary disease. | Date of admission. | Date of death. | Post-mortem appearances. |
|---|---|---|---|---|---|---|
| 22 | M. | 19 | Abscess of internal ear; phlebitis of right lateral sinus and internal jugular vein | Jan. 15, 1877 | Jan. 16, 1877 | Dura mater over petrous portion of temporal bone swollen; ashy grey. Small quantity of lymph in cavity of arachnoid. Subarachnoid fluid turbid. *Veins.*—Right lateral sinus from torcular full of puriform fluid. Right jugular vein inflamed, coats thickened; small adherent coagula on surface; no large adherent coagula. *Pleuræ.*—Full of offensive purulent fluid. *Lungs.*—Contain very numerous softening infarcts. *Spleen* 9¼ oz., swollen, soft. *Kidneys.*—Swollen cortex. |
| 23 | M. | 36 | Compound fracture, with depression of left parietal bone | Sept. 17, 1877 | Sept. 27, 1877 | Fracture of skull had been trephined, bone around bare and necrosed. Dura mater wounded. "Purulent matter" over whole left hemisphere. Right lateral sinus contains decolorised and puriform clot. Several fractured ribs on left side. *Left pleura* full of offensive pus. *Right lung* gorged with blood. No infarcts. *Left lung* collapsed; numerous pyæmic abscesses. *Spleen* very large and soft. *Kidneys* swollen. *Liver* pale and soft. |
| 24 | M. | 32 | Compound dislocation; secondary amputation through elbow | Mar. 27 | April 17 | Wound ununited. Pus burrowing up arm. Brachial artery normal. In the middle of the arm a branch joining the basilic vein is filled with decolorised and partly softened clot. *Lungs.*—Marked hypostatic congestion. Numerous infarcts in both lungs, commencing to soften; chiefly in lower lobes. Slight pleurisy over the softening infarcts. *Liver* large and fatty. *Spleen* 10 oz; very large and soft. *Kidneys* swollen. |

TABLE IX.—GROUP VII. *Acute necrosis, or infective periostitis.*

| No. | Sex. | Age. | Primary disease. | Date of invasion. | Date of death. | Duration of case. | Symptoms. | Post-mortem appearances. |
|---|---|---|---|---|---|---|---|---|
| 1 | M. | 16 | Acute necrosis of femur | Aug. 7, 1874 | Aug. 12, 1874 | 5 days | Taken suddenly ill on the 7th. Pain in limbs. Delirious. 9th.—Kept bed from onset. Right leg amputated two years before for disease following a blow. Admitted on the 10th. Swelling and redness of right arm from shoulder to wrist; delirious. Temp. 108·9° to 106°. Swelling of left knee and thigh. Rapidly sank and died Aug. 12th | Post mortem twelve hours after death. Serous fluid in left knee. Serous infiltration of muscles of thigh. Two thirds of length of femur bare, and surrounded by pus. No necrosis in arm. Excess of synovia in elbow and wrist. Veins of limbs healthy. *Pericardium.*—Abundant recent lymph. *Heart.*—Substance inflamed. Abscess commencing to form in one part. *Lungs.*—One small abscess in right lung. *Spleen* 4 oz., soft. *Blood* from heart dark maroon colour. No bacteria to be found in it. |
| 2 | M. | 16 | Acute necrosis of humerus | Sept. 15, 1877 | Sept. 26, 1877 | 11 days | Sudden invasion on 15th; severe headache. Better on 16th. On 19th herpes appeared on lips, and pain in shoulders. No rigors. On 21st was seen by a doctor, who diagnosed acute rheumatism. Delirious at night. Swelling of arm not noticed till 24th. Arm swollen from elbow to shoulder. Temperature 103°, great prostration; temperature gradually rose to 108° on 26th, shortly before death; no great variations; sweating; no incisions in arm; trace of albumen in urine | Post mortem eighteen hours after death. No superficial petechiæ. Swelling of *left arm.* Tissues infiltrated with serum. Periosteum separated from upper two thirds of humerus by grumous offensive pus. Shoulder-joint and line of epiphysis healthy. Small subperiosteal abscess close to elbow. Elbow full of pus, not offensive. Medulla free from pus. *Veins.*—Veins of arm as high as axilla and as low as bend of elbow full of puriform clot. *Pleuræ.*—Recent lymph. *Lungs* gorged with blood, |

| No. | Sex. | Age. | Primary disease. | Date of invasion. | Date of death. | Duration of case. | Symptoms. | Post-mortem examination. |
|---|---|---|---|---|---|---|---|---|
| | | | | | | | | numerous infarcts, mostly hæmorrhagic, a few softening. *Pericardium.* — Numerous petechiæ, recent pericarditis. *Heart.*—Numerous patches of inflammation in muscular substance. One or two small abscesses in wall of left ventricle. *Spleen* 7½ oz., somewhat swollen. One small abscess. *Kidneys* swollen. Two minute points of pus. |
| 3 | M. | 19 | Acute necrosis of ulna and humerus | Feb. 2, 1878 | Feb. 16, 1878 | 14 days | February 2nd. — Complained of pain in right *wrist;* no injury. Swelling of arm on the 10th. Admitted on the 11th. Pus evacuated from tissues about *elbow*-joint. Temp. 100·2°. Temperature on 16th 104°. No rigors. Notes imperfect | Two recent incised wounds on outer side of right forearm. Fœtid purulent infiltration of muscles of forearm. Middle third of ulna entirely deprived of periosteum. Lower two inches of humerus also bare. *Veins* of forearm full of "pus." Veins of arm in similar condition. *Glands* in axilla swollen. *Joints.*—Pus in right elbow and shoulder. *Lungs* slightly œdematous and congested. *Liver* pale. *Spleen* 5½ oz., natural. *Kidneys* pale. Other viscera normal. |
| 4 | | 16 | Acute necrosis of left tibia | Probably Jan. 10, 1878 | Jan. 16, 1878 | 6 days | No history of injury or acute specific fever. January 5th.—Felt pain in legs. 7th.—Took to bed; treated for rheumatism; no rigors. Admitted on the 11th. Very ill; acute pain in right side; tongue red; pulse feeble. Left leg swollen; œdematous. Femoral | Post mortem five and a half hours after death. Wounds perfectly free from any odour of decomposition. Quite clean. Pus alkaline. Left *saphena vein* full of grumous, broken-down clot, containing no leucocytes. Multitudes of granules and some moving organ- |

| | | | | | | | | |
|---|---|---|---|---|---|---|---|---|
| | | | | | | | glands enlarged. Saphena vein at inner side of knee; marked out by superficial redness; plugged with clot. Urine healthy. Free incisions. Whole tibia bare. Pus red. *No organisms* to be detected in it. *Temperature* steady, between 102° and 103°. *Blood examined* on the 13th and 14th. *No organisms.* Red corpuscles form masses and not rouleaux. No vomiting; no diarrhœa; delirium; convulsions. During last twelve hours of life temperature rose from 102° to 105°. Died at 5.30. At 6.30 temperature had risen from 105° to 108·9° | isms. *Glands* in groin swollen. Left tibia in greater part bare. Lower epiphysis loose. *Heart.*—Numerous subpericardial petechiæ at back of heart. *Lungs.*—Numerous softening infarcts in both lungs. *Liver* slightly swollen and soft. *Spleen* not abnormally soft or large. *Intestines* healthy. *Kidneys.*—Numerous infarcts, some softening. *Blood* from right auricle at post mortem contained moving jointed organisms. *Joints.*—Left knee and ankle and right elbow full of pus. |
| 5 | M. | 8 | Acute necrosis of tibia | ? | [Mar. 4 | ? | Admitted February 8th. Acute periostitis following slight injury. Pale, thin. Pulse 140. Fluctuation over whole tibia. Effusion in knee. Incision. 11th.—Another incision. 24th.—Amputation refused by parents. March 4th.—He died | *Bone.*—Greater part of tibia bare. Some new bone forming in places beneath the periosteum. *Lung.*—Several secondary abscesses in lung. Foul pus in left pleura. *Kidneys* congested. *Other organs* healthy. Blood fluid twenty hours after death. |
| 6 | F. | 15 | Acute necrosis of tibia | ? | Jan. 11, 1874 | ? | Admitted January 2nd. High temperature. Abscess opened. No rigors noted | *Bone.*—A small extravasation of blood beneath the periosteum. Suppuration in medulla opposite this point. Another patch of inflamed medulla near upper epiphysis. *Lungs.*—Numerous softening, hæmorrhagic infarcts. Other organs healthy. |
| 7 | M. | A boy | Acute necrosis of femur | July 3, 1877 | July 26, 1877 | 23 days | July 3rd.—Came home from school ill. Feverish. Pains all over. Left knee red and swollen. 6th.—The same, but delirious. Great pain. Temp. 105°. Admitted into medical ward. 9th.—Thin | Abscesses on both ring fingers opening the joints. No other joint superficially affected. *Pericardium* distended with puriform fluid. *Pleuræ.*—Both coated with recent lymph. Numerous sub- |

| No. | Sex. | Age. | Primary disease. | Date of invasion. | Date of death. | Duration of case. | Symptoms. | Post-mortem appearances. |
|---|---|---|---|---|---|---|---|---|
| | | | | | | | and feeble. Tongue dry. Temp. 102°; pulse 132; resp. 60. Left thigh flexed on pelvis. Great pain. Pericardial friction. *Urine* normal, sp. gr. 1022, high coloured. 10th. — Screaming from pain. 14th. — Diarrhœa to the 18th. Sweating freely. 22nd.—Pleuritic effusion. Much toothache. Some stumps were removed. Some abscesses formed over the knuckles, and were opened. Collapsed, and died on the 26th. Diagnosis not made during life. Supposed to be rheumatism. Temperature about 102° to 103°. No rigors | pleural extravasations. *Lungs.*—Bronchial tubes filled with airless puriform fluid. *Heart.*—Surface of a curious mottled colour. Vegetations on surface of apex of heart. Some recent fibrinous clots on mitral valve. Substance of wall mottled on section. *Liver* congested. *Spleen* large and firm. *Stomach.* — Rugæ stained with effused blood. *Kidney* peels readily on external surface. Some small white spots, in some cases surrounded by extravasated blood. Similar spots in pyramids. *Head.*—Extravasations of blood under pericranium. *Brain.*—Gelatinous clot in longitudinal sinus. Excess of fluid beneath arachnoid. *Left hip.*—A collection of pus was found separating the periosteum from the bone about the trochanter and upper part of the left femur. |
| 8 | M. | 9 | — | Jan. 13, 1877 | Jan. 22, 1877 | 9 days | Admitted January 15th. For days before complained of pain in legs; no rigors. On admission, pallid and ill-nourished; pains in legs and front of chest; no redness or swelling; extension of legs; increased pain. Urine slightly albuminous. Temp. 103°. Fell to normal on 17th; slightly elevated till 20th, when it reached 103°. | Right cheek swollen and red; a small abscess at root of right bicuspid. *Heart.*—Pericardium contains ½ of a pint of thick pus; shaggy lymph. Two ulcerated patches, excavating muscular substance; a small abscess in the muscular wall. *Lungs.*—¾ pint purulent fluid in left pleura; lungs congested. *Liver* congested. |

| | | | | Date of admission. | Date of death. | Post-mortem appearances. |
|---|---|---|---|---|---|---|
| | | | | | | and remained high till death. No diarrhœa; no vomiting; increased pericardial dulness; friction; delirium from 17th. Swelling of face and toothache about 15th or 16th. Cyanosed before death. *Spleen* normal. *Kidneys.*—Congestion and scattered points of suppuration in both. |
| 9 | M. | 3 | Acute necrosis of left tibia | July 18, 1876 | July 25, 1876 | Body much decomposed; large part of tibia necrosed; some new bone formed in it; abscesses opened in leg by recent incisions. Large abscess in left axilla. *Lungs* congested and œdematous. *Pericardium* contained 4 oz. of pus. No abscesses in substance of heart. *Veins* not mentioned. |
| 10 | M. | 11 mos. | Acute necrosis of femur | ? | Sept. 13, 1876 | Shaft of femur completely bare. Abscesses had been opened by free incisions. *Pleura.*—In right side 8 oz. of creamy pus. *Lung* collapsed and congested. Other viscera normal. |
| 11 | F. | 15 | Acute necrosis of tibia and shaft of humerus | Feb. 12, 1877 | Feb. 16, 1877 | Greater part of shaft of tibia bare. Incisions had been recently made down to the bone. Epiphyses loose. Medulla pink and grumous. Cancellous tissue presents patches of injection. Pus between periosteum and bone at lower end of humerus. *Basilic vein* full of puriform fluid, extending into axillary vein. Veins of leg healthy. *Heart.*—A few scattered points of commencing myocarditis. *Pericardium* healthy. *Pleuræ.*—Numerous ecchymoses, lymph, no fluid. *Lungs* contain very numerous infarcts. *Liver* pale. *Spleen* 3½ oz., not enlarged, soft, greasy. *Kidney.*—Very few minute infarctions in cortex. |
| 12 | F. | 13 | Acute necrosis of fibula and ungual phalanx of right middle finger | ? | Jan. 11, 1875 | An incision over outer side of right fibula, just above malleolus. Lower third of shaft of fibula bare. Ungual phalanx of right middle finger bare. *Pleuræ.*—Recent pleurisy on left side. *Lungs.*—Numerous infarcts in both lungs; none softened. *Heart* healthy. *Liver* soft. *Spleen* large and soft, numerous infarcts, some softened. *Kidney.*—A few small infarcts. *Veins.*—Nothing abnormal found on careful examination. |

TABLE X.—GROUP VIII. *Ulcerative endocarditis.*

| No. | Sex. | Age. | Primary disease. | Date of invasion. | Date of death. | Duration of case. | Symptoms. | Post-mortem examination. |
|---|---|---|---|---|---|---|---|---|
| 1 | F. | 35 | Ulcerative endocarditis | — | Feb. 28, 1878 | — | Attack of "ague" October, 1877, returned December, 1877. Repeated rigors. Admitted February 12th, 1878. Loud systolic murmur. Gradually got worse. Irregular temperature, but rigors ceased; tongue dry, sordes. Became insensible, and died on the 28th. Albumen in urine. Spleen could not be felt during life. Abdomen swollen and tender | Body fat. A few recent ecchymoses in subcutaneous fat. *Heart* enlarged. Endocardium of left auricle opaque. Mitral valve presents an irregular mass of vegetations, ¾ inch by ½ inch; some subendocardial infiltration in valve, ventricular surface of valve irregularly eroded, small adherent clots, some firm, some soft and crumbling. Pericardium contained 1 oz. of turbid fluid, numerous petechiæ. One small embolic abscess in substance of right auricle. *Lungs.*—Here and there small scattered ecchymoses. *Pleura* contained turbid fluid, no lymph. *Peritoneal cavity.*—One pint of turbid, semi-purulent fluid, no lymph. *Liver* acutely swollen. *Spleen* enlarged, moderately firm, not friable, no abscesses or infarcts. *Kidneys* small. |
| 2 | M. | 22 | Ulcerative endocarditis | — | June 21, | — | Two months before admission had pain in loins and forehead. Shortly after he had shiverings every evening. A few days before admission symptoms ceased; very weak. Admitted May 7th. Emaciated, anæmic. Later on he had rigors almost daily. Highest tem- | Slight œdema of ankles. Numerous cutaneous *petechiæ*. *Heart.*—Minute subpericardial petechiæ. On mitral valve two large vegetations, firm but friable; some calcareous granules in parts. Ventricular wall thickened. *Lungs.*—A few minute hæmorrhagic beneath |

| | | | | | | | | |
|---|---|---|---|---|---|---|---|---|
| | | | | | | | regular. Vomiting; progressive emaciation. June 18th.—Blood examined, some granular matter, excess of white corpuscles, great deficiency of red. Gradually became weaker and died. Urine albuminous | *Liver* dark brown and firm. *Spleen.*—Pulp soft, two large, old infarcts (caseous), and several smaller infarcts immediately beneath the capsule. *Kidneys* large, white, no infarcts. |

TABLE XI.—*Spontaneous pyæmia and septicæmia.*

| | | | | | | | |
|---|---|---|---|---|---|---|---|
| 1 | M. | 48 | Jan. 10 | Mar. 19 | 3 mos. | January 10th.—Shivering on coming out of a hot room; cough next day. Since then *frequent rigors*; sweating at night; bowels regular. On January 30th, February 4th, and March 11th nearly got well, but relapsed soon after. Admitted March 14th with above symptoms and pain in back of neck, head, and calves; pulse 114; liver dulness slightly increased; no other marked physical signs. 15th.—Cough less. 16th.—Eruption like impetigo on legs; delirious at night. 17th.—Eruption increased; delirium worse. 18th.—About twenty hard, inflamed, cutaneous lumps on each leg, size of peas; some suppurating, red raised patches, size of crown-piece, on forearm. 19th.—Delirium constant; eruption increased. Blood extravasated in some of the suppurating points; patch on forearm fluctuating; glans penis apparently gangrenous. Died. Patient was a butler. | *Teeth.*—Right molar decayed, bone healthy; no inflammation. *Skin.*—Bullæ on face, legs, and arms; purple, with red areola. Several lumps due to small abscesses in the muscles of forearm. Glans penis swollen; dark purple red. *Joints* perfectly healthy. *Larynx.*—Ulceration of membrane lining the ala of the thyroid cartilage, surrounded by congestion and ecchymosis. The patch was made up of numerous minute purulent heads. *Lungs.*—Both intensely congested; numerous collections of minute abscesses were found, with distinct pyæmic characters; two or three larger accumulations of unhealthy pus, size of filbert. *Heart.*—Nothing abnormal. *Liver*, 72 oz. *Kidneys* congested. *Spleen* much congested, granular on surface. *Glans penis* infiltrated with pus. |

| No. | Sex. | Age. | Date of invasion. | Date of death. | Duration of case. | Symptoms. | Post-mortem appearances. |
|---|---|---|---|---|---|---|---|
| 2 | F. | 21 | Nov. 12, 1876 | Nov. 24, 1876 | 12 days | Good previous health. November 12th.—Began to suffer from headache and cough, with slight expectoration. 17th.—Languid pain in chest, general aching. 19th.—Vomited. 22nd.—Admitted. A rigor; bowels regular. (On 19th was out of doors, but was very ill in the evening; temp. 105°). 23rd.—Two loose stools, dark colour; twelve distinct rose spots; constant delirium; temp., M., 102·8°; E., 104°; loud systolic murmur. 24th.—Vesicular eruption on fingers and toes and forehead; in some places pustular; temp. 104·8°; died; delirious till death | *Skin.*—Purple hæmorrhagic spots at ends of fingers and toes; a few vesicles on front of legs, some becoming pustular; herpetic spots on scalp and forehead. *Subcutaneous tissue.*—Slight ecchymosis under scalp, corresponding to the herpetic spots. *Brain.*—Small collection of pus under visceral arachnoid; effusion of blood into left hemisphere and in cerebellum. *Heart.*—Beneath endocardium, chiefly at upper part of right ventricle, were a few small spots, the size of pins' heads, apparently minute collections of pus; zone of congestion round them. *Lungs* congested; in upper lobe two or three cone-shaped congested spots. *Liver.*—Two or three spots, mottled with yellow, beneath the capsule. *Spleen* normal. *Intestine.*—Spots of minute suppurations in mucous membrane; nothing like typhoid ulceration. *Kidneys.*—Specks of pus in cortex, mostly immediately beneath capsule. |
| 3 | F. | 39 | Sept. 15 (?) | Oct. 14 | 29 days | Patient, a nurse, admitted Sept. 21st. Weak for some months; sore throat and pains in neck; fauces and tonsils red and swollen; no rash. In six days throat got well, but pain still continued in neck; patches of erythema appeared on both sides of neck, behind parotids; margins raised; pain and swelling of left hand and shoulder day before admission. 21st.—Pain, redness, swelling of both hands; pain in left shoulder; pain in left face and deafness of left ear; teeth on that side serious. 27th. | *Heart* 12 oz., soft and flabby. *Lungs* congested at bases. *Liver* 64 oz., pale and fatty. *Spleen* 4 oz., soft. *Intestines* congested; hæmorrhagic patches in mucous membrane. *Kidneys* slightly congested, otherwise normal. *Blood* very fluid 36 hours after death. |

| | | | | | | | |
|---|---|---|---|---|---|---|---|
| | | | | | | rose rash, itching; blotches ¼ in. diameter, not raised, disappeared on pressure. October 4th.—Rheumatic pains gone; red papular rash; rigor; temp. 104·5°; pulse 132; throat sore again; offensive breath; purulent ophthalmia. 8th.—Lips swollen; sordes; rash darker, resembling purpura, but disappearing on pressure; pulse 140. 10th.—Vomiting; blebs on skin; eyes very bad. 12th.—Diarrhœa; no vomiting; rash nearly gone; epidermis desquamating. 14th.—Died | |
| 4 | M. | 48 | Feb. 28 | April 5 | 36 days | Cough 3 months. February 28th.—Severe rigors. Admitted March 3rd. Jaundiced; liver dulness increased; temp. 103·8°; great abdominal pain; purgatives; jaundice diminished; much cough. He remained unchanged some time, jaundice then increased; emaciation. Four days before death sordes, profuse sweating; red flush on hands and wrists. | *Lungs.*—Right contained at base a small circumscribed area of "secondary pneumonia;" congestion of mucous membrane. *Liver* large, lobules distinctly marked out. *Joints.*—Pus in left sterno-clavicular and wrist-joints. |

MARCUS BECK.

# APPENDIX III.

## NOTES OF MICROSCOPICAL EXAMINATION OF BLOOD DURING LIFE.

---

CASE 1. *Acute necrosis of humerus (periostitis, involving elbow-joint); rigors; amputation; recovery.*—George E—, æt. 21. Admitted January 24th, 1878. Operation February 1st, 12.30 a.m.

*Blood examined* February 1st, 3 p.m.—Temp. 101°; pulse 96, full, slightly dicrotous. (Day very cold and ward cold.) Blood coagulates with great difficulty; red corpuscles natural, forming rouleaux slowly. Granular masses of rather large size, consisting of distinct granules, which appear ovoid or round, and measure 1·5 $\mu$ in diameter. The granules are of pretty uniform size, much larger than those seen in the white blood-corpuscles. On subsequently squeezing the slide, in order to break up the white corpuscles, the rouleaux separate. Some of the white corpuscles were squeezed out, but the granular masses thus produced were much less coarsely granular than those above mentioned. Most of the white blood-corpuscles natural, but some only half the diameter of the majority. Proportion of white to red, average 1 to 50. No bacteria or vibriones. (Number of white blood-corpuscles excessive; red normal.)

*Temperatures:*

January 24th.—E. 101·2°.
25th.—M. 99·8°; E. 104·2°; 3 p.m. 102·9°.
26th.—M. 102·4°; E. 103·2°.
27th.—M. 102·7°; E. 103°.
28th.—M. 102·8°; E. 103·8°.
29th.—M. 103·7°; E. 104·6°.

30th.—M. 103·4°; E. 101°; 3 p.m. 106·8°, shivering.

31st.—M. 98·2°; E. 99·6°.

Febuary 4th, 6.30 p.m.—*Blood* (with Dr. H. U. Smith and Mr. Pitts). White blood-corpuscles decidedly more numerous than before, red scantier; white appear natural; amœboid movements active. Rather less granular matter, but of the same character as before. No bacteria. Temperature is higher again.

6th, 3 p.m.—Temp. 101°; pulse 92, somewhat dicrotous; respirations 28. Feels better. *Blood.*—Fewer granular masses, but still of the same kind. *White* corpuscles natural; amœboid movements natural; average number in thirty-two fields only 5. No bacteria or micrococci.

Case 2.—Thomas H. H—, æt. 36. Punctured wound of elbow-joint. Fracture of inner condyle of humerus. Rigor February 4th, in morning.

*Blood.*—February 25th, 5 p.m.—Temp. 103°. Very few red corpuscles; white in very great excess; in a considerable number of fields the average is 1 white to 18 red. Characters of white natural. Very numerous moving particles, some extremely minute, some double-jointed, others in strings, and yet others rod-shaped, with independent locomotive movements, evidently rod-shaped bacteria; these latter measured about 1·5 $\mu$ in length, the others too small to measure alone, but their relative size nearly that given in drawings (Plate I, figs. *a*, *b*). Some of the more minute dotted filaments only just visible (with Hartnack, obj. 10, oc. 2).

26th, 6 p.m.—Blood of somewhat dark colour. Red corpuscles natural. White in great excess. A considerable number of small ovoid granules. Some bacteria still seen, dumb-bell-shaped, in very active movement, continuing after the fibrin filaments had formed. None of the others seen to-day.

Patient died on March 16th, at 3.15 p.m., body examined March 18th, 2 p.m.

Abscess in temporo-sphenoidal and occipital lobes of right hemisphere of brain. Fracture into condyle. Excision of left elbow-joint.

Right lung, 1 lb. 9½ oz.; left lung, 1 lb. 5½ oz.; heart, 13 oz.; liver, 4 lbs. 8 oz.; spleen, 12½ oz.; kidney, 12 oz.; brain, 3 lbs. 1½ oz.

Body of an emaciated male. Rigor mortis well marked in lower extremities. Much lividity of posterior surface of trunk. Slightly

jaundiced colour of skin. Left hand and forearm œdematous. Excision of left elbow by vertical incision over olecranon; surface of wound unhealthy. Lower ends of bones in wound-surface necrosed. Veins of left arm healthy. A few old adhesions between outer surface of left lung and chest-wall, also between base of lung and diaphragm. Right pleura healthy. Pericardium adherent over entire surface of heart; old calcareous plate in pericardium, size of a penny, situated in the fibrous pericardium, adjacent to left auricular appendix. Right auricle and right ventricle empty; left auricle empty; left ventricle ditto. Surface of heart coated with fat. Walls of heart pale and flabby. Much post-mortem staining of valves and great vessels. Spleen large, substance rather soft and friable. Both kidneys somewhat pale, otherwise healthy.

*Lungs.*—Left surface rather emphysematous. Bronchi exude muco-purulent-looking fluid; upper and back part œdematous, otherwise healthy. Right anterior part of upper lobe: surface emphysematous. At posterior part of upper lobe is a cavity, size of pigeon's egg immediately under pleura, which is adherent to chest-wall. Cavity contains cheesy-looking material. Lower lobe congested, otherwise healthy.

*Liver.*—Upper surface of right lobe adherent to diaphragm. Gall-bladder contains normal quantity of bile; substance pale and fatty.

*Brain.*—Veins of pia mater much congested. In interpeduncular space superficial to pia mater is a collection of sero-purulent fluid lying on pons and extending a certain distance down medulla. This fluid exudes from a large abscess cavity situated in right temporo-sphenoidal and occipital lobes, also extending into descending horn of lateral ventricle of same side. Cavity extends also into interpeduncular space beneath pia mater; cavity has tolerably thick walls, and contains a quantity of purulent fluid.

CASE 3.[1] *Amputation of left arm; osteo-myelitis; symptoms of pyæmia; secondary amputation; death.*—W. T—, æt. 65, watchman.

November 14th, 5 p.m.—Three rigors this afternoon. *Blood.*—Red corpuscles of natural appearance; coagulation natural, but a tendency to rather rapid crenation. White blood-corpuscles in some excess; amœboid movements natural. Numerous minute ovoid

[1] Appendix II, Table I, Case 4.

granules with separate movements. Rod-shaped bacteria, measuring 1·5 $\mu$ to ·3 $\mu$ in length, with free independent movements—a number seen.

15th, 6 p.m.—Rigor in morning. Temp. now 97·5°. Delirious; talking much, loudly. Pulse 120, full, somewhat dicrotous. *Blood.*—Red blood-corpuscles scanty but normal, forming rouleaux, though less readily than natural, and tailing off easily, as in anæmic blood. White in great excess, numerous clumps, and also uniformly scattered over the field. Red and white carefully counted in six average fields, proportion 1 white to 25 red; a number of others less accurately counted gave similar results. White blood-corpuscles with very rapid amœboid movements, rapidly becoming granular masses. Very few other granular masses. No free granules. Only one bacteroid body discovered on prolonged search; this about 1·5 $\mu$ in diameter, and one highly refractile ovoid body, not freely moving, about ·8 $\mu$.

16th, 7 p.m.—Temp. 100·4°. White blood-corpuscles much more numerous than before, varying a good deal in size. Red not abnormal. Except a small number of minute free granules, nothing seen at first; but after half an hour two or three very minute, almost invisible.

*Post-mortem examination* (six hours after death).—Weather cold, almost frosty. Body brought down soon after death. Rigor mortis well marked. No petechiæ; no anasarca.

*Blood* from superficial vein in left groin swarmed with micrococci and bacteria. From another adjacent none at all, and from one in right groin none at all. From a small superficial vein a little below left ankle none at all to be discovered. Blood from cephalic vein of left arm, no bacteria; from left subclavian vein, a few dumb-bells. From right auricle only two bacteria to be discovered. Blood quite natural in other characters; red blood-corpuscles normal.

*Fluid* from right pleura no bacteria; from pericardium no bacteria.

*Fluid* from pleura and pericardium contained no bacteria.

*Discharge* from wound swarmed with bacteria.

*Joints.*—Both knee-joints, ankles, hips, and right shoulder and elbow examined and found to be healthy.

*Head, brain, &c.*—Dura mater natural. Old softening of the greater part of the right temporo-sphenoidal lobe, and of a large part

of the convolutions of hemisphere adjacent, also of nearly the whole of right corpus striatum. Extreme atheroma of cerebral arteries. Nothing else abnormal.

*Spinal cord* not examined.

*Larynx, trachea, and thyroid gland* natural.

*Pleuræ.*—Left, general old slight adhesions. Right normal.

*Lungs.*—Left somewhat emphysematous; right more so. Some patches of broncho-pneumonia, especially at the upper part of lower lobes of both lungs, much more marked there than elsewhere, especially in left. *No infarcts* whatever to be discovered in any part of the lungs.

*Heart.*—A very large, loose clot in right auricle; also in right ventricle. No staining of endocardium. Some narrowing both of aortic and mitral orifices (old endocarditis).

*Liver.*—Soft, pale, greasy.

*Spleen.*—Swollen, pale, soft, greasy.

*Kidneys.*—Granular contracted; not very advanced.

*Supra-renal bodies* natural.

*Stomach and intestines* natural.

The stump was carefully examined, and nothing of an abnormal character found; the axillary vein showed no sign of phlebitis or softening clot in any part of its course; the axillary artery contained a normal clot.

*Note.*—This case is an important one. It was clinically a most typical case of pyæmia; the arm was amputated for a very severe burn; osteo-myelitis followed, with symptoms of pyæmia; amputation was performed higher up, but the symptoms continued, and the patient died with all the features of pyæmia; yet after death the most careful examination failed to discover any secondary deposits, or even any secondary lesions such as usually occur. Bacteria were found in the blood in considerable number on only one occasion, two days before death; none at other times.

CASE 4.—Mary M'G—, æt. 34. Admitted August 8th, 1877. Excision of right knee, August 18th. Amputation, February 13th, 1878. Rigor, February 17th, 3·50 to 4·15 p.m.

February 19th, 5 p.m.—Temp. 102·5°; pulse 120, small and rapid. Anæmic, tongue dry red, somewhat brown in centre, tremulous. Blood from finger has characters of anæmic blood; forms rouleaux naturally, but readily broken up; red scanty, white in slight excess,

but nothing else notable in characters. Very few granules; nothing else abnormal.

21st, 4.30 p.m.—Temp. 103°. Blood from finger pale. Red blood-corpuscles natural, but very scanty, white in large number, of pretty natural appearance and equal size; nine fields accurately counted; average number of white in field 16, proportion to red 1 to 50. Some microcytes measuring only 3·6 $\mu$ in diameter, of reddish colour. No bacteria; very few granules.

22nd.—Had a slight rigor at 1 p.m. Temp. at 5 a.m. 105°, at 3 p.m. 101°; pulse 108 (moved into small ward). *Blood* now thin and watery, much more so than before. Red blood-corpuscles natural, form rouleaux normally; white to red as 1 to 40. Elongated rod-shaped bacteria now seen, measuring 3·5 $\mu$ to 4 $\mu$ long; some ovoid bodies with distinct movements, and other jointed ones of smaller size, all with distinct movements. The bacteria move very freely, continuing in movement after the fibrin filaments have appeared. Some ovoid bodies measuring nearly 3·$\mu$ in length have apparently amœboid movements. *Pus* from wound quite natural; no bacteria or granules.

23rd, 3.30 p.m.—Temp. 105·2. Had a slight rigor at 4 a.m. lasting 10 minutes, temp. 100·4°. Another very slight at 12, temp. 99. At 3 p.m. temp. 105·2°, injection of carbolic acid given; 3.30 p.m. temp. 105·2°; 4 p.m. 103°; pulse 136, small and weak; face flushed, frequent retching and slight vomiting. *Blood.*—Red corpuscles, scanty, form normal rouleaux, easily separated. White blood-corpuscles appear to be much less numerous in proportion than before; very active in their movements. Proportion 1 to 140 (several careful estimates). Very numerous granules of various size, also very numerous, extremely minute jointed filaments, some only just perceptible, others larger, some in clusters (fig. 1 *a*, Plate I). The average length of the individual granules, as estimated from the length of the chains, was about ·15 $\mu$ to ·25 $\mu$. Some larger filaments, nearly ·3 $\mu$ long, made up of these. A few distinct bacteria-like rods, from 2·5 $\mu$ to ·3 $\mu$ long, in no respect differing from ordinary bacteria. The careful examination of several different slides gave precisely the same result.

25th, 6 p.m.—Temp. 102° (very ill yesterday, no rigor. Temp. to-day not over 102°). *Blood.*—Red blood-corpuscles look more numerous, coagula normal. White to red 1 to 45, on average of about fifteen fields; the variation in different fields very slight. There

are now very few granular masses, no free granules and no moving particles: no bacteria or micrococci visible on most careful examination.

26th, 5 p.m.—Had a severe rigor this afternoon, beginning at 3.30 and lasting an hour. Temp. at 12, 102·2°; 3.30, 105·2°; 3.45, 106·5°; at 4, 104·4°; 5.15, 100·6°; 5.45, 102°. The two last taken during examination of blood.

*Blood* bright-coloured red. Red blood-corpuscles not so scanty, but of anæmic character, tail out easily but form normal rouleaux. White in much less excess, though still abundant, varying from 7 to 10 in field. A considerable number of fields counted, but the white adhere so rapidly to the glass that the estimate was considered of no value. Proportion estimated about 1 to 100. Very few free granules only after a prolonged search. But both before and after coagulation the following bodies were seen and some of them watched for some time after. (The whole observation occupied an hour, different specimens of blood being examined in succession.)

1. A few ovoid granules about ·5 $\mu$ in diameter, with apparently locomotive movements.

2. A few ordinary rod-shaped bacteria, some of elongated ovoid shape, measuring rather less than 1·5 $\mu$ in length, with very distinct locomotive movement, lasting after the subsidence of all other movements.

3. Some much smaller bodies, at first rather difficult to see owing to their extreme tenuity; first noticed by their movements, which were of very active locomotive character. They consisted of rows of dots 2, 3, 4 or more in number, forming chains which measured usually not more than ·75 to ·1 $\mu$. Their movements were very active and lasted long after quiescence of the fluid and of Brownian movements. See fig. 1 *a*, Pl. I.

27th, 2.15 p.m. Temp. 99°; pulse 108, weak, not dicrotous. Great pallor; profuse perspiration. *Blood.*—Red corpuscles of natural size and appearance, form rouleaux naturally. White natural, amœboid movements active. Proportion of white to red (average of twelve observations, of which each gave almost exactly the same proportion), 1 to 50. Only one bacterium found, this of a character of two dots, not more than ·4 $\mu$ long. One or two other moving granules, but a prolonged search showed no other bacteroid bodies. *Pus* taken from deep-seated granulations contains normal pus-corpuscles and very numerous bacteria, precisely resembling

those seen yesterday in the blood, extremely minute, in active movement, and some other free granules of the same kind. There are also one or two larger rod-shaped bacteria. Perspiration from neck, which is very profuse, contains some bodies which are smaller than these rod-shaped bacteria, but larger than the rows of dots seen above.

28th, 5.15 to 5.50 p.m.—Temp. 99·5°; pulse 120. No rigor to-day; temperature was 102° at 11.25 a.m., the highest to-day, 101·2° at 12 midnight, and 99·2° at 2 a.m. Is very prostrate, quite sensible, profuse perspiration, very typical cowshed odour. *Blood* natural; coagulation natural. White corpuscles natural in character; amœboid movements normal; size natural. In about twenty fields, average 11. Only one dumb-bell seen. No bacteria. *Pus.*—Much fewer bacteria than yesterday, and in less active movement; characters otherwise unaltered. Died March 2nd at 8 p.m.

*Post-mortem* March 4th, at 3 p.m. Body of medium-sized female, somewhat emaciated. Stump of amputation through middle third of right thigh. Surfaces of flaps have scarcely any appearance of granulating. Superficial necrosis of exposed end of bone for one inch. Right external iliac vein contains breaking-down puriform clot, which extends into common iliac. A large bedsore over the sacrum communicates with a large abscess in the cavity of the pelvis on right side, which extends also downwards into gluteal region, the lower part of sacrum and the coccyx are denuded of periosteum and roughened.

*Pleuræ.*—Normal; *lungs* emphysematous; œdema of lower lobe of right. Right 22 oz. left 15½ oz.

*Heart.*—Flabby, otherwise natural. Weight 10 oz.

*Liver.*—45½ oz., flabby, fatty looking.

*Spleen.*—4 oz. Very soft and friable.

*Kidneys.*—*Right* shows typical tuberculous pyelitis, ureter and base of bladder also involved. Left natural.

*Brain.*—Natural.

No secondary deposit or inflammation could be anywhere discovered; the abscess in pelvis was in evident connection with the bedsore over sacrum.

CASE 5. *Abscess in groin of doubtful origin; opened by puncture; rigor.*—W. H—, æt. 45. Admitted January 21st, 1878.

February 4th, 6.30 p.m.—Temp. 102·8°; pulse 108, full, dicrotous.

Profuse perspiration. *Blood.*—Enormous increase of white corpuscles—the majority of usual size, but some considerably smaller, and a few distinctly nucleated. In some fields (of No. 10 obj., 2 oc. Hartnack) as many as sixty or seventy, but time failed to count many fields. Red natural, but scanty. Many spherical or ovoid highly refractile granules, not very uniform in size, but the majority not more than about ·0015 mm. No moving bacteria.

6th, 3 p.m.—Temp. not taken; pulse 108, somewhat weak and dicrotous. Prostrate. Pain in abdomen. *Blood.*—White corpuscles still in great excess, average in field 30, proportion to red 1 to 24 (twelve observations). White corpuscles not abnormal, only one or two of small size. Very distinct masses of granules (as in Case 1), and when a mass of the same size as a leucocyte was compared with it, side by side, the contrast between the two was very great. The individual granules are ovoid or angular, about ·0015 mm. No bacteria or moving particles. Red corpuscles natural, somewhat scanty.

8th, 3.30 p.m.—Temp. 102·5°. 4 p.m.—Temp. 103·4°; pulse 160. *Blood*, 4 p.m.—Enormous increase of white corpuscles, which average 30 to 40 in field—of normal characters. Very numerous granular masses as before; the granules are sharply defined, ovoid, or rounded, some much more definitely so than those seen before. In some cases they are joined end to end. They measure about 1·5 $\mu$ in length, and are about $\frac{1}{2}$ or $\frac{1}{3}$ of that in width. No distinct moving bodies seen. No bacteria. A few microcytes.

*Urine* contains a trace of albumen, red blood-corpuscles, and some few pus-cells.

Case 6. *Myositis and cellulitis.* (Case 2, in Appendix IV.)—Blood examined by Mr. Wagstaffe, who found very numerous bacteria, mostly of apparently dumb-bell shape.

Case 7. *Rupture of perinæum; operation; pyæmia.*—Amelia S—, female, 35. Blood examined October 24, at 5 p.m. Temp. 102°. Patient apparently moribund, respiration catching, short restless cough; pulse small, rapid, fluttering. Marked yellowish tint of skin; pyæmic odour and aspect well marked. Red corpuscles appear natural, form rouleaux readily; no irregularity in shape or size. White very numerous, 20 to 35 in field (estimated proportion to red 1 to 20); characters quite natural; none with more than one nucleus seen; amœboid movements active. Masses of granular matter abundant.

No bacteria or other moving bodies observed. No free granules, Died October 25th. No post-mortem allowed.

CASE 8. *Amputation of thigh; pyæmia.*[1]—Joseph F—, æt. 18, labourer. Thigh amputated May 26th.

June 14th, 1878.—White corpuscles not obviously increased; amœboid movements natural; red corpuscles scanty, form rouleaux fairly well. No bacteria or moving particles.

15th.—No excess of white blood-corpuscles, if anything somewhat scanty, a few of them about two-thirds diameter of the rest. Some bacteria and vibriones in very active movement.

CASE 9. *Fracture of jaw; pyæmia.*—J. C—, June 14th, 1878. Enormous increase of white corpuscles, estimated 1 white to 20 red. Amœboid movements hardly perceptible. No bacteria.

CASE 10. *Double amputation of legs; pyæmia.*—August 14th, white blood-corpuscles in great excess (10 to 14 in several fields); red normal. No increase of protoplasmic masses. No trace of bacteria on prolonged examination.

CASE 11. *Chronic pyæmia, with pustular eruption.* (Case 4, in Examination of Organs, Appendix IV.)—July 11th, 5 p.m. Blood thin and watery. Red corpuscles aggregate with difficulty, but otherwise not notable. White somewhat abundant. Amœboid movements natural, some few nuclei; only one to two minute moving specks. No rod-shaped bacteria. *Pus* from forehead: pus corpuscles ill defined; many vibriones, but no rod-shaped bacteria.

No bacteria were found on two other examinations.

CASE 12. J. W—. Great increase in white blood-corpuscles and granular matter. No moving bodies.

CASE 13. *Amputation of thigh.*—A. F—, male, æt. 17. Examination, July 13th. Temp. 103·5°, pulse, 100, full, moderately firm, regular; skin dry, hot. Discharge, which has been profuse, began to lessen last night, when rigor occurred. *Blood.*—White 1 to 50 (seven estimations) red, diameter ·0075 to ·0080.

16th.—Considerable increase in white blood-corpuscles, estimated on several observations as 4 white to 100 red. Red form rouleaux, though not easily. No excess of granular matter, no bacteria.

[1] Appendix II, Table VIII, Group IV, Case 2.

CASE 14. W. H.—August 4th. Great increase in white blood-corpuscles, red natural; no bacteria.

15th.—In twenty fields quite as many white as red corpuscles. White somewhat variable in size, but otherwise natural. A number of motionless, highly refractile granules seen in all the twenty fields examined, and several elongated bacteria seen in all.

CASE 15. Elizabeth H—, æt. 48. Sarcoma of thigh; excised March 26th. Symptoms of blood poisoning 24 hours after operation. March 31st, 9 p.m.—A rigor occurred at 7.13 p.m., lasting twenty minutes. Temperature now 102·5°. Patient semidelirious; profuse perspiration, hurried breathing, pyæmic aspect. Blood of quite normal character. White not obviously increased. Examination, lasting half an hour, showed nothing but two bacterium termo of ordinary character. Died. No post-mortem allowed.

CASE 16. *Amputation of thigh; rigors; pyæmia.*—March 31st. No bacteria. White blood-corpuscles much increased in number.

CASE 17. *Periostitis of tibia.*—Mary A—, æt. 10.

*Abstract of history.*—Fell and struck her leg on January 2nd, 1879. Swelling and redness on Jan. 4th. Admitted on Jan. 6th. Immediately after admission on Jan. 6th an incision was made, and a quantity of fœtid pus evacuated.

8th.—Spots observed on trunk and limbs about midday. Delirium. No rigors, no diarrhœa. Physical signs of pericarditis. Albuminuria. Tenderness over spleen. Enlargement of liver.

9th.—Blood examined at 8.40 p.m. Enormous increase of leucocytes. Bright, highly refracting granules, about 1·5 $\mu$, in masses, seen in great abundance. Smaller bodies, not more than ·4 $\mu$ in diameter, in active movement. Rod-shaped and dumb-bell bacteria. Minute, rapidly-moving bacteria of much smaller size, similar to those seen in Case 4. Other larger protoplasmic masses of peculiar shape, moving freely and giving out amœboid processes. Died at 9.10 p.m.

*Temperatures:—*

January 6th.—E, 105·4°.

7th.—7 a.m., 104°; p.m., 103°.

8th.—2 a.m., 104°; 11 a.m., 103·6°; 2 p.m., 103°; 5 p.m., 102·8°; 8.30 p.m., 102·6°; 11 p.m., 103·4°.

9th.—1 a.m., 102·2°; 5 a.m., 102°; 8 a.m., 101·2°; 12 noon, 102·1°; 2 p.m., 103·3°; 5 p.m., 102°; 7 p.m., 102·2°; 8.30 p.m., 102°.

CASE 18.[1] *Ulcerative endocarditis.*—Annie J—, æt. 35. Admitted February 12th, 1878. Died March 1st. Post-mortem eight hours after death. Symptoms of ague, rigors recurring pretty regularly twice a day, between 10 and 12 a.m. and p.m. Temp. 105° or so, falling at times to 94°.

*Blood.*—February 26th, 5 p.m.—Temp. 97°; pulse 88. Very great increase of white blood-corpuscles—in many fields, 20 to 30; red very scanty—in many fields not more than 3 red to 1 white. Red show typical characters of anæmia. White, amœboid movements natural; some few are smaller than natural, others rather larger and distinctly vesicular in the centre, the majority natural. No bacteria, only very few granules, and nothing else abnormal. No other examination of the blood made.

*Post-mortem*, March 1st (7 hours after death).—Temp. in interior of liver 95·5° F. Body still warm. Abundant subcutaneous fat. One or two small ecchymoses in subcutaneous tissue of left leg. Very slight anasarca of feet.

*Peritoneal* cavity contains about six ounces of semi-purulent fluid. Serous membrane nowhere injected.

*Pleuræ.*—Right contains half a pint of turbid fluid, containing flakes of lymph. Left a like quantity, more distinctly purulent.

*Pericardium* also 1½ oz. of yellowish serum, with some flakes of lymph. Some minute pin's-head white spots surrounded by injection over left auricle.

*Heart.*—Large; both ventricles somewhat dilated, especially right, which contains very voluminous coagula. Pulmonary valve competent. Left ventricle contains a large mass of clot, some of which is of ante-mortem origin. Mitral valve appears to close almost completely, but on the posterior segment is a large mass of fungous vegetations, which projects downwards ¼ inch into the ventricle. Other smaller vegetations on valve.

*Lungs.*—Congested; hypostatic pneumonia.

*Liver.*—Enlarged, soft; outline of lobules fat.

*Spleen.*—Enlarged, firm; no visible infarcts.

*Kidneys.*—Small, pale, firm. Old and recent infarcts in cortex.

Nothing important in other organs.

[1] Appendix II, Table X, Group VIII, Case 1.

CASE 19.[1] *Pyæmia. Lateral lithotomy.* Group I (*a*), Case 13.—F. B—, æt. 21. Abscesses in the subcutaneous tissue, and one irregular-shaped, softening patch of dirty yellow colour in the spleen.

*Blood.*—Examined one day before death for bacteria, with a purely negative result.

CASE 20. *Pyæmia; Lateral lithotomy; wound sloughy.* Group I (*a*), Case 14.—W. C—, æt. 18. This patient was so irritable and nervous that the blood could not be examined during life. At the *post-mortem* examination, seventeen hours and a half after death (weather cold), a drop of fluid blood obtained from a superficial vein showed a great excess of white corpuscles. These were excessively granular but of good size. The red corpuscles were with very few exceptions crenated. They did not form rouleaux, but being heaped up in irregular masses in which the outlines of the individual corpuscles could not be recognised. No rod-shaped bacteria or micrococci were seen, and nothing presenting independent movement. The pus from the pleura showed pus-cells of ordinary shape and size, but excessively granular. The liquor puris was teeming with bacteria; some rod-shaped, some pointed, none showed any very active movements.

CASE 21. *Pyæmia.* Group I (*a*), Case 5.—In this case the blood was examined repeatedly during life. As the patient became gradually weaker the blood became paler in colour and poorer in red corpuscles. There was slight actual, and very great relative, increase of the red corpuscles. Some small granules were observed at various times, but nothing was seen that could be said, with any certainty, to be an organism.

## NOTE ON MICROSCOPIC EXAMINATION OF BLOOD AND ORGANS WITH REFERENCE TO BACTERIA.

There is no reason to believe that the micrococci found in these cases were different from those found by other observers in decomposing pus. There may be a doubt whether the larger bodies, viz. those measuring 1·5 $\mu$ or more, are spores of bacteria or larger micrococci. Again, the rod-shaped bacteria from 1·5 to 3 $\mu$ in length differed in no distinguishable respect from ordinary bacterium

[1] Cases 19, 20 and 21, are furnished by Mr. Beck.

termo. The bodies concerning which the greatest doubt exists are the very minute rods seen in these cases, and more particularly observed in the blood and wound secretions of Case 4.

It seems more than probable that these bacteria are identical with those observed by Dr. Burdon Sanderson and others in the peritoneal fluid of animals suffering from artificial septicæmia. Dr. Sanderson's description is as follows:—"The peritoneal fluid was viscid, and coagulated imperfectly or not at all. It contained pus-corpuscles, which were relatively not numerous; the plasma (liquor puris) often exhibited a tremulous movement, which under high powers is found to be due to the presence of minute rods. With lower powers particles cannot be distinguished; all that can be seen is the peculiar tremulous movement of the liquid, which, however, is sufficiently characteristic. In addition to this appearance, the liquid contains other actively moving rod-like bodies, larger than the particles above mentioned, but still not greater than $\frac{1}{500}$ of a millimètre ($2\,\mu$) in length." "In the most rapid cases dumb-bells and chains are mostly absent." And further on—"In all the acutely infected animals to which the table relates, in which the blood was examined, it exhibited microscopic appearances which were characteristic and unequivocal. They were of two kinds. The blood plasma exhibited more or less distinctly tremulous movement of the particles above described, and the colourless corpuscles often contained rods in their substance, and that the blood discs seemed to adhere to each other, the blood possessing a remarkable viscidity."[1] This description, with which I was not acquainted at the time, might have served almost equally well for the description of the blood of Case 4, Appendix III.

The description given by Koch of the bacilli which he found in the blood of animals inoculated with decomposing blood may also be advantageously compared. "If the animals died after *inoculation* with decomposing or septicæmic blood, then only the small bacilli appeared in the blood, and that without any exception, and always in large numbers. These bacilli, which lay either scattered or in small clusters between the red blood-corpuscles, measured from ·8 to $1\,\mu$. Their thickness, which could only be judged of, not measured, is about ·1 to $\cdot 2\,\mu$. The bacilli in septicæmic blood are often seen two connected together, either in a straight line or forming an obtuse angle. Longer chains to as many as

[1] 'Rep. of Med. Off. Loc. Gov. Board,' new series, No. 6, p. 63.

four bacilli also occur, but rarely. Without staining the bacilli are remarkably difficult to recognise in fresh blood, even when one already knows their form, and I have not been able to arrive at any certainty as to whether they possess an independent movement. Their relation to the white blood-corpuscles is remarkable. They crowd in them and increase in number in them. One often finds hardly a single white blood-corpuscle in which there are not bacilli to be seen."

Dr. Koch also states that he has found that these bacilli grow like splenic fever bacilli, but not like these to long threads, but only to thick heaps consisting of separate bacilli. In some cases also he has seen spores appear in the bacilli.

The results of these two observers accord with my own observations on the bacteria found in acute septicæmia in the guinea-pig. The blood when first examined, and also the serous exudation which as observed by Dr. Sanderson, is remarkably viscid, swarmed with these very minute rods, which are very difficult to distinguish unless by staining, or until the eye is accustomed to their minute difference in refraction from the fluid in which they float. By cultivation of these in serum or aqueous humour, there were obtained, in successive generations, first spores, then rods, and subsequently zooglœa masses consisting of short rods, many containing spores, the rods being usually or frequently in pairs, with spores at their attached extremities, longer filaments composed of from four to six rods, and in some cases filaments with no obvious divisions, but containing spores at intervals.

The relation of these bacteria or bacilli to the white blood-corpuscles which is noticed by Sanderson and Koch is also mentioned by Birch-Hirschfeld and other observers as holding good also in the case of micrococci. They found that both in pus and blood there was a marked tendency to accumulation of these organisms in the protoplasm of leucocytes, especially around the nucleus, which in some cases were obscured by them.

It may be that the disappearance of these bodies, partial or apparently entire, from the blood, in the cases observed may be due to the tendency which leucocytes display to take up all sorts of foreign particles, a power which they share with all active protoplasm.

It is natural to inquire how it comes to pass that, in those cases in which bacteria were found in the blood during life, they were not

always found in the microscopic examination of the organs after death. The discrepancy is, however, more apparent than real. For as regards bacteria of the size and appearance of bacteria termo, they were in so small a quantity in the blood that they would only be accidentally discovered in examination of sections. Moreover, in sections examined in the ordinary way, isolated bacteria would not be recognised and could not with certainty be distinguished from fibrin filaments or other minute lines. In sections examined by the special method above detailed, a few bacteria might always be seen; but so long as only isolated rods were seen, it would be impossible to decide whether they might not have been introduced from without during the examination. The presence of the characteristic movement during life is the main test of their nature; this is of course absent in sections. It is only when they occupy definite positions, are in large numbers, or are accompanied by other changes, that they can be definitely stated to exist in the sections examined.

With regard to the far smaller bacteria seen in some cases (especially that of McG—, Case 4), it appears to me very doubtful whether they are likely to be discovered after death unless by other means than those we have employed. For, owing to their extreme minuteness and tenuity, it is almost impossible to distinguish them except when in movement, and the other tissue elements, filaments of fibrin, &c., bear so close a resemblance to them that it is extremely difficult to assert their presence with assurance. It is true that Koch states that he has succeeded in identifying them in sections by means of his method and of a special illumination. We did not succeed in sufficiently destroying all the fibrin filaments in any specimen to allow of their certain recognition.

Other considerations have already been referred to, viz. the fact that these bodies only appeared in the blood from time to time, and then disappeared, indicating the probability of what Koch and others assert as a fact, that they are taken up by the leucocytes and also by other active protoplasts.

## Note on the Injection of Pus.

The important series of observations made by Dr. Birch-Hirschfeld ('Arch. de Heilkunde,' 1873, p. 193 *et. seq.*) may here be referred to, as having an important bearing on this subject.

In the examination of healthy fresh pus from non-febrile patients he found that the pus-corpuscles were distinguished by their equal size, rounded form, sharp contour, clear protoplasm, and the fact that the nuclei were mostly invisible without the use of reagents. Together with this he found also the coarsely granular cells filled with fat granules, which are well known as occurring in old pus. In the liquor puris no bacteria were found, unless one here and there in a wound exposed to the air; and that especially where there were many suppurating wounds, as in hospitals, and where pus was retained and decomposed. In the case of a gangrenous wound in connection with bone disease in a phthisical patient, he also found bacteria. Frequently, however, he found micrococci in pus, especially in hospitals, and their appearance coincided with the onset of fever. The micrococci thus observed were smaller than *micrococcus ureæ*, but larger than those described by Cohn in vaccinia, and by Oertel in diphtheria. The medium length of the pairs of micrococci was from 2 to 4 $\mu$. They had no definite movement.

The pus in which they were found was altered, the cells, instead of being of uniform size, were very various in size, their contour was not sharp, or uniform; often there appeared to be projections upon it. The protoplasm was more cloudy than natural and was filled with granules, smaller than fat-granules, and with a different refraction. The nuclei were visible without the aid of reagents. On treatment with acetic acid, instead of the nuclei becoming clear and the protoplasm swelling up and disappearing, there remained rounded granules arranged in chains, some of which soon float out. These are also insoluble in ether. Similar changes are also seen where the bacteria of ordinary putrefaction are present.

As the process advances the micrococci multiply and then colonies are formed; these being masses of micrococci, with others isolated or in pairs lying around them. Hirschfeld never saw the zooglœa masses with intermediate substance described by Cohn. As the number of these colonies increases, the pus deteriorates, and Hirschfeld believes that they then enter into the tissues.

Hirschfeld examined the *blood* also, and found that just as the local deterioration of the wound is parallel to the increase of the bacteria in the normal secretion, so do the severity and the rapid course of the infection agree with the number of the bacteria which are present in the blood.

In cases of recent amputation in which any number of micrococci

were seen in the wound, similar ones were very soon seen in the blood. In no case did he find that the number in the blood bore any comparison with the number found in the wound, but towards the fatal termination he often found two or three to one red blood-corpuscle. Usually only the smallest form of double micrococci were to be found. (Hirschfeld remarks that the single ones are not readily to be distinguished from isolated elements, due to breaking down of the white blood-corpuscles, but those of which he speaks resisted liquor potassæ, acetic acid, and ether). He also found changes in the white blood-corpuscles similar to those seen in pus-corpuscles, though in a less degree. He observed also a great increase in the number of the leucocytes. No change was found in the red blood-corpuscles such as that described by Coze and Feltz.

In some cases, however, he found little or none of the above-mentioned changes in the blood. Hirschfeld next made a series of experiments on animals (rabbits and dogs), with a view to ascertain the comparative effects of injection of healthy pus and pus containing micrococci and bacteria in three series of experiments.

Series I.—The injection of healthy pus produced no results beyond slight temporary fever.

Series II.—On the other hand, pus containing micrococci when injected produced fever of an irregularly intermittent type, with loss of appetite, wasting, and death in sixteen to twenty-four days. The intensity of the symptoms was proportioned to the number of micrococci, not to the condition of the patient from whom the pus was taken. On the first day no rise of temperature was observed. On the second it rose to 40·7C., falling again to normal. On the third day, or in the night from the third to the fourth, there was a marked rise of from 42° to 43°; and from that time rapid wasting, loss of appetite &c. Again the temperature fell, rising again to 42° or 43° before death. Some of the animals died in seven days, one lived twenty days, but death was rarely delayed beyond the fourteenth day.

Post mortem there was found suppuration around the seat of injection. When the pus was merely injected into the subcutaneous tissue, there was but little affection of the internal organs. The kidneys were usually diseased, presenting degeneration of the epithelium, sometimes colonies of micrococci in the tubes. Abscesses were found in the lower lobes of the lungs, in two cases only with colonies of micrococci in the vessels. In one case, masses of micrococci were found in the vessels in the liver with surrounding puru-

lent infiltration. The *spleen* was much enlarged, the cells swollen and granular, like the leucocytes in the blood.

SERIES III.—A third series of experiments was made with pus containing many ordinary rod-shaped bacteria of ordinary decomposition, some from a case already mentioned where they were found in the wound, others from pus left to decompose.

Some pus which contained micrococci and bacteria was taken, one half injected at once, produced results similar to those in Series II, the other half, diluted with distilled water, was placed in a glass closed with a cotton-wool plug. This latter did not develop the micrococci nor bacteria after the first day. Then he injected some of this, and in eighteen days no symptoms had appeared.

When, however, the putrid pus was injected fresh, containing bacterium termo and lineola and bacillus subtilis, the action was the same whether it was from healthy or pyæmic pus, viz. it produced the usual septicæmia.

W. S. GREENFIELD.

# APPENDIX IV.

## NOTES OF MICROSCOPICAL EXAMINATION OF ORGANS, TOGETHER WITH SOME SPECIAI NOTES OF CASES.

---

### SERIES I.—CASES EXAMINED BY DR. GREENFIELD.

CASE 1.[1] *Excision of ankle. Septic intoxication.*—E. R. A—, æt. 6. Admitted December 17th, 1877. Died February 19th, 1878. Disease of ankle; excision February 16th. Delirious at 2.30 p.m. on February 18th, vomited at 8.30 p.m., when temp. 96°; at 12 midnight temp. 98°. 19th.—At 2.30 p.m., temp. 100·4°; 3.50, temp. 104°; died.

*Post-mortem examination* (twenty-two hours after death).—Body of very well nourished female child. Slight yellowish tint of skin, especially of face; conjunctivæ yellowish. No petechiæ on skin, no anasarca.

Recent excision wound of left ankle; vertical incisions over inner and outer malleoli. Edges of wound of deep red colour, the flaps swollen; no sign of gangrene. Lower part of shaft of tibia for about half an inch bare of periosteum, dry, very soft, and of somewhat yellowish colour. An inch above the lower end the cancellous tissue appeared quite healthy. Slight inflammation of lower end of fibula; the bone appearing quite healthy. Astragalus soft and spongy, easily cut through with a knife; cancellous tissue of intensely purple colour with small hæmorrhagic points scattered throughout, os calcis also extremely soft. Signs of intense inflammation and suppuration around the wound, but not extending more than an inch above it. Some inflammatory œdema extending half way

[1] Vide Appendix II, Table I, Case 3.

up the leg. Popliteal and posterior tibial arteries and veins healthy. No sign of inflammation in popliteal space. Glands enlarged, but no sign of inflammation. Other tissues of leg healthy. Knee-joint healthy. No swelling along sheath of femoral vessels; superficial femoral vein contains dark fluid blood, and appears perfectly healthy, so also common femoral. The superficial glands of the groin are distinctly swollen, with small patches of commencing suppuration.

*Peritoneum* healthy.

*Pericardium* healthy, free from ecchymosis.

*Heart* 8¼ oz., healthy.

*Pleuræ* healthy.

*Lungs.*—Some of the larger bronchi contain fluid resembling unaltered blood. Throughout the lower lobes of both lungs, and in upper lobe of right are numerous small points of hæmorrhagic infarction, evidently due to inhalation of blood from the bronchi.

*Thymus* rather large, appears healthy.

*Spleen* small, 1 oz. in weight, firm, healthy.

*Liver* weighs 15½ oz., not enlarged. Gall bladder natural, and contains dark bile. On section the liver presents a very curious appearance. The centres of the lobules are of a bright canary yellow colour; the periphery is translucent and greyish, whilst an intermediate zone is of brick red colour. In some parts of the liver the translucent greyish zone at the periphery of the lobules is more marked. The substance of the organ is generally firm, not readily broken down. On the surface there is nothing to indicate the peculiar appearance seen on section.

*Suprarenal capsules.*—Medullary portion somewhat congested, otherwise natural.

*Kidneys* weighed 5 oz. Capsule readily separated, surface smooth, substance generally of pale colour; venæ stellatæ well-marked. Cortex, especially interpyramidal portion, swollen, of a dead white colour, free from ecchymoses.

*Bladder* natural, contains slightly bile-stained urine.

*Stomach* contains altered blood mixed with mucus; otherwise healthy.

*Intestines* natural throughout.

*Fauces and posterior nares* contain fluid blood. No ecchymosis in pharynx. Larynx natural. Some ecchymoses in submucous tissue of larger bronchi.

*Brain and membranes* natural.

*Microscopical examination.*—The following parts were examined: —Granulating surface of wound, periosteum and tissues surrounding the wound, glands from popliteal space and groin, liver, kidney, spleen, lung, and thyroid. All of these organs were examined with logwood and with methyl-violet staining, and by Koch's method.

*Tissues of wound, &c.*—The superficial parts of wound showed but little sign of granulation; the surface was covered with an amorphous granular material, which in some parts contained small masses of micrococci. The connective tissue appeared generally swollen and infiltrated with fibrinous exudation, containing but very few leucocytes. The vessels, both in the subcutaneous tissue and beneath the periosteum, showed marked changes. In many of the capillary venules were masses of micrococci, either completely blocking up the channel, or, more commonly, adherent to the wall of the vessel and projecting into the lumen. Some of the latter seemed to be remains of a larger mass, as several separate clumps were attached near each other, as if a large plug had been washed away and had left portions sticking to the wall. (See fig. 4, Plate I.)

The small arteries in the vicinity of the wound showed very characteristically the various stages of obliterative endarteritis. The organisation appeared to be much more complete than in the similar change in the skin in Case 4, and suggested the probability that it might be a more chronic process.

The periosteum itself showed no marked change beyond considerable swelling, and in some parts distant from the wound, bodies resembling typical tubercular granulations were observed.

The *glands* from the popliteal space and the groin showed little change. No micrococci were discovered in them.

*Kidney.*—The following changes were observed:

1. A very peculiar condition of the epithelial lining of the convoluted tubes, analogous to that seen in the hepatic cells.

2. Multiplication of the nuclei of the endothelium of the afferent arterioles of the glomeruli; proliferation also of the muscle-cells; multiplication of the nuclei of the glomeruli; these changes precisely resembling those seen in scarlet fever.

3. Thrombi, mainly composed of leucocytes, in some of the venulæ rectæ.

4. Small tracts of interstitial exudation here and there in the cortex.

1. The condition of the epithelium, both of the convoluted

tubules and the ascending tubes of Henle, closely resembled that of the liver cells. They were much swollen, so that in many parts the tubes were entirely closed. The part of the cells most affected was that nearest to the basement membrane; this appeared to have undergone a segmentation of the protoplasm smoething like multiple vacuolation. The more central (*i. e.* nearest the lumen) parts of the cells, though highly granular, were not segmented, or were so to a much less degree; and from this it resulted that in the centre of the tube was a core of granular protoplasm, surrounded by a few nuclei, and between this and the wall of the tube a structure, very similar to a capillary filled with blood, the segmented protoplasm looking like polygonal cells massed together. (See fig. 2, Plate IV.)

2. The changes in the afferent arterioles and glomeruli were precisely similar to those seen in the early stages of scarlatinal nephritis. The multiplication of the muscle nuclei was especially well marked, though, of course, in a very early stage

3. *Thrombi in venules.* Only a few of these were found, but the patches of exudation seen in other parts render it probable that similar changes existed pretty widely. The thrombi was almost entirely composed of leucocytes. No similar changes were seen in arterioles.

4. The small tracts of exudation were scattered through the cortex. They consisted merely of leucocytes accumulated in the capillaries and migrating in their vicinity. They appeared to be analogous to those seen in the liver.

5. Many of the vessels were filled with blood (normally). On examination with high powers in sections prepared by Koch's method no bacteria were found. In addition to these, amorphous fibrinous plugs were found in some of the capillaries, but no micrococcus plugs.

*Liver.* In the neighbourhood of the portal spaces was found great infiltration with leucocytes, giving in some parts an appearance under a low power very similar to that seen in leucocythæmia. (See Pl. V, fig. 1.) together with this was a very remarkable condition of the hepatic cells. These were generally swollen to such a degree as entirely to obscure the normal linear radiating arrangement of the cells, especially towards the centre of the lobules (Pl. V, fig. 3), whilst at the periphery the capillary network was more distinct, and the cells in many parts were separated from

the capillaries and each other, and lay isolated in the interstices. But the most striking feature consisted in an apparent segmentation of the protoplasm, which looked as if broken up into a number of somewhat angular masses within the cell, the nucleus of which was in the majority almost entirely obscured. (Pl. V, fig. 2.) The appearance differed entirely from that seen in fatty degeneration, and no oil drops were found in any of the cells thus affected. There was also a remarkable uniformity in the distribution and extent of the affection. None of the cells showed any sign of breaking down such as is seen in acute yellow atrophy. Many cells contained abundant granules of bile pigment.[1]

In some of the vessels were found amorphous plugs surrounded by leucocytes, but these did not present the usual appearance of micrococci, nor were any bacteria or micrococci distinctly observed.

*Lungs.*—The only change found consisted in a widely distributed broncho-pneumonia, many of the air cells also contained blood.

*Thyroid* was perfectly healthy, no micrococci discovered.

*Summary.*—No micrococci or bacteria were found elsewhere than in the wound, where alone micrococci were discovered. The chief morbid change consisted in the presence of intense irritation in the liver and kidney, shown by the exudation in the portal spaces, and the peculiar change in the protoplasm of the secreting cells.

CASE 2. *Pyæmia (? infective myositis); abscesses in muscles of right arm, in heart, &c.; diffuse cellulitis of left arm.*—Thos. B—, æt. 25, carman. Admitted under care of Dr. Murchison February 2nd, 1877. Died February 3rd, 8 p.m. (This case is one of such rare character that the notes are given in full.)

*History.*—Father dead, of dropsy, æt. 48. Mother living, æt. 49, well. Patient had an attack of "sunstroke" last August, was driving his van when he felt giddy and fell off; was sick and delirious. For three weeks was in the London Hospital, and was not well for seven weeks. A few days before the present illness commenced he had a fight, and in striking missed his aim. Present

[1] The change in the cells in the central zone of the lobules of the liver has a close resemblance to an exaggeration of the normal reticulated structure of the liver-cells, which has been described by Dr. Klein in a paper published since this case was examined. ('Quart. Journ. of Micro. Science,' April, 1879, No. lxxiv.) From a comparison of the preparations from this case with Dr. Klein's drawings, it would seem that the morbid swelling has brought this peculiar normal structure into relief.

illness began on Friday, January 26th, with pains across loins, which continued till two days ago. He kept at his work, however, till January 29th, but since then has kept in bed. On January 29th and 30th he had some shivering, and has since had a good deal of perspiration. On January 31st he began to have much pain across the hypogastrium shooting up to the right hypochondrium, and, as he says, "doubling him up." On January 31st he had slight epistaxis, about a teaspoonful. Vomited last night. On night of January 29th he was very delirious. On February 1st he began to have aching pains in both arms and legs, and at the same time the arms became red and swollen.

*Notes on blood by house physician.*—Blood drawn in capillary tube at 12 midday, examined 1.30 p.m. White corpuscles average 1 to 30 red. Bacteria numerous, very active, 20 to 40 in each field. Numerous large inactive particles.

*State on admission.*—Expression anxious, countenance rather sallow, but conjunctiva white. Pulse 124, feeble, regular; resp. 50, shallow. He complains of aching pains in both arms, and also in his legs. Whole of right arm and forearm much swollen, brawny red, and tender, the inner and posterior aspects of forearm especially swollen. The left arm is also swollen similarly, but to a less degree. Both pit a little on pressure. Both calves painful, slightly swollen, and hard. Tongue slightly coated and moist, red at edges. Appetite bad; much thirst. Bowels acted yesterday. Breath a little short; no cough. Some abdominal pain, but no tenderness. Spleen not enlarged. Liver not materially enlarged. In right flank a tender point midway between ribs and crest of ilium, but no tumour or induration to be felt. Lungs and heart present nothing important.

*Temperatures*:—February 2nd.—2 p.m., 102·6°. 3rd.—3 a.m., 102·4°; 11 a.m., 103°; 1.15 p.m., 104·4°; 2.45 p.m., 105°; 3.45 p.m., 105°; 5.30 p.m., 105·4°; 7 p.m., 106·2°.

3rd, 10 a.m.—Restless, has not slept. Mind now clear, but wanders at times. Pulse very weak, 124, small, regular. There is still general swelling, redness, and thickening of both arms, with here and there specially elevated and thickened patches of a purple hue, changing colour like a bruise; slight herpes on lips. No enlargement of glands of neck. Lungs.—Over front of left chest and in left axilla distinct pleuritic friction; back not examined. Heart.—Action feeble, pericardial friction, especially marked near

apex. Abdomen somewhat tympanitic, not tender. Spleen slightly enlarged. Urine 1032, acid, contained a trace of albumen.

No shivering, but sweating at intervals. At 5.30 p.m. vomited, and violent sickness recurred two or three times. Died at 7.30 p.m. after a severe attack of vomiting. Several small bullæ seen on thorax and back before death.

Was ordered at 1 p.m. Chloral Hyd., gr. xx; Pot. Brom., gr. xxx; Quin. Disulph. gr. v, 4tis h.

*Post-mortem examination* (on February 5th, forty-three hours after death. Weather cold and dry. Thermometer 30° on night of 4th and 5th. Highest temp. on 4th, 45°).—Body of strong muscular man. Rigor mortis strongly marked both in upper and lower limbs. No external marks of injury or of open wound, except a small graze on lower lip. No petechiæ on skin.

Both arms swollen; right with some superficial abrasion from desquamation of cuticle on forearm. Some rounded swellings on forearm, and one near elbow. Left arm generally swollen.

On making incisions lengthwise into right forearm some general œdematous infiltration of subcutaneous tissue and of intermuscular planes was observed. At the points of most marked swelling circumscribed inflammation of the subjacent muscles was found, in some places extending deeply nearly to the bone, the muscle being partly injected, partly whitish, and in part broken down into a pinkish grumous pus. In other parts was a more diffuse myositis. The cellular tissue adjacent also showed signs of suppuration, but this appeared to be secondary, not running along the septa, as in diffuse cellulitis. Some serous infiltration and general swelling extended upwards at back of arm, but little on inner side. Brachial vessels and veins apparently healthy throughout. No sign of swelling in axilla. Axillary glands slightly reddened, but free from obvious inflammation. Elbow-joint healthy. Bones of forearm and arm also apparently healthy.

Left arm: subcutaneous cellular tissue from wrist to shoulder infiltrated with serum; in some places swollen to half an inch in thickness. No sign of suppuration here. No abscesses anywhere seen in muscles.

Both knee-joints healthy. Some slight serous infiltration of cellular tissue over left calf. No sign of suppuration. Femora and left tibia and fibula healthy, so far as could be ascertained.

Fauces, mouth, pharynx, œsophagus, and larynx and trachea

normal, with the exception of slight serous infiltration of muscles of pharynx and cellular tissue at posterior part.

Mediastinum normal; so also sternum, ribs, &c.

*Pericardium.*—Normal. Some minute subpericardial ecchymoses over anterior septal groove.

*Heart.*—14 oz. Right auricle much distended with imperfectly coagulated and somewhat viscid blood; so also right ventricle. Left auricle and ventricle containing very dark treacly blood. Endocardium very deeply stained everywhere. Muscular tissue of wall of left ventricle in its upper half of pale yellowish-white colour, mottled here and there with ecchymosis, the section in places granular; the condition apparently one of acute myocarditis. No actual abscess to be discovered. Lower down were one or two smaller patches of similar change. Valves normal. Entire absence of all signs of endocarditis.

*Pleuræ.*—Right, with general recent inflammation over lower lobe. Left, with a small patch of recent inflammation, covered by a thin layer of lymph, about one inch in diameter, over the small tongue of lung overlapping the pericardium; none elsewhere.

*Lungs.*—Right, 1 lb. 6 oz.; left, 1 lb. 5½ oz; both with the general appearance of commencing decomposition, and some general congestion. One or two small recent pyæmic infarcts, only partly decolorised, in lower lobe of right. One in anterior part of left, beneath inflamed pleura above mentioned. No sign of bronchopneumonia.

*Liver.*—4 lb. 1½ oz., somewhat enlarged. Blood flowing from hepatic veins, turbid, pinkish, as if mixed with milk. Opaque swollen condition, as if from commencing decomposition.

*Spleen.*—4 oz., small, firm.

*Kidneys.*—14½ oz., swollen, and opaque whitish colour of cortex. Staining from decomposition of blood.

*Stomach and intestines.*—Normal.

*Brain and membranes.*—Normal; so also sinuses and temporal bones, so far as examined. Brain weighed 2 lb. 15 oz.

Muscles in spinal groove opposite spine of scapula on left side appeared slightly injected, as if from bruising, but this somewhat doubtful. Bones of spine, membranes, and cord normal throughout.

*Microscopical examination of heart.*—The sections were examined by logwood staining, and also by staining with methyl-

anilin-violet, and treatment with acetic acid. In all the sections were tracts of various size, which stained more deeply with methylanilin. In these positions were found very numerous bacteria in the intermuscular septa. In some parts they were densely packed, so as to form a distinct mass of colour visible with a low power. More commonly they were only thinly scattered, being especially abundant within and around the blood-vessels. In some of the smallest arterioles they appeared nearly to fill the lumen; in others, they lay lengthwise along the wall, within or outside it. In many parts they were found only in the arterioles or in their immediate neighbourhood, but in some they penetrated along the capillaries, and formed a network between the muscular fibrils; scarcely any penetrated the sarcolemma (Pl. I, figs. 2 and 3).

These bacteria were for the most part rod-shaped, measuring 1 $\mu$ to 3 $\mu$ in length, though many reached 4 $\mu$, and from ·3 $\mu$ to ·5 $\mu$ in thickness. In many of the longer ones a process of fission was visible. One or two longer filaments, 12 $\mu$ in length, were seen; these contained numerous oval spores.

In some parts clumps of very minute spores were found, resembling micrococcus clumps, but these were very scanty.

*Muscles of arm.*—The muscular tissue in the neighbourhood of the abscesses presented extensive tracts of inflammation, exudations of leucocytes, here and there small hæmorrhages. The muscular bundles were separated in many parts by fibrinous exudation, with but few leucocytes, the fibres having in many places lost their striation and assumed a peculiar glassy appearance.

On examination with higher powers, only one or two bacteria were found on very prolonged investigation of numerous sections. But both in the blood in the vessels, in thrombi, and in the exudation, were seen, either isolated or in clusters, micrococci, measuring from 2 to 4 $\mu$ in diameter, mostly rounded, a few ovoid. In some of the sections, in which the colour had been very completely removed from the other tissues, these came out with great distinctness. Larger masses of micrococci were also discovered in some parts, resembling those seen in the other cases (see Pl. I, fig. 6, and Pl. II, fig. 1).

*Skin* over inflamed muscles presented only scattered patches of inflammation, in which were no special characters. No micrococci or bacteria discovered.

*Kidneys.*—Nothing abnormal observed.

*Lungs.*—Slight catarrhal exudation in many alveoli; no other specific change.

In connection with this remarkable case, some similar cases may with advantage be mentioned, which are recorded by Dr. Nicaiase, under the title of *infective myositis* or *malignant myositis*, in the 'Revue Mensuelle de Médecine et de Chirurgie,' 1877.

He states that the disease consists of acute, diffuse, suppurative myositis, accompanied by grave general symptoms and rapid death.

(A). M. X—, æt. 40. Epileptic. July 5th.—Had a fit. Worked the next day.

6th.—Pain in the inner and upper part of the thigh. Could not work.

8th.—Saw a doctor. Deep-seated inflammation of thigh.

10th.—Fever. Inflammation of muscles of thigh, supposed to be due to rupture during the fit. Same evening had pain in right shoulder and side.

11th.—Side of chest swollen, œdematous, skin thickened and hard, yellowish tint, some redness; redness of thigh; high fever, sweating.

12th.—Œdema and redness extended; delirium. Temp. 39·4° (103° F.).

13th.—More swelling; no fluctuation. Some petechiæ on back. Temp. morning, 38° (99·5° F.); evening, 104°.

14th.—No fluctuation, not much change; sweating; no albumen in urine.

15th.—Worse. Temp. 104°. Died July 15th, night.

*Post-mortem*, July 17th.—Decomposition far advanced. *Thigh.*—Subcutaneous cellular tissue contained no pus, adductor muscles infiltrated, no collection of pus; muscular substance greyish, infiltrated with pus, spongy; some infiltration in pectoralis major and serratus magnus; congestion of lungs; spleen black and pulpy; liver fatty; kidneys healthy; no superficial wound could be found anywhere.

(B). *Suppurative myositis of triceps femoris.*—Man, æt. 45, butcher, strong; following some hard work, he felt pains in the thigh, and was obliged to keep his bed. On admission a few days after there was a large yellowish-red patch on the thigh, indurated

and moderately sharply defined. No subcutaneous collection of pus; doubtful deep fluctuation; general state bad. The following day there was evident fluctuation, an incision made. The triceps was found to be infiltrated with pus; a purulent layer superficial to it. Abundant serous infiltration. The man died four days after. Post-mortem not recorded.

(c). *Varicose ulcer; lymphangitis; purulent arthritis of knee; diffuse myositis of triceps femoralis and brachialis.*—M. X—, æt. 62. Good previous history. Simple fracture nine years before. Two years afterwards a varicose ulcer formed. On admission there was a large foul ulcer on the *left* leg. Viscera healthy. Washed with carbolic acid, 1 to 50.

A few days (October 3rd) after admission a severe rigor and lymphangitis, with swelling of the inguinal gland, appeared.

4th.—Worse.

6th.—Pain in *right* knee.

7th.—Worse.

8th.—Worse.

9th.—Incisions into knee.

10th.—He died.

*Post mortem.*—Serous infiltration of thigh. A few abscesses size of peas in course of the lymphatics. Vastus internus infiltrated with pus. Adductors pale and discolored. Purulent infiltration of the triceps of the arm. Elbow healthy. Hypostatic congestion of lungs. Nothing in heart or brain. Liver yellow and a little soft. Spleen blackish and diffluent. Kidneys congested.

Nicaisse wisely offers no explanation of these cases.

Case 3. *Chronic pyæmia with multiple suppuration.* (Case 11 in Appendix III.)—E—. Died July 14th, 10 a.m. Post mortem 2.30 p.m.

*Post mortem* (four hours and a half after death) by Dr. Greenfield. Weather warm, very wet. Wind south-west.

Rigor mortis scarcely commenced. Body generally emaciated. Some anasarca of both feet and ankles. No petechiæ or ecchymoses. Some swelling of tissues below right clavicle and in subpectoral region. Blood in veins thin and watery.

Forehead, eyelids, especially left, upper part of nose, and front of scalp of dusky red colour, swollen, with numerous groups of small

pustules scattered over it, some broken, covered with thin watery secretion or scab, but many, size of small shot, embedded in substance of swollen and inflamed tissue. On cutting into this the whole swelling found due to similar multiple points of suppuration about the size of mustard seed or rather larger. Small, dusky-red patches in skin over left tibia; on section these have exactly the same appearance as those on forehead. Left little finger, also, especially along middle phalanx, presents an exactly similar condition going down to bone. Other patches not examined. Both ankles, both knees, and left elbow, with shoulder-joints, examined. No pus in any of them, only some excess of synovia, especially in ankle and right knee. Caries of third metatarsal bone of right foot. The whole upper lip completely destroyed—eaten away—up to root of nose. The alveolar border of jaw exposed and slightly invaded. Edges of ulceration rather smoothly cut, covered with thin secretion. Glands on left side of neck in upper part, at one point adherent to the skin, and converted into thick pus. Some ulceration of skin not unlike strumous ulceration. No obvious recent enlargement of glands in upper part of neck. Swelling in lower part of neck on right side, just above clavicle and shoulder; and much more marked just below clavicle. Considerable œdema of subcutaneous cellular tissue. In deltoid and pectoralis, close to clavicle, and for about two inches below, signs of intense inflammation, and very numerous scattered points of suppuration, the pus being very thick and almost semicaseous—the condition exactly like that in skin, &c. A vein of some size here found filled with soft pinkish-white clot. Axillary vein not affected. No obvious swelling of glands. No suppuration.

*Brain.*—Membranes, &c., of brain quite normal. Brain remarkably healthy looking.

*Pericardium* contained about two ounces clear serum.

*Heart* large, healthy looking. Valves, &c., normal.

*Pleuræ* each contain nearly a pint of clear serum, a coagulum of lymph in left.

Both *lungs* spotted with numerous ecchymoses. On surface very abundant, scattered, pale nodules, varying in size from a small pea to half an inch in diameter, somewhat prominent, the larger ones flattened on surface, irregularly rounded; all surrounded by a more or less marked zone of congestion and minute ecchymoses, but no exudation. Patches of collapse scattered over posterior surface of

both. On section of lungs patches similar to those seen on surface were found also to be scattered irregularly through both lungs, most marked towards surface. They were of yellowish or pinkish-white colour, rather sharply outlined, surrounded by a zone of congestion, which in some was very intense; they had an almost caseous appearance, and seemed to be made up of multiple points of suppuration. A few were softened and tending to excavate. Towards the root of the lung, and extending from it in arborescent fashion, very beautifully defined patches of broncho-pneumonically arranged fibroid tubercle, in one or two places beginning to caseate, but these quite exceptional.

*Bronchial glands* not obviously affected.

*Peritoneum* normal.

*Liver* rather large and pale, otherwise normal.

*Spleen* enlarged and deeply congested, but slightly mottled, rather firm and dry. No infarcts.

*Stomach* normal.

*Intestines* not fully examined. Mesenteric glands apparently normal.

*Kidneys* rather large and pale. Some general swelling. Nothing else.

*Bladder* not examined.

In left groin a puckered smooth scar as from old abscess. Around this a dusky purple blush and slight central sloughing. On section the superficial layers of skin separated by pus from deeper, and in tissues around are multiple points of suppuration like those elsewhere. One small pustule on glans penis.

*Larynx.*—Slight thickening about ary-epiglottic fold; otherwise normal.

*Trachea* normal. Perforating ulcer of soft palate with thickened edges, quiescent, chronic.

*Tongue* coated and thick.

*Microscopical examination. Finger.*—In the part of the finger examined were numerous minute abscesses, measuring from 1 millimètre to much smaller; these were mainly situated in the skin and subcutaneous tissue. For the most part they appeared to have been formed around veins, for some of the smaller abscesses occupied the situation of a vein, part of the coats of which were still visible, the abscess apparently consisting merely of a vein which had contained a puriform clot, its walls infiltrated with

leucocytes, and more or less broken down. These abscesses contained broken-down pus, together with a large number of ovoid or rounded bodies, measuring from 2 $\mu$ to 5 $\mu$ in diameter, which stained very deeply with logwood or methylanilin-violet. (Pl. IV, fig. 1.)

The smaller arteries in the neighbourhood of these minute abscesses had undergone a change analogous to that which has been described as "obliterative endarteritis." The outer coat, where actual suppuration had occurred in its vicinity, was usually much thickened and infiltrated with leucocytes. The middle coat showed little or no alteration. The inner coat was swollen somewhat irregularly, in some parts to such a degree as nearly to exclude the vessel, in other parts the lumen was occupied by a thrombus. The swelling, though mainly hyaline, was here and there infiltrated with leucocytes. (Fig. 3, Pl. III.)

The endothelium was markedly proliferated in some of the sections, appearing mainly to compose the plug in the interior of the vessel, and in all the sections it had become desquamated.

One or two bacteria and micrococci were found in the blood, in vessels and elsewhere, but not in sufficient numbers or with sufficient constancy to appear to be of any importance.

*Muscles.*—The muscles in various parts contained also numerous minute abscesses, scarcely larger than those in subcutaneous tissue. Their contents resembled those in the skin; surrounding them were somewhat extensive tracts of fibrinous exudation, of blood, and of leucocytes. The muscular fibres presented various stages of degeneration. No bacteria or micrococci anywhere seen.

*Lungs.*—The portions examined showed extensive pneumonic changes and tuberculosis, but nowhere any sign of bacteria or micrococci.

*Kidneys.*—Nothing abnormal.

CASE 4. (Case 4 in Appendix III).—McG—. Clot *in situ* in femoral vein, lung, liver, and kidney examined; sections stained with logwood, methylanilin-violet, and the modified method of Koch.

*Thrombus in situ.*—Nothing special was observed either in the clot itself or in the walls of the vein. Only a small portion of the clot remained adherent to the wall; this showed no sign of organisation. No bacteria or micrococci, nor anything beyond what is usually seen.

*Lungs.*—Scattered patches of pneumonia; some of alveoli filled with catarrhal, others with fibrinous exudation, but with no special features. Many vessels contain recent thrombi; in some of these, bodies resembling micrococci were seen, but no bacteria, and no clumps of micrococci.

*Liver* for the most part natural, but some of nuclei of hepatic cells stain very deeply with logwood or methylanilin, and with a high power ($\frac{1}{15}$th) this appears to be due to the accumulation of a large number of very deeply stained bodies resembling micrococci completely obscuring the nucleus; in some as many as twenty or more counted; in others only two or three seen; others quite natural. One or two small vessels thrombosed; thrombi contain much granular matter, scarcely stained.

*Kidney* with a low power, no very marked change beyond very early stage of chronic interstitial nephritis in some of superficial parts of cortex. Marked cloudy swelling of epithelium of convoluted tubes. No micrococci or bacteria.

Case 5. *Acute necrosis.* (Case 17 in Appendix III.)—M. A. A—.

*Skin.*—The skin of the finger contains here and there minute abscesses, chiefly in subcutaneous tissue, not more than half a millimètre in width. They are sharply defined, contain only leucocytes, broken down in centre. In the neighbourhood of these abscesses micrococci are found scattered through the tissue, some isolated, many others double, a few in lines or clusters. No clumps or zooglœa masses in vessels. Some of the arterioles are filled with thrombi, consisting almost entirely of fibrin and leucocytes; and some micrococci are observed in them, scattered here and there.

*Brain.*—Scattered through the more superficial parts of the brain are found here and there minute abscesses (Pl. V, fig. 5) and points of infiltration with leucocytes which have not yet broken down. Numerous minute arterioles plugged with leucocytes, some of these leading to the parts infiltrated with leucocytes. Micrococci were found in these infiltrated portions.

*Heart.*—Pericardium here and there swollen and infiltrated with leucocytes, especially around vessels; many small vessels filled with plugs of leucocytes and fibrin. Near the surface numerous arterioles filled with clumps of micrococci, measuring from 6 to 15 $\mu$ in diameter; others contain only smaller masses not completely filling the vessels; some smaller clumps also seen in the tissues, not

obviously in vessels. The individual micrococci measure about ·15 to ·3 $\mu$ in diameter. (Pl. II, fig. 2, and Pl. III, fig. 1.)

Many small vessels in superficial parts of heart are filled with leucocytes and fibrin, and some micrococci are found here and there in the vessels.

*Lungs.*—Nothing of any importance was found in the lungs in parts examined.

*Thyroid body.*—Scattered through the thyroid were numerous points of suppuration, varying in size from the minutest speck to the size of a mustard seed. On microscopic examination many other foci of commencing inflammation are found. In the larger abscesses, and those completely broken down, nothing special is observed, but in several of those not yet broken down there are seen clumps of micrococci near the borders of the inflamed tract. None were found in the vessels elsewhere in any of the sections examined.

*Supra-renal body.*—In one of the sections an arteriole plugged with micrococci was found, but none in any other section; and no other changes.

CASE 6. (Case 5 in Appendix III.) Liver and kidney alone examined by logwood and methylanilin methods.

*Liver.*—Hepatic cells not obviously affected. Slight interstitial fibrosis at periphery of lobules; this very probably old. In one of the small branches of hepatic vein a thrombus was found composed almost entirely of leucocytes. No bacteria or micrococci.

*Kidney.*—Some general chronic interstitial change, rendering difficult any recognition of acute interstitial changes. Epithelium of convoluted tubules in many parts swollen, very granular, and breaking down. Hyaline, colloid, and epithelial casts in small number in straight tubes. No bacteria or micrococci discovered.

CASE 7.[1] *Amputation of left thigh for disease of knee-joint; suppuration in shoulder-joint; pyæmia.*—Jane H—, æt. 36.

*Post-mortem examination.*—Flap healthy looking, but rather deeply undermined. Lower half inch of shaft of bone bare, but not necrosed. No osteo-myelitis. No general cellulitis. Sheath of femoral vessels through its entire length thickened, infiltrated, but free from pus. Superficial femoral through its whole length filled with creamy fluid, and small shreds of soft, creamy, pinkish clot, its walls much

[1] Appendix II, Table VI, Case 9.

thickened, especially inner coat, which is of greenish-yellow colour, and rough on its interior surface, injected here and there. At the lower end, vessel filled by firmish adherent clot, and completely closed. The softened condition of the clot extended as far as the first inch of the external iliac vein, which beyond this was completely closed by a rather firm dark red clot adherent to its walls; beyond this the vessel channel again became free, and its walls were quite healthy. Suppuration in right shoulder-joint only; all the other joints of limbs healthy. Hypostatic congestion of lungs, with a few small patches of broncho-pneumonia in lower lobes. Spleen 8 oz., somewhat enlarged, firm. Nothing special in other organs.

*Microscopic examination of liver and kidney.*—*Liver* fatty, with some interlobular fibrosis resembling that in Case 1.

*Kidney*, no special change. No micrococci or bacteria were discovered in either.

CASE 8.[1] *Morbus coxæ; lardaceous degeneration; pyæmic abscess in liver. Liver.*—Presented very advanced lardaceous degeneration, together with some chronic interstitial changes. Minute abscesses were scattered through its substance. No special changes, however were discovered.

CASE 9. *Amputation of thigh.*—*Liver* fatty. Some of the liver-cells present a very peculiar deep staining with hæmatoxylin. In the capillaries adjoining are seen what appear to be double micrococci in considerable number, but not forming anywhere zooglœa masses. No other changes of importance.

CASE 10.[2] *Phlebitis of portal vein; abscesses in liver; pyæmia.*

*Portal vein and clot.*—Nothing special was found either in the portal vein and the tissues surrounding it, or in the clot *in situ*. Both presented the usual appearances. No bacteria or micrococci were found in either.

*Kidney* presented nothing special beyond some swelling of epithelium of convoluted tubules.

CASE 11. *Stump from case of pyæmia following amputation of thigh for compound fracture.*—A section about ¾ inch in depth to

[1] Appendix II, Table III, Group I (B), Case 6.

[2] Appendix II, Table VI, Group IV, Case 6.

include the granulating surface of the wound and the subjacent tissues was examined by logwood staining and Koch's method.

The granulating surface appeared healthy; the granulation cells for the most part of normal size and appearance. Towards the surface of the wound micrococci separate or in dumb-bells were seen in some abundance, but not extending more than a very short distance into the granulations, except here and there where they penetrated much more deeply.

The fatty and connective-tissue planes were for the most part natural, and contained no fibrinous exudation. But here and there the connective-tissue corpuscles were found to contain large numbers of micrococci in their protoplasm, and micrococci also lay scattered around those cells where they infiltrated them in considerable number. The contrast between these cells and healthy ones was very striking, especially in sections stained with methylaniline, and only partially cleared with acetic acid.

The blood in some of the vessels contained numerous micrococci, which appeared also to infiltrate the endothelial cells. Some of the arterioles showed a thickening of their intima, but they were for the most part natural. Some veins showed infiltration of their walls with leucocytes, which also filled the lumen, but beyond this nothing abnormal.

CASE 12.[1] *Ulcerative endocarditis.* (No. 18 in Appendix III.)—Only the spleen and kidney were examined.

*Spleen.*—Tissue for the most part natural, but here and there were masses of micrococci. They could not always be seen to be surrounded by the wall of a vessel, but in other respects were similar to those seen in other cases. (Pl. I, fig. 5.)

*Kidney.*—No micrococci discovered. Here and there were small atrophied tracts, apparently due to old infarction, but no recent change was discovered.

## SERIES II.—CASES EXAMINED BY MR. MCCARTHY.

CASE 13. *Pyæmia.* Table II, Group I (*a*), Case 13.

*Wound.*—Surface covered with a thick granular layer which stained with logwood. It was probably composed of slougby

[1] Appendix II, Table X, Group VIII, Case 1.

tissue containing numerous micrococci. No micrococci in the vessels or lymph spaces beneath.

*Secondary subcutaneous inflammation.*—Presented nothing characteristic. No organisms to be detected in a section stained in the ordinary way with logwood.

*Lungs, liver, spleen, kidneys and brain* also examined. Nothing characteristic to be observed. In one of the lumbar lymphatic glands a single colony of micrococci was observed in a vessel. With this exception the results of the examination of about fifty different slides were purely negative.

CASE 14. *Pyæmia.* Table II, Group I (*a*), Case 5.—An examination of about fifty slides from the heart, liver, lungs, spleen, kidneys, brain, and thyroid body showed nothing in the way of colonies of micrococci, or of bacteria, or microscopic points of inflammation or suppuration.

CASE 15.[1] Victor G—, æt. 2, died October 20th, 1877.

*Lungs.*—Some of the smaller blood-vessels plugged with infarcts. Extravasation of blood into air vesicles in neighbourhood of such vessels. In other parts catarrhal pneumonia, and among the cells filling the air vesicles of such parts some multinucleated cells and groups of micrococci. Small lymph follicles in walls of bronchi.

*Thyroid gland.*—Some of the larger veins plugged with coagula, in which were groups of micrococci. Other vessels filled with débris of disintegrating blood-corpuscles.

*Heart.*—Subpericardial vessels filled with blood. Thickening of pericardium in parts, due to swelling of bundles of fibrous tissue. A large mass of micrococci in one specimen, with commencing granular disintegration of surrounding muscle fibres. The mass of micrococci had in part escaped from containing vessel through a rupture of the walls, and was surrounded by some few pus-corpuscles.

*Spleen.*—In perfect preservation, and numerous sections showed nothing abnormal.

*Liver.*—Many capillaries plugged with micrococci, and in some parts, and these not always near the plugged capillaries, liver-cells were infiltrated with fat, and in some cases to such an extent that the cells after treatment with alcohol and oil of cloves resembled ordinary fat-cells after like treatment.

*Kidney.*—Glomeruli of Malpighian bodies obscured by increased

[1] Appendix II, Table IV, Case 3.

number of nuclei. Thickening of coats of afferent vessels. Epithelium of convoluted tubes swollen so as in many parts to completely obliterate lumen of tubules. Many vessels between collecting tubes plugged with micrococci, and in some parts such groups of micrococci formed centres of miliary abscesses. In some vessels fibrinous infarcts and extravasated blood in neighbourhood. In many collecting tubes small mulberry masses, composed of aggregations of small bodies, usually round, but sometimes irregular in shape from mutual pressure. These small bodies, usually about one third the size of a coloured blood-corpuscle, stained deeply with hæmatoxylin at periphery, and remained colourless at centre, and dissolved without effervescence in dilute hydrochloric acid.

*Supra-renal capsules.*—Blood-vessels in medullary part plugged with coagula containing groups of micrococci.

*Brain.*—Except an unusual number of so-called corpora amylacea nothing noticeable.

CASE 16.[1] September 18th, 1878.

*Lungs.*—Enormous quantities of micrococci, sometimes with a few intermixed blood-corpuscles, filling large subpleural vessels, sometimes in perivascular sheaths of large blood-vessels. In one specimen a small branch given off from a large vein had burst, and through the rupture blood had become extravasated into surrounding structures, and in this were large groups of micrococci (see Pl. XI, fig. 1). Throughout substance of lung many capillaries on air-vesicles were plugged with these organisms, which were also to be found mingled with the disintegrating cells in patches of catarrhal pneumonia. The surface of pleura was covered with fibrinous vegetations, and most especially where subjacent vessels were filled with micrococci. In many parts also much thickened by swelling of bundles of fibrous tissue.

*Liver.*—Connective tissue in portal canals much swollen, and in many parts crowded with colourless blood-corpuscles. Epithelium of hepatic ducts swollen so as often to almost obliterate lumen of duct. Some of the portal veins plugged with fibrin. Liver acini much changed. In some, hepatic cells swollen and cloudy; in others, the cells shrivelled, with nuclei much diminished in size or absent, and containing a great abundance of bright yellow pigment granules. In the latter kind the sustentacular structure of the

[1] Appendix II, Table VII, Group 5, Case 3.

acinus was much thickened, which was especially noticeable where the loosened hepatic cells had fallen out, leaving exposed to view the containing network. In this sustentacular structure were many connective-tissue corpuscles, some multinucleate. In a section a single acinus might be found with greatly shrivelled cells completely surrounded by acini, which differed from the normal only by cloudiness of the hepatic cells. In other parts of the same section the shrivelling process had extended through contiguous acini as to leave a comparatively normal acinus insulated. In every section capillaries could be found plugged with micrococci, often, from unequal distension, presenting a varicose appearance. Such capillaries were to be found in slightly changed acini, as well as those which were most altered from the normal.

*Kidney.*—Sections from this organ presented very different appearances at different parts. In some places the epithelium was normal, and well preserved; in other parts of the same section it was swollen, granular, and extensively detached from the basement membrane, which in parts where the loosened epithelium had fallen out appeared thicker than usual. Many of the collecting tubules contained mulberry masses, such as were described in Case 15. In other tubules the epithelium was much pigmented. The vessels varied in appearance like the tubules. Some were normal and well preserved; in others the endothelium was much detached, and either lay as a collapsed tube in the lumen of the vessel, or had its component cells separated from one another and intermixed with blood-corpuscles. In some of the glomeruli there was an increased number of nuclei; in others the walls of the component vessels were swollen and stained deeply with hæmatoxylin. Of this latter change many different stages could be observed in the same specimen, from slight swelling of some of the component vessels to complete obliteration of the lumen of all, and the transformation of the glomerulus into a homogeneous deeply stained mass. The afferent vessels were similarly affected, and all the structures in their walls seemed to participate in this change, but the adventitia most. Some of the small arteries contained apparently fibrinous embolisms. Pl. VII, fig. 3, shows such an embolus, lodged at the point where the vessel bifurcates. There was little change in immediate neighbourhood, and it had probably become lodged there just before death. Some few vessels contained groups of micrococci, but in this respect the sections of kidney presented a marked

contrast to those of the liver and lung from the same subject. Sections of brain, testicle, and of a large vein filled with a thrombus were examined, but nothing noteworthy was observed. (No other viscera sent for examination.)

CASE 17. *Lithotomy.* Group I (*a*). Case 14.—*Viscera examined.*—Heart, lung, lymphatic glands, liver, kidney, prostate gland. The only noteworthy change observed in this case was greatly increased cell growth in the connective tissue of the various organs except the heart. It was specially noticeable in the prostate and in the kidney. In the latter the glomeruli were sometimes completely masked by nuclei, and in some parts the intertubular structures crowded with small round cells to such a degree as to completely conceal the tubules. In many parts were also extravasations of blood.

In the *lungs* catarrhal pneumonia, hæmorrhage into pulmonary vesicles, and greatly increased lymphoid growths along bronchial tubes, were observed.

The *heart* appeared normal.

The *liver* was not well preserved. No micrococci in any organ.

CASE 18.[1] *Infective endocarditis.* Middlesex, September, 1878.—Viscera examined—Heart, kidney, liver, prostate gland.

*Heart.*—The subendocardial vessels of the mitral valve contained masses of micrococci. The blood-vessels showed considerable hypertrophy of the intima. This could be seen in all stages. In some vessels the intima was irregularly hypertrophied, so as to project at certain points into the lumen of the vessel. In others the change had occurred uniformly all over the intima, and this in various degrees even to complete obliteration of the lumen. The pericardial surface of the heart was in some places coated with an uniform layer of micrococci imbedded in a homogeneous substance, and in parts, where the pericardium appeared as if eroded, masses of micrococci had penetrated among the deeper structures. In some of the larger vessels in the substance of the heart were numbers of colourless corpuscles imbedded in fibrin and adherent to the wall of the vessel.

*Liver.*—Some of the larger vessels contained coagulated blood, with masses of micrococci imbedded in it.

[1] Appendix II, Table X, Group VIII, Case 2.

There were some inflammatory changes in the connective tisssue of the portal canals, but the liver-cells did not present any abnormality.

*Kidney.*—Epithelium extensively detached, basement membrane thickened, glomeruli with great increase of nuclei, and in some parts intertubular structures filled with round cells. No micrococci were found. Prostate normal.

CASE 19. *Acute necrosis of left tibia* (Appendix II, Table IX, Group VIII, Case 4).—January 18th, 1878. Organs examined—Lungs, heart, thyroid gland, liver, kidney, testicle, and thrombosed femoral vein.

*Lungs.*—Catarrhal pneumonia. Infarcts with extravasation of blood. Some large vessels with fibrinous masses containing enormous numbers of colourless corpuscles adherent to a part of the circumference. Many of the pulmonary vesicles filled with degenerating epithelium, containing groups of micrococci.

*Heart* apparently normal.

*Thyroid gland.*—Micrococci in some capillaries.

*Liver.*—Some few groups of micrococci in large vessels. Changes in connective tissue and liver-cells, similar to those in Case 16.

*Kidney.*—Epithelium swollen and granular. Some glomeruli shrivelled, with thickening of coats of afferent vessels.

*Testicle* normal.

*Thrombosed vein.*—Wall of vein much thickened by swelling of fibrous tissue; vasa vasorum distended with blood. The clot which had filled the vessel had fallen out of the sections, leaving some adherent to the inner surface. This consisted of disintegrating corpuscles, fibrin, and groups of micrococci.

*Lymphatic glands.*—Considerable thickening of wall of vessels.

CASE 20. (Appendix II, Table III, Case 16).—Organs examined—Lungs, thyroid gland, supra-renal capsule, kidney, liver, spermatic cord.

*Lungs.*—Lobular pneumonia. In some of the less altered parts capillary vessels plugged with micrococci.

*Thyroid gland.*—Blood-vessels generally much changed. In some the intima was hypertrophied, in others the middle coat presented a homogeneous appearance stained pale violet with hæmatoxylin; in others the adventitia was much thickened, apparently from

swelling of bundles of fibrous tissue, among which, in some parts, was an unusually large number of connective-tissue corpuscles. No micrococci were found.

*Suprarenal capsule.*—Some capillaries filled with micrococci. No other change observed.

*Kidney.*—In some sections was to be seen very clearly what appears to be the normal relation of the basement membrane to the epithelium of the collecting tubules, but which has not, so far as I can ascertain, been previously described. The membrane sends in processes between the epithelial cells so as when cut vertically to show, when the loosened epithelium has fallen out, a number of projecting points and a crenated border towards the lumen of the tube. When the tubule is seen from the surface these processes appear as lines running transversely to the axis of the tube, and when the epithelium has fallen out, resemble the rungs of a ladder. When the section has cut the tubule obliquely they resemble reduplications of the inner part of the membrane like valves in a vein. Pl. IX, fig 2, shows the arrangement very clearly, but they may be possibly unusually distinct from some commencing pathological change. Since, however, my attention was directed to it by this specimen, I have observed more or less distinctly a similar arrangement in many other sections from different kidneys. In the basement membrane are also to be seen stellate cells. In other sections from this kidney the epithelium of the convoluted tubules was so swollen as to altogether obliterate the lumen of the tubes. The nuclei were increased in number, and these with the compressed capillaries, the endothelial nuclei of which were more distinct than usual, alone served to distinguish the tubules from each other. The glomeruli were in many parts with greatly increased numbers of nuclei, and the larger vessels were much thickened. More particularly the middle coat, which in some places had lost all trace of any structure, and presented a homogeneous appearance deeply stained with hæmatoxylin.

*Liver.*—Some capillaries filled with micrococci. Liver-cells swollen, cloudy, and abundantly infiltrated with fat. Many also contained an abundance of bright yellow pigment granules. There were many connective-tissue corpuscles in the sustentacular structure, and colourless corpuscles in the lymph spaces between the liver-cells and blood-vessels.

*Spermatic cord.*—The connective tissue of the cord was crowded

with small, round cells, and in almost every section examined were miliary abscesses.

CASE 21.[1] *Acute necrosis of humerus; phlebitis of brachial veins; secondary abscesses in lungs, heart, spleen, and kidneys.* Organs examined—Heart, lung, kidney, liver, spleen, lymphatic gland, thrombosed vein.

*Heart.*—Pericardium much thickened in parts from swelling of fibrous tissue. Subpericardial vessels distended, some with disintegrating coloured corpuscles, others with fibrinous coagula containing a great number of colourless corpuscles. Adventitia of blood-vessels much hypertrophied. Lymph spaces between muscular fibres of heart and capillaries in many places crowded with colourless corpuscles. In other parts great increase of connective corpuscles. Some capillaries plugged with micrococci. These were found as well in parts of the heart, which microscopically showed no other change; as also in parts which were much altered from the normal. Pl. VIII, fig. 3, shows such a group of micrococci which have partly escaped from the vessel into surrounding tissue, which appears to be normal. The muscle fibre was in some places quite normal, in others marked by double transverse bars with a paler interspace, resembling an exaggerated diagram of the junction of the muscle cells of the heart. Closer examination, however, showed that this appearance resulted from a rupture of the superficial part of the muscular fibre, with contraction and swelling of the ruptured parts, and the remaining portion of the fibre appearing as the paler interspace. Many gradations of this change could be observed in different parts of the same sections. In some fibres the interspace could scarcely be made out, in others the ruptured portions had separated very widely, and the tissue between was much diminished in thickness; in others, the rupture of the fibre was complete, and only irregularly contracted, distinctly separated masses of muscle fibre were to be seen, which in other parts were represented by granular masses showing no trace whatever of muscle structure (Pl. VIII, figs. 1, 2). The heart contained numerous miliary abscesses.

*Lung.*—Extravasated blood beneath pleura and into lung substance. In some places the blood had escaped through the ruptured pleura on to the surface of the lung. A few groups of capillaries on air vessels plugged with micrococci. Catarrhal pneumonia.

[1] Appendix II, Table IX, Group VII, Case 2.

*Kidney.*—Epithelium in many parts swollen and pigmented, often completely detached from the basement membrane, which was thicker than normal. Endothelium of blood-vessels much detached. Adventitia of larger vessels swollen. Greatly increased number of nuclei in some glomeruli and afferent vessels thereof. Other glomeruli contracted to one third their normal size. Some capillaries among the convoluted tubules plugged with micrococci. Extravasations of blood beneath capsule.

*Liver.*—Liver-cells cloudy, granular, almost all studded with bright yellow pigment granules. Intralobular veins thickened, and liver-cells round them shrivelled and in many parts fallen out. Connective tissue of portal canals hypertrophied, and with increased number of cells. Many capillaries in acini plugged with micrococci without any noteworthy difference in liver-cells surrounding them. Some of the larger veins with remains of coagula adhering to the intima, and in them plumose crystals (? tyrosin).

*Spleen.*—A few capillaries contained micrococci. In many parts the Malpighian corpuscles and splenic pulp cloudy from granular matter between the lymph corpuscles. In other parts the adenoid structure replaced by masses of swollen fibrous tissue most markedly in neighbourhood of larger vessels.

*Lymphatic gland.*—Much congested; at periphery some extravasation of blood with gland substance. Vessels all distended with coagulated blood. In centre of gland a large vessel cut transversely, showing a smaller lateral branch plugged with micrococci, which projected in a mass with a free rounded extremity into the lumen of the larger vessel.

*Thrombosed vein.*—Nothing noteworthy.

CASE 22.—A. M—. Organs examined—Heart, kidney, liver, spleen, inguinal and lumbar lymphatic glands, and brain.

*Heart.*—Some muscular fibres, with an early stage of rupture similar to that described in Case 21. Nuclei of muscle fibre very large, and with Klein's network very distinctly visible. Congestion of subpericardial vessels with some small extravasations of blood. No micrococci found.

*Kidney.*—Great congestion of surface vessels. Glomeruli with increased number of nuclei. Epithelium swollen and cloudy. Some mulberry concretions in collecting tubules. No micrococci found.

*Liver.*—Hypertrophy of connective tissue round intralobular veins. Cell infiltration of portal sheaths. Liver-cells in many places infiltrated with fat, in others shrivelled, and where they had fallen out thickening of sustentacular structure; some few capillaries plugged with micrococci.

*Spleen.*—Increased adenoid growth round vessels with commencing granular disintegration of adenoid structure.

*Lymphatic glands.*—Vessels in capsule with walls much swollen, in some endothelium extensively detached. In the substance of the gland the adventitia much swollen. In many parts gland tissue replaced by considerable quantity of bundles of swollen fibrous tissue, staining pale violet with hæmatoxylin. Between many of such bundles clefts lined with endothelium, suggesting that the change has resulted from hypertrophy and swelling of adventitia of vessels, encroaching upon and replacing gland tissue. In other parts the adenoid structure swollen and similarly stained, with but few lymph corpuscles remaining. In many of the masses of fibrous tissue are giant cells of varying form. In many, however, the nuclei are arranged with such regularity at the periphery as to irresistibly suggest their origin from the intima of a blood-vessel. A great many capillaries throughout the gland were plugged with micrococci. A special point of interest in this case is that while no micrococci could be discovered in any of the other organs, every section of the glands sent for examination teemed with these organisms. Among masses of degenerating fibrous tissue many laminated bodies, sometimes irregularly spherical, and frequently trefoil-shaped (Hassel's corpuscles), are found.

*Brain.*—Numerous corpora amylacea, sometimes isolated, sometimes in groups.

*Lungs.*—Every section showed numerous vessels, capillaries, and others, filled with micrococci. Many bronchial tubes stripped of epithelium and filled with pus. Air-cells contained a very great number of large round cells filled with black pigment. Catarrhal pneumonia in many parts and extravasations of blood.

*Liver.*—Portal sheaths infiltrated with round cells, which, in many parts, were aggregated in dense round masses. Similar infiltration in centre of many acini. In such acini many liver-cells much shrivelled and pigmented. Other parts of section quite normal.

*Spleen.*—Hyaline degeneration of middle coat of vessels. Great

increase in adenoid growth round such vessels. At other parts adenoid tissue degenerating and becoming replaced by swollen fibrous tissue.

*Kidney.*—Some vessels with micrococci. Great increase of nuclei in glomeruli in afferent vessels. Cellular infiltration of intertubular substance. Extravasations of blood.

*Coagula from large veins.*—Some sections showed intermingled micrococci.

No other organs sent for examination.

CASE. 23. *Thyroid gland.*—To the naked eye this organ appeared so healthy and well preserved that sections were made for demonstration of the normal structure of the gland. Many capillaries were found plugged with micrococci, and in larger vessels masses of these organisms, usually spherical in form, were to be seen in coagula of blood and fibrin. No other change observed.

*Lungs.*—Many of the smaller bronchi stripped of epithelium and filled with pus; catarrhal pneumonia; numerous capillaries on air-cells filled with micrococci.

*Heart.*—No observed change.

*Kidney.*—Every section examined contained many groups of micrococci; sometimes in capillaries, in which they could be traced through several branches, sometimes as large round masses, which had escaped from the ruptured vessel. Epithelium well preserved, but in some parts detached from basement membrane. In some tubes mulberry concretions.

*Liver.*—Some capillaries contained micrococci. Liver-cells infiltrated with fat.

*Inguinal glands.*—Vessels much congested; some in capsule contained micrococci.

CASE 24. *Thyroid gland.*—Capillaries plugged with micrococci.

*Lung.*—Bronchial tubes in many places with epithelium detached or altogether gone, and with lumen filled with pus. In some parts lymph-follicles in walls of tubes. Extravasations of blood into air-vesicles; catarrhal pneumonia; capillaries in air-vesicles plugged with micrococci. In other parts air-vesicles filled with pus. Subpleural lymphatics in parts much distended and their walls thickened, so as to form distinct projections above the surface of the pleura. At other parts fibrous vegetations.

*Heart.*—Pericardium much thickened from swelling of fibrous tissues and considerable cellular infiltration. In some parts miliary abscesses. In other parts, vessels plugged in varicose form with micrococci. Intermuscular substance of heart infiltrated with cells so as in some places to greatly obscure muscle structure. Mitral valve normal.

*Liver.*—Thickened connective tissue of intralobular veins and cell infiltration of portal sheaths; bile ducts nearly occluded by swollen epithelium; liver-cells much pigmented, and capillaries in many parts filled with micrococci.

*Supra-renal capsule.*—A group of capillaries together with parent trunk, all plugged with micrococci. No other changes observed.

*Kidney.*—Epithelium swollen. Many tubes plugged with mulberry concretions and others with homogeneous coagula staining deep violet with hæmatoxylin. Numerous miliary abscesses which in some parts had completely destroyed all kidney structure. In others dilated Malpighian bodies and the tube leading from them were covered with pus corpuscles, so as by their shape alone to show what they had originally been. Many vessels filled with micrococci. One such in the centre of a small abscess.

*Spleen.*—Increase of adenoid tissue. Many vessels plugged with micrococci.

*Lymphatic glands; lumbar and axillary.*—Swollen, vessels thickened, some in lumbar gland filled with micrococci. Also an abundance of bright yellow pigment granules.

CASE 25. *Pyæmia.* (Appendix II, Table VII, Group V, Case 9.)

*Lungs.*—Pleura much thickened; in parts great dilatation of lymphatics and rupture at surface of pleura. Micrococci in subpleural vessels and on surface of pleura. Congestion of blood-vessels with micrococci either filling up lumen of tube, or as round masses in coagula of fibrin and corpuscles. In parts, catarrhal pneumonia with micrococci in disintegrating epithelium.

*Liver.*—In some parts liver-cells cloudy. Nucleus invisible; outlines of cell indistinct. In others, cells containing much pigment and separated by greatly distended lymph spaces. Many capillaries contain micrococci.

Cellular infiltration of portal sheaths. Great thickening of sustentacular structure.

*Kidney.*—Great thickening of intima of larger vessels, smaller

vessels with micrococci. Swelling of matrix near papilla, epithelium detached at many parts, at others swollen and cloudy.

*Coagulum from femoral vein* contained groups of micrococci. No other part preserved for examination.

CASE 26. *Pyæmia.* (Appendix II, Table II, Group *a*, CASE 19.) —Portions of almost all the organs of this subject, including some of the skin over the forehead where a swelling had been observed during life, were examined. In prostate, bladder, and kidney were evidence of inflammatory changes to a considerable extent, both old and recent. The subcutaneous structure of forehead was œdematous, and infiltrated with round cells, but no micrococci could be found. Cf. Case 17.

CASE 27. *Pyæmia with multiple suppuration.*

*Lung.*—Purulent pneumonia; extravasations of blood. Some vessels plugged with laminated fibrin, a few micrococci seen in coagula in vessels, others in disintegrating cells and air-vesicles.

*Liver.*—Very considerable thickening of connective tissue round intralobular veins. Cell infiltration of portal sheaths, often to a considerable degree, and round small bile ducts, of which, however, the epithelium was normal, and the lumen, if anything, dilated. Liver-cells, some infiltrated with fat, others much pigmented, frequently shrivelled and disintegrated, round intralobular vein, and in some parts replaced by groups of small round cells.

*Kidney.*—Matrix near papilla much swollen and granular; basement membrane throughout more distinct than normal, and taking blue stain with hæmatoxylin. Epithelium unusually well preserved. Some blood-vessels plugged with coagula. Malpighian capsule and commencement of tubules often filled with homogeneous deeply-stained coagulum. A very few capillaries contained micrococci, and some larger vessels had small irregular patches of coagula adhering to the intima, and containing micrococci.

*Spleen.*—Adenoid tissue extensively replaced by fibrous tissue; in some parts altogether, in others much less. Other parts quite normal. Extravasations of blood.

CASE 28. *Necrosis of femur; secondary abscesses in lungs.*—Male, æt. 54. *Post-mortem* twenty-eight hours after death.

[1] Appendix II, Table VIII, Group VI, Case 1.

*Kidney.*—Some of the veins near surface of kidney were so enormously distended that not more than about half could be got into field of microscope with No. 4 object, Hartnack. These vessels were some filled with laminated fibrin, others with grey-coloured débris, which with No. 11 immersion, Hartnack, was seen to consist of very minute uniform granules, perhaps débris of decomposing blood. Smaller vessels had similar débris intermixed with fragments of laminated fibrin. In centre of kidney some vessels with laminated fibrin adhering to walls of very irregular thickness. In one Malpighian body a single vessel of the glomerulus was enormously distended with bacteria. The vessel had ruptured, and the bacteria had escaped into cavity of capsule, and then expanded in a cauliflower-like mass (see Pl. X, fig. 1). The matrix was much swollen, and in many places stained violet. The basement of convoluted tubes was much thickened, stained blue, and in some parts where the epithelium had fallen out showed processes such as were described in Case 20, but much thickened and deeply stained (Pl. IX, figs. 3, 4). Epithelium throughout very granular and detached. Specimen not in good preservation.

In many of the Malpighian bodies there was laminated coagulum between glomerulus and capsule. In others no trace of structure could be made out, all being replaced by a homogeneous, deeply-stained violet mass. Many of the convoluted and straight tubes contained similar material.

*Axillary vein.*—Filled with coagulum. Two bands of fibrin extended across lumen from wall to wall, dividing vessel into three compartments. The central contained fine bands of fibrin radiating from the limiting bands and many colourless corpuscles, the lateral compartments only coloured corpuscles. Walls of vein much thickened. Vasa vasorum congested, and some containing micrococci. Tissue round vein much infiltrated with small round cells.

*Axillary gland.*—Vessels both in capsule and gland substance much thickened. Those in gland substance usually homogeneous in appearance and deeply stained. Some micrococci in vessels.

*Thyroid gland.*—Changes in vessels similar.

Cases 29, 30, 31. These were so much alike that one description may do for all:—Catarrhal pneumonia, infarcts, extravasations, thickening of pleura, interstitial inflammation of heart, liver and kidney, fibrous changes in spleen.

CASE 30. Bacteria were found in a medium-sized vessel in heart, and in a glomerulus of kidney; but their position, free in the lumen of the otherwise empty vessel, suggested the possibility of *post-mortem* origin.

All these cases, but more especially 30, showed swelling of matrix, which reached even to free border of kidney in some places. It had a ground-glass appearance. Many of the glomeruli appeared as homogeneous violet-coloured masses.

31 showed in liver extensive fatty degeneration, but sometimes curiously limited to a single cell. Thus, in a section, a cell might be seen composed of a narrow ring of protoplasm, and a large cavity representing where the dissolved fat had been. Such a cell would be separated from any similar cell by several comparatively normal cells. In other parts a group of cells would be seen so changed. Micrococci were found in liver and kidney of this case and not in the others.

JEREMIAH MCCARTHY,
W. S. GREENFIELD.

# REPORT.

## SESSION 1878-79.

---

## DISEASES, ETC., OF THE NERVOUS SYSTEM.

### 1. *Diffuse punctiform hæmorrhages in substance of cerebral hemispheres, in an instance of extreme congestion of brain due to obstructed pulmonary circulation.*

By Sidney Coupland, M.D.

The specimen exhibited presents a condition which I believe is a very unusual result of severe mechanical congestion of the brain of short duration. It is a pathological truism to say that anatomically vascular congestion is known only by its effects, for the condition itself (mere distension and fulness of vessels) affords no safe criterion. For even when carried to an extreme degree the condition of "vascularity" of an organ is liable to so many modifications, from the mode of death, the position of the body at and after death, the condition of the blood and the elasticity of the walls of the vessels. There is no organ which illustrates this more strikingly than the brain; for here it is notorious that symptoms obviously due to hyperæmia may leave behind no record, whilst, on the other hand, a condition of mere vascularity alone counts for little as an indication of the state of the cerebral circulation during life. In spite of this there is a lingering opinion that when the white matter of the cerebral hemispheres appears on horizontal section to be studded with "puncta cruenta" there must have necessarily been excess of blood in the brain during life. Practically, however, this is no true

and safe indication, and it is not until by its intensity or long continuance that congestion has led to rupture of vessel and hæmorrhage, or to vascular dilatation and surrounding induration, that definite and obvious changes are produced; and records of a permanent character are left by a phenomenon commonly so transitory and fleeting.

In the present instance the hyperæmia was of short duration, but of severe degree. It was due to an attack of acute bronchitis in an emphysematous subject, and was therefore complicated with asyphyxia, which may in part explain the striking effects produced. The facts of the case are these. I am indebted for the notes to Dr. Greenhow, who has kindly allowed me to bring the case before the Society.

Caroline D—, æt. 21, a tailoress, was admitted into the Middlesex Hospital under the care of Dr. Greenhow, on November 30th, 1878. She was an undersized, stunted, ill-nourished girl, with a narrow but deep chest. She had always been delicate, had suffered from measles and scarlet fever when young, and had been subject to a cough from infancy. For the past two winters she had been obliged to lay up on account of her cough. Exposed to all weathers on her way to work, she took cold about a month before admission, and became eventually so ill as to compel her to cease work and to seek relief at Gerrard Street Dispensary, whence she was sent to the hospital.

On admission she was suffering from great dyspnœa; features markedly cyanosed; finger-ends bulbous and nails slightly incurved. There was a slight but frequent and abortive cough. There was no œdema. Chest markedly emphysematous; its respiratory movements mainly clavatory. The percussion resonance was not very clear in either infraclavicular region; whilst posteriorly there was slight dulness in the left supra-spinous fossa. The expiratory murmur was everywhere prolonged, and in front was attended with rhonchus. Rather fine crepitation at base of left lung, and râles of a coarser type over lower three fourths of right back. Heart's impulse felt in epigastrium; both sounds were loud, and there was a rough systolic open murmur. At 1 p.m. temp. 98·2°; pulse 140; respiration 40. At 9 p.m. temp. 99·2°; pulse 144; respiration 38. At midnight the dyspnœa was increased, and pulse feebler. The following are brief notes of her daily progress.

December 1st, 9 a.m.—Temp. 98·4°; pulse 140; respiration 40. Did not sleep in the night. The cough is not very troublesome and she

has expectorated some viscid, mainly purulent material. Continues much cyanosed; urine, sp. gr. 1030, acid, free from deposit and from albumen. There are abundant sonoro-sibilant râles audible throughout the chest; moist sounds predominate at the bases. 9 p.m. temp. 100°; pulse 126; respiration 44. Breathing laboured and shallow. Is continually moaning, and is very restless, tossing her arms about. At 6 p.m. she had a severe attack of urgent dyspnœa, relieved by wet-cupping to the extent of 2½ ounces.

December 2nd, 9 a.m.—Temp. 99°; pulse 132; respiration 40. Has been moaning nearly all the night; only occasionally dozing, but there is continual jactitation; she now lies in a semi-comatose state, passes urine involuntarily. There is an audible tracheal râle, but the lividity is less than yesterday. 9 p.m. temp. 99·4°; pulse 124; respiration 40. Has not spoken all day; decubitus dorsal and low in the bed; breathing very shallow. There is no expectoration, and she can scarcely swallow.

December 3rd, 9 a.m.—Temp. 99·4°; pulse 132; respiration 36. Lies in the same semi-comatose state; moaning at times. Pulse is compressible. There is an occasional abortive cough, and coarse bubbling râles are audible all over front of chest. The systolic murmur is no longer to be heard. She cannot be made to swallow any food. 9 p.m. temp. 100°; pulse 132; respiration 36. Has remained much in the same state all day, but has swallowed some beef tea and brandy this evening. The lividity has again increased.

December 4th, 9 a.m.—Temp. 100°; pulse 124; respiration 40. There is now less lividity. The coma continues, but at one time there was slight apparent consciousness. She takes a little food. 9 p.m. temp. 102·6°; pulse 136.

December 5th, 9 a.m.—Temp. 101°; pulse 120; respiration 34. Is now completely unconscious, but the breathing appears easier and the lividity is less. The cough is not so frequent, and she takes a little nourishment. 9 p.m. temp. 104·2°; pulse 144; respiration 40. Sweating profusely. Lies in the same unconscious state; pupils equal and sensitive to light. There is no paralysis of limbs. Abundant moist bubbling râles all over front of chest. Heart sounds loud. Lividity again increased.

December 6th, 1 a.m.—Pulse 160; respiration 52. Breathing shallow and gasping. 9 a.m. temp. 104·2°; pulse 156; respiration 32. Is much weaker. Pulse is small and running. General condition is unchanged. 7 p.m. temp. 105·6°; pulse 180. She died at 10 p.m.

The *post-mortem* examination was made sixteen hours later. There was pronounced cadaveric rigidity and lividity.

*Head.*—The dura mater was natural; its sinuses contained fluid blood and some loose gelatinous clot, but no adherent coagula. Pia mater on convexity notably vascular; not only were its veins engorged with blood but the whole membrane was marked by finely injected vessels. There was no fluid beneath it, and no flattening of convolutions. Arteries at base normal. No inflammatory exudation in any part of the membrane. The *brain* was firm; there was no undue vascularity of grey matter; no hæmorrhages into it. But pervading the whole of the central white substance of the cerebral hemispheres were numerous red points and dots varying in size from a pin's head to a mere pin's point, some of a dark purplish colour, others of a bright red; they thickly studded each cut surface of the *centra ovalia* as they were successively exposed to view in layers. These "puncta" could not be washed away by a stream of water, whilst the brain tissue around and between them had a faint yellowish and orange-coloured tint. There was *no softening;* indeed the brain was remarkably firm in consistence. Singularly limited to the central white substance, hardly any of these red points were met with in the medullary rays of the convolutions, and none occurred in the cortex itself. There was no fluid in the lateral ventricles, of which the walls were natural, with the exception that beneath the ependyma of the right posterior cornu were several red points, evidently hæmorrhagic. The occurrence of these suggested the hæmorrhagic character of the others, a conclusion further borne out by the fact that when cut in any direction they invariably maintained a circular or nearly circular outline. There was much vascularity of the choroid plexus and the velum, and the veins of Galen were full of blood. The optic thalamus and corpus striatum on each side were natural and firm, cerebellum, pons, and medulla natural.

*Thorax.*—Both lungs bound to parietes by old and firm adhesions. They were both pigmented and emphysematous, and greatly congested in their dependent parts; whilst the bronchial tubes were filled with opaque muco-pus. The right side of the heart was distended with fluid blood; and soft black clot, partly gelatinous, was contained with the meshes of the chordæ tendineæ and columnæ carneæ. The walls of the right ventricle were tough and thick, viz. $\frac{5}{16}$ inch. The left ventricle firmly contracted and empty; its

contracted wall measuring ½ inch in thickness. The valves were natural, their orifices having the following circumferential measurements:—

Right auriculo-ventricular—3½ inches. Pulmonary—2½ inches.
Left auriculo-ventricular—3 inches. Aortic—2¼ inches.

The abdominal viscera presented all the characters of chronic passive congestion.

Thus, it will be seen, the case was by the condition of the brain lifted out of the ordinary category of cases of death from severe bronchitis complicating emphysema. No doubt remained, after microscopical examination, that most of the red points were foci of hæmorrhage. The preparations and drawings before the Society show clearly the existence of blood outside as well as within the vessels, displacing the nervous tissue.

But the question arises, By what means has such wide-spread capillary hæmorrhage been brought about? Why also is it limited to the white matter? It is a rule almost without exception that this form of "capillary apoplexy," as Cruveilhier termed it, is limited to the condition of red softening, and is attributable to blocking of vessels by thrombosis or embolism. Thus it is seen around the seat of a large hæmorrhage, in the vicinity of rapidly growing tumours, and in embolic areas. It is also seen frequently to a marked extent in cases of thrombosis of the large dural sinuses, but in such cases the hæmorrhage is most marked in the pia mater and the cortex. Dr. Bright in the second volume of his 'Reports of Medical Cases' figures (Plate VI) such a case, where there was ante-mortem clotting in the longitudinal sinus, and in the veins entering it. The drawing shows punctiform hæmorrhage in the substance of both hemispheres, especially in and around the grey matter, which at one part of the anterior lobe was in a condition of red softening; and there was also extensive hæmorrhage in the pia mater both on vertex and base.

The case I bring forward seems to me to fall under a similar category. Indeed, the appearances must be due either to obstructed return of blood from the cerebrum or to disease of the walls of the cerebral vessels, or to altered condition of the blood. The second alternative is quite out of the question, for the wide-spread and symmetrical disposition of the hæmorrhages would at once negative it. Nor did the microscope reveal any change in the walls of the vessels of a degenerative kind. In the belief, then, that there is here a rare instance of the effects of severe mechanical congestion of the

brain, due to the obstructed pulmonary circulation, I hasten to add that the actual extravasation, widely diffused as it was, must have been a late event in the history of the case, for no softening of brain substance has been caused by it; and it seems probable that in the rapid rise of temperature on the day preceding death we have clinical evidence of the occurrence of the stasis and hæmorrhage. In Plate XIX, fig. 6, of the second volume of his reports, Bright figures a portion of brain showing extreme congestion of the minute vessels, from a man in whom the lungs were "extensively hepatised and œdematous." But it does not appear that actual ecchymosis occurred in that case. How far the carbonisation of the blood in these asphyxial conditions would aid in determining its escape from the feebly supported vessels in the cerebral hemispheres I do not know. "Congestion of the brain" is a constant feature of asphyxia, but congestion sufficient to produce general capillary hæmorrhage is surely exceptional, but by no means inconceivable.

*January 7th*, 1879.

---

## 2. *Hæmorrhage into the cerebellum; rupturing into the fourth ventricle.*

By W. Allen Sturge, M.D.

E. W—, a labouring man, æt. 43, was admitted into the Royal Free Hospital, on April 25th, 1879, in a comatose condition. The only history that could be obtained was that he was intemperate in his habits, that his eyesight had been failing for about six months, during which period he had been in the habit of getting up at night to pass water; and that for some days prior to his attack he had complained of strange feelings in his head. About 10 a.m. on the morning of the day of his admission he was seized with giddiness, and vomited some clear green fluid. He continued to feel giddy and to vomit all the morning, but remained at his work. About 1 o'clock he became somewhat suddenly unconscious, and remained so until his admission at 8 p.m. His breathing was at that time stertorous; pupils contracted. Heart sounds normal. Thirty-

four ounces of urine were drawn off, which contained about one eighth of albumen. Shortly after admission his breathing became very slow, not more than three or four respirations taking place per minute. He died at 9.30 p.m.

*Post mortem.*—The membranes of the brain were found to be somewhat congested. The lateral ventricles were distended with a quantity of blood-stained serum containing fragments of clot. The foramen of Monro was filled up with coagulum, which completely filled the third ventricle. Thence the clot could be traced down the aqueduct of Sylvius, which it had distended to the size of a large crow-quill, into the fourth ventricle. The cerebellum was found to contain a large clot which had nearly destroyed the right lobe, and had encroached on the left lobe. Near the middle line was a ragged opening leading from the clot-filled cavity in the cerebellum into the fourth ventricle, thus accounting for the presence of the clot in this and in the other ventricles. The kidneys were congested, and presented the appearance of an early stage of the granular change. The bladder contained about 20 oz. of albuminous urine. The other organs were healthy.

*April 29th*, 1879.

---

### 3. *Dermoid cyst of the brain.*

By J. Pearson Irvine, M.D.

This specimen of dermoid cyst of the brain was removed from the body of a female child (æt. 7), who was under the care of Dr. Julius Pollock, in Charing Cross Hospital. She was admitted in April, 1878, on the surgical side, was thence transferred to the medical ward, and some notes of her early condition have been on this account accidentally mislaid. Her history prior to admission was almost *nil*, and the little given of doubtful character. Her friends could not be depended upon, and all that could be determined with certainty was that the child had for some months been suffering from a gradually increasing loss of power in the lower

extremities, and that she had fallen violently on the back of the head two years before the time of admission.

*On admission* there was decided loss of power in the legs, which was attributed to some surgical spinal lesion not uncommon in children of her age. The loss increased during her stay in hospital, and at length became absolute. Sensation was also impaired. A double internal strabismus gradually developed, and general convulsions occurred on several occasions. The temperature was very variable, but usually there were daily rises to about 101° Fahr. during the first fortnight after admission. Afterwards there were at times seven or eight day periods in which the temperature was subnormal. There was no interference with the mind, and the patient who died on June 6th, 1878, retained consciousness to the last. Owing to the unfortunate loss of the earlier notes of the case I am not able to furnish more than the above meagre clinical history.

At the *post-mortem* examination the body was fairly well nourished. The spinal column was first opened, and the cord examined *in situ;* then the skull cap was removed and a triangular piece of bone, which took with it the posterior half of the foramen magnum, so that the brain and cord could be examined, and then removed together. The skull cap was very thin and brittle, and posteriorly was adherent to the membranes of the brain. On endeavouring to cut through the dura mater over the right lobe of the cerebellum a quantity of pus escaped, and it was found that the brain membranes were completely grown together. A transverse incision was made, and an abscess discovered which had invaded the greater part of both hemispheres of the cerebellum. This abscess was bounded without by the membranes and within by brain substance, changed as in most cerebral abscesses. The abscess contained puruloid matters, cheesy masses and shreds of tissues, and its walls were lined by a thick layer of cheesy soft substances, which had all the appearances of those described as sebaceous. But beyond all these the cavity contained a tuft of hair, rolled in a somewhat regular coil, pale and etiolated as compared with the brown hair of the head. (The tuft and a specimen of the normal hair were shown to the Society).[1] Microscopically, the hair which escaped from the skull had all the characters of true hair. Thus, what seemed at first sight an abscess was really a cyst of dermoid nature. It involved

[1] These specimens are in the museum of Charing Cross Hospital.

the greater part of the cerebellum, and had extended downwards so as to invade and partly destroy the posterior region of the medulla oblongata, and the upper portion of the cervical cord; but the parts were fragile, and it was impossible to determine the exact extent of destruction. The cord below was normal. The lateral ventricles were greatly distended by pale limpid fluid, and at the base of the brain there were further evidences of obstruction of vessels. The brain-substance generally was soft. The viscera of the thorax and abdomen were healthy.

The specimen is a pathological curiosity. It is unquestionably one of dermoid cyst of the brain, and must have commenced therefore in the earliest period of fœtal life. The explanation of its occurrence is not difficult. During the development of the fœtus a portion of the dermoid layer must have shared in the process of involution of the epiblast, and though enclosed in the skull must have remained capable of producing skin-products almost equally with the true skin. So we found accumulations of sebaceous matter, and above all a tuft of well-formed hair, which clearly indicated the sebaceous nature of the cyst. It is remarkable that the brain should have so long adapted itself to this extraordinary accident of development and its consequences. Is it not possible that the severe fall on the head, of which there was a clear history two years before death, set up in the cyst, an inflammatory process; that secondary changes occurred in consequence, and enlarged the cyst, so that as an abscess it encroached upon the brain and finally caused death? This is the only instance of dermoid cyst of the brain recorded in the 'Transactions' or elsewhere, as far as I can ascertain. *November* 19*th*, 1878.

---

### 4. *Spinal cord from a case of infantile paralysis.*

By Frederick Taylor, M.D.

M. A. R—, æt. 3, was admitted into Guy's Hospital, under Dr. Habershon's care, on October 23rd, 1878, and died November 6th. From an early age she had been the subject of infantile paralysis, but the immediate cause of her death was broncho-pneumonia.

The history of the paralysis given by her mother is as follows:—When fifteen months old she was taken rather suddenly ill one day, and appeared to have something the matter with the hip. For a time it was supposed that she had received a blow, but of this there is no real evidence whatever. For three days she was feverish, and it was then noticed that the left leg was paralysed, and so painful that she could not bear its being lifted. The pain continued ten days longer, and then completely subsided. The paralysis, however, remained, but no other part of the body than the left lower extremity was, as far as the mother knows, at any time affected. She was seen by a doctor, and in course of time the limb was galvanised by a magneto-electric machine. At first there was no response to the current, but after a few months the muscles distinctly reacted; and about six months after the commencement of the illness the child was enabled to support herself on the leg, and even to walk. In September of this year, 1878, she began to cough and to lose health, and she was brought to the out-patient department of Guy's Hospital. There her cough was prescribed for, and at the same time she attended three times a week to have the limb galvanised. While this was being done on October 2nd she coughed up a considerable quantity of blood, and continued subsequently so ill with cough, hæmoptysis, and mucous expectoration that she was admitted into the ward, where she died a fortnight later. The left leg was noted to be smaller than the right, and to have very little power in it.

On examination *post mortem* the child was fairly nourished. The lungs were affected with extensive broncho-pneumonia and pleurisy; the other thoracic and the abdominal viscera were healthy.

The lower extremities were both rather small, but there was no very obvious difference between them either in thickness or length; the foot, however, was narrower on the left side, and the toes looked shorter. On cutting into the muscles on the left side they were found to be extremely pale, pinkish-yellow in colour, soft and gelatinous in consistence. They contrasted remarkably with the corresponding muscles of the right side, which were of the natural deep red tint. The muscles of the back and front of the thigh and the calf of the leg were thus affected, but the psoas and iliacus were healthy. The gluteal muscles and those of the anterior tibial region and sole of the foot were not examined.

The left anterior crural nerve was somewhat less brilliantly

white than the right, but there was no appreciable difference in size.

The brain was healthy and weighed 41 oz.

The spinal cord was of the size one would expect at the age of three, was firm and appeared at first healthy, but transverse sections through the lumbar region showed a slight diminution in the size of the left half of the cord, and the anterior roots of the lumbar nerves also appeared smaller.

The spinal cord and portions of muscle were given me for further examination, and they were placed in chromic acid. After hardening and staining in this reagent, transverse sections showed, even to the naked eye, a very distinct affection of the left side of the cord in the lumbar region. It was, in all its measurements, smaller than the right side: thus, transversely across the commissure—

Right side, 3½ mm. Left side, 2½ mm.

Antero-posterior measurement of grey matter—

Right side, 4½ mm. Left side, 3½ mm.

Transverse measurement of anterior cornu—

Right side, 2½ mm. Left side, 1½ mm.

The difference in size is chiefly to be referred to the anterior cornu, but it is also quite clear that the antero-lateral column and the posrior cornu are smaller on the affected side. On examination with the microscope the deviations from the healthy standard are very striking. In the first place there is, on the left side, an almost complete absence of the motor ganglion cells of the anterior cornu; in most sections a few are visible, commonly one or two in the most anterior part of the cornu, and a few along its innermost border near the commissure. But the larger groups, which normally occur in the centre and at the outer border, as well as the small group at the antero-internal angle, often occupying together nearly two thirds of the whole cornu, are totally unrepresented. The few cells that remain in front are small in size, have but few processes, and are pale in colour, that is to say, they are not so deeply stained as the corresponding cells on the opposite side.

The next most striking feature is the absence of the axis-cylinders, which naturally form a complete network in the anterior cornu, especially in its anterior part. That this is not a mere accident of staining is shown by the fact that, on the opposite side, the front part of the cornu presents quite the usual appearance. On the left side, however, it is only here and there, close by the margin, that a

few axis-cylinders run for short distances from some of the root-fibres into the substance of the cornu.

Thirdly, there is a marked alteration of the tissue forming the basis of the grey matter. Instead of its forming an open spongy structure, with delicate-walled capillaries easily visible within it, in this case it presents an almost uniform felt-like appearance, the result of the close matting together of the finest possible fibres. In the neighbourhood of the white columns these fibres can be traced from the nerve root-fibres radiating into the substance of the cornu, never reaching so far as the axis-cylinders do in the same position, but losing themselves in the general substance of the cornu. Elsewhere the fibres run in all directions, grouped more or less, but no group running for more than a very short distance without interruption by others. Scattered throughout are round and oval connective-tissue nuclei of the same size as, and no more numerous than, in the normal grey cornu structure. In this tissue are here and there imbedded the remaining axis-cylinders and atrophied nerve-cells, the latter wanting the clear translucent space which surrounds the healthy ganglion-cells. Over the greater part of this indurated tissue the vessels are less numerous. In many sections a large main trunk runs through the centre of the cornu, with a wide space and much perivascular tissue about it, but there are scarcely any capillaries to be seen. Near the outer border, however, there are many vessels, not, I think, really more numerous than usual, but more prominent on account of the deep staining which their thickened walls take from reagents.

No granular corpuscles were found in any specimens.

The antero-lateral columns show distinct traces of being diseased. The structure close to the grey matter is much more dense than natural; the nerve tubules, as shown on transverse section, are smaller; and the connective-tissue bands are more abundant, so that in places, especially along the outer border of the cornu, it is difficult to be sure where the grey matter ends and the white column begins. The root-fibres passing to the surface are wanting in the proper amount of nerve-fibres, recognisable by the staining of axis-cylinders. Some of the tracts show a proper proportion of axis-cylinders, but others appear to consist only of bands of the same fine fibres which have already been described as radiating into the grey cornua (see Pl. XII, figs. 2 and 3).

In the posterior half of the cord the grey cornu and white columns

## DESCRIPTION OF PLATE XII.

Plate XII illustrates Dr. F. Taylor's case of Diseased Spinal Cord in Infantile Paralysis. (Page 197.) From drawings by himself.

FIG. 1.—Represents a transverse section of the lumbar enlargement of the spinal cord, magnified 12 diameters. Scarcely any cells are visible in the left anterior cornu, and they are very deficient in the central and outer parts of the right cornu. The left side of the cord is much smaller than the right.

FIG. 2.—From the antero-internal angle of left anterior cornu, with adjacent anterior column. Magnified 180 diameters. It shows the dense felt-like structure of the grey matter, with scattered nuclei; entire absence of nerve-cells and axis-cylinders. One nerve-root contains many axis-cylinders, but the others are made up entirely of connective tissue.

FIG. 3.—From the anterior border of left anterior cornu, with adjacent anterior column. Magnified 160 diameters. The same dense connective tissue, and in addition, *a*, axis cylinders; *b*, atrophied nerve-cells.

Fig 1

x 72

Fig. 1.

nat size

Fig 2

x 180

3

a

b

share the reduction of size which the whole left side suffers, but there is no essential alteration in kind of structure.

Microscopic examination of the anterior nerve-roots shows that those on the left side are not entirely devoid of nerve-fibrils, but these fibrils are, for the most part, only one half the thickness of those on the right side, while they are only scattered here and there and are surrounded by a quantity of white fibrous tissue, consisting of delicate fibres in longitudinal parallel bundles. On the right side the nerve-fibres measure $\frac{1}{2000}$ in., on the left side $\frac{1}{4000}$ in. I could detect no difference in the fibres of the sensory roots of the two sides.

I should not omit to mention that though the left limb alone was paralysed, and the muscles and nerve-roots of the right side appear to be perfectly sound,[1] yet the anterior cornu of the right side presents some rather remarkable features. They are, especially, the absence, through the greater part of the lumbar region, of a considerable number of ganglion-cells, as compared with the grey matter of a number of presumably normal cords in my possession. There is no mistaking it for the cornu of the left side, but nevertheless the centre and the outer part of the cornu are almost entirely devoid of the usual ganglion-cells and axis-cylinders, and consist only of the neuroglial basis of the grey matter. Moreover, at the antero-internal part this substance is much more dense, presenting almost the same characters as some of that on the affected side (see fig. 2). The lesion of the grey matter of the spinal cord was confined to the lumbar enlargement.

Portions of muscle from the left lower extremity showed very complete granular and fatty degeneration of the fibres; striations being entirely absent in some specimens.

*Remarks.*—The present case adds one more to those which have been accumulating within the last ten years (especially on the Continent) to show that the disease known as "infantile paralysis" is connected with a definite lesion in the spinal cord. Cases on record have been arranged in two groups, according as the paralysis and atrophy have been in existence prior to *post-mortem* examination a short time, such as a few months, or a longer time, such as two or more years. In this instance the disease had commenced one year and three quarters before death, and the case may there-

[1] The muscles were only examined with the naked eye, but the nerve-roots microscopically after teasing, and on transverse section.

fore be classed with the latter group. With the several instances of this group it agrees in the absence of ganglion cells, and in the increased density of the connective tissue of the grey matter. The absence of granule-corpuscles and of any considerable number of connective tissue nuclei is in accordance with the relatively long duration of the spinal affection. One feature in the case remains unexplained, namely, the deficiency of ganglion-corpuscles in the right anterior cornu, on the side of the healthy limb. This might have been cleared up by a more complete examination of the right limb both before and after death. *February 4th*, 1879.

---

5. *A portion of the spinal cord, with drawings and microscopical specimens, from a case of acute anterior poliomyelitis in a child, fatal within six weeks from the onset.*

By F. Charlewood Turner, M.D.

A. A—, æt. 2½, a well-developed child, and of healthy parents, was admitted into the London Hospital on November 29th, 1877, with paralysis of all her limbs, attributed to a fall a month before. She came under the care of Mr. Hutchinson, by whose kind permission the case is brought under the notice of the Society.

It was stated that the child had had inflammation of the lungs when three months old, and had had convulsions during dentition. Just four weeks before her admission to the hospital, on Thursday, November 1st, the child had been taken up stairs, and was descending again, when she slipped and fell on her back. For a fortnight after this she played about as usual; but on the Wednesday week following the accident she complained of being cold all the morning, and later in the day she became quite ill, and she has not moved her legs since. It had been noticed that for two or three days previously the child had been very sleepy, and not so bright and lively as usual. On the Saturday following the mother noticed that the child could not get her arms to her head. When admitted the child had an anæmic appearance, but tolerably good muscular development. She

lay on one side with her head thrown back, and her legs extended. The head could be rotated and bent backwards, but could not be bent forwards without signs of pain. The legs were not moved; the arms were moved now and then. There was no reflex action of the legs on tickling the feet, and sensation over these limbs was lost. In the upper limbs it seemed to be perfect. Slight enlargement of the articular ends of the radii and of the ribs was noticed. The evacuations were passed involuntarily. The temperature was observed to vary during the first week between 99° and 100°; on December 7th it was at the normal point, and subsequently remained below that level. The pulse was unaffected.

December 6th.—The child lies in the same quiet state. She sleeps well. Appetite good. Temp. 99·4°. Child is fretful.

10th.—More lively, the head no longer thrown back, and she now lies on her back.

11th.—Evacuations still involuntarily; the urine reported to be abundant. Sensation is restored in the legs, and they are drawn up a little this morning. The arms are much better, their movements being quite free.

12th.—The child can move the toes slightly.

17th.—The temperature had risen to 102° in the morning; the eyes were slightly suffused, but no rash could be seen. She had had a little cough for a day or two, and this was more troublesome. The evacuations continued to pass involuntarily. The left arm seemed to be more powerful than the right. In the evening the temperature had risen to 104°.

20th.—A morbillous rash appeared in the morning about the chin and neck. The temperature, which had been falling since the 17th, was now 101°. The breathing, in the mean time, had become difficult. The veins around the orbits were observed to be prominent. The rash had extended to the trunk and limbs, and had disappeared on the 23rd, the temperature having fallen to the normal point on the 22nd. The chest trouble, however, became more urgent, and was accompanied by great deficiency of the urinary functions, there being complete suppression for twenty-four hours. The child succumbed to these complications on December 25th, no materia change in the paralytic symptoms having been observed in the meantime.

The autopsy was made by Mr. R. W. Parker, on the following day. To him I am indebted for the following notes.

Externally the spinal cord and its membranes appeared abnormal to the naked eye. The cord was very firm to the touch throughout its whole length. On section the grey matter looked very pink in all parts, and in places, especially about the lumbar enlargement, there was in addition a gelatinous look about the white matter immediately adjoining the posterior cornua. This gelatinous appearance was in roundish patches. About the centre of the lumbar enlargement, or somewhat lower, there was a patch of reddened, gelatinous-looking matter, corresponding exactly with the anterior cornu on the left side. It had a margin of darker colour than the centre, as from decolorisation of an hæmorrhagic extravasation. It was as large as a swan shot. No other similar patches were found. In the lungs were patches of broncho-pneumonic consolidation throughout. The other organs seemed normal.

The specimen exhibited, a portion of the lumbar enlargement of the cord imbedded in wax, showed the upper surface of the section made through the point of hæmorrhagic softening above mentioned. A defined depression with a rough surface could be seen occupying the anterior cornu on the left side. Inspection of sections, made through the cord at successive levels, showed that the antero-lateral column on the left side was distinctly smaller than that on the right throughout the whole length of the cord, and that the left anterior cornu was also smaller than the right. From this circumstance it could be determined with certainty in all the microscopical specimens which were the right and left sides of the sections.

Examination under the microscope of thin sections made through the cord, in the immediate neighbourhood of the point of hæmorrhage, showed that, in this region, the grey substance of the cord had undergone profound and extensive changes (see Pl. XIII). In these sections, when examined under a comparatively low power ($\frac{2}{3}$ inch), no trace of nerve structure could be distinguished in either anterior cornu, or in the outer part of the base of the posterior cornua. The whole of the area had a pale, translucent appearance, especially in its central parts; it had also a confused appearance from infiltration of leucocytes, which were, however, not massed together so as to hide the tissue invaded by them, but they were disseminated separately, in clusters, and in small groups. They were massed in greater numbers in the sheaths of the larger arterioles, rendering these vessels conspicuous objects in the field. This sheathing of the vessels by collection of corpuscles in their outer

## DESCRIPTION OF PLATE XIII.

Plate XIII illustrates Dr. F. Charlewood Turner's case of Acute Anterior Polio-myelitis in a Child. (Page 202.) From drawings by A. T. Hollick.

FIG. 1.—A portion of a section through the lowest part of the lumbar enlargement, showing the left anterior cornu and region adjacent. The drawing shows the complete disorganisation of the nervous structures over nearly the whole of the anterior cornu, and over a portion of the outer part of the central grey substance behind it. Magnified to 25 diameters.

FIG. 2.—Represents a portion of the area of disorganisation of the centre of the left anterior cornu in a section made through the upper part of the lumbar enlargement. It shows numerous corpuscles in the granular protoplasm, and defined well-stained nuclei, disseminated through a fine reticulum, in which are also seen bodies which appear to be the atrophied relics of stellate nerve-cells. A small arteriole is also shown in the several rows of corpuscles, granular bodies, and nuclei crowding its outer sheath.

Fig. 1.

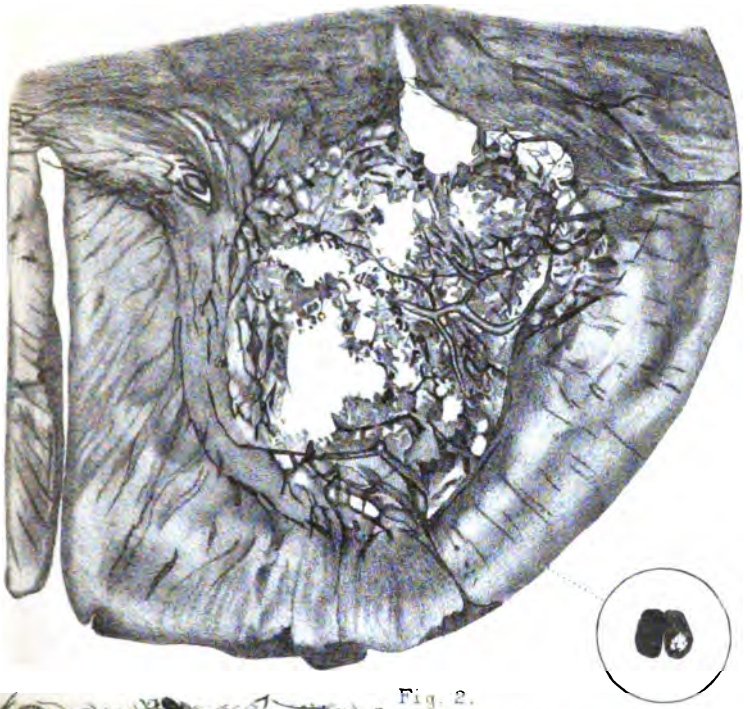

Fig. 2.

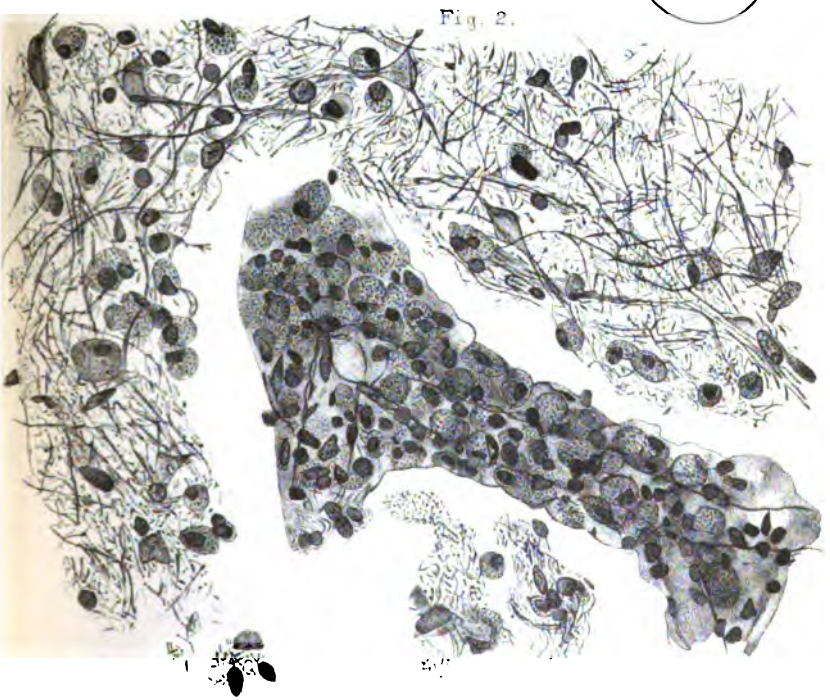

R. Mintern Lith.

Mintern Bros. Imp.

coats was especially conspicuous in the left anterior cornu, in these and in all the other sections made through the lumbar enlargement. In the posterior cornua, at the posterior part, interlacing bundles of nerve-fibres and several good-sized stellate cells could be seen with a low power, the latter having distinct processes and well-defined nuclei. In the inner part of the posterior cornua many nerve-fibres and stellate cells could be seen, but they appeared less well-defined. It was noticeable that the right posterior cornu was less extensively affected than the left, and showed more numerous polar cells.

The whole grey substance was abundantly infiltrated with leucocytes disseminated through it, singly and in clusters. Leucocytes were similarly disseminated over the sections of the white columns to a less degree. The whole section had a hazy appearance, as from albuminous infiltration (? œdema). It was very noticeable that the massing of the leucocytes along the vessels was seen to a marked extent only in the anterior cornua, and in the large arterioles entering the anterior cornua at their bases from the bottom of the anterior median fissure. Vessels extending from the cornua into the antero-lateral column seemed to lose their thick corpuscular cloaks. In the posterior cornua a few vessels were seen clustered with leucocytes, but to a comparatively slight extent.

In sections made a short distance lower down, about a quarter of an inch below the seat of hæmorrhage, the changes in the left anterior cornu were found to be as extreme, and very nearly at extensive as above. In one of the sections made at this level, the disorganised area of the grey matter on this side had become partially separated from the adjacent tissues, in a manner which rendered its extent clearly visible to the naked eye (see Plate XIII, fig. 1). Examined under the ⅛-inch objective this area of disorganisation is seen to occupy the whole of the anterior cornua, excepting only narrow strips on the inner and outer borders, and to extend backwards through the central part of the grey substance to the base of the posterior at its outer part, but without encroaching upon it. Within this area, conspicuous by its translucency and pale colouring, a delicate reticulum, infiltrated with corpuscles, and supporting vessels thickly sheathed with the same, is alone visible under this power. In the remainder of the anterior cornu and in the outer part of the posterior cornu at its basal part, where something of the normal appearance of the nerve-structure is preserved, only a few stellate cells are distinguishable, imperfectly defined and without visible

nuclei. In the hinder part of the posterior cornu and in its inner basal region well-formed stellate cells are visible, with distinct nuclei and long processes, and interlacing bundles of nerve-fibres. On the right side of the grey centre the changes visible are less extreme at this part. The central area of the right anterior cornu is pale and translucent as on the left, and the nerve structures have almost wholly disappeared, but the area of this disorganisation is imperfectly defined, and less extensive, wider tracts being left at each border of the anterior cornu. In some of these sections, quite in the centre of the right anterior cornu, two or three stellate cells are visible under a low power, some of them with distinct nuclei and processes; but few nerve-fibres are distinguishable. In the posterior cornua more polar cells are visible than on the left side.

When examined under a higher power (Hartnack No. 7), the parts most profoundly changed, both in these sections and in those made in close proximity to the hæmorrhagic softening, still present traces of the nerve structures, in the form of relics of atrophied stellate cells and a few nerve-fibres. Under a high power the characters of the corpuscles disseminated through the reticular structure, and clustered along the vessels are distinctly seen. Plate XIII, fig. 2, represents a portion of the left anterior cornu, in a section made about half an inch above the point of extravasation, in the upper part of the lumbar enlargement. Here a small vessel is seen surrounded by two or three layers of corpuscles situated outside the muscular coat (which could be made out distinctly by accurate focussing), and within the outer limit of the tunica adventitia. These corpuscles are seen to be of considerable size, consisting of masses of granular protoplasm with defined and well-stained nuclei. There are some protoplasmic masses which seem to have lost their nuclei. Similar corpuscles, granular protoplasmic masses, and free nuclei are seen scattered in clusters or single over the field. The corpuscles of the stroma are also conspicuous by their size and thickness of their processes.

Tracing the area of degenerative changes further downwards it was found that sections made in the terminal cone of the cord, about half an inch below the sections first described, show comparatively little change. In the median and outer part of the anterior cornua, however, on the left side more especially, the stroma appears coarse and open, in contrast with its very fine texture in the adjacent parts,

the stellate cells are small and pale, and their nuclei indistinct, and here and there connective-tissue corpuscles are conspicuous, even under a low power. Here, too, there is clustering of leucocytes about some of the vessels.

In sections made higher up in the lumbar enlargement, about half an inch above the point of hæmorrhage, the area of disorganisation in the anterior cornua is of less extent and of more defined outline than in the sections below. These areas, conspicuous in the sections to the naked eye when viewed against the light, are of a circular outline, with a diameter of about two thirds of the width of the cornu, and occupying the outer angle of the anterior cornu with the outer and fore part of its central region. In this area only traces of the nerve structures are visible, relics of polar cells and a few nerve fibres, with swelling of connective-tissue corpuscles and thickening of their processes; the larger vessels, with masses of leucocytes around them, are here even more conspicuous than in the sections previously described. In the outer and hinder part of the anterior cornu and of the central grey substance the tissue is translucent, its structure confused, and the stellate cells ill-defined. The posterior cornua appear to have suffered little or no disturbance. The stellate cells in them are large and well-defined, with their nuclei and processes distinct. The changes in the right anterior cornu are less marked than those on the left.

The changes met with higher up are of a less active kind. In sections made through the upper part of the lumbar enlargement, a few vessels are seen covered with corpuscles in the anterior cornua, but at no part is there evidence of the degree of disorganisation of the nervous tissue, seen in the inflammatory foci in the sections below. The changes seen affect the central and outer region of the anterior cornua, and the central grey substance adjacent. The nerve fibres here are scanty, and the polar cells atrophic, the connective-tissue corpuscles are very large, and their processes thick, so that many of them are quite conspicuous under the lower power (two thirds inch). The section in this part also has a translucent appearance, and the tissue is disordered. In the left anterior cornu, in the anterior and inner regions, several large and conspicuous polar cells are seen, these parts having a normal appearance; in remarkable contrast to this is the absence of any such healthy-looking cells in the right anterior cornu in nearly all the sections. The vesicular columns of Clarke are the most con-

spicuous objects in these sections, the nerve-cells in them being numerous, and larger than those in the anterior horns.

In section made in the lower dorsal region the same appearances were found. In all the sections examined, a deficiency in the number of polar cells in the anterior cornua is noticeable, especially on the right side; in several sections no nerve cells being distinguishable in the right anterior cornua under a low power ($\frac{2}{3}$rds inch). In the left anterior horn from one to four large stellate cells are visible with large nucleus and well-formed processes. In all the sections also many connective-tissue corpuscles are large and conspicuous in the outer and back parts of the anterior cornua and adjacent regions, and in a less degree throughout the anterior cornua. In the former region also there is the same translucent area. It seems probable that the thinness of the sections in this part, and the very marked deficiency of the nervous structures there, may in part be due to the hardening solution (ammonbichromate) not having so effectively permeated the part; these regions being those parts of the grey centre of the cord, which are furthest from the surface.

In the sections through the upper part of the dorsal region the appearances were the same, excepting that the stellate cells in the left anterior cornu were much more numerous, as many as ten being visible in some of the sections. In the right anterior cornu there was the same marked absence of these cells, in some sections none being visible under the lower power. In the cervical enlargement somewhat more active changes were found. Many of the larger arterioles, were rendered conspicuous by the corpuscles clustered along their walls; and the leucocytes besides being more freely scattered over the field than in other sections, were in one or two places more closely aggregated in definite clusters. In sections made through the lower part, the deficiency of stellate cells was very marked in the left anterior cornu, a group of nerve cells being seen at its inner angle, but none elsewhere. In these sections nerve cells were visible in all parts of the right anterior cornu, those at the inner angle, and those at the outer angle especially, forming large and conspicuous groups. In the central region they were small. In this region also, as in the left anterior cornu the nerve fibres were few, and the connective-tissue corpuscles large and prominent.

In section made at a higher level in the cervical enlargement the

changes seen were the same, excepting that here the right anterior cornu was that especially affected. Polar cells were recognisable only at the inner part of the right anterior horn, and in a narrow strip along its anterior and outer border. The left anterior cornu in many sections showed numerous stellate cells. In section made through the medulla oblongata, and pons Varolii and corpus striatum, no marked changes were observable beyond the rather abundant dissemination of leucocytes.

The changes in the white columns of the cord were most noticeable in the antero-lateral columns, and more particularly in that of the left side. The changes consisted (1st) in an enlargement, and apparent increased number of the connective-tissue corpuscles, with thickening of their processes, and (2nd) in a marked loss of regularity in the arrangement of the structure; and (3) in the wasting of the axis-cylinders of the nerve-fibres, and the disappearance of their sheaths.

In the anterior columns, at some points, the connective-tissue corpuscles were so closely drawn together, that their angular projections were almost in contact. In these more changed parts the shrivelled axis cylinders of wasted nerves appeared as fine, well-dyed points. The effect of the sclerotic changes on the structural arrangement of the tissue was well seen in a comparison of the contiguous inner margins of the anterior columns, in the coarseness of the left column when compared with the less affected column on the right. The presence of round spaces containing nerve fibres, apparently formed by the contraction of the tissue around, gave the former a perforate appearance. In the posterior white columns the regular arrangement of the nerve fibres was preserved. In the lower lumbar region the definition of structure was somewhat obscured apparently by recent serous exudation; elsewhere the lines of the tissue were clear.

In this case, then, the anatomical changes show that the anterior grey columns were most intensely affected; that these columns were the only parts of the grey substances of the cord in which definite structural lesions were found, excepting only at the lower part of the lumbar enlargement, in the immediate vicinity of a point where the lesion of the anterior column was of the most extreme degree, possibly of quite exceptional intensity.

The anterior grey columns being primarily the seat of such acute inflammatory lesions, the extent and degree to which adjacent parts

of the grey centre are affected in any case must vary with the severity of the primary lesion.

In the present case the changes in the posterior grey columns appears to have been of a secondary character, and although such as might be expected to be followed by some permanent impairment of the sensibility of the lower limbs, do not seem to afford any ground for removing the case from the category of poliomyelitis anterior acuta, or "infantile paralysis."

With the exception of the persistence of the usually more transient disturbance of the action of the sphincters, the clinical course of the case followed that so characteristic of infantile paralysis, in the rapid recovery of sensation (probably partially only in the lower limbs at least), and in great part of mobility in the upper limbs, and in some degree in the lower limbs also.

An observation of the spinal cord from a case of acute anterior polio-myelitis in an infant, fatal in an early stage, is recorded by MM. Roger and Damaschino in the 'Gazette Médicale de Paris,' 1871 (No. 41 *et seq.*). In that case the child took scarlatina about six weeks after the onset of the paralysis, which affected the left arm and leg. While convalescent from the scarlatina, loss of power in both legs was observed to have occurred. This was followed in two days by some free hæmorrhage from the rectum. Broncho-pneumonia supervened from which the child died nine or ten weeks from the first appearance of the paralysis, and only three weeks from the paraplegic symptoms. The appearances presented in the lumbar and cervical enlargements in that case, as described by M. Damaschino, correspond with those presented in the sections from the present case, excepting those made in the immediate neighbourhood of the hæmorrhagic focus.

It is possible that in both cases the changes observed were of a more active kind than would usually exist at a stage of the disease corresponding with the period at which the examination was made. The occurrence of a zymotic disease, would naturally tend to produce a recrudescence of a local inflammation in a part but partially restored by the process of resolution. The distinct reappearance of symptoms of paralysis in the one case, and possibly the apparently rather recent hæmorrhagic softening in the other, may thus be accounted for. It seems possible that the latter may have been in excess of the original lesion, and that the extension of disorganisation so far into the posterior part of the grey centre in the im-

mediate neighbourhood of the hæmorrhage may have been an exceptional phenomenon in this case owing to the super-induction of a state of zymotic blood-poisoning on a local disease already severe. *February 4th*, 1879.

---

## 6. *Case of infantile paralysis.*

By Henry Humphreys, M.D.

The sections of spinal cord I have the honour of bringing before the Society were obtained from a child æt. 3 years and 6 months, who died of scarlet fever at the Children's Hospital, Pendlebury, on May 26th, 1878. The account of the case is as follows :—The family history was good. The child herself began to walk when fifteen months old. Two months later she fell ill with "relaxed bowels," and lost the use of her legs. Soon afterwards she recovered the power of walking to a limited degree. But the left leg continued weak, so that she would often stumble and fall. Latterly that leg had regained much strength, but had not grown so much as the right leg. A further peculiarity had been noticed during the last fourteen months, namely, that she always walked upon the left heel, the toes and ball of the left foot not touching the ground at all.

On admission she was a fat healthy-looking child. There was a well-marked talipes calcaneus of the left heel, the foot being in the position of dorsal flexion, the ball and toes not touching the ground. The left lower limb was a quarter of an inch shorter than the right. The left calf, at a level three inches below the head of the tibia, measured five eighths of an inch less in girth than the right, and the left thigh a quarter of an inch less in girth than the right, at a level four inches above the head of the tibia. No reaction was obtained either to the faradic or constant current on the wasted limb. Nevertheless from the somewhat unusual nature of the deformity, there is reason to believe that some tonicity must have been left in the extensor muscles of the left leg. The child was healthy in all other respects.

About a week after admission she developed signs of scarlet fever, of which she died six days later. The fever was characterised by a high temperature and severe angina.

At the autopsy twelve hours after death, with the exception of some cloudy swelling of the kidneys and liver, the abdominal and thoracic viscera were healthy. The spinal cord was of firm consistence. In the lumbar portion it presented changes evident to the naked eye. Here on section the left half was seen to be considerably smaller than the right, and in particular the left anterior cornu appeared remarkably smaller and more opaque-looking than the corresponding part of the opposite side.

A small portion of the gastrocnemius was removed. Beyond pallor it exhibited no coarse changes.

On microscopical examination of the cord after hardening in chromic acid and staining with carmine marked changes were found in the lumbar portion for two inches above the origin of the terminal cone. Dividing that piece of the cord into three segments, and taking a typical section (Woodcut 1) from the lowest segment, a marked want of symmetry between the right and left halves of the section is the first noticed. If the transverse diameter of the entire section be represented by 95, that of the right half will be 50, and of the left 45. On the same scale the transverse diameter of the grey portion measured through the central canal will be 84, that of the right half 44, and of the left 40. The breadth of the right anterior cornu will be 30, of the left 23. The right and left posterior cornua show no appreciable difference in breadth. Thus the asymmetry of the section is seen to be due principally to a shrinking of the anterior and lateral portions of the grey matter on the left side, the white columns of the two sides presenting very little difference in breadth.

Next a marked difference is noticeable in the large nerve-cells of the two sides. Following the classification given by Erb in Ziemssen's 'Cyclopædia of Medicine' the large nerve-cells in the lumbar region may be divided into four principal groups. First; there is the medial group; which may be represented by *a* (*vide* Woodcut), an antero-lateral group *b*, a postero-lateral group *c*, and a group *a'* peculiar to the lumbar region situated between *a* on the one hand and *b* and *c* on the other. In addition to these the posterior vesicular column makes its appearance in the upper part of the lumbar region. In the section under consideration (fig. 1) the medial group (*a*) is not represented on either side. The group *a'* numbers 25 on the right, but has entirely disappeared from the left side. The antero-lateral group (*b*) numbers 50 on the right, 4 on the

WOODCUT 1.

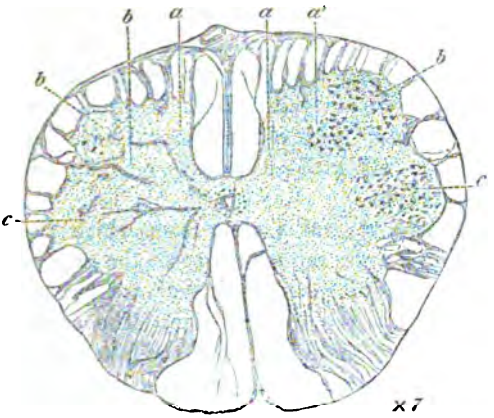


1. Section from the lower lumbar region of cord. *a* indicates the region occupied by the medial group of nerve cells. No cells represent this group on either side. *a'* indicates on the right side a group of cells peculiar to the lumbar region. On the left side this group has entirely disappeared. *b* indicates on the right side the antero-lateral group of cells. On the left side a few cells only of this group remain. *c* indicates on the right side the postero-lateral group. On the left side this group has entirely disappeared. Several vessels, from which the perivascular sheaths have shrunk away, are shown on the left side.

WOODCUT 2.

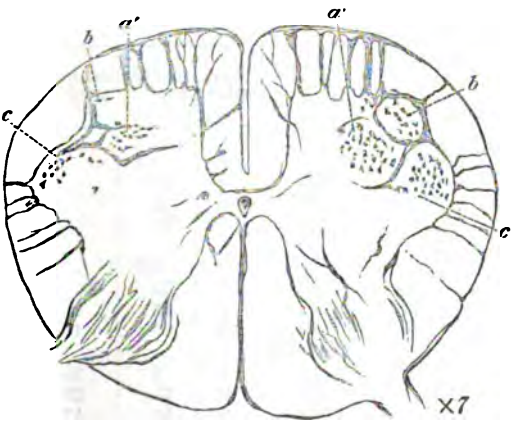


2. A section from the middle lumbar region. The letters *a*, *a'*, *b*, *c*, have the same meaning as in fig 1; on the left side the group *b* has almost entirely disappeared, causing a marked falling in of the circumference of the grey matter. The groups *a'* and *c* are fairly well represented on the left side, but the cells composing them are not so numerous as on the right side.

left side. The postero-lateral group (*c*) numbers 96 on the right, but has entirely disappeared from the left side. Thus there are 171 large nerve-cells on the right, against 4 on the left side. The latter are slightly smaller than those on the right side. They are not pigmented, their nuclei are well marked. Scarcely a vestige remains of any other large nerve-cells of the diseased side. Much shrinking of the regions from which the cells have entirely or partially disappeared is noticeable.

On the left side several vessels from which the perivascular sheaths have shrunk away are seen to cross the grey matter. These vessels are more numerous, and their perivascular spaces wider on the diseased than on the healthy side. The capillaries likewise are more prominent in the former than the latter situation. In the grey matter of the diseased side fewer axis cylinders are seen and the anterior roots are somewhat narrower than on the opposite side, no changes are noticeable in the white columns.

Twenty sections have been examined from the lower segment of the lumbar portion of the cord, 23 from the middle, and 24 from the upper segment. A considerable variation in the number of the nerve-cells is noticeable in the different sections, but the same general description applies to all of them. The results of the examination may be exhibited in a tabular form as follows.

| Region of cord. | Name of the group of nerve cells. | Healthy side. | | | Diseased side. | | |
|---|---|---|---|---|---|---|---|
| | | Maximum number of cells. | Minimum number. | Average number. | Maximum number. | Minimum number. | Average number. |
| Lower lumbar segment | a | 4 | 0 | ·2 | 7 | 0 | ·9 |
| | a′ | 33 | 0 | 15 | 0 | 0 | 0 |
| | b | 87 | 9 | 52 | 30 | 0 | 13 |
| | c | 110 | 58 | 79 | 43 | 0 | 11 |
| Middle lumbar segment | a | 14 | 0 | 6·3 | 10 | 0 | 4·3 |
| | a′ | 50 | 10 | 32 | 38 | 0 | 10 |
| | b | 38 | 9 | 22 | 17 | 0 | 6 |
| | c | 70 | 0 | 37 | 40 | 0 | 12·4 |
| Upper lumbar segment | a | 18 | 1 | 9 | 20 | 0 | 8·7 |
| | b′ | 73 | 6 | 31 | 28 | 0 | 5·4 |
| | Posterior vesicular column | 34 | 3 | 11 | 17 | 0 | 6·4 |

An examination of a large number of sections from the dorsal and

cervical regions of the cord shows that there is no marked difference in the groups of nerve-cells belonging to those parts. In the present case, therefore the changes are limited to the lumbar region of the cord, and consist mainly of a remarkable diminution in the number of the large nerve-cells belonging to the anterior and lateral parts of the grey matter of the left side. It throws no light upon the cause of the disappearance of the cells.

In conclusion, I have to thank my friends Drs. Ross and Bury for much help in the preparation and examination of the sections.

*January 4th*, 1879.

---

## 7. *On the pathology of tetanus and hydrophobia.*

By James Ross, M.D.

The following observations on the microscopical changes found in the nervous system in tetanus and hydrophobia are in large measure confirmatory of the observations of Lockhart Clarke, Dickinson, Clifford Allbutt, Benedikt, Coats, and Gowers. The material at my command consisted of portions of the nervous system from four cases of traumatic tetanus, and from six cases of hydrophobia.

The changes observed in the medulla oblongata in hydrophobia corresponded closely to the careful drawings and accurate description of Dr. Gowers; except, perhaps, with respect to his description of the clot within the blood-vessels. The distribution of these vascular and perivascular changes in the medulla oblongata was, in one of my cases, almost coextensive with the distribution of the vessels. The grey matter on the floor of the fourth ventricle was most affected, probably because it is the most vascular; but similar changes were found in the *formatio reticularis*, olivary bodies, restiform bodies, and to a less extent in the anterior pyramids. I am indebted to Dr. Young, of the Owens College, for the illustrations which accompany this paper, and fig. 1, Plate XIV, shows very faithfully the condition of the medulla in the case mentioned. It will be observed that, although the nucleus of this hypoglossal is infiltrated with leucocytes, its cells are not much affected, while scarcely a trace is left of the cells of the spinal accessory and pneumogastric nuclei. The

same condition is shown under a higher magnifying power in fig. 2, where the cells of the nucleus of the hypoglossal appear healthy, although the tissue is densely infiltrated with leucocytes. The infiltration of the grey matter of the olivary bodies with leucocytes is illustrated by fig. 3. Similar vascular and perivascular changes were observed, though to a less extent, throughout the whole extent of the pons, in the grey substance surrounding the aqueduct of Sylvius, and in the corpora quadrigemina, as already described by Dr. Coats. The cortex of the brain and subjacent white substance were infiltrated with leucocytes, and the pyramidal cells of the fourth layer of the cortex were often partially filled with small yellow granules. The cortex of the cerebellum and subjacent white substance were also much infiltrated with leucocytes, the changes here being almost, if not quite, as marked in extent as in the brain, and the cells of Purkinje were very granular. It would appear, therefore, that hydrophobia is a disease of a very diffused character.

The changes found in the spinal cord in hydrophobia, deserve special mention. These changes are not always well marked, and in three of my cases they might very readily have been overlooked, while in the other three marked alterations were observed in the upper dorsal region, and the cervical enlargement. One of the anterior horns, from a section of the cervical enlargement, is represented, by Dr. Young, in fig. 4. The whole of the grey substance is infiltrated with leucocytes, and the vessels on each side of the central canal are surrounded by them. A vessel comes from the surface of the cord, by the side of the anterior roots, and divides into two branches on reaching the grey substance; the internal branch is distributed to the area which lies between the median and antero-lateral groups of cells, while the external branch passes between the antero-lateral, and what I may call the central group of cells. In the section from which fig. 4 was sketched, only branches of this vessel are seen. On reaching the grey substance the vessel is surrounded by leucocytes to a very unusual extent. Another vessel passes from the surface to the antero-lateral group of cells, and it also is surrounded by many layers of leucocytes. Three distinct miliary abscesses were observed in the external margin of the antero-lateral group of cells in the cord taken from a child, four and a half years old, who died of hydrophobia at St. Mary's Hospital, under the care of Mr. Ewart.

## DESCRIPTION OF PLATE XIV.

Plate XIV illustrates Dr. Ross's Observations on the Pathology of Tetanus and Hydrophobia. (Page 215.) From drawings by Dr. Young, of the Owens College.

FIG. 1.—Section of medulla oblongata from a case of hydrophobia, showing extensive infiltration of the tissues with leucocytes; all the cut vessels being surrounded by them. The nucleus of the hypoglossal nerve is infiltrated with leucocytes; but its cells are apparently healthy. Almost all the cells of the nucleus of the pneumogastric nerve have disappeared, and the nucleus of the spinal accessory nerve was similarly affected lower down the medulla.

FIG. 2.—Portion of the nucleus of the hypoglossal nerve from same section as Fig. 1, under a higher magnifying power. The ganglion cells appear healthy, although they are surrounded by leucocytes. The cut ends of the vessels may be seen surrounded by numerous leucocytes

FIG. 3.—Portion of grey matter of olivary body from same section as Fig. 1, magnified, showing infiltration with leucocytes.

FIG. 4.—Section of the anterior horn of the grey substance of the cervical enlargement of the spinal cord in a case of hydrophobia. *m.* Median; *al.* Antero-lateral; *pl.* Postero-lateral; and *c.* Central group of ganglion cells. Showing infiltration of the tissues with leucocytes, and the cut vessels surrounded by them. The ganglion cells have apparently disappeared from the area which lies between the median and the antero-lateral groups, and only two or three of the cells of the central group are seen; while some cells have also apparently disappeared from the margins of the antero-lateral and postero-lateral groups. The central group was also infiltrated with red blood-corpuscles.

FIG. 5. Portion of the area from which the cells had apparently disappeared in Fig. 4, magnified. Showing that the cells are still present, although they are much shrunk, and some of their processes destroyed. The walls of the cavity surrounding them are infiltrated with leucocytes or covered by nuclei.

FIG. 6. Tetanus. Section of the anterior horn of grey substance from the middle of the lumbar enlargement. Showing infiltration of the tissue with leucocytes, and apparent disappearance of the ganglion cells from the area lying between the few remaining cells of the median group and those of the antero-lateral group; also apparent disappearance of a considerable portion of the cells of the postero-lateral group.

FIG. 7. Vessel from the anterior median fissure from the same section as Fig. 6, surrounded by numerous leucocytes.

FIG. 8. Vessel cut obliquely from the grey substance from the same section as Fig. 6, showing its lymph sheath surrounded by leucocytes.

Fig. 1.

Fig. 2.



Fig. 3.



Fig. 4.

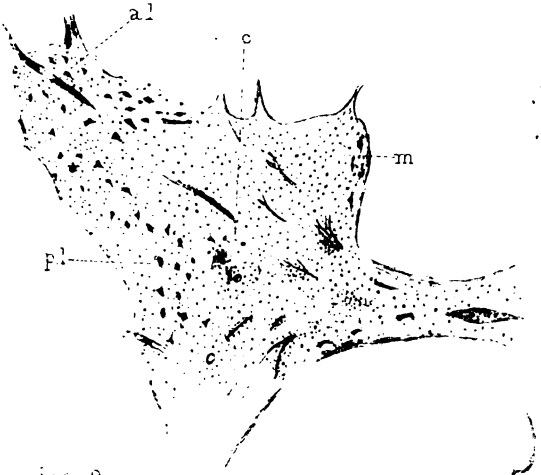


Fig. 5.

Fig. 6.

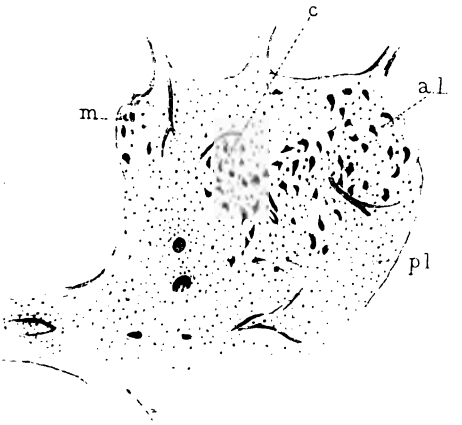


Fig. 8.

Fig. 7.

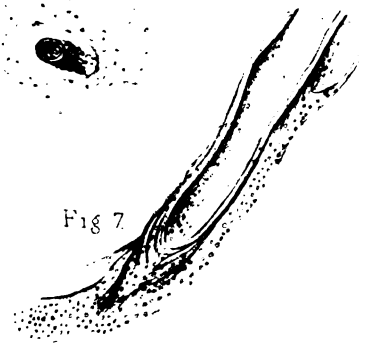

R. Mintern Lith.

Mintern Bros. imp.

The most interesting changes, probably, have occurred in the ganglion cells themselves. Two or three cells, of normal size, may be observed in the part of the median group which is nearest to the anterior fissure, and full-sized cells may also be observed in the central portion of the antero-lateral and postero-lateral groups. When examined under a low power, all the cells seem to have disappeared from the territory which lies between the few remaining cells of the median group (fig. 4, m) and the antero-lateral group (fig. 4, a l), while the cells of the central group (fig. 4, c) have also, with the exception of two or three, disappeared, and a considerable number must have also disappeared along the margins of the antero-lateral and postero-lateral groups. When the areas from which the cells have apparently disappeared are examined with a higher power, it is seen that remnants of the cells are still present. The cells are surrounded by a partially empty cavity, the walls of which are covered by either leucocytes or nucleoli, while the cells are themselves shrunk to a very variable extent (fig. 5). The cell membrane appears to be shrunk around the nucleus and nucleolus, and a small quantity of granular contents; but one or more processes can almost always be detected; the full-sized cells often contain yellow pigment granules, and sometimes appear to be increased instead of being diminished in size. A number of red-blood corpuscles are infiltrated into the central group of cells (fig. 4, c) and the cells themselves are much altered and diminished in size. The vesicular column of Clarke, especially in the upper dorsal and lower cervical regions, is usually much infiltrated with leucocytes, and its cells are often deformed and shrunken. The cells of this group are frequently found healthy at the junction of the dorsal and lumbar regions.

On comparing a section of the cervical enlargement of the cord, in a case of tetanus, with that already described from the case of hydrophobia, the morbid lesions presented manifest similarities. A large number of leucocytes were infiltrated in tetanus through the whole of the grey substance, and more especially in the grey commissure; but they did not crowd round the vessels as in hydrophobia, and many areas of the granular degeneration of Clarke were also observed in the former. So far, therefore, the morbid alterations in the two sections did not correspond; but with regard to the alterations of the cells in the anterior horns, and in the vesicular column of Clarke, the description given of one applies almost exactly to the

other. Minor differences, with respect to the alterations of the cells in each affection, might be described, but the broad fact stands, that the groups of cells which are shrunken and altered in hydrophobia, are also affected in tetanus.

In one of my cases of tetanus, the lumbar region of the cord was affected to an unusual degree. A section from the middle of the lumbar region is shown in fig. 6. A vessel from the anterior fissure, represented in fig. 7, is seen to be surrounded by leucocytes, and the whole of both the grey and white substance was densely infiltrated with leucocytes, although the latter were not usually aggregated in the perivascular spaces and around the vessels as in hydrophobia. A vessel from the grey substance, cut obliquely, is shown in fig. 8, the lymph sheath of which is filled with leucocytes. The most interesting changes were again observed in the ganglion cells of the anterior horns. A few cells of normal size were observed in the portion of the median group nearest the anterior fissure, the greater portion of the cells of the antero-lateral group, and a few of those of the postero-lateral group, were also of normal size; but the greater portion of the cells of the median group, and some of those in front of the antero-lateral, a few of those between the antero-lateral and postero-lateral groups, as well as the cells of the posterior portion of the postero-lateral group, had apparently disappeared, when the section was examined with a low power. The disappearance of these cells was, however, apparent, and not real; under a high power, the cells in these areas could be seen shrunk in their cavities, as already described in hydrophobia, fig. 5. Similar changes, although less in extent, were observed in the other three cases of tetanus, and in the lumbar region of the cord in hydrophobia.

Other interesting facts with respect to the cells which are shrunken, and those which maintain their normal size, are that the former are smaller than the latter in the normal cord, that they are situated in the most vascular areas of the anterior horns, and that they are the last cells to be developed in the cord. The cells which have maintained their normal size (figs. 4 and 6) are represented in the cord of a five months' embryo, by large cells with a distinct nucleus, and well-developed processes, while the cells in the areas with shrunk cells are represented by small angular cells without processes; even in a nine months' embryo the processes of these cells are undeveloped. The latest developed cells are those which suffer first in other

forms of central myelitis, as well as in infantile paralysis and progressive muscular atrophy, so that there is nothing special in their being the first to become diseased in tetanus and hydrophobia.

With respect to the medulla in tetanus, the cells in the internal and anterior portions of the nucleus of the hypoglossal appear to be considerably altered, while those of the body of the nucleus appear normal. The cells of the nuclei of the spinal accessory, and pneumogastric, appear always to suffer, while the longitudinal vessel which lies in the deepest part of the floor of the fourth ventricle is, as Dr. Coats remarks, usually surrounded by red blood-corpuscles. The body of the nucleus of the facial is apparently healthy, but a group of smaller cells lies anterior to it, in which the vessels are always distended, and the cells shrunken and deformed. The motor nucleus of the fifth, the nucleus of the abducens, and that of the third and fourth cranial nerves do not show any signs of disease. A large number of leucocytes were observed in the olivary bodies, the brachium of the pons, and between the fibres of the seventh nerves; but it is doubtful how far these transgress the limits of health.

In the roots of the fifth nerve, which proceed from the cerebellum, large vessels were observed which were distended with red blood-corpuscles, and the whole of the surrounding tissue was densely infiltrated with leucocytes. The corpus dentatum of the cerebellum and the white substance subjacent to the cortex, were also densely infiltrated with leucocytes and intersected with distended blood-vessels to an extent which it is scarcely possible not to regard as the result of disease. The cells of Purkinje were surrounded with leucocytes, and their contents appeared granular, but they did not offer any very decided evidences of disease. *April 29th*, 1879.

## II. DISEASES, ETC., OF THE ORGANS OF RESPIRATION.

### 1. *A peculiar degeneration of the lung of uncertain nature.*

By Samuel West, M.B.

J. O'B—, æt. 52, a tailor, came to me as an out-patient at the City of London Chest Hospital complaining of great debility and troublesome cough. He gave this history—that he had been losing strength for six months, but that otherwise he believed himself to be in fairly good health until six weeks ago; that he then had a severe cough and profuse thick expectoration which developed suddenly, and soon compelled him to take to bed. He had rapidly lost flesh, but had had no night sweats or hæmoptysis.

The patient was too ill to examine accurately, but it seemed most probable from the presence of crepitation and impaired resonance at the left apex, that he had been attacked with pneumonia six weeks before, which had run a bad course, and had possibly led to partial gangrene. The patient was admitted at once into the Hospital, but little more could be made out. He became very delirious. The temperature was usually between 103° and 105°. Tongue dry, and pulse very feeble, and on the fifth day he died.

*Post-mortem.*—Body large in frame, but considerably emaciated. Rigor mortis slight. Heart dilated and flabby; pale and slightly fatty. Right pleura natural. Right lung congested and œdematous, but otherwise natural. Left pleural cavity obliterated by loose adhesions, easily broken down. Left lung.—The lower lobe congested and œdematous, containing hardly any air. The upper lobe felt completely solid, much enlarged and marked with furrows from the ribs. Upon its surface were puckerings and wrinklings which evidently covered cavities beneath. On section a greenish puriform serous fluid escaped, which was not gangrenous or stinking, and the

cavities collapsed. These cavities were long irregular sinuses or fistulous tracts, quite superficial, communicating, many of them, freely with one another, and measuring some inches in length. One and all lay quite superficial immediately beneath the pleura, which was itself hardly at all thickened, and had lost but little of its polish or smoothness. In the deeper tissue of the lung, no cavities were to be found; nor were there any traces of dilated bronchi. The walls of the cavities were rough, formed of altered lung tissue, contained no caseous substance, but only detritus of lung tissue. Across the cavities ran coarse trabeculæ, the remains doubtless of the vessels and bronchial tubes. The whole substance of this lobe was solid throughout, of a dark grey colour, hard to the feel and coarsely granular, the granules apparently being the thickened alveolar walls and small bronchi in section. The consolidation was not the same throughout, being for about one inch or one and a half inches from the surface due to an apparent pneumonic infiltration while the rest was of the nature more of a solid œdema. Immediately round the cavities, and in some places where the cavities were still small, yellowish streaks seemed to radiate inwards towards the deeper substance of the lung, but it could not be distinctly seen to what these streaks belonged, whether to the septa, or to blood-vessels &c. The smallest cavities of all contained a semi-transparent, greenish, opalescent, gelatinous substance, and it was apparently by the fusion of these small cavities that the large ones were formed. These cavities were found irregularly scattered over the whole surface of the upper lobe, on its anterior, inner, posterior, and outer surfaces, but the most extensive lay on the outer surface. The bronchi were much congested. The rest of the organs were congested, but not otherwise pathological.

*Microscopical examination.*—Portions of the lung were hardened in a mixture of chromic acid (one sixth per cent.), two parts, and methylated spirit one part. The sections were stained with hæmatoxylin and picrocarmine, and mounted in Dammar varnish.

A section was taken from a part of the lung where the process was not far advanced, and where the cavities were still small, perpendicularly to the pleural surface. The lung was here riddled with cavities of all sizes, the most minute being towards the deeper part. These cavities increased rapidly in size towards the surface, and immediately beneath the pleura fused to form the irregular sinuses described above. All these cavities were occupied by a

coarse, fibrillar network, in the meshes of which a transparent, more or less homogeneous substance lay, while the walls were covered by a thin lining of richly nucleated tissue, which will be described when the mode of formation of the cavities is discussed.

The interalveolar tissue, especially that round the bronchi, was much thickened and deeply pigmented, while the rest of the lung tissue here was solid from what was apparently a pneumonic infiltration.

The pleura was hardly at all thickened, and was separated from the large superficial cavity by a narrow zone of similarly consolidated lung tissue.

Examination with a higher power of the consolidated parts showed the existence of smaller cavities still, some not larger than an alveolus. The lung was evidently emphysematous, for the alveoli were larger than normal and irregular in shape. The smallest cavities were seen to be alveoli themselves, and every gradation might be traced between these, the smallest, and the largest, which were formed by the fusion of many alveoli in the way to be described shortly.

The infiltration to which the consolidation was due strongly resembled at first sight that found in pneumonia. It was formed of closely aggregated cells in a coarse network of fibrin, but it differed from ordinary croupous pneumonia in the fact that the fibrin network was so coarse, and that the cells were not lymph- or pus-cells, but all epithelial large cells, with well-defined nuclei, which stained deeply.

The cavities described above were produced from a peculiar degeneration of this infiltration.

The minute details of the change which occured seemed to be these:

The large cells in the centre of the alveolus became swollen and more transparent. The nuclei began to break up and to form small, irregular, darkly-stained fragments. The cell-wall disappeared, the nuclei became more fragmentary, and gradually disappeared until at last nothing was left of the cell except a faintly granular transparent substance, which stained (like colloid substance) very faintly with carmine. The fibrin network seemed to persist, so that ultimately the alveolus resembled closely the cavities described above, being filled with a fibrin network, in the meshes of which a colloid-like substance lay. This change commenced in the centre and spread peripherally, so that on the margin was found a zone of tissue

undergoing the same changes. This was the richly nucleated lining referred to above, and which existed alike in all the cavities from the smallest to the largest. This change having commenced in the alveolar contents, soon propagated itself to the walls, as might be seen in a section taken from the walls of a small cavity and magnified about 300 diameters. These were much thickened, and their connective tissue appeared to be split up into an irregular network by an infiltration of epithelial cells, similar in character to those described as composing the alveolar infiltration. Towards the cavity all clear distinction between the walls and the cavity was gradually lost, the fibrils of connective tissue forming apparently some of the coarser trabeculæ or meshes and the cells, gradually undergoing similar changes to those just described.

By this involving of the walls in the same change, the process of degeneration extended and the cavities grew.

One further peculiarity remains to be noticed. In many of the cavities a very marked concentric arrangement of the coarser meshes are seen. These were, as has been observed, in all probability the remains of the connective tissues of the alveolar walls. It is most difficult to explain this appearance. It suggests pressure from within, and there are, so far as I can judge, only two possibilities—the one that there is a continuous growth of fresh cells from the walls of the cavities, which undergo the "colloid" degeneration; the other that this "colloid" substance, if I may call it so, is very hygroscopic, and once formed swells. The former explanation seems to be the more probable. I may observe that there was hardly a trace in any part of caseous degeneration.

It is very difficult to decide to what class to refer this disease. In its limitation to one lobe it resembles pneumonia, with which also the clinical symptoms so far agreed that the diagnosis was made of an imperfectly resolved pneumonia. But the localisation of the process only to the superficial parts of the lung, the slight affection of the pleura, the microscopical appearances, and the peculiar degeneration are distinctly opposed to this view. The only alternative would seem to be to regard it as an epithelial new growth. This would be supported by the epithelial character of the cells, by the spreading of the process to the alveolar wall, by the peculiar degeneration of the new tissue, and by the excentric growth of the larger cavities.

I cannot decide between these views. On the whole, I should, if pressed, incline to the opinion that the process was one of new of an epithelial character, closely akin to the cancers, and that the degeneration was similar to that which we know to occur not unfrequently in such formations. I have been able to find no similar case recorded.[1] *December 3rd*, 1878.

---

## 2. *Chronic lobar pneumonia; grey induration; gangrene and secondary suppuration in lower lobe of lung.*

By Sidney Coupland, M.D.

This is a well-marked example of a condition of lung which, although not extremely rare, has not yet been thoroughly studied histologically. It is the condition termed by Addison "grey induration," and it equally well falls under the head of "fibroid degeneration" of Sutton, or the "cirrhosis" of Bastian. But there can be no doubt that here, at least, the sclerosed condition is the direct outcome of a pneumonic process. I think that the microscopical preparations shown are convincing on this head, all stages in the formation of fibrillated tissue being traceable from the intra-alveolar exudation of croupous pneumonia. The resulting induration is then more than a sequela, a new process started by the previously inflamed tissue. However desirable it might be to get rid of the phrase "chronic inflammation," still it signifies something more than the neutral term "sclerosis," or the even less applicable one of "cirrhosis." At the same time it would be wrong for me to deny solely, from the conclusions drawn from the case before me, that cases of indurative lung disease strictly comparable in their causes and character to cirrhosis of the liver or of the kidney do not occur. I am too much indebted to the clear and cogent teaching of Dr. Bastian to lightly make so sweeping a denial. I only wish to say that the present specimen resembled, in its macroscopical characters, the conditions described as "cirrhosis"; but microscopically it did not conform to the characters of that state. Before proceeding to relate the case, I may observe that in his course of patho-

[1] Since the above communication I have seen a second similar case.

logical lectures at the École de Médecine, in 1877, M. Charcot,[1] returning to the subject of his well-known inaugural thesis, published in 1860, clearly defined the true nature of the various kinds of indurative lung disease (exclusive of tubercular phthisis and chest disease), variously styled "cirrhosis" and "chronic pneumonia." The classification is as follows:

I. Chronic lobar pneumonia.
  A. Prolonged Lobar Pneumonia.
    1st variety—Red induration.
    2nd „ Red mingled with grey induration.
    3rd „ Grey or slaty induration.
  B. Recurrent lobar pneumonia.
II. Chronic Broncho-pneumonia.
  Carnification of lung with bronchiectasis.
  Corrigan's "cirrhosis," "fibroid phthisis," &c.
III. Chronic Pleurogenic Pneumonia.
  True interstitial pneumonia.

It seems to me that the specimen I now exhibit falls under the head of the above third variety of chronic lobar pneumonia.

To Dr. Greenhow I am indebted for permission to exhibit the specimen, and also for the following notes of the case:

J. G—, a plumber, 41 years of age, was admitted into the Middlesex Hospital, under the care of Dr. Greenhow, on October 23rd, 1878. His family history was unimportant. He had had good health until ten years ago, when he began to suffer from winter cough and shortness of breath, which during the last few years had become noticeably worse. He had never had hæmoptysis. There was no history of his ever having had gout, rheumatism, or syphilis, but he was a free drinker of beer and spirits. His present illness dated from two months before admission, when, after getting wet through, he again began to suffer from shortness of breath, cough, and attacks of darting pain passing from the right armpit towards the sternum. The pain was relieved by local applications, but the cough continued, and was accompanied by the expectoration of thick offensive matter. He became gradually very weak and ill, losing his appetite, and at length he sought relief at the hospital. He was an aged-looking, careworn, ill-nourished, pallid man, with bald head and grey beard. He was in an extremely prostrate condition, so as to

[1] Fully abstracted in the 'Revue Mensuelle de Médecine et Chirurgie,' 1878, p. 776.

preclude physical examination of the chest; and as he never rallied from this prostration, no extended examination was ever made. He appeared to be suffering from severe bronchitis, having a troublesome paroxysmal cough, with copious muco-purulent expectoration. There was considerable dyspnœa and severe cyanosis. There was also a high degree of pyrexia.

Throughout the thirteen days of his stay in hospital he remained very prostrate; was generally delirious at night; the temperature ranged between 100° and 103°. The urine was albuminous. During the last two days of life obstinate diarrhœa set in, and he died on November 6th.

The body was examined seven hours after death. Cadaveric rigidity slight. In left inguinal region a tumour, the size of two fists, found to consist of a hernial sac containing a large quantity of omentum, which was not adherent to the sac-wall.

*Thorax.*—Rib-cartilages not calcified.

The right pleural cavity obliterated in its posterior half by firm blending and thickening of its two layers, and elsewhere in the greater part of the cavity there was some tolerably firm adhesion between costal and pulmonary pleura. The left lung was nowhere adherent.

*Right lung* was removed, together with most of the costal pleura. A thin layer of false membrane coated the greatly reddened visceral pleura over the anterior part of the lower lobe. The lobes of the lung were firmly united together. The anterior two thirds of the upper lobe, as well as the middle lobe, were considerably pigmented, very voluminous, and emphysematous. The posterior and lower part of the upper lobe was perfectly consolidated, the consolidation reaching upwards to within two inches of the apex of the lung, and corresponding mainly to the region of adherent pleura. On section, the consolidated part was found to extend inwards to the depth of about three inches; it was extremely firm and tough, "creaking" under the knife, the cut surface presenting a uniformly smooth, glistening appearance, of a slate-grey colour variegated by scattered deposits of black pigment. Although the overlying pleura was considerably thickened, there were no well-marked fibrous bands traversing the altered tissue; but an appreciable amount of thickening occurred around the bronchi and blood-vessels, which appeared on the cut surface as scattered white fibrous streaks. This indurated tissue was sharply marked off from the emphysematous paren-

chyma in front of it, the prominent margin of the former being very uneven in outline. Lastly, the pleura covering the lower half of the anterior part of the non-consolidated portion was thick and opaque. With the exception of some cavities, presently to be described, the lower lobe was consolidated throughout, very tough and giving much resistance to the knife; the lobe presented on section a smooth and glistening surface, which close inspection proved not to be quite uniform, islets of spongy tissue being perceptible here and there. It was of a greyish and, in parts, of a pinkish-grey tint, stippled with points of black pigment, not markedly traversed by definite fibrous bands, save those forming the walls of the bronchi and blood-vessels. The blending of the pleural layers above mentioned formed a tough fibrous investment to the posterior border of the lobe, as well as to its inferior surface, which it had been found impossible to detach from the diaphragm. The upper and posterior part of the lobe was, however, the seat of a vomica, the size of a duck's egg, and of a like shape; lined by a tolerably thick and definite pyogenic membrane, it contained a quantity of dirty brownish-grey semifluid material of highly offensive odour, whilst shreds of sloughing tissue depended at one part from the wall; this wall was not smooth, but was rendered irregular and uneven by ridges running in various directions, as in a phthisical vomica. At the upper part of the cavity some further ulcerative action appeared to be in progress, for the cavity extended a short distance upwards into the adjacent portion of the consolidated upper lobe, the interior of this (more recent) part of the cavity being destitute of a definite lining and presenting a reddish colour. The cavity came close to the surface of the lobe above and posteriorly. In addition to this, the posterior part of the lobe was further the seat of numerous small suppurating foci, none larger than peas, full of pus, and closely packed together, so as to give quite a riddled appearance to this part of the lobe. The tissue surrounding them, although as dense, firm, and smooth as the rest of the lobe, was of a dark brick-red colour, so that it had a "carnified" appearance, which, on examination with a lens, proved to be due to the minute vascular injection of the tissue.

The bronchial tubes throughout the lung were full of muco-purulent secretion; their lining membrane was intensely reddened. It was thought that their calibre was slightly but uniformly dilated, but the dilatation, if any, was but small, certainly not proportionate

to the extent and degree of the induration. At the same time the whole volume of the lower lobe was certainly reduced in size, especially when compared with the size of the upper lobe. The lung, with adherent pleura, weighed 48 oz.

*Left lung* presented no consolidation whatever in any part. Its pleural covering was perfectly natural. The parenchyma was considerably pigmented, soft, non-crepitant, emphysematous. The bronchi contained some mucus, and their lining membrane was for the most part pale, or only blood-stained in places. This lung weighed 15 oz.

It should be added that neither lung presented any fibrous nodules, caseous or cretified masses, or other indications of early catarrhal pneumonia or tubercle.

There was a considerable amount of glairy tenacious mucus in the upper air passages, especially in the larynx, and also above and below the epiglottis. The laryngeal mucous membrane covering the vocal cords was deeply eroded, and that covering the anterior and inferior surfaces of epiglottis was thickly covered by mammillary elevations and minute erosions and ulcers.

The *heart* was rather large, weighing 9 oz. Tolerably firm fleshy clots filled the right auricle and ventricle, and extended into the pulmonary artery. Soft black clot in left auricle, the left ventricle being contracted and almost empty. Valves natural. Some scanty fatty degeneration of inner coat of aorta.

*Abdomen.*—Omentum well laden with fat. Mucous membrane of stomach pale and thick; of intestines highly vascular, with minute injection in parts of the ileum, but no ulceration in any part. Contents of bowel semifluid and pale yellow.

The *liver* weighed 60 oz., was swollen and friable.

*Spleen.*—No capsular thickening; tissue very soft.

*Kidneys.*—Both finely granular on surface, with red and white mottling of cortex, the consistency of which was diminished.

Various portions of the affected lung were examined microscopically, and I exhibit a series of specimens showing the changes met with. I shall first describe the appearances exhibited by sections from the densest part of the organ—that which presents the character of slaty induration to a most marked extent. Under a low power the thickened pleura is observed to send in processes into the pulmonary tissue, and the interlobular septa are obviously thickened and pigmented. Then much dense fibrous tissue encircles

bronchi and blood-vessels, the former presenting patches of black pigment in the midst of the more or less concentrically arranged bundles of connective tissue. The alveolar parenchyma presents a most intricate feltwork, for although the outlines of the alveolar walls can be plainly made out, yet the alveoli are shrivelled, and their interior appears to be filled with interlacing bundles of connective tissue running in all directions. Under a higher power it is remarkable to observe how in many parts the alveolar wall retains almost its normal tenuity. Its capillary plexuses are very prominent, but in the regions under consideration are hardly at all concealed by any thickening of the wall. And this occurs in parts where the interior of the alveolus is largely occupied by what appears to be fairly well-developed fibrous tissue, not arranged in any definite manner, but forming coarse felted bundles, which pass at many points to join similar bundles in the neighbouring alveolus. A few leucocytes are here and there entangled in the meshes of this felted tissue, and in some alveoli cells of a distinct epithelial type intervene between the capillary plexus of the alveolar wall and the organised contents. At the same time it is obvious that, in places, actually organic connection has occurred between the alveolar wall and the contents, for capillaries can be seen, filled with blood, here and there traversing the new fibrillated tissue. But that all these contents cannot be formed by outgrowths from the alveolar wall is, I think, shown by the study of other parts of the affected lungs, of which I shall speak directly. Nor is it true that in all parts of the induration the alveolar wall remains intact. It will be seen that, side by side with alveoli with unchanged walls are others where considerable thickening has taken place. Hardly anywhere, however, is it possible to fail in distinguishing the limits of the alveoli.

In close contiguity to advanced alterations like these are others showing transitional changes. There are parts, recently inflamed, where the alveoli are filled with a delicate meshwork of fibrinous condition entangling leucocytes and catarrhal cells in their meshes —appearances precisely those yielded by a recently hepatised lung. Again, other alveoli are filled with granular amorphous masses, evidently due to disintegration of the inflammatory products. Next in order come other alveoli, the walls of which are unaltered, but which contain within them a delicate, almost homogeneous, substance, which presents distinct fibrillation, and which passes over at various

points from one alveolus to another. In the interior of this material long and delicate spindle-cells can be made out, together with other bodies resembling leucocytes. One of the specimens exhibited shows this in a very striking manner (see fig. 1, Pl. XV). It is the first stage of *organisation of the exudation products* of croupous pneumonia. From this to a more organised, fibrillated, and vascularised intra-alveolar meshwork there seem to be all gradations of change. Fine and delicate capillaries containing blood can, here and there, be seen permeating the new tissue, and indicating that organic connection has been made between the alveolar walls and the alveolar contents. I believe that we have here evidences of actual organisation taking place in inflammatory exudations, probably through the medium of the exuded leucocytes. Certainly, the appearances admit far more readily of this interpretation than of that which assumes any ingrowth of new tissue from the alveolar wall. Then comes the final fusing of the whole parenchyma into the nucleated fibrous meshwork, the alveoli shrinking in bulk, and some of them presenting quite a shrivelled appearance.

But the lung shows also certain secondary changes. There is the gangrenous cavity in the upper lobe, and the disseminated foci of suppuration scattered throughout the layer. Of the former I have nothing to say; it is not uncommon in cases of this kind, and I have no microscopical evidence to bring forward with regard to it. But the latter is a change of great interest, probably caused by the inhalation of putrid matter into the bronchi of the lower lobe (for the abscesses are scattered throughout the posterior and most dependent part of the lobe); it presents us with an example of suppuration occurring in the recently and uniformly indurated parenchyma. The smooth marbled surface of section is riddled with the scattered points of suppuration, whilst the firm tissue around these points is intensely vascularised, so that it is further varied, and in parts uniformly reddened by minutely injected vessels. Microscopical examination shows very well the manner in which the suppuration has advanced. In the neighbourhood of one of the small abscesses there is an abundant infiltration of leucocytes in the alveolar wall. These walls are, more or less, concealed and thickened by the new cells, but what is most interesting is the fact that the newly formed *intra*-alveolar tissue has been destroyed by the secondary inflammation of the walls, for the alveoli here are all occupied by shrivelled granular masses, showing distinct fibrillation,

## DESCRIPTION OF PLATE XV.

Plate XV illustrates Dr. Sidney Coupland's Case of Chronic Lobar Pneumnonia. (Page 224.) From drawings by himself.

FIG. 1 represents section of that portion of the consolidated tissue which was the seat of secondary suppuration. At two points abscesses are seen, and around them there is abundant leucocytic infiltration. × 50 diameters.

FIG. 2. From a portion of the same section as Fig. 1, showing the shrivelling and degeneration of the intra-alveolar exudation-products. × 500 diameters.

FIG. 3. Portion of the consolidated tissue from the seat of "grey induration." The alveolar walls are almost unaltered, but the intra-alveolar exudation products show apparently the direct organisation of the inflammatory material in the development of spindle-cells and fibrillation. × 500 diameters. (See p. 230, to which the figure refers; and, p. 231, *for* Figs. 2 and 3, *read* 1 and 2.)

Fig. 1.



Fig. 2

Fig. 3.

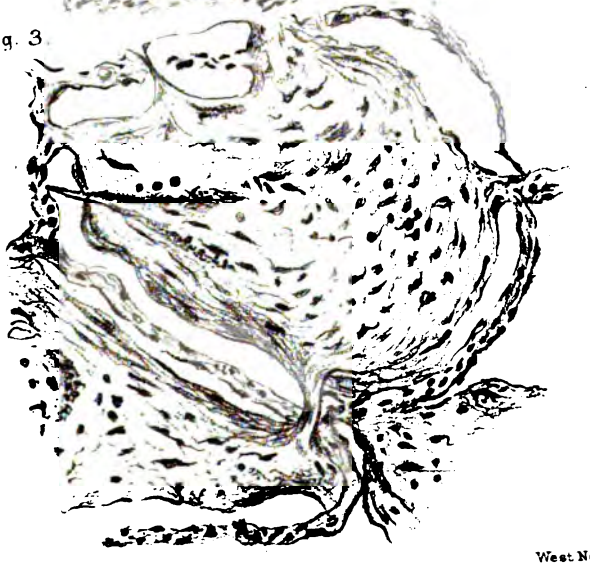

West Newman & Co. imp.

yet obviously degenerate. The intense inflammatory change in the alveolar wall has probably caused obliteration of the delicate new vessels supplying the new formed material. This has, therefore, been arrested in its growth, and has become, in fact, necrosed, whilst its shrivelled remnants can be seen partially filling the alveolus, or, perhaps, invaded by leucocytic infiltration (see Pl. XV, figs. 2 and 3).

In conclusion, it seems to me that the consolidation in this case—a true example of the slaty-grey induration of Addison, and also an example of the "fibroid degeneration" of Sutton—is mainly due to organisation of the products exuded into the alveoli in inflammation of the lung. The process seems to be still in progress, and thus we have had an opportunity of observing it in its various stages. It is, then, strictly speaking, a chronic lobar pneumonia.[1] It is right to add that the organisation of intra-alveolar products has been pointed out by Dr. Green ('Pathology,' 3rd ed., p. 347), but I am not aware that any other writers have drawn attention to it, or, at any rate, have laid that stress on it which it surely deserves. The other points in the case worthy of note are the association of this condition with granular kidney and a history of chronic alcoholism. Such an association was pointed out by Dr. Sutton as being evidence in favour of the "fibroid-degeneration" view, for it was met with in most of his cases. As to the diffuse suppuration in the lower lobe being due to inhalation (or rather, perhaps, the gravitation) of the foul material from the gangrenous cavity, there is collateral evidence of the intensely irritating character of this material in this case in the presence of the laryngeal ulceration and the supervention of diarrhœa towards the close of life, when the patient had no longer any power to expectorate, and probably swallowed much of this putrilage.

*January 7th*, 1879.

[1] It is hardly necessary to point out that this differs wholly from "chronic interstitial pneumonia." *There* the indurative change affects mainly the inter-lobular septa, an anatomical seat analogous to that of the hepatic change in ordinary cirrhosis of the liver.

### 3. *Nodular fibroid phthisis,? syphilitic.*

By James F. Goodhart, M.D.

*Fibroid phthisis, with disseminated caseous nodules in the lung, some of these breaking away from the lung tissue and one of them leading to rupture of a vessel and hæmoptysis; emphysema; granular kidneys.*

A man, æt. 55, was brought to the hospital for severe hæmoptysis, and he died ten minutes after his admission. The only history that could be obtained was that he had had repeated attacks of hæmorrhage.

He had grey hair but was fairly nourished, and his skin showed no trace of stain or scar of any description.

The hinder part of each parietal bone was irregular, as if it might have been formerly inflamed, but the pericranium was not inflamed, and the bones presented no particularly characteristic appearances.

It may be further added, to shorten the description as much as possible, that, granular kidneys excepted, there was no disease in any other organ but the lung.

There were a few old adhesions about the right pleura. The left was finely adherent and much thickened over its upper half; occasional adhesions elsewhere.

The upper lobe of the left lung was in a state of extremely dense fibroid change, greyish in colour, and cicatricial in appearance. This material enclosed two or three cavities, half an inch in diameter, one of which was punched out of the fibrous area, much like some old and deep indolent ulcer in the leg. These cavities had smooth walls without granulation. In other parts of this lung there were disseminated nodules of all sizes and all remarkable for their denseness. Most of them, particularly those which had reached any size, were of a yellow caseous appearance, enclosed in a firm capsule of fibrous nature, and in several places separating from the lung tissue by a sharp crack, as if the indurated material had torn away from the soft healthy lung. The nodules, though looking yellow and caseous, were most of them very tough, some of them calcareous; only one or two pultaceous. The smaller nodules, though easily felt, were with difficulty distinguishable to the eye, because their dark-grey colour so much corresponded with that of the lung. The lung tissue intervening was

extremely emphysematous (Pl. XVIA, fig. 3). In the other lung the disease, as far as the nodules are concerned, was quite similar. They were even more numerous, and it was in the upper part of the lower lobe on this side that the hæmorrhage had occurred from a large branch of pulmonary artery, into which the ulcer at the edge of one of these masses had opened. There was no aneurysmal dilatation of the vessels of the lung. The apex on this side was nearly free. The unaffected parts were even more emphysematous than those upon the other side. The larynx and bronchial tubes were healthy The microscopical appearances are depicted in Plate XVI A, figs. 3, 4. Fig. 3, under a low power, shows a nodule with emphysematous lung around it. Fig. 4 is from the margin of one of the fibroid nodules showing the giant cells and stroma.

This case was exhibited to elicit an opinion as to its nature. Nothing is known of the man, and there was no evidence whatever of any syphilitic lesion in the body; and yet, from what I have seen and from what others have recorded of lung disease in cases of undoubted syphilis, I consider the morbid appearance in this lung to be characteristic enough to enable me to say that the patient had had syphilis. *December 3rd*, 1878.

---

## 4. *Two cases of tubercle of the lung, spreading from yellow elastic nodules in the lung (? gummata).*

By JAMES F. GOODHART, M.D.

1. *Old syphilis; gummata (?) in the lung, with secondary grey tubercle round them; amyloid liver, stomach, and intestines; amyloid and granular kidneys; uræmic convulsions.*

A MAN, æt. 37, was admitted, under Dr. Moxon, into Guy's Hospital on April 10th 1878. He had previously been an inmate of the same institution four times, three times for periostitis and albuminuria, once for albuminuria and fits. His father died of phthisis, at 32. No history of gout or rheumatism. He had syphilis sixteen years ago and he had drank hard of spirits. He was very wasted, with jaundiced skin, his liver down to the umbilicus, and his urine, of low specific gravity, containing a little albumen.

His chest was carefully examined, and nothing detected but deficient entry of air into the right lung. He died about three weeks after his admission from uræmic convulsions.

The brain and skull were healthy.

Both lungs were very symmetrically diseased, and much of this was indubitable grey tubercle rather thickly clustered. But what was most noticeable was that in the centre of many of the tubercular tracts were sharply defined tough yellow nodules, the size of large peas. Some of these looked very like gummata, and gummata I am inclined to think they were. Each lung contained several such, and in every case the nodule appeared to have acted as a centre for the spread of grey tubercle round it (Pl. XVI). The apices were free from tubercle, though a good part of each upper lobe was affected. There was no marked fibrous change. The position of the yellow nodules is shown in the Plate. They were studded about the lower lobes. The larynx was healthy. The solid viscera and intestine were lardaceous, the kidneys being granular in addition, and full of small cysts. There was no other evidence of syphilis. The testes were healthy. The microscopical appearances of the disease in this lung are shown in Plate XVI A, figs. 1, 2.

2. *Cancerous ulcer of the hepatic flexure of the colon; peritonitis; gumma in the lung, with tubercle round it; gumma in the testes; ? gummatous aortitis.*

The patient was 62 years of age, and was admitted to Guy's, under Dr. Moxon, May 15th, 1878. He was married, and had a family of nine children. No history of tumours in the family. Twelve months before admission he had an attack of severe griping pain in the umbilical region of the abdomen. This was gone next day, and he remained well until a month before he was admitted; since then he had had diarrhœa and abdominal pains which became so severe a week before he came that he gave up work in consequence. Then he vomited, and has continued to do so two or three times a day since. The pain was spasmodic and the abdomen had gradually become distended. He said he had not wasted at all, but he was very spare. The abdomen was distended in the cæcal region, and more flat in the region of the transverse colon, so that he was thought to have some stricture of the hepatic flexure. His lung attracted no attention and was not known to be diseased. He continued to vomit, and died collapsed.

## DESCRIPTION OF PLATE XVI.

This Plate illustrates Dr. Goodhart's Case of Tubercle of the Lung spreading from yellow elastic Nodules in the Lung (? gummata). (Page 233.) From a drawing by Mr. W. Hurst.

The lung has been cut open and the section turned back. At the lower part of the lobe are some yellow masses with grey miliary tubercle distributed thickly round them. The upper part of the lobe is quite healthy.

H. Knight del. lith.

West, Newman & C° imp.

## DESCRIPTION OF PLATE XVI A.

This Plate illustrates Dr. Goodhart's Cases of Fibroid Tubercle and Tubercle spreading from Caseous Nodules. (Page 232.) From drawings by himself.

FIGS. 1 and 3.—Tubercle spreading from caseous nodules (see coloured plate).

Fig. 1.—Showing tubercular infiltration of the walls of the pulmonary alveoli. $\frac{1}{8}$ in.

Fig. 3.—From the margin of a small caseous nodule.

*a, a.* Giant cells.

*b, b.* Tubercular nodules. 1 inch.

FIGS. 2 and 4.—Fibroid tubercle.

Fig. 2.—From the margin of one of the fibroid nodules.

*a, a.* Giant cells.

*b.* Fibrous stroma. $\frac{1}{8}$ inch.

Fig. 4.—Section of a small tubercle.

*a.* Vessel with pigment in its walls.

*b.* Compressed air vesicles.

*c.* Septum containing pigment.

*d.* Tubercle.

N.B.—In the text, page 233, *for* "Fig. 4" *read* "Fig. 2."

Fig 1

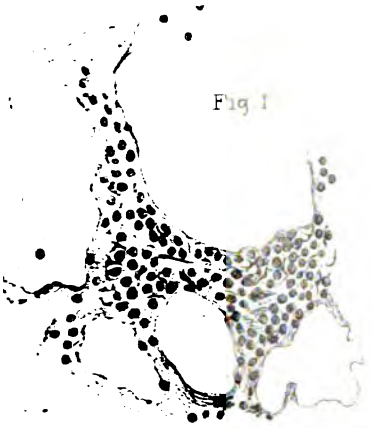

Fig 2

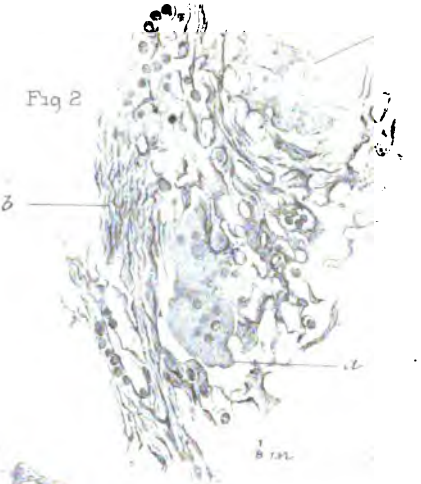


Fig 3

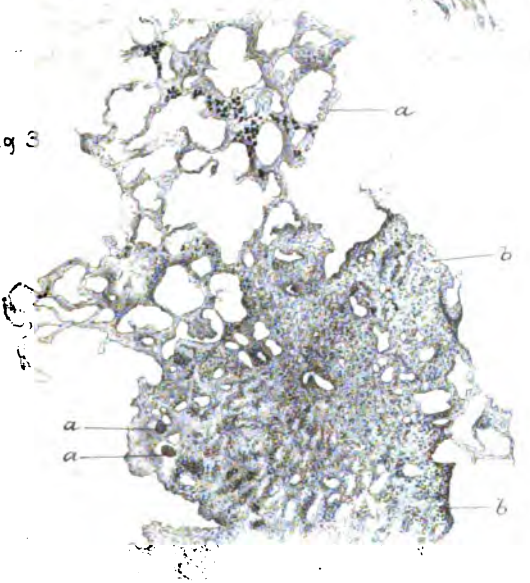


Fig 4



At the *post-mortem* a circular, tough yellow nodule, quite like a gumma, was found in the hinder part of the upper lobe of the right lung. Round it was a quantity of grey tubercle, and similar grey tubercle was found in the other lung.

In the ascending arch of the aorta about an inch above the valves was a half inch diameter isolated nodule of leathery atheroma, with central softening. The abdominal aorta was patchy and atheromatous.

There was an annular stricture of the colon under the gall-bladder, which admitted the index-finger easily. The intestine above the stricture was distended with pultaceous fæces, and its coats were thick; that below was empty. The mucous membrane of the bowel above was ulcerated. Under the microscope the constriction proved to be due to a spindle-celled sarcoma. One testis contained a circumscribed fibrous patch (gumma).

I examined the lung from the first case microscopically, and there could be no doubt of the tubercular nature of the disease; that is to say, it consisted of nodular interstitial growth, in some places caseating, in others fibrillating, and with giant cells here and there (see Pl. XVI A, figs. 1, 2).

The drawing exhibited of the first of these two cases shows to what an extent the growth of grey tubercle has gone on.

The case seems to me of interest from two points of view. In the first place, if I am right as to the gummatous nature of the nodules, ti may be taken to prove that well-marked grey tubercle will develop in the lung of a syphilised individual quite unmodified by the syphilitic virus; in the second place it is an example of a chronic inflammation of specific origin, and in no way tubercular, leading by a slow process of infection to the development of tubercle in the parts around it, and it is in this way that the case is of especial value.

I do not want it to be considered that I bring the case forward as a proof that syphilis will lead to the development of tubercle. I merely wish to put the case on record as one where *non-tubercular* has led to tubercular inflammation. Its value is of course but little as an isolated case, but taken with others which have been recorded, and with the many more which doubtless will be recorded in the future, it will help towards the proof which is slowly developing that tubercle is not pathological but anatomical, not an entity but a form.

P.S.—It was suggested at the meeting of the Society by Dr. Douglas Powell, that the nodules described were similar to those described by Dr. Reginald Thompson, and ascribed by him to the impaction

and inspissation of blood in the bronchia from previous hæmoptysis.

I have submitted my specimens to Dr. Reginald Thompson, and he considers that they are the relics of old pulmonary hæmorrhage. But I may add that I have also had an opportunity of examining Dr. Thompson's specimens by his kindness, and I still consider that the microscopical differences between his slides and mine are considerable, and bearing in mind that many things undergoing fatty changes must necessarily put on the characteristic of yellowness, and that toughness and elasticity are certainly attributes of gummata as well as of old hæmorrhages, I still think that these nodules are very probably gummatous. *December 3rd*, 1878.

---

## 5. *Two cases of pneumothorax of the right side.*

By Samuel West, M.B.

Henry H—, æt. 22, was admitted into Victoria Park Hospital with phthisis of both apices. He gave the history of two years' dyspnœa and cough, of slight hæmoptysis twelve months before admission, and loss of strength and flesh for the last six months. His father had died of phthisis, it was said, but all his brothers and sisters, five in all, were healthy. For five weeks after admission he gradually gained flesh and strength, but was then suddenly attacked without any apparent cause, with great dyspnœa and pain in his right side. Physical examination showed that pneumothorax had developed. Twenty-four hours later the dyspnœa became so urgent that the right side was tapped with the aspirator and about 120 ounces of air escaped. Twelve hours later he was tapped a second time, with the removal of still more air. On each occasion he was much relieved, but only temporarily, and about forty-eight hours after the sudden attack he died.

The following is a brief account of the *post-mortem*. The abdomen was opened in the usual way and the left half of the sternum removed. The organs were then found in the following positions: The liver was much depressed, so that the lower border came about

an inch below the umbilicus. This depression affected chiefly the right lobe, so that the organ was remarkably twisted, the notch between the lobes being situated just under the tip of the ninth rib on the left side, and the left lobe in great part hidden from view under the ribs. The gall bladder, which was not visible on the surface, was found slightly to the left of the umbilicus. Between the upper surface of the liver and the lower edge of the ribs on the right side was seen the lower surface of the diaphragm convex downwards. The apex of the heart was under the sixth rib, three inches outside the nipple line; it was not twisted in any way, but was simply pushed over; the left pleura was much distended and reached, opposite the third rib, two inches to the left of the middle line of the sternum. From this point its left border curved towards the right sterno-clavicular joint above, and to the xiphoid cartilage below. Above the clavicle it rose one inch and a half into the root of the neck. These limits corresponded almost exactly with the percussion areas obtained before opening the body as seen in the diagram. On opening the right side of the chest the right lung was seen flattened from side to side. There were some few adhesions at the apex, but nowhere here was the pleural cavity completely obliterated. As the lung lay in the chest against the spine the perforation-hole was seen in its mid-lateral aspect, of the size to admit perhaps a No. 3 catheter, oval in shape, and somewhat funnel-shaped, from the fact that the pleura after perforation had retracted slightly from the edges of the opening. The pleura for some distance around was infiltrated with pus, but there was no general pleurisy, and not more than two ounces of serous fluid in the pleural cavity.

The hole was found to communicate with a small cavity in the middle of the upper lobe (there was no middle lobe in the lung), of the size of a cherry. The walls were soft, slate-coloured, and covered with caseous matter. There were besides numerous other small cavities, many of them superficial, and in the apex one measuring about three quarters of an inch in diameter.

The left lung was emphysematous, with chronic bronchitis and peribronchial thickening. There were several cavities pyriform in shape, and superficial, evidently bronchiectatic; one in the apex was about two inches long, and irregular in shape. The walls were much thickened and hard, but not caseous.

In the second case the patient was a man æt. 40, who was admitted

for what was believed to be rather rapidly advancing phthisis. He gave a good family history, and stated that he had only been ill for the last four months.

Like the last case, he was suddenly seized by pain in the right side and dyspnœa; was found to have pneumothorax and died in about forty-eight hours.

The body was examined in the same way as the last, the organs were all similarly displaced, and the description of the last case applies in all its details to this one also.

The pleural cavity was obliterated by old adhesions over nearly the whole upper lobe of the right lung. The perforation hole lay upon the postero-lateral surface, and was of about the same size as the last, and, like it, oval in shape. It communicated with a cavity, irregular in shape, and about two inches in diameter, situated in the upper and posterior part of the lower lobe, the upper wall of which was formed by the thickened pleura between the upper and lower lobes. Its walls were thickened, with coarse trabeculæ (the remains of the old vessels, &c.), and caseous. The upper lobe was converted almost entirely into one large cavity, the walls of which were in the same condition.

In the left lung there were numerous small cavities, with a good deal of caseation. The trabeculæ of the lung and the peribronchial tissue were somewhat thickened, and in addition a great part of the lung was solid with recent pneumonia, probably catarrhal.

In this last case the changes in the lungs were those which are characteristic of the more acute forms of phthisis, in which the softening of caseous pneumonia plays such an important part, and it is with these changes that the pneumo thorax is usually associated. In the first case, however, there was but little caseous degeneration, the change in the lungs being almost exclusively those due to chronic bronchitis and bronchiectasis, and that pneumo thorax should develop under these conditions, is I believe, an event of rare occurrence. *March 4th*, 1879.

## 6. *Cases illustrating the lung changes caused by compression of the large bronchial tubes.*

By J. Pearson Irvine, M.D.

Case 1. *Destructive pneumonia. Compression of left bronchus by an aneurism of the ascending aorta.*

Charles S—, æt. 43, a groom, was admitted into Charing Cross Hospital on January 22nd, 1878. He could give but little account of his family history; his father and mother died at advanced ages, probably of bronchitis. The patient himself had suffered frequently from mild attacks of rheumatism, but up to March, 1877 was never seriously ill. He then caught cold, which was followed by a violent dry cough, which continued up to the time of his admission. In August, 1877, he came up to London from Newmarket, and attended as an out-patient at Brompton Hospital, but went on with his work, until increasing dyspnœa and other symptoms forced him to give up his occupation in January, 1878. During his illness he had oftentimes experienced "choking sensations" which occasionally started him in his sleep. Feelings of "tightness" about the chest had troubled him, compelling him to "open his waistcoat," and preventing him from eating for an hour or more after he got home from his work. He never brought up blood. He had been a free drinker, especially of beer and whiskey, and in his work as a groom at Newmarket had been considerably knocked about. But he could give no account of any direct injury to his chest or elsewhere, and there was no history of syphilis.

During the six weeks the patient was in the hospital he was on the surgical side. His symptoms were a continuation of those just given, varying from time to time. There were evidences of aortic aneurysm; a tumour with expansile pulsation was felt in the right and left second spaces near the sternum; there was dulness over the manubrium, and an inch outside the sternum from the right clavicle to the second space. On the left side, dulness was lost in lung dulness. There was also a systolic murmur over the pulsating tumour, and the second sound was sharply accentuated. The left back was dull almost throughout, and absolutely dull and resisting over its lower half. There was no falling in of the side; on the contrary, it seemed very full though the spaces did not bulge. Vocal fremitus was moderately strong. In

front the same signs were met with, but the dulness was less absolute at the upper part of the chest. The breathing was bronchial over the back, with corresponding râles, which were not numerous. During the progress of the case amphoric breathing took the place of bronchial over the back, and the râles became more metallic and gurgling. Whispering pectoriloquy also developed, and there occurred, in short, evidences of disintegration of the left lung. There was, from the first, almost complete loss of expansion on the left side, and over the left bronchus in front, and along the left spine as low as the middle of the scapula stridulous breathing. The right lung presented all the evidences of a very extensive emphysema. As I have said, the general symptoms were a varying cough, with but little expectoration, and that mainly bronchitic and free from blood, and sensations of choking and dyspnœa. The voice became changed shortly after admission, and orthopnœa was decided towards the last. The patient sank from exhaustion on March 11th, 1878.

The *post-mortem* examination was made on March 12th, 1878. There was no depression of either side of the chest, and both lungs encroached across the middle line of the sternum. The pleuræ on the right side were everywhere free, but on the left generally adherent. The right lung was an excellent specimen of large-lunged emphysema; in its apex two caseous nodules of small size were found, evidently very old, and undergoing no disintegration. The left lung was so adherent that in attempts to remove it, it broke down, and sero-sanguineous fluid escaped in large quantities.

An aneurysm was found involving the ascending part of the thoracic arch, and about the size of an orange. It had grown backward and to the left so as to compress the left bronchus, and it is remarkable how a comparatively small tumour growing in this direction can grasp the bronchus, and thus lead to decided lung-changes. The left vagus traversed the aneurysm, and was of course stretched, but no change could be found in it or the pulmonary plexuses.

The left bronchus of all the air-passages was the only one compressed. What then were the changes in its lung? It was larger than natural, so that its anterior border crossed the middle line; it was adherent, and on removal looked more like a solid viscus than lung. It was marked on the surface by the ribs, and the red-and-white pressure bands across it alternated more distinctly than in many cases of acute croupous pneumonia. The general surface was

smooth and hard to the touch; the pleura over it was greatly thickened, and the lobar divisions were obliterated by adhesions, which varied as regards chronicity, some breaking down quite readily. The lung itself was remarkably changed. On section the upper lobe was found to be cribriform, and the epithet "honeycombed" was particularly applicable in its description, for regular and distinct cavities, about the fourth of an inch in diameter appeared on section, and these were bounded by fibrous walls, to all appearances mainly the remains of the fibrous tissues of the lungs. The cavities were filled with muco-purulent matter, which resembled those described in my previous cases.[1] The lower lobe of the left lung was hard, firm, and solid; the surface of sections had generally a "gelatinous" look, interrupted by thickly-sown, creamy-yellow, caseous patches. Some of these were as big as a millet-seed only, others had run together into masses the size of a sixpence, and there were all gradations between these diameters. All were surrounded by the gelatinous band alluded to in this and in previous cases. The whole of the appearances—the honeycombing, the caseous nodules in various stages, and the gelatinous consolidation—were exceedingly characteristic—judged by other specimens—of those met with in the lungs in which there has been chronic compression of bronchia.

The degree of the compression in this case was considerable, and possibly had come on with comparatively great rapidity; the aneurysm gripped the left bronchus immediately below the bifurcation, had led to perforation of its softer coats, and had partially disintegrated the cartilaginous rings. The disorganisation was so great that two ulcerated openings were found in the bronchus, each as large as a small bean, and these perforations were exactly opposite the greatest pressure-points of the aneurysm, but the aneurysm itself—perfect as regards its walls—had not ruptured into the bronchus.

CASE 2. *Aneurysm of aorta and destructive changes in left lung (destructive pneumonia) from compression of its bronchus.*

Sarah C—, a charwoman, æt. 50, came into Charing Cross Hospital on May 31st, 1878, under the care of Dr. Pollock, whom I have to thank for the chance of showing the specimen. Up to six

[1] 'Path. Trans.,' vols. xxviii and xxix.

months back her health had been fairly good, and her family history was singularly satisfactory. She was the mother of three children, and had suffered from four miscarriages, attributed to the "unkindness" (which meant the violence) of her husband, traces of which remained as scars on her nose and forehead. There was no definite history of syphilis. Her husband was given to drinking, in consequence of which she had to work hard as a charwoman for many years. Six months before her admission her illness began with what she described as a cold. At the time she was living in a damp kitchen, and exposed to all the vicissitudes of her occupation. Breathlessness was the leading symptom of this attack, but cough and expectoration quickly followed, and then pain, which was mostly felt at the lower part of the left chest. She suffered also from palpitation (which was an old symptom with her), and became an out-patient at a dispensary, but, not improving, was obliged to seek relief in a parochial hospital, where she stayed a week only. For some time afterwards she was not under medical care, though she continued to cough and to suffer from pain in the left side, chiefly after attacks of coughing. She could do no work, her appetite was lost, she wasted rapidly, had night sweats, and was admitted into Charing Cross Hospital in a very debilitated condition.

She had some œdema of the legs on admission, but this quickly disappeared, and there was no albuminuria. Her cough rapidly abated, except at night; the sputa was purely bronchitic, and small in quantity. The temperature was never high, but there were occasional rises lasting a few days, the highest noted being 102·8° Fahr. The pulse was usually full and "bounding," and averaged 108; the tongue moist, but with a glazed and leathery look. Her appetite and her condition generally rapidly improved after admission.

On examination soon after admission the left chest was found to be "deficient" in expansion; there was over it universal dulness on percussion, with tenderness also, due, in part, to repeated examinations. The side was so large that pleurisy, with effusion, was suspected, and the heart's apex was too far to the right. But vocal fremitus and resonance were not wanting, and probably increased on this side, and on auscultation amphoric breathing could be heard, "distant" in character, but still distinct, and unaccompanied by râles. At the base, in particular, was *distance* in the sounds remarkable. The whispering of the patient was also audible even at the extreme base, though it was indistinct as regards the words uttered.

On the right side there were marked evidences of emphysema and bronchitis, which it is not necessary to give in detail. Râles of sibilant and sonorous character are met with, and the percussion-note was hyper-resonant. The subclavicular region on the left was as dull as parts below, and this I venture to think an important fact, because in most cases of pleuritic effusion we do not find absolute dulness in this place, but that peculiar tympanitic note which a compressed lung yields. A pulsation was met with in the second left intercostal space near the sternum, and, as this was expansile, aneurysm was diagnosed.

The additional signs of aneurysm were, bulging of the chest at this part, a thrill synchronous with the contraction of the ventricle, and a systolic murmur. The pulsation in the interspace was visible as well as palpable, but it was impossible to circumscribe the dulness of a probable aneurysm because of the universal dulness on the left side.

During the time the patient was in hospital the pulse continued equal on the two sides. The second sound over the aorta was "roughened," and the heart's action, generally, quickened. There was no apex murmur.

There was little change in the symptoms after her admission. The temporary improvement due to quiet and nursing did not continue, and it soon became clear that the case was almost hopeless. The temperature fluctuated between 98° and 101° Fahr., but never reached the height met with in ordinary acute phthisis. A symptomatic treatment was followed to the relief of the patient; quinine was given with good results, ammonia and bark were at times also followed by satisfaction, then opium was required; in short, the case was one of those in which the best treatment is that of almost constant change of remedies at our disposal. This means in such a case, that the prognosis was fatal; and the patient did not improve. The right side of the chest expanded so rapidly that the left seemed sunken, and puerile breathing over the right lung became most decided, while over the left distant amphoric (or tubular) sounds became more marked.

In August the harsh systolic bruit at the base of the heart and over the upper half of the sternum was much more determined; and at this time the bronchitic expectoration was more profuse than it had hitherto been. The temperature also was very irregular, and evening exacerbations reaching 102° Fahr. were commonly

followed by morning falls to 98° Fahr.; and these peculiar variations of fever suggested the possibility of the existence of left empyema. Almost up to the day of death these irregularities of temperature occurred; but on September 26th, 1878, the patient had an attack of hæmoptysis, and shortly afterwards died.

On *post-mortem* examination the body was not much emaciated. The right lung was a typical specimen of large-lunged emphysema. The left lung was adherent almost throughout, and there was no fluid in either pleural cavity. The adhesions of the pleura and lung were most marked at the apex and base, and in some places they were nearly half an inch thick, and quite gristly in their character. The left lung sank when placed in water, and when cut into its substance was found to be firm and tough throughout. Large quantities of pinkish purulent-looking matter escaped from the surface of sections of this lung, and evidently came from loaded bronchial tubes, dilatation of bronchial tubes and consecutive cavities. The bronchiectatic condition was generally and evenly distributed, and had been followed by destruction of lung tissues and increase in the fibrous elements of the lung. The glands in the tracheal bifurcation were very large and blackened. There was no blood in the left bronchus, but the trachea contained much clotted blood. An aneurysm, involving in a very irregular manner the arch of the aorta, had ruptured into the left bronchus. The aneurysm began an inch above the root of the vessel, was sacculated in kind, and its walls were exceedingly fragile. There was but little adventitious growth in them, which consisted of the external coat of the vessel. The aneurysm was not larger than an orange (with saccular projections), but had so grown as to compress the left bronchus and completely occlude it, and to cause ulceration of all its walls immediately beyond the division of the bronchi. The right bronchus was not compressed. The recurrent laryngeals, right and left, were equally affected. The aneurysm contained no firm clot, but in parts was lined by thin layers of fragile fibrin. Death occurred from hæmorrhage, the aneurysm having ruptured into the compressed bronchus.

CASE 3.—*Emphysema, collapse, and destructive changes in the left lung, due to compression of its branches by an aneurysm of the aorta.*

Henry F—, æt. 50, a London brickmaker, was admitted into

Charing Cross Hospital on September 24th, 1878, under the care of Dr. Silver, whom I have to thank for the opportunity of showing the specimen. His family history was excellent, and he knew of no relations who had suffered from chest affections. He himself had not had a day's illness until Christmas, 1877, when he got wet, caught cold, and began to cough very much. He became weak, but kept about and worked irregularly, sometimes being unable to do anything at all. In May, 1878, he attended as an out-patient at Brompton, and shortly afterwards began to have more or less fixed pain in the *right* side. His cough was at the time troublesome, and the expectoration bronchitic (judging by his description), and occasionally streaked with blood. He had no night sweats and no œdema of the legs, but wasted rapidly. He was not a man of temperate habits. Beer had been his favourite drink, in large quantities.

After admission it was found that the man had considerable orthopnœa, and that his voice was husky. His expectoration was muco-purulent and considerable, his cough troublesome, especially at night, and there were frequent attacks of paroxysmal dyspnœa. The chest was as barrel-shaped as that of the most typically emphysematous; the right side was hyper-resonant, the breath-sounds over it of a harsh blowing character, and bronchial râles were here and there audible. The left side, though large as the right, was dull at the base, and absolutely dull over its lower third. There was a loss of resonance (a tympanitic note) on the upper half of this side, and the dulness resembled that of pleuritic effusion, in the fact that it gradually passed into a tympanitic note from below upwards. At the left base (as high as the angle of the scapula) the breath sounds were amphoric and very distant, but distinct, especially on forced breathing, and accompanied by corresponding râles. Over the same part could be detected whispering pectoriloquy and strong bronchophony, with certainly no diminution in the vocal fremitus. There was little expansion (if any) of the left base. The heart's apex could not be localised, but its general impulse was in the normal position; its sounds were indistinct, but pure. In the second and third right spaces, about an inch from the sternum, there was an expansile pulsation, not continuous with the cardiac impulse though synchronous with it, and there was here also an irregular area of dulness difficult to circumscribe (without painful percussion) because of the decided

emphysema. A systolic murmur could be heard over the seat of pulsation, and a sharply accentuated second sound. The urine was full of phosphates and free from albumen.

During the patient's stay in hospital his breathlessness, huskiness of voice, &c., continued. His pain was mostly in the right infra-axillary region, to which opiate fomentations were applied. The left side gradually but rapidly increased in dulness from below upwards, and the other physical signs mentioned continued to be met with. The side did not fall in, and the intercostal spaces did not bulge as the degree and extent of dulness increased. Towards the end the right chest changed materially; there occurred diminished resonance at the base, and increase in the bronchial râles, the subcrepitant variety at first prevailing. The temperature was almost from the first normal or subnormal, and from October 26th to November 9th it was subnormal. On November 16th it rose suddenly to 103° Fahr., and next day the patient died.

He had been, therefore, about two months in hospital, during which time pain in the chest, cough, and dyspnœa of a paroxysmal kind had been his main troubles. Ethers, ammonia, camphor, and opiates internally, as well as external applications were tried to relieve his symptoms with a certain amount of success, but the man sank very rapidly in spite of all efforts and remedies.

The *post-mortem* examination was made the day after death, and a large quantity of perfectly clear serous fluid was found in the left pleura, and the left lung was partially collapsed. The right lung extended beyond the mesial line, and was emphysematous. The pericardium was thickened and universally adherent, and the anterior margin of the left lung was firmly connected by these adhesions with the pericardium. There was a complete matting together, in fact, of the mediastinal tissues. On casual examination one could see a general dilatation of the aorta immediately beyond its valves, and at some points this vessel had become eroded, and was protected from rupture by the strong adhesions, that is, the fibrous growths, in the mediastinal tissues. The pulmonary artery was dilated as well as the aorta, though on it the aorta must have encroached. The left lung, though partially collapsed, was distinctly emphysematous. On section it showed scattered pneumonic patches—in fact, the early changes met with in compression of a main bronchus. The aneurysmal condition of the aorta was most interesting; it was, in the old sense of the term, almost entirely

"false," and the blood had channelled through parts which had given an adventitious protection. But the outgrowths of the vessel had compressed the left bronchus, and thus caused death, and the case is valuable because it shows that external compression of a bronchus may set up a variety of accidents, and because the exact determination of these must direct the medical and surgical treatment. The aneurysm was of the rapidly-growing kind; the arterial walls had yielded at once, and a sacculated condition had followed whose particular pouches had not given way because the outside tissues in the mediastinum had developed fibrous changes. Such changes could not avert the dangers of compression, though for a long time they might have prevented death from rupture of the diseased artery.

The fact that in one hospital alone numerous cases of decided lung changes in association with compression of a main bronchus have been met with in a comparatively short period shows that instances such as those reported are not clinical or pathological curiosities, but examples of almost every day disease. In the 'Pathological Transactions' for 1877 and 1878 (vols. xxviii and xxix) I have attempted to describe the results of the compression of a main bronchus, and I need not again dwell on the dangers in detail. It appears to me beyond all question that the vast destructive changes met with are a mechanical consequence of bronchial compression, and not due to compression of the nerves, as has been asserted. It has been maintained by me that emphysema is the first result of a gradually increasing outside occlusion of a main bronchus, and the case of Henry F— most decidedly bears out this view. Where the trachea itself is compressed emphysema develops in both lungs, and if the compression affects one bronchus more than another the emphysema is more decided in the corresponding lung. The emphysema is a consequence of the gradually increasing impediment to expiration which outside pressure from aneurysm must cause. The same pressure would, of course, lead to accumulation of secretions, and thus bronchiectatic and emphysematous changes would go on together when the obstruction became well developed. Destructive changes would follow or accompany these, collapse might occur in lobes or lobules, and thus, *post-mortem*, a series of intermingled changes or a striking single change might be found. I have so completely explained my views in the 'Transactions' and elsewhere that I should be simply taking

up space without a fair reason if I dwelt upon them more fully. All the changes named have been found in a number of cases, and in all there was no proof that pressure on nerves was the cause of the mischief. Sir William Gull in 'Guy's Hospital Reports' for 1859 described destructive lung changes, and believed them to be due to pressure on the nerves. In no single case met with in my series was this interpretation of the changes applicable, though of course one must admit that pressure on nerves might lead to destructive changes in the lungs, as it does elsewhere. But it would be difficult to explain the occurrence of emphysema by the nerve-pressure theory in these cases, and in the many and varied appearances met with, and the symptoms during life could be explained by the mechanical compression of the bronchi, and as that pressure was invariably found on the side in which the changes occurred it seems fair to decide that in the cases reported by me compression of the bronchus and end of nerves was the cause of all the mischief. I would only add that in all the cases it was the left bronchus which was compressed by aneurysms.

Both from a clinical and pathological stand-point the results of pressure by aneurysms or other mediastinal growths are important. I venture to advance—(1) that emphysema follows compression of a bronchus; (2) that bronchiectasis may be associated with this emphysema; (3) that destructive pneumonia may follow it; (4) that collapse of the lung whose bronchus is compressed may occur early in the stage of compression, and that pleuritic effusion may in consequence occur; (5) that pressure on the vagi may affect the nutrition of the lungs; (6) that in many cases, while the mechanical effects of the bronchial compression are beyond doubt, the pressure on nerves may take an important part in the general results.

It should be added that in many cases aneurysm may compress the lung substance directly, and thus bring about clinical signs and pathological appearances which it would be out of place to dwell upon in this paper. I venture to ask comparison of my cases with one reported by my friend Dr. Powell. *January 21st*, 1879.

## 7. *Mediastinal tumour invading the right lung and occluding its bronchi.*

By R. Douglas Powell, M.D.

I bring this case forward as of special interest in connection with the series of similar cases just shown by Dr. Irvine.

This specimen was removed from a man, æt. 42, who was admitted into the Middlesex Hospital under my care (through the kindness of Dr. Cayley) on December 3rd, 1878. He was a married man, of temperate habits, a plumber by trade, and in fairly good circumstances. He had never had any previous illness of importance except a slight attack of acute rheumatism, and had enjoyed good health until January, 1878. In the latter half of that month he had cough and hæmoptysis, the attack lasting fourteen days. In the following April he became jaundiced and suffered from vomiting, at the same time the cough returned with sanguineous expectoration, and lasted to nearly the end of July. On August 15th there was a return of hæmoptysis, two ounces in quantity. The jaundice had now faded. The cough was very troublesome and painful, and expectoration difficult. The sanguineous nature of the expectoration continued, with occasional intermissions, up to the time of his admission, and, indeed, until his death. He complained of a dull, aching pain in the right chest, with occasional sharp pleuritic pains, and since October he had at infrequent intervals felt a sharp darting or plunging pain through the lung. He had lost considerably in flesh, and was weak and breathless on exertion.

The physical signs noted on December 5th were that he was a spare man of sallow complexion. Temperature normal. Chest well formed, the right side being, however, perceptibly larger than the left, and motionless during respiration. The heart's apex beat was situated a little to the left of the left nipple line. The right side was very dull on percussion below the nipple level in front, and posteriorly as high as the spine of the scapula, a slanting line in the axilla connecting these two levels. Over the dull regions the vocal fremitus and resonance were annulled and respiratory sounds absent. An occasional dry pleuritic rub could be heard, however, over the base, and the heart sounds were conducted. Above

the nipple level the percussion note was markedly hyper-resonant, having a deep-toned tympanitic quality, and this character extended upwards to the apex and to the middle line. In the supra-spinous fossa also the percussion was tympanitic in quality. The transition in front between absolute dulness and hyper-resonance was remarkably abrupt, and did not alter with the position of the patient. Over the hyper-resonant regions in front the respiratory sounds were coarse, exaggerated, and both vocal fremitus and resonance were increased. In the supra-spinous fossa respiration was somewhat bronchial.

The heart and other organs except the liver were apparently normal. The liver was enlarged, but its surface felt smooth. An examination of the sputa showed it to consist of mucus containing blood-discs and some groups of agglutinated cells resembling white blood-corpuscles; no elastic tissue were found.

There was at this time no difficulty in coming to a diagnosis that the man was suffering from malignant disease (lymphoma) of the mediastinum, invading the right lung, and occluding the lower division of the right bronchus. The possibility of fluid being also present was negatived by an exploratory puncture.

Six days later, on December 11th, a remarkable change had taken place in the physical signs. The dulness in front had extended a little upwards from the nipple level, and its limit was not so clearly defined; above there was still marked resonance, but less deep toned than before. The respiratory sounds, however, instead of being coarse and exaggerated, were extremely feeble, and vocal fremitus and resonance were both notably less than on the healthy side. There was otherwise no notable change in the patient's state, but it was obvious that the upper bronchus had become invaded by the growth.

On the 13th the temperature suddenly rose to 103°, the patient suffered from greatly increased dyspnœa, with severe pain in the chest, and died on the 14th.

*Post-mortem examination from notes by Dr. Coupland.*—The immediate cause of death was found to be recent pericarditis, set up by the invasion of the right and posterior part of the pericardial sac by new growth. The right pleural cavity was obliterated by universal adhesions of the costal and pulmonary pleura, the union being less firm over the upper than the lower lobe, the blended and thickened membranes in the latter region forming a fibrous investment nearly a

quarter of an inch in thickness. The lobes of the lung were firmly united. The posterior mediastinum on the right side was filled by a large lobulated mass of new growth, which occupied the bifurcation of the trachea, and projected backwards between the trachea and œsophagus in the form of a large, soft, oval tumour, exuding on section a quantity of pinkish creamy material. Several enlarged pigmented glands were clustered around and adherent to the structures at the root of the lung. A vertical section was then made of the lung from apex to base, from the surface to the root. The upper lobe presented a greyish-black surface, smooth and glistening from œdema, a quantity of serous fluid escaping from the cut surface. The main bronchus passing to this lobe was so much compressed (and invaded) by the mediastinal growth as hardly to admit of the passage of a bristle. The tertiary and smaller divisions of the bronchi in this lobe were obviously but uniformly dilated, and contained clear mucoid secretion.

The rest of the cut surface of the lung (middle and lower lobe) presented the appearance of an invasion of the growth from the mediastinum into the pulmonary substance. Thus the inner third or more of the lung was replaced by a tolerably firm, opaque, white mass, with a scalloped or crenated outline when it bordered on the less altered tissue, whilst here and there outlying knots of the same material occurred beyond the limits of the growth. The cut surface of the solid mass presented lines and patches of pigment, and also the cartilaginous framework of some of the bronchi, the calibre of which was occupied by the new growth. There remained a considerable portion of lung substance in the lower lobe less obviously invaded. This had a greyish, but smooth appearance, and towards the lower part was riddled by numerous cavities, some freely intercommunicating, and all full of greenish muco-pus. The cavities had no definite lining, their walls were ragged, and they could be traced to communicate directly with bronchial tubes, but were shut off from the trachea by the occlusion of the main bronchi. The "grey induration" of the periphery was subsequently found to be due to diffuse infiltration of the elements of the tumour in and among the alveoli. The bronchus passing to the lower lobe and its divisions were then examined by incisions made down the back of the lung. These passed through the centre of the cancerous growth, which completely invested them, and not only so, but infiltrated their walls, converting the lining membrane into a soft, white,

irregular surface. Tracing the tubes further down they were found to be dilated and their walls extensively ulcerated by the cancer growth, and most of them terminated in the abscess cavities above mentioned.

Left lung enlarged; quite free from growth.

Liver large, curiously misshapen, studded with small white nodules, and containing a large lobulated mass of growth.

Left kidney also contained a nodule of growth.

The trunk of the pneumogastric nerve on the right side was of full size and normal appearance down to the point where it entered, and rapidly became lost in the mass of the growth.

On microscopic examination the tumour was found to be of the usual lympho-sarcomatous nature presenting no characters of special interest. In the upper lobe the texture of the lung was somewhat thickened, and the capillaries enlarged. There was some pigmentation also present, and the alveoli were occupied by catarrhal cells. The lower lobe was infiltrated throughout with cancer. The dense tissues about the cavities being also the seat of fibroid induration with scattered deposits of pigment.

*Remarks.*—I have dwelt somewhat upon the clinical features of this case because they have a very direct bearing upon the view to be taken as to the nature of the relationship between the tumour present and the lung destruction secondary to it. Did the disorganisation of the lower lobe of the lung arise as a consequence of disturbed innervation from pressure of the growth, or did it arise from blocking of the lung by strangulation of the bronchus leading to it?

Although the first physical examination here recorded is dated December 5th, I may say that, since the preceding August, the patient had been under my observation and under that of my colleague, Dr. Symes Thompson, whose patient he originally was; and at that time the signs at the right base were negative—dulness and absence of respiration, with annulled fremitus, &c.—showing that that portion of the lung was thus shut off from the external air and the destructive changes proceeding within it obscured to us. The pneumogastric trunk up to the point where it entered the morbid growth and speedily became lost was fully of normal size, and appeared in a perfect state of nutrition. Again, in the upper lobe of the lung ten days before death respiration was vigorously proceeding, when six days later it was arrested, and the patient

dying after three days more, we find the corresponding bronchus strangled, its radicles already dilated with accumulating secretion and the lung somewhat œdematous[1] and thickened, but otherwise unaltered. My belief is that this upper lobe was beginning to undergo the same destructive changes as had gone on in the lower lobe; the changes being brought about in the first place by occlusion of the bronchus, then, as a consequence, accumulation of secretions in all the corresponding branches of the bronchus within the lung, and thus pressure backwards upon the lung texture, catarrhal accumulations within the alveoli, and secondary inflammatory consequences in the alveolar framework. All these changes proceeding silently—shut off from clinical observation—to their final result, viz. large bronchial cavities distended with muco-purulent secretion, the cavity walls consisting of compressed and indurated lung, and adjacent cavities at parts breaking into one another by secondary destructive softening of intervening lung tissue.

I believe this explanation, which is in accordance with that advocated by Dr. Irvine in his preceding paper, and in connection with some cases which he brought forward on a previous occasion, to be the true one in the great majority of cases. But in some cases, as I have ventured to remark elsewhere, "it is readily conceivable that partial destruction of the pulmonary nerves may, by lowering the vitality of the lung, render it more liable to the occurrence of inflammatory changes, and that complete destruction of these nerves at their origin might directly induce inflammatory destruction of the organ. In the main, however (if I may be permitted to continue the quotation), I should feel disposed to regard the mechanical obstruction at the main bronchus as being in most cases sufficient to account for such secondary lesions as we find. In some of the cases which I have quoted the secretion from the bronchial membranes went on with a vigour undiminished by any impairment of nervous influence, and the pneumonic changes present were apparently directly due to obstruction to the escape of this secretion. It is very possible that pressure upon the nerves may give rise to muscular paralysis of the bronchial tubes, as suggested by Dr. Bennett, without affecting their secreting power."[2]

[1] It is quite probable that this œdema may have been produced by the continued respiratory efforts, whilst the bronchus was so narrowed as no longer to permit the access of air, the result being a cupping-glass suction upon the lung, causing congestion and effusion of serous fluid into its tissue.

[2] Reynolds' 'System of Medicine,' vol. v, article "Mediastinal Tumours," p. 11.

There is, of course, still a third hypothesis possible to explain the destructive changes in the lower lobe, viz. that they might have been due to softening and breaking down of the lung tissue infiltrated with growth. There can be no doubt, however, that the growth commenced in the posterior mediastinum at the root of the lung, and that the peripheral portions in the lung were consequently the most recently affected. The fibrous toughening of the lower portion of the lung with the greatly thickened fibrous pleura clearly indicated a chronic inflammatory process; the elements of the growth found scattered more or less through this part of the lung being from secondary extension.

The hæmoptysis and sanguineous tinging of sputa probably arose from the fungating growth in the main bronchus.

*January* 21*st*, 1879.

---

## 8. *Specimens of bronchial gland disease.*

By Thomas Barlow, M.D.

No. 1 consists of the viscera of the neck and thorax of a female child, aged 3½ years, who had been under my care for double empyema. Under free drainage the right empyema had quite recovered, and the left, opened at a later date, had all but recovered, when the child took whooping-cough.

On what I believed to be the seventh day of this disease there was definite impairment of resonance in the first right interspace close to the sternum. Although there was no bronchial breathing I supposed at the time that this dulness was due to a patch of lobular pneumonia. Such was not the case. The child died on the morning of the ninth day from asthenia.

There was no disease of the apex of the right lung, and the dulness was undoubtedly due to some enlarged lymphatic glands behind and internal to the apex of the lung, which are obvious enough in the specimen. There is nothing more to be said of them except that they were about half as big again as the glands in this position generally are, that they were deep red in colour, not specially soft, that the right vagus nerve was stretched over them, but not obviously widened, reddened, or adherent to them.

The glands of the neck were rather swollen, and the other intrathoracic glands were swollen, especially the median gland situated at the bifurcation of the bronchi, but it will be seen that the group behind the apex of the right lung is most notably swollen of all.

The larynx and trachea were natural; the bronchi were somewhat injected.

The upper lobe of the right lung was healthy, the lower lobe still a little tough from slightly defective expansion subsequent to the right empyema; the organising lymph corresponding with the old pleural cavity was not more than $\frac{1}{16}$th of an inch thick. On the left side the empyema cavity was reduced to a small pyramidal space at the left base; the walls were nearly collapsed, there being no pus in the cavity. The lung was firmly adherent in the neighbourhood, and although the re-expansion elsewhere was inferior to that of the right side there was no actual carnification. On neither side was there any bronchial dilatation, and there was no accumulation anywhere of muco-pus in the bronchi.

No. 2 shows the thoracic viscera of a boy, aged seven months, who had been under the joint care of Dr. David Lees and myself, at the Hospital for Sick Children, Great Ormond Street. Many of the intrathoracic glands contained small caseous spots, as, indeed, did most of the glands of the body, but the only intrathoracic gland notably enlarged belongs to the group behind the apex of the right lung. It is about three quarters the size of a Spanish chestnut, and is caseous throughout. To its capsule the right vagus is very firmly and extensively adherent as it passes down to the posterior pulmonic plexus. There are a few sparingly disseminated tubercular nodules in both lungs, and in the right upper lobe there is a mass of caseous pneumonia, part of which has undergone rapid softening, forming a cavity into which some caseous material loosely projects. There were miliary granulations in liver, kidneys, and spleen, and the spleen was enlarged.

This child's troubles dated chiefly from the time of his having measles, about one month before he was brought to the hospital, and forty-five days before his death.

The only point to which I will refer are the symptoms, which perhaps had relation to bronchial gland conditions. He had some dulness to the right of the manubrium, and a frequent, short, dry, slightly clangy cough. But there was nothing like a whoop, nor was the cough specially paroxysmal, and it was not followed by

vomiting. The cry was pretty good, and there was no stridor about the respiration.

*Remarks.*—It may be held that the enlargement of the glands in No. 1 had to do with the empyema. So far as I have observed, *post mortem*, enlargement of the bronchial glands does not occur in empyema.[1] Further, the objection to such a view in this case is that the right empyema had recovered, and that this enlargement (although not correctly interpreted) was manifested by signs during life only after the onset of the whooping-cough. I think probably the enlargement depended on the whooping-cough, but it is the only example of marked bronchial gland enlargement which I have seen *post mortem* in that disease. Twice I have seen slight enlargement. I suspect that the bronchial glands do not suffer so often or so much in whooping-cough as in measles, although frequently I have seen during life the slight *cervical* gland enlargement in hooping-cough to which Dr. Hugh Ley long ago referred.

With respect, however, to Dr. Noel Gueneau de Mussy's view that pressure of the enlarged bronchial glands on the vagus induces the characteristic whoop, I wish to point out that although the child from whom specimen No. 1 was taken had undoubtedly hooping-cough, with paroxysms followed by vomiting, yet she had no whoop, albeit the glandular enlargement was considerably greater than ordinarily attains in the disease.

In No. 2, as I have pointed out, in spite of the adhesion of the right vagus to the capsule of a greatly enlarged bronchial gland, there was not only no whoop, but the cough was not even paroxysmal.

Sir William Gull[2] has described destructive lung disease depending, as he believes, on compression of the vagus and pulmonary plexus.

In specimen No. 2 there was marked compression of one vagus, but no such disease of lung obtained as described by Sir William Gull. The single cavity present was due to rapid breaking down of caseous pneumonia. Dr. Irvine has brought specimens of lungs to this Society having characters corresponding very much with Sir William Gull's description, but taken from cases of thoracic aneu-

[1] I have, however, lately made a post-mortem on a case of empyema of two years' duration, dating from scarlet fever, and in which enlargement of bronchial glands with caseation occurred (Sept., 1879).

[2] 'Guy's Hospital Reports' for 1859.

rysm, and he has given reasons for believing that the lung changes depended on compression of bronchus and ulceration rather than from pressure on vagus. I have observed one case of destructive lung disease resembling in character the condition described by Sir William Gull, where there was no evidence of compression of the vagus, but where the disease seemed to be due to the ulceration and gravitation of morbid products consequent on the impaction of a foreign body in the bronchus.

Specimen No. 3 consists of the thoracic viscera of a boy, aged nine months, who was an out-patient of mine at Great Ormond Street.

Tubercle in all forms will be seen in the lungs, and caseation and enlargement of several intrathoracic glands, but the special point to be noted is that the gland situated in the bifurcation of the bronchi is enlarged and partly caseous. The upper part has also undergone destructive changes at separate centres, giving rise to some small closed cavities, one of which approaches the capsule of the gland. That wall of the right bronchus is adherent to this gland and is distinctly thinned.

The bronchial mucous membrane in this neighbourhood shows some miliary tubercles and some small ulcers, probably tubercular.

In the phthisis of infants there are many points connected with the rôle of the bronchial glands which deserve study other than the *quæstio vexata* of the dissemination of miliary tubercles from them by infection. It is an old observation that one of the causes of vomicæ in the lungs of children is the softening and ulceration into the lung of some of the glands partly embedded in the lung tissue near the root. But the gland or glands situated in the bifurcation of the bronchi when they caseate and ulcerate into a bronchus are sometimes of great importance. It has been shown by Dr. Gee[1] that such disease may give rise, in the lung to which the ulcerated bronchus goes, to a pneumonia, sometimes gangrenous. I have seen two cases where this occurred, and where, also, purulent pericarditis ensued.

In this specimen actual perforation had not occurred, though it probably would have done if the child had lived a little longer. The specimen is brought to show how the process of ulceration in such cases may proceed from both sides simultaneously.

*January* 21*st*, 1879.

[1] 'St. Bartholomew's Hospital Reports,' vol. xiii.

# III. DISEASES, ETC., OF THE ORGANS OF CIRCULATION.

## 1. *Case of stenosis of the pulmonary artery from disease of the valves, probably of congenital origin.*

By T. B. Peacock, M.D., F.R.C.P.

G. D. T—, a boy, æt. 13, residing in Wandsworth Road, was admitted into Charity Ward, St. Thomas's Hospital, under the care of Dr. Peacock, on July 20th, 1876.

No satisfactory history of his previous state of health could be obtained, but he could not be ascertained to have ever had rheumatism or any other illness, likely to lay the foundations of cardiac disease. He was reported never to have been strong and to have always been livid in the face in cold weather. He was, however, in his usual state of health until four months before his admission into the hospital.

When admitted his face was flushed and his lips purple. He had much difficulty of breathing, and the face and extremities were puffy, and the abdomen tumid. The urine had a specific gravity of 1025 and was not albuminous. On examination a loud double murmur was heard at the base of the heart, at the upper part of the sternum, and on each side of that bone, but it was most distinct in the course of the pulmonary artery, where also a very marked thrill was felt. The jugulars were distended, and there was very obvious pulsation in the carotids.

The dropsical symptoms became more marked after his admission into the hospital, and on the 19th of September the abdomen measured 27½ inches in circumference at the umbilicus, and above that line 30 inches. The abdomen increased in size. He was therefore tapped two days after, and about 8½ pints of yellow-coloured fluid was removed. The abdomen, however, rapidly refilled, and on October 27th the circumference at the umbilicus was 30 inches, and above that point 31 inches. In addition to the systolic sound before

noticed, there was a diastolic whiff heard over the orifice, and in the course of the pulmonary artery a double murmur was audible towards the apex, and a systolic sound in the left dorsal region. The thrill was very distinctly felt over a large space, but was most marked in the second and third left inter-cartilaginous spaces. The abdomen continued to enlarge, and on November 29th measured 31 inches at the umbilicus, and 33¾ inches above. He was again tapped, and 13½ pints of fluid were removed. On the following day he complained of pain in the abdomen, and soon after he began to sink, and died in a few hours.

On *post-mortem* examination the peritoneal cavity contained a pint and a half of fluid. The surface was generally opaque and irregularly thickened with a thin layer of recent lymph, and the serous coat of the intestines was somewhat injected.

The capsule of the liver was opaque, and covered with rather dense fibrous layers, and very firm and tough. The hepatic veins were distended, and the surface of the liver mottled. The spleen was much enlarged, and the capsule irregularly thickened and its substance tough and deeply congested. The kidneys were of their natural size, their capsules not adherent, their substance tough and congested.

The pericardium contained eight ounces of clear fluid. The heart weighed about nine ounces avoirdupois. The anterior surface was almost entirely composed of the right ventricle. The right ventricle was very much dilated, and its walls greatly hypertrophied and excessively firm and resistent. The right auriculo-ventricular aperture was of large capacity. The pulmonary orifice very much constricted from disease of the valves. The three curtains were blended together so as to form a kind of diaphragm extended across the orifice, and protruded forwards in the course of the vessel, and perforated in the centre by a small rounded aperture, admitting only a ball 10 Paris lines in circumference = to 22·5 mm., or 0·88 English inches. There were three frena or cross bars, on the upper or arterial surface of this diaphragm, indicating the former lines of separation of the segments, or the lines of incomplete division. The imperfect curtains had deep sinuses behind them, and were much thickened. The trunk of the pulmonary artery was of somewhat large size, and its coats were thick. The left side of the heart was free from disease, except that the valves were somewhat thickened.

The heart was otherwise well formed, the fœtal passages being

completely impervious. The following are the weight and dimensions of the heart:

Weight about 9 oz.

Transverse diameter, 42 Paris lines, = 94·5 mm., or 3·73 English inches.

WOODCUT 3.

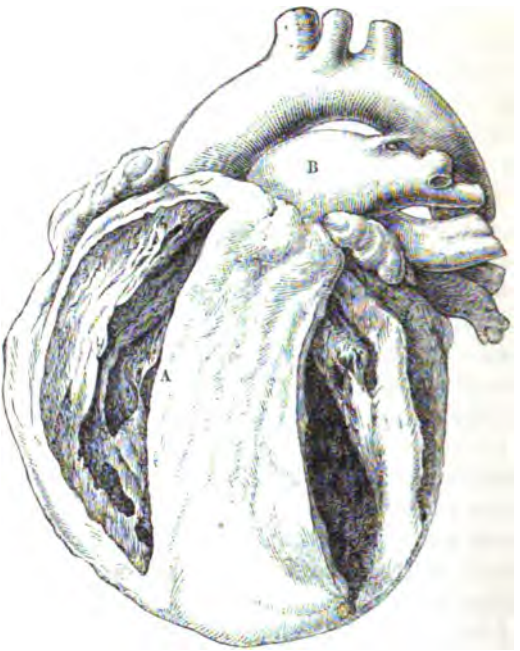

A. The right ventricle, showing the enlargement of the cavity and the thickening of the walls.

B. The trunk of the pulmonary artery.

C. The orifice of the pulmonary artery seen from below, showing the diaphragm formed by the united valves and the constricted aperture in its centre.

Vertical diameter, 44 Paris lines, = 99 mm., or 3·84 English inches.

Thickness of the walls of the right ventricle:

At the base, 3 Paris lines, = 6·75 mm., or 0·266 English inches.

At midpoint, 2·75 Paris lines, = 5·17 mm., or 0·23 English inches.

At apex, 2 Paris lines, = 4·5 mm., or 0·177 English inches.

Walls of left ventricle:

Base, 3·5 Paris lines, = 7·87 mm., or 0·31 English inches.

The right auriculo-ventricular aperture admitted a ball measuring in circumference 42 Paris lines, =94·5 mm., or 3·71 English inches.

Pulmonic orifice, 10 Paris lines, = 22·5 mm., or 1·88 English inches.

Left auriculo-ventricular aperture, 28 Paris lines, = 47·25 mm., 1·86 English inches.

Aortic aperture, 24 Paris lines, = 54· mm., or 2·13 English inches.

*Remarks.*—Cases like that just related, in which, with extreme disease of the valves of the pulmonary artery, the heart is otherwise well formed, are of very rare occurrence. I have only, myself, met with this and one other instance, during many years service at the Royal Free, St. Thomas's, and the Victoria Park Hospitals, and I was only able, in 1866, to refer to six or seven similar cases.[1] More recently, however, MM. Constantin Paul[2] and Raymond Solmon,[3] in special memoirs, have each published an original case, and referred to some others not previously mentioned by myself. Cases, however, in which extreme obstruction in the neighbourhood of the orifice of the pulmonary artery, coexists with deviations from the natural conformation of the heart, such as defects in the intraventricular septum, or the imperfect closure of the foramen ovale are by no means uncommon. I have myself published several cases of the kind, and referred to many other similar instances;[4] and Stölker,[5] in an inaugural dissertation presented to the Medical Faculty of Bern, has collected together abstracts of 116 such cases published in various countries, with one case under his own observation.

In cases of the latter kind it can scarcely be disputed that the disease of the valves of the pulmonary artery has been of congenital origin, but when there is no coincident defect in the conformation of the heart it may be doubted whether the valvular or other disease has not been acquired in after life. MM. Paul and Solmon suppose

[1] 'Malformations of the Human Heart,' 1866, 2nd edition, p. 121.

[2] 'Mémoires de la Société Médicale des Hôpitaux de Paris,' Année 1871, "Du Rétrécissement de l'Artère Pulmonaire Contracté après la Naissance," par le Docteur Constantin Paul, p. 45.

[3] 'These pour le Doctorat en Médecine,' Paris, 1872, "Du Rétrécissement Pulmonaire acquis," par Raymond Solmon.

[4] 'Malformations,' pp. 45, 50, 51, 53, 57, 60, and 75.

[5] 'Ueber Angeborne Stenose der Arteria Pulmonalis,' Bern, 1864.

such to have been the case in the instances they have related, and the same view is taken by Claude Bernard of a case which he has recorded. From, however, the precise similarity of the disease of the valves or adjacent parts of the pulmonary artery in both sets of cases I cannot but suppose the disease to have a similar origin in both. It must, however, be concluded, that, where the fœtal passages are found completely occluded, the degree of obstruction at the pulmonic orifice must, at the time of birth, have been only slight.

MM. Paul and Solmon draw attention to disease of the lungs as existing in several of their cases, and regard the obstruction at the pulmonary orifice as the cause of the latter. In the case now related the lungs were free from disease, but the subject of my previous case died of phthisis.[1]

A specimen somewhat similar to this was exhibited at the Society at a subsequent meeting, and in that instance the patient was, I believe, also phthisical. On that occasion attention was drawn to the large size of the trunk of the pulmonary artery notwithstanding the extreme constriction of the orifice. This I find generally to be the case where the septum of the ventricles is entire, whereas in the cases in which with obstruction at or near the orifice of the pulmonary artery there is an aperture in the septum of the ventricles, the trunk of the pulmonary artery is generally small and its coats very thin. *October 15th*, 1878.

---

2. *Malformation of the heart; stenosis of the pulmonary valve, with dilatation of the pulmonary artery and hypertrophy of the right ventricle; patency of the foramen ovale, with a cribriform opening in the septum of the auricles* (*ductus arteriosus closed*).

By David W. Finlay, M.D.

Grace C—, æt. 23, by occupation a nursemaid, was admitted into the Royal Hospital for Diseases of the Chest on 27th Sep-

[1] 'Pathological Transactions,' vol. x, 1858-9, p. 107; 'Malformations,' p. 122.

tember, 1877. She was a stunted, ill-developed looking girl, weighing only 5 stone 10 lbs., her height being 4 feet 7 in. Her father is living, but is reported to suffer from asthma. She has a sister and two brothers, one of whom also suffers from asthma. Her mother is dead, cause unknown. Patient had always been subject to shortness of breath and cough, and had been laid up two years before admission with "some fever." Six days ago, while at work, she brought up with coughing a considerable quantity of blood, and she continued to spit blood more or less up to the time of her admission. The catamenia had not been present for four months.

On admission her face and lips were cyanosed; her pupils small and equal; pulse 76, regular, but small and compressible; resp. 84; temp. 98°; fingers and toes markedly clubbed and the nails blue. The form and movements in respiration of her chest were fairly normal, but there was some crepitation over the apices of both lungs anteriorly, and over the right apex and left base posteriorly, with very slight impairment of resonance on percussion. The heart's maximum impulse was felt in the fifth interspace, an inch below and half an inch internal to the nipple; the præcordial dulness was slightly increased upwards. A loud, harsh, systolic murmur was heard over the whole of the præcordia, being most intense over the second left interspace close to the sternum. It could be traced very distinctly to the left clavicle, and was audible, also, over the left scapular region. The murmur was accompanied by a somewhat diffused thrill felt over the base of the heart. The urine was clear, having a sp. gr. of 1020, and free from albumen.

On October the 2nd she had a slight recurrence of the hæmoptysis, and on the 6th it was noted that a systolic murmur could be heard over the right base of the heart, of a lower pitch and softer character than the one before described, which was also audible in the carotids.

She remained in the hospital until the 23rd of October, when she was discharged with her general condition much improved, but without marked change in any of the physical signs of either heart or lungs.

She continued to attend the hospital as an out-patient until 15th January of this year, when she was again admitted to the ward in an almost moribund condition, complaining of weakness, difficulty of breathing, distressing cough, and pain and oppression about the region of the heart. Her pulse was 120, occasionally inter-

mittent; resp. 84, of a sighing character. She was somewhat emaciated, her face and hands livid, and her feet œdematous. Moist sounds could be heard everywhere over both lungs, most marked, however, at the right apex and base, with blowing breathing, prolonged expiration, and impaired resonance. The heart's impulse was heaving, and the præcordial dulness increased in all directions. In other respects the physical signs were much the same as already described.

She died on January 17th, two days after admission.

The *post-mortem* examination took place twenty hours after death, and was performed by Dr. Gabbett, the acting house physician.

The body was somewhat emaciated, and there was slight œdema of the feet.

The pericardium was healthy, and contained three drachms of clear serum.

The heart was considerably enlarged, the increase being mainly in the right auricle and left ventricle, the former being much distended, and the latter forming nearly one half of the anterior aspect of the heart as it lay *in sitû*. The right auricle contained a quantity of fluid blood and clots. The cavity of the auricle was of great size, and its wall much hypertrophied. The fossa ovalis measured an inch in diameter, and at its anterior part was situated the patent foramen ovale, a valvular opening measuring half an inch in length, while the septum at its posterior part was perforated in a cribriform manner over an area measuring half an inch vertically by three eighths of an inch laterally. The right auriculo-ventricular orifice was small, permitting the passage of one finger only, and on one of the segments of the tricuspid valve, which in other respects seemed healthy, there were two small warty vegetations of the size of pins' heads. The cavity of the right ventricle was small and its wall greatly hypertrophied, measuring three eighths of an inch at the base; the infundibular portion of the ventricle was relatively large. The segments of the pulmonary valve were distinct, but coherent, leaving between them an opening of somewhat triangular shape, which measured a quarter of an inch in diameter (see Plate XVI B.) The anterior segment was less than half the size of either of the others, behind both of which there were pouches of considerable size. The trunk of the pulmonary artery was greatly dilated, measuring four inches in circumference, half an inch beyond the valve. The ductus arteriosus was closed.

## DESCRIPTION OF PLATE XVI B.

**This Plate illustrates the Cases of Dr. Crocker, Dr. Finlay, and Dr. Peacock, of Congenital Heart Disease.**

FIG. 1 illustrates Dr. Crocker's case of congenital malformation of the heart. (Page 273.)

The valves of the pulmonary artery are seen to be adherent, forming a cone, at the apex of which an aperture the size of a crow-quill leads into the pulmonary artery.

FIG. 2 illustrates Dr. Finlay's case of malformation of the heart. (Page 262.)

A. Opening of the pulmonary valve (probe passing through it from the right ventricle.

B. Dilated pulmonary artery laid open.

FIG. 3 illustrates Dr. Peacock's case of congenital disease of the aortic valves. (Page 277.)

The right and left segments are blended together, and the united segment so formed is partially adherent to the posterior valve, so that the whole three segments are united. A frænum extending upwards from the united right and left valve shows the seat of union of the two valves.

Fig. 1.

Fig. 2.

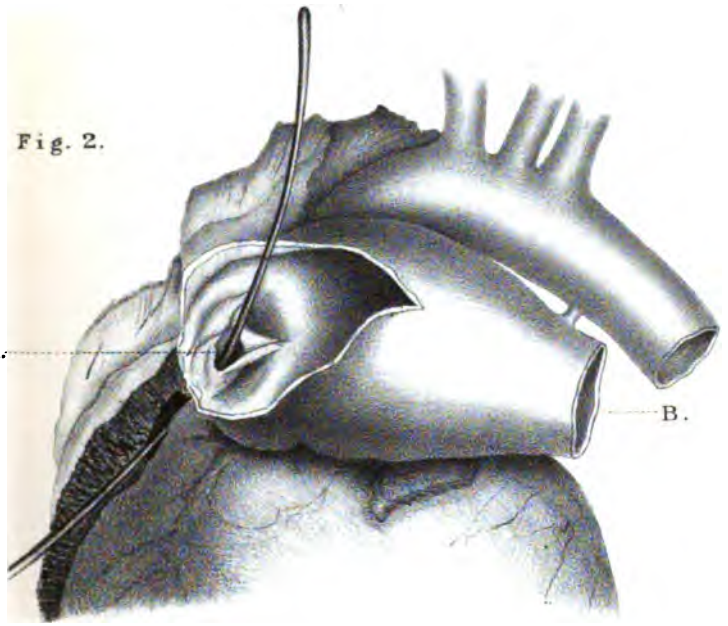


Fig. 3.

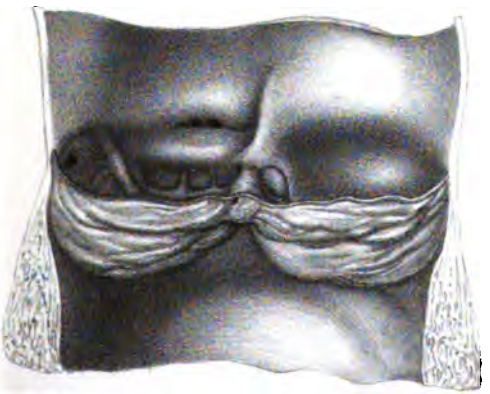

R. Mintern lith.

Mintern Bros.

The left auricle was large, but its wall not hypertrophied. The left auriculo-ventricular orifice was also large and the mitral valve incompetent, the margins of its segments being rough and, together with the chordæ tendineæ, opaque and much thickened. The cavity of the left ventricle was large, containing a little fluid blood and many clots; its wall measured half an inch in thickness at the base and a quarter of an inch at the apex. The aortic valve seemed normal, measuring two inches and a quarter, but the root of the vessel presented some patches of atheromatous degeneration. Beyond the point of origin of the great vessels the aorta was somewhat suddenly narrowed, its circumference scarcely exceeding an inch and one eighth, whereas the ascending portion measured two inches and a half. The heart, with the trunk of the pulmonary artery and arch of aorta, weighed 9¾ oz.

The right lung was universally adherent to the chest-wall, most firmly at the apex, where there was a vomica the size of a hen's egg. The greater part of the lung was buoyant, and crepitated on pressure, but there were patches of consolidation scattered through it, which, on section, presented the appearance of disseminated masses of tubercle. There were a few small cavities in the lower lobe, which was extremely congested and œdematous.

The left lung was also adherent, although not so firmly. A cavity the size of a large marble existed at the apex, and there was congestion and œdema of the whole lower lobe. There were masses of caseous glands in the posterior mediastinum.

The liver was large, engorged with blood, and partially adherent to the diaphragm, presenting, on section, the nutmeg appearance.

The spleen was small.

The right kidney was large and rather irregular in shape, presenting a rounded prominence on its anterior superior aspect. The left was small. Both were congested, but their structure appeared normal on section.

The chief points of interest in this case seem to be the presence of the cribriform opening in the septum of the auricles coexisting with an open foramen ovale, and the extreme dilatation of the trunk of the pulmonary artery, which, in cases otherwise similar, is generally found smaller than natural.

*March 4th*, 1879.

### 3. *Defect in the ventricular septum of the heart, probably congenital; unusual site of aperture.*

By Sidney Coupland, M.D.

This heart, which exhibits a very rare variety of malformation, was obtained from the body of a man, about 40 years of age, who was brought to the Middlesex Hospital, on October 9th, 1878, dead from an attack of hæmoptysis.

The organ is somewhat hypertrophied, both ventricles being enlarged and their walls unduly thickened. The valves are free from disease, with the exception of one of the aortic cusps, which was thickened, as below described. On laying open the conus arteriosus the upper part of the ventricular septum is seen to be perforated by an oval or rather crescentic aperture. The aperture is of sufficient size to admit of the passage of a No. 12 catheter (it measured four lines by one and a half line in diameter), and is seated on the posterior wall of the conus, immediately below and to the right of the posterior segment of the pulmonary valve. It will be seen (see Woodcut 4, fig. 2) that this cusp is thus left unsupported below for about one third of its length, and that it is more opaque and more fibrous than its fellows. The margins of the orifice are smooth and fibrous, the anterior being rounded and concave, the posterior somewhat bevelled off, the anterior cusp of the aortic valve projecting into it on this side. The endocardium on the opposite wall of the conus, *i. e.* the anterior wall, about a quarter of an inch from the septum, is the seat of a limited, smooth, opaque, white, fibrous patch (fig. 2 *b*), the size of a sixpenny-piece. Viewed from the left ventricle, the aperture has the following relations:—Its shape is more oblong than it appears on the right side, and it occupies the fleshy part of the septum about a quarter inch from its union with the anterior wall of the ventricle. Its lower margin is concave upwards, is smooth and bevelled off. It is formed by tough fibrous tissue, continuous with an irregularly-shaped patch of similar thickening, extending for about half an inch over the muscular septum. The upper margin is formed by the bulging segment of the anterior—sometimes called *right*, as above it issues the right coronary artery—aortic cusp, the outer half of which was wholly unsupported. It is this cusp which can be seen on the right side bulging into the

posterior portion of the orifice. This unsupported half of the segment is greatly thickened compared to its other half, but the cusp is perfectly entire. The orifice is thus placed between the anterior or "right," and the left posterior or "left" valve-cusp, but is in closer contiguity to the former than the latter. The only other morbid change lies in the presence of a slightly raised and small patch of fibrous thickening on the ventricular surface of the anterior mitral cusp (fig. 1 *c*). This patch is seated a little above the centre of the cusp, at a point, indeed, which in the closed ventricle must have been

WOODCUT 4.

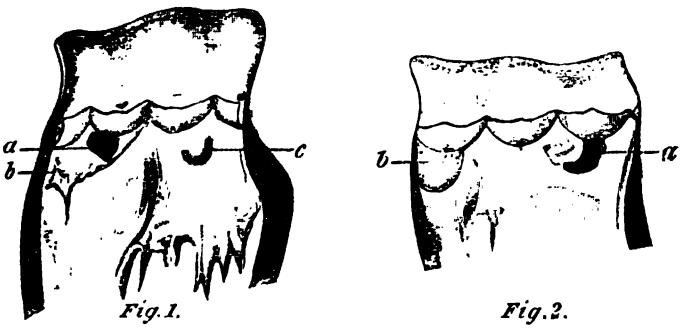


Fig. 1 represents aorta and left ventricle laid open. *a*. Aperture in septum (anterior part) bounded above by the right aortic valve. *b*. Patch of fibrous thickening of endocardium bounding the aperture. *c*. Thickened patch on surface of anterior mitral cusp. The left aortic cusp has been divided in laying open the vessel.

Fig. 2 represents pulmonary artery and infundibulum laid open. *a*. Shows situation of aperture, with the aortic cusp projecting into it on its posterior border. *b*. Patch of fibrous thickening on wall of conus opposite to the aperture.

exactly opposed to the orifice in the septum. There is no further malformation of the heart; the foramen ovale is closed, but the fossa ovalis is unusually large, occupying nearly the whole of the auricular septum. The pulmonary artery and aorta are of normal size, and the ductus arteriosus is completely obliterated. Both lungs were advanced in phthisical changes, extensively excavated, one large-chambered cavity in the right upper lobe being traversed by branches of the pulmonary artery, which exhibited numerous aneurysmal dilatations in their course. The actual source of the hæmorrhage was not discovered, but blood filled this cavity, and also completely blocked the bronchi on both sides.

There are but few points that require comment respecting this specimen. It speaks for itself. I need hardly remind the Society that the usual seat for congenital deficiency in the septum of the ventricles is the membranous summit of the septum—the part known as the "undefended space." It is the last part of the septum to be developed, and, owing to its wholly fibrous or membranous character, it is the weakest part of the septum, and consequently the most frequent starting-point for aneurysms in this situation. But that congenital defects do occur in other parts of the septum through the muscular part, and in front of the membranes, is acknowledged by Dr. Peacock in the following passage of his work on 'Malformations of the Heart' (2nd edit., p. 28):—"While, however, deficiencies in the septum cordis are most commonly situated at the base, they are not confined to that situation. Occasionally, though, so far as my observation serves me, very rarely, the division between the left ventricle and the infundibular portion of the right is perforated, so as to form a connection between the left ventricle and the origin of the pulmonary artery." And he refers, in a foot-note, to two specimens illustrating this condition in the Museum of St. Thomas's Hospital. I have not had the opportunity of seeing whether other of our metropolitan museum collections contain parallel specimens. None have been exhibited to this Society since its foundation.

I believe the defect in the present case to be congenital, although the lack of any previous history of the case, and the absence of any other congenital defect, except the remarkable size of the fossa ovalis in the right auricle, deprive me of any further support to this mere opinion.

The chronic endocardial thickening around the orifice, and the thickening of the portions of the aortic and pulmonary valves left unprotected, are obviously related to the length of time during which blood must have flowed through this channel, and by no means point to a primary inflammatory condition as the starting-point of the perforation. As to the direction taken by the current or eddy of blood which at every ventricular contraction must have passed through the orifice and have occurred in its vicinity, I should say that for a long time it must have passed from right to left. The remarkable limited tendinous patch of thickened endocardium on the opposite wall of the conus was, I believe, produced by the impact of this cross-current of blood. But as life advanced, and the pulmonary circulation became increasingly difficult, owing to the

lung disease, may not the direction of this stream have been modified, or even reversed? I cannot help thinking that the fibrous patch on the mitral cusp testifies to such a change in the direction of the stream. *November 5th*, 1878.

P.S.—Since the above specimen was shown to the Society I have been confirmed in my surmise as to the rarity of the condition it exhibited, by finding the late Professor Rokitansky, in the monograph[1] which he published towards the close of his long career, recording only two similar cases which came under his personal cognisance. This work embraces the most complete exposition of malformations involving the septa and walls of the heart which has yet been published, and seeks to explain the occurrence of many a rare anomaly by reference to perverted developmental changes, of which a complete account is given. It may be interesting if I present here a brief summary of that part of the subject which is illustrated in my specimen. Dividing the ventricular septum into an anterior and posterior half, the membranous part (or undefended spot, as it is termed) being the point of division, the defects, such as in my case, are seated in the foremost part of the anterior septum, placed, that is, below and in front of the right aortic valve, and perforating the conus arteriosus just below the mouth of the pulmonary artery. Rokitansky, as I have said, relates two examples of this anomaly which have come under his notice. The first (Case 19, p. 24) is illustrated by a drawing. It closely resembles the specimen I brought before the Society. It was the heart of a youth, seventeen years of age, who died from some febrile disorder a day or two after admission into hospital, and presented numerous minute abscesses on the cardiac wall, in addition to the following changes of old date:—The apex of the organ was bifid, the left ventricle dilated, the aorta slightly displaced to the right, and the posterior wall of the conus arteriosus on the right side was larger and more curved than normal. Owing to the misplaced position of the aorta, its posterior valve was displaced rightwards, and below it was the small *pars membranacea*. The pulmonary valves were also so displaced that the anterior appeared on the inner side, the left anterior, and the right posterior. A rounded orifice occurred in the most anterior part of the anterior septum. On the left side it lay beneath the right aortic valve, 10 mm. in front of the membranous septum. It

[1] 'Die Defecte der Scheidewände des Herzens,' Wien, 1875.

was 9 mm. in diameter, and was bounded below and on the right by a tough ring of thickened endocardium, concealing the fleshy margin on the right side; it appeared in the conus, 13 mm. in front of the *pars membranacea*, as a small aperture 6 mm. in diameter, just below the right pulmonary valve, its bevelled margin being formed by tough fibrous tissue, except above, where the right aortic valve was visible from this side. The endocardium of the conus was thickened in a white tendinous manner from the margin on to the anterior wall of the conus. The portion of the right aortic valve projecting into the aperture was thickened. The pulmonary valves were slightly fenestrated; the aorta and pulmonary artery were of normal calibre; the foramen ovale persisted as a small aperture the size of a hemp-seed, and the ductus arteriosus was closed. It will be seen how very closely this case corresponds, even in details, with my own.

The other specimen described by Rokitansky (Case 20, p. 25) was met with in the body of a male child three years of age, who died from pericarditis and chronic pneumonia. The heart was generally enlarged; tendinous patches and villous processes of connective tissue adhered to the outer surface of the ventricles. In this case also the aorta was displaced rightwards, immediately behind the pulmonary artery, and the posterior wall of the conus arteriosus was elongated and bulging. There was consequently a similar change in the relative situations of the aortic and pulmonary valves, the posterior aortic cusp having a position more to the right than normal, the anterior pulmonary cusp more internal, the left more anterior, and the right more posterior than normal. The perforation in the foremost part of the anterior septum appeared on the left side about 6 mm. in front of the small *pars membranacea*, and beneath the right aortic valve. On the right it appeared in the conus, 10 mm. from the mouth of the pulmonary artery between the right and left valves, as a hole barely 4 mm. in diameter. It was bounded by a tendinous margin, prolonged on the left side as a small process of thickened endocardium, whilst above was the base of the right aortic valve. There was some gelatinous swelling of the free margins of the pulmonary valve and of the anterior mitral cusp. The pulmonary artery and aorta were stenosed; the fosa ovalis was of very large size, and presented an aperture in front and above the size of a millet-seed; the ductus arteriosus was closed.

In commenting on this anomaly later on (l. c., p. 125) Rokitansky says that at first sight the considerable endocardial thickening at the

margins and in the vicinity of these apertures might be urged as evidence that the loss of substance was an acquired condition. He had seen two cases where the ventricle was perforated from myocarditis.[1] On the other hand, the close similarity of the two cases described, and the fact of the defect being capable of explanation on developmental grounds, renders the view as to their origin in acquired states somewhat dubious. He points out that in both cases the right aortic valve formed the upper margin of the orifice, which appeared in the conus, in the one case beneath the right and in the other between the right and left pulmonary valves, involving the fleshy part of the septum in both cases. The slight malposition of the aorta, the seat of the membranous septum beneath the posterior aortic valves, the change in form and direction of the conus and the pulmonary artery, are also points of agreement in both cases; points too of congenital abnormality, which in the first case was also seen in the bifid character of the heart's apex. He further points out that were it not for the primary displacement of the aorta the aperture should traverse the pulmonary artery, and not the infundibulum, and he seeks an explanation for the defect in a failure of complete union between the arterial septum and the ventricular septum, a junction which takes place before the completion of the posterior part of the anterior septum. The endocardial thickening of the margins and of the apertures are due to subsequent inflammatory changes. Lastly, as to the course taken by the blood-stream, the distinguished author believes that in his first case the flow must have been from the left ventricle into the right; but that in the second case the enlargement of the right side due to the pulmonary disease may have caused a flow through the orifice in the reverse direction.

[1] As shown by Pelvet and others, so-called septal aneurysms probably sometimes arise from degeneration of the fleshy part of the septum. A remarkable instance came under my own notice at the Middlesex Hospital in 1876, and has been published by Dr. Henry Thompson in a clinical lecture in the 'Medical Times and Gazette.' But, as Thurnam showed, and as our 'Transactions' amply illustrate, aneurysms in this region generally start at the membranous or undefended part of the septum, which is also the favourite seat for congenital defect.

### 4. *Congenital heart disease; pulmonary stenosis, with dilated pulmonary artery above the stenosis.*

By Thomas Barlow, M.D.

This heart was taken from a female child, æt. 4, who was a patient of mine at the Hospital for Sick Children, Great Ormond Street.

The venæ cavæ are natural. The right auricle is hypertrophied and dilated. The foramen ovale is patent; it will admit an ordinary goose-quill; one edge is round, the other sharp. The curtain of the tricuspid valve is opaque and a little thick. There are no vegetations.

The great size of the heart is chiefly due to the hypertrophied right ventricle, which measures vertically three inches, and the greatest thickness of whose wall is three quarters of an inch, the thickness even of the wall of the conus arteriosus being a quarter of an inch. The septum of the ventricles is intact.

The three pulmonary artery valves are united into a funnel-shaped dome, with a small slit at the top and three fræna at the base. Above this the pulmonary artery is dilated.

The left auricle is much smaller and thinner than the right.

The mitral orifice is natural.

The greatest thickness of the wall of the left ventricle is a quarter of an inch.

The aortic valves are natural.

The great vessels are given off normally from the aorta.

The ductus arteriosus is closed.

With respect to the other viscera, the epiglottis was congested in front and behind, and the larynx was congested also. No false membrane was present. The trachea and bronchi showed extensive punctiform and ramiform injection. There was very little mucus.

The lung tissue was healthy. One bronchial gland was a little swollen—the one at the bifurcation of the bronchi.

The liver was hard and slightly nutmeg in character.

The spleen was hard, but not enlarged.

Kidneys also felt tough, but showed no special naked-eye change.

The history was that the child had always been very short-breathed. When brought to me her finger-ends were slightly bulbous, and she was rather blue. She had a prominent sternum,

cardiac dulness extending to one finger's breadth to the right of the sternum, the upper limit in the third left space, and the impulse felt as low as the sixth space. She had a loud systolic murmur heard all over the cardiac region, but best over the sternum, opposite the third ribs, and over the second left space. There was no thrill anywhere to be felt. The liver was enlarged (three fingers' breadth below the margin). Nothing abnormal was heard over the lungs. Her eyes were watery, and with a temperature of 101° it was suspected she was evolving some acute specific disease.

Next day she had some large blue spots on the trunk. Her pharynx showed purplish-red congestion. She was almost aphonic, but she had no special dyspnœa, and her cough was not definitely clangy.

Dr. Squire's specimen, shown to this Society,[1] of the larynx and trachea of a dog who had contracted measles, helped me to picture this child's condition of respiratory passages, and to the diagnosis of the cause of her fever, and next day measles was confirmed by the character of the rash and the coryza, and within a fortnight by some other children manifesting the disease.

She died in thirteen days, apparently from asthenia rather than asphyxia. Probably but for the measles the child might have lived for years. It is remarkable how free her lungs were from disease.

Amongst cases of congenital heart disease this is noteworthy, because with stenosis of the pulmonary valves of the usual dome shape there was completion of the septum of the ventricle and dilatation of the pulmonary artery above the stenosis.

*March 4th*, 1879.

---

## 5. *Case of congenital malformation of the heart.*

By H. Radcliffe Crocker, M.D.

Minnie B—, æt. 6, admitted June 29th, 1878, under Dr. Donkin. Died October 3rd. Born at full time. Cyanosed at birth. For first few months had severe fits of convulsions.

*Physical signs.*—No evidence of displacement or enlargement of

[1] 'Path. Trans.' vol. xxvii.

the heart. Throughout stay in hospital there was constantly heard reduplication of first sound over ventricles, the first half being the louder. There was also noticed a faint blowing systolic murmur over the right base of the heart, sometimes distinct and sometimes not heard at all. (By a medical man who had the patient under observation for some time before admission to hospital it was said that there used to be heard a very loud and harsh systolic murmur all over præcordial region, loudest at aortic cartilage.) The patient died suddenly in a fit of epileptiform convulsions, the temperature at first being depressed, but rising some time before death to above the normal.

*Post-mortem.*—The heart weighed $4\frac{1}{4}$ oz. The transverse diameter was equal to the length. The circumference of the whole heart was $6\frac{12}{16}$th inches, greatest vertical length $2\frac{12}{16}$th inches. The right auricle was dilated and communicated through the foramen ovale with the left auricle by a valvular slit $\frac{1}{4}$ inch long. The two cavæ and coronary sinus opened normally into the right auricle. The tricuspid orifice and valves were normal, measuring $8\frac{3}{16}$ths inches in circumference. The right ventricle was large, and its walls were $\frac{3}{16}$ths of an inch thick. The infundibulum was small, forming a separate cavity, $\frac{3}{4}$ inch long by $\frac{1}{3}$ inch in diameter, but having a communication with the ventricle. At the upper part of the sinus (in the undefended space), lying immediately behind the posterior cusp of the tricuspid valves, there was an oblong aperture in the septum leading into the left ventricle and aorta. The left auricle was normal, the veins opening in the usual way. The left ventricle was thin; its walls being only $\frac{2}{16}$ths inch in section, and the whole ventricle was smaller than the right one. The mitral valve and orifice were normal.

The valves of the pulmonary artery were adherent, forming a cone, at the apex of which was an aperture the size of a crow-quill leading into the pulmonary artery. The pulmonary artery was about a third of an inch in diameter and very thin-walled, but divided normally into its right and left pulmonary branches. The ductus arteriosus was pervious, admitting a probe. The aorta arose partly from the right ventricle.

*Lungs.*—The posterior half of each lung and some patches in the anterior half were collapsed, and very difficult to inflate.

*February 4th*, 1879.

## 6. *Case of congenital malformation of the heart.*

By H. Radcliffe Crocker, M.D.

James B—, æt. 2, admitted under Dr. Donkin August 9th, 1878. Died October 6th. Said to have been healthy when born. At six months of age began to have fits of convulsions, and has been subject to them ever since.

*On admission.*—Very emaciated; face much cyanosed; fingers much clubbed. Heart's apex in fifth space ½ inch inside nipple line. First sound at apex reduplicated, the first half being the louder. The cardiac physical signs remained the same until death. The child gradually sank, and died quietly. Temperature varied very much, at times being only 96° and 97°, at other times rising to 104°. The average temperature was, however, above the normal.

Lungs almost completely collapsed, very little crepitant tissue anywhere. Heart weighed 2¼ oz., transverse diameter greater than longitudinal. Right auricle was large and dilated; the foramen ovale had a slit-like orifice, ¼ inch long, opening into left auricle, and separated by some columnar fibres from a larger slit, ½ inch long, formed by the non-adherent edge of the Eustachian valve; the cavæ opened normally into the auricle. The tricuspid valve was normal. The right ventricle was dilated and hypertrophied, the walls being ⅜ths inch thick. There was a V-shaped aperture in the undefended space of the septum ventriculorum, about the size of a goose-quill.

The infundibulum was distinctly separated from the sinus but communicated with the ventricle, a sacculus passing downwards about ¼ inch into the substance of the septum ventriculorum, terminating above in a small aperture the size of a probe, which opened into a very small thin-walled pulmonary artery, the obstruction at the orifice of the artery being caused by a membrane which showed no evidence of a valvular origin. The foramen was not in the centre of the obstructing membrane. The left auricle was normal, as were also the mitral orifice and valve; the left ventricular cavity was slightly dilated, its walls were $\frac{3}{16}$th inch in thickness, and it communicated through the septum ventriculorum with the aorta, which was much dilated in its ascending portion, and arose almost entirely from the right ventricle. The ductus arteriosus was impervious. The other vessels were normal. *February 4th*, 1879.

## 7. *Case of congenital malformation of the heart.*

By H. Radcliffe Crocker, M.D.

Christopher P— came as out-patient, August 22nd, under Dr. Warner, then being seven months old. The mother complained of the child having fits. The child was healthy when born, and was said to have been fairly plump and of good colour until it was fourteen days old; no blueness was observed up to that time; it was being suckled. When a fortnight old the mother went to look at the child while in its cradle, and first noticed a change in its appearance; it was short of breath, of a blue colour, and seemed cold and ill. She called in a surgeon, as it was thought the child would then die.

*Present condition.*—Distinctly cyanotic; veins of head very visible; fontanelle depressed. No cardiac bruit apparent; cardiac hypertrophy; pulse irregular and intermittent. Fingers and toes not clubbed. No signs of pulmonary collapse or disease.

*Post mortem*, November 20th.—The lungs were extensively collapsed. The heart weighed $1\frac{1}{4}$ oz.; it was nearly globular in shape, the transverse diameter being $1\frac{3}{4}$ inch and the length $1\frac{9}{16}$th inch; the circumference was $4\frac{3}{4}$ inches. The ventricular portion consisted almost entirely of a much hypertrophied and dilated left ventricle, the walls being $\frac{1}{4}$ inch in thickness. The mitral orifice and valve were normal, but the part of ventricles anterior to the valve formed a smooth-walled pouch, the septum ventriculorum being concave instead of vertical. From the top of this pouch the aorta arose, and at the upper part of the septum was a foramen, rounded, rather smaller than a quill, which led into the rudimentary right ventricle, the cavity of which consisted merely of a shallow channel $\frac{3}{16}$ths inch in diameter, leading from the porforation in the septum to the infundibulum, preceded by a canal $\frac{1}{3}$ inch long and about the size of a crowquill, which terminated in the pulmonary orifice, narrowed, by adherent valves, to a diameter of a line, the pulmonary artery itself being not more than $\frac{1}{4}$ inch in diameter and very thin-walled. It measured $\frac{6}{16}$ths inch long, and ended naturally in right and left pulmonary branches. The ductus arteriosus was closed in its middle part. The right auricle was much larger than the left, the two cavæ and coronary sinus opening into it normally. There was no

opening into the right ventricle, nor any trace of tricuspid valves. A needle thrust through the centre of the floor would go into the anterior pouch of the left ventricle, before alluded to, just in front of the aortic orifice. The foramen ovale was widely open, admitting the tips of two fingers, and was divided in two by a thin cord of membrane. The aorta was slightly dilated at its ascending portion, but was otherwise normal. *February 4th*, 1879.

---

8. *Disease of the aortic valves originating in congenital defect.*

By T. B. Peacock, M.D.

H. S—, a girl, æt. 19, admitted into the Victoria Park Hospital October 8th, 1878. She stated that, when five years old, she fell down some stone steps, and after that had constant pain in the back and gradually became deformed. She had always had a cough, and two years before her admission into the hospital, spat a small quantity of blood. She had been seriously ill for about a year, since which time her cough had been more troublesome, and had been attended by expectoration. She had also had pain in the region of the heart and a sense of fluttering. In early life she had suffered from pain in the knees and ankles, but it could not be ascertained that she had ever had a decided attack of rheumatic fever.

When admitted she was very much deformed. There was an angular curvature of the spine at the end of the cervical, and the beginning of the dorsal, regions, and her head fell forwards, resting on the upper part of the thorax. She could not walk or support herself without assistance, but there was no impairment of sensation in the limbs. She complained of palpitation, her face was flushed, and there was some swelling of the lower extremities. A rough systolic murmur was heard at the base of the heart, and that was followed by a loud second sound, and occasionally by a diastolic murmur. She improved in general health while in the hospital, and became capable of walking a short distance without assistance; but she died somewhat suddenly on December 22nd, having suffered for the previous week from headache and sickness.

On *post-mortem* examination, the bodies of the last two cervical

vertebræ, and of the first dorsal were found destroyed, and there was an abscess containing thick, dark-coloured pus, which proceeded from the diseased bones and lay immediately behind the upper part of the sternum and the ribs on the right side. The heart was of large size for the age and sex of the subject, and the aortic valves were found extremely diseased. The right and left segments were blended together, and the united curtain so produced was adherent at the angle and side to the posterior segment, so that the whole three segments were united. Though the union of the right and left was the most complete, there was a frænum or band on the upper side of the united curtain, showing the former point of separation, or the seat of union, of the two segments. The edges of the valves were much thickened, so that there must have been considerable obstruction to the flow of the blood from the ventricle and from the adhesion of the united segment to the posterior curtain, probably also some regurgitation. *March 4th*, 1879.

---

## 9. *Penetrating wound of the heart, involving the transfixion of both ventricles, but not causing death for several minutes.*

By J. P. H. Boileau, M.D.

The heart and the details of this case were forwarded to Netley by Surgeon-Major James Davis, A.M. Dept.

Private A. D—, 95th Regiment, was, on the 5th November, 1878, skylarking with a boy in the kitchen of the officers' mess. The boy took up an old knife (a French cook's knife), and was brandishing it about to keep the deceased off, when the blade flew from the handle, and inflicted the fatal wound. The deceased stooped forward, and the blade fell out from the chest. He then went up to the plate room, ascending fifteen steps, and laughingly told the mess serjeant of the occurrence. He then ran to the hospital, a distance of 200 or 250 yards, meeting on the way a woman, to whom he laughingly said that the baker's boy had stabbed him. When within a few yards of the hospital he fell, and did not speak again. About five minutes elapsed between the receipt of the wound and the moment he fell. He was carried into the hospital, and was found to have a gaping wound of the left

breast, situated between the third and fourth ribs, and midway between left nipple and sternum. There was not any external hæmorrhage. He expired in five minutes.

*Autopsy.*—Pericardium full of dark blood. The heart was not closely examined until it had been in preserving spirit for some days, when the following points were noted. Incised wound on anterior surface of right ventricle $\frac{7}{10}$ths of an inch in length, quite close to the septum. On tracing the course of the wound which opened into the cavity of the right ventricle it was found to pass through the septum, entering the left ventricle, out of which it passed by an opening near the base about $\frac{1}{5}$th of an inch in diameter. The knife-blade in traversing the cavity on the left ventricle almost completely severed the chordæ tendinæ of the anterior flap of the mitral valve. All the cavities of the heart were quite empty. *April 15th*, 1879.

---

## 10. *Case of rapid enlargement of the heart.*

By James F. Goodhart, M.D.

Arthur P—, æt. 17, was admitted into Guy's Hospital under my care on February 19th, 1879. His father had had frequent attacks of acute pneumonia, and one brother died of some cardiac affection. The patient had always been pale, but until three weeks before he was admitted his health had been very good. I made very particular inquiries on this point from his mother and two other relatives, and also from himself, and they all agreed that he had never had any illness before whatever. He had worked as a porter, though not very laboriously so, till three weeks ago, when he caught cold, and next day his feet, knees, and joints of his arms were swollen and painful. He had been feverish and obliged to keep his bed ever since. He had also been delirious with pain in his chest, and for a fortnight had had difficulty of breathing. He was excessively ill-looking, very anæmic, and breathing at the rate of fifty per minute. Pulse 120, soft and full; temperature 100·5°. His lips were livid, and he appeared quite moribund. He was so ill as to forbid any careful examination, but the heart's action was tumultuous, and there was a mitral regurgitant bruit. The air

entered the bases of the lungs but imperfectly. He died three days after his admission.

I need not go at length into the general account of the inspection; it will suffice to say that the viscera were those of a case of heart disease—swollen kidneys, splenised lung and congested liver; but the heart was in the following condition:—Weight 19 oz.; pericardium universally adherent by soft lymph and gelatinous adhesions of recent date. On raising the parietal layer a stratum of fine tubercles, like minute sand-grains, was left behind on the visceral surface, such a state as might very well have been called tubercular pericarditis, but to which the term "granular" is more applicable, since there was no evidence of any tubercle in any other part. The right ventricle was distended with some three ounces of *post-mortem* clot, its walls a little thick. The left ventricle also contained clot, and was rather widely dilated. The walls of the heart of a pale yellowish colour, and mottled. Beneath the endocardium, below the aortic valves, and also in the musculi papillares, the striation of fatty degeneration was commencing. There was no old disease of either set of valves, but both aortic and mitral were fringed with a uniform row of rather exuberant, hemp-seed-sized, soft, recent granulations. No ulceration. I examined sections of the muscular wall microscopically, and there was a considerable quantity of interstitial cell-growth around the vessels, and between the muscular fasciculi. This was in the fresh state. After hardening the muscle in chromic acid, I could not detect more than a very moderate amount.

The point of interest in this case is the weight of the heart, nineteen ounces, and the duration of the illness, only three to four weeks, so that assuming this lad to have started with a heart of normal size it had doubled its weight in four weeks. The next question is—What is the cause of the increase of weight? Was it due to mere swelling or to hypertrophy of the muscle? I am inclined to think that most of it was due to muscular increase, because the new material between the fibres did not seem to me to account for so much, but it must be admitted that simple swelling is difficult to gauge by the microscope. In either view the case is of very considerable clinical interest, and if the increase in size is due to muscular hypertrophy there is much physiological interest attaching to it also, as a case showing the rate of hypertrophy of the cardiac muscular fibre. Not many such cases are on record.

Dr. Peacock has published two cases, Dr. Quain two, and the former has published an article in the 'Edinburgh Monthly Journal,' vol. vii, p. 405, upon the subject, and lately Dr. Stone, in the 'Croonian Lectures' at the College of Physicians, has estimated the increase to take place in the few known cases as at about an ounce a week, but in this case it appears to have been much more rapid than that. *April 15th*, 1879.

---

## 11. *Case of warty growth on tricuspid valves.*

By H. Radcliffe Crocker, M.D.

Eliza D—, æt. 13, had been an in-patient of the East London Children's Hospital, under both Dr. Eustace Smith and Dr. Donkin.

*History.*—Never had rheumatic fever; had had measles and scarlet fever, and seven years previously chorea, and had never been well since. Whether there was any relation between the scarlatina and the chorea was not stated. When last admitted there was general venous congestion, cyanosis, and anasarca, some degree of orthopnœa, hurried respiration with albuminuria and clubbed fingers.

*Physical signs.*—Bulging of præcordial region and of sternum at junction of upper and middle part. Impulse visible over a wide area, the apex beating 1½ inch external to, and the same distance below the level of, the nipple.

The heart's dulness reached upwards to the second rib, its left border being 1½ inch to the left of the nipple line, whilst its right border was ½ an inch within that line.

There was a presystolic thrill and murmur at the apex, the murmur audible as far out as the axillary line and towards the ensiform cartilage. At the base, to the left of the sternum, between the second and third ribs, there was also a short, distinct, diastolic thrill and murmur audible all over the area of dulness, but loudest over the seat of the thrill. Three days later the basic thrill was perceptible, but the murmur was inaudible. There was evidence of fluid in the pleuræ, especially of the right side; pulmonary œdema and cardiac failure increased, and she died three weeks after admission.

*Post mortem.*—General anasarca and dropsy: left pleura contained ʒvj, and right ʒxviij of fluid; the pericardium ℥ij.

The heart was very large, especially transversely, and weighed 12½ oz. The right auricle and ventricle were much distended with dark *post-mortem* clot, and were both dilated, the ventricle being much hypertrophied. The bicuspid valve appeared competent and, with Sibson's cone, measured 3½ inches in circumference. The edges on the auricular surface were fringed with papillæ about ⅛ inch long.

The left auricle was dilated and hypertrophied to a less degree than the left ventricle. The mitral orifice was contracted to a mere slit measuring one inch in circumference. The pulmonary artery was very large, but the valves were competent. The aortic orifice leaked very slowly by the water test, but was probably competent during life.

The lungs were extremely congested, heavy, and œdematous, and all the organs bore the usual evidences of prolonged venous congestion.

The cardiac symptoms seem to have commenced eight years previously in association with chorea and without acute rheumatism The diastolic murmur at the base to the left of sternum heard for a short time, seems referable to the pulmonary artery, though *post mortem* the valves appeared competent. The distended state of the right side of the heart and the pulmonary congestion rendering it extremely probable that there was temporary over-distension of the vessel, the orifice being thus too large for the valves: a diastolic murmur from such a condition is recorded by Hope, and quoted by Hayden in his elaborate work on the heart.

The tricuspid lesion was no doubt as usual secondary to the mitral stenosis. All authors concur in the extreme rarity of warty growths on the tricuspid valve; thus Sibson, in vol. iv of 'Reynolds' System,' records only one case in the *post-mortem* records of St. Mary's for twenty years. A case is recorded in the nineteenth volume of the 'Transactions' by Dr. Wilson Fox in a girl of three years in association with congenital malformation of the heart: and Dr. Morrison, in the twenty-sixth volume, also records extensive warty growths on both pulmonary and tricuspid valves. The size of the heart, weighing 12½ oz., is also noteworthy, Dr. Peacock assigning 10 oz. as the maximum normal weight for the adult healthy female. *February 4th*, 1879.

## 12. *Rupture of the aorta within the pericardium.*

By NORMAN MOORE, M.D.

THE patient was a man, æt. 59, who was for five days a patient in St. Bartholomew's Hospital under the care of Dr. Andrew.

He was a well-made, muscular man, and had no dropsy, but suffered from shortness of breath and palpitation of the heart. A systolic and diastolic murmur was audible at the base, and from the somewhat ill-defined sounds heard at the apex it was thought possible that he had some degree of mitral in addition to his well-marked aortic disease.

On the afternoon of March 29th he sat up in bed to drink some tea, and instantly fell forward dead. I made the *post-mortem* examination on March 31st.

On removing the sternum the pericardium was seen to be greatly distended, and when laid open was found to contain two pints of clotted blood. There was no thickening of the pericardium. The heart showed a moderate degree of hypertrophy, and weighed 23 oz. when freed from its contained clots. The tricuspid and pulmonary valves were normal. In the appendix of the left auricle was a firmly-adherent *ante-mortem* clot. The flaps of the mitral valve were adherent to one another, and their edges had some calcified growths upon them. On pouring water into the aorta its valves were found to be incompetent. Two of the valves were so closely adherent to one another as to give at first the impression that the orifice had only two instead of three valves. The valves showed some calcification on the inner surface, and their edges were slightly curled over towards the centre of the vessel. One inch above the valves the aorta was almost completely torn across transversely, and a third of an inch higher up it showed a small additional and also transverse rent. A clot was found extending from the great rent in the aorta by a small passage between its layers into the sac of the pericardium, and this was evidently the course by which the blood had flowed from the aorta into the pericardium at the moment when the patient sat up in bed. The rupture with a partial dissection had, perhaps, taken place some time before, and the slight exertion was enough to

tear the remaining shred of tissue between the dissected passage and the pericardial sac. There was no aneurysmal dilatation of the aorta. It showed a slight degree of atheroma near the left carotid and left subclavian orifices, but in the rest of its course it was almost free from alteration of the lining membrane, and was perfectly elastic. The aortic wall was exceedingly thin at the region of the two rents in it. The liver, spleen, and kidneys showed signs of the chronic engorgement usual in heart disease, but were not the seat of any special morbid changes. The cerebral arteries were perfectly normal. Cases of aortic aneurysm opening by dissection into the pericardium are not very rare, but rupture of a diseased aorta without aneurysm into the pericardium is much less frequent. From October, 1867, the *post-mortem* registers at St. Bartholomew's do not describe a single case. *May 20th*, 1879.

---

## 13. *Unusually large aneurysm of the ascending portion of the arch of the aorta which burst externally.*

By Henry A. Lediard, M.D., F.R.C.S.

J. B—, æt. 37, was admitted into Cleveland Street Sick Asylum on April 16th, 1877, and died on the 12th of the July following.

The patient had been a potman in a public-house for four years, but for the last eighteen months he had worked as a coal-porter. He had had a cough for eighteen months, dyspnœa for nine months, and a tumour over the chest, which had been growing gradually larger for ten months. During the last few weeks the tumour had been painful, the pain being increased by getting up stairs with heavy loads of coal.

There was a large oval pulsating tumour on the right side of the sternum, over the second, third, and fourth costal cartilages. Percussion over and around it was dull; the heart's action was thumping, the second sound accentuated, but no murmur existed. The apex beat was diffused, passing to the seventh and eighth intercostal

space in the nipple line, and there the sounds were thumping and muffled. Over the right scapula the shock of the heart was very distinct. The pulse slow and regular, and the radials were equal in time and strength. There was a ringing and husky cough, together with scanty bronchitic sputa; the urine was healthy; there was no dysphagia; the pupils were equal; and his chief complaint was that of weakness.

A week or so later the aneurysm suddenly increased in size towards its left edge, and filled up the depression over the sternum, and assumed a more circular outline. This was associated with increased pulsation and pyrexia, and towards the end of April ecchymosis appeared over the tumour, and then faded away. On the 15th of May there was a pricking sensation round the base of the aneurysm, and the right nipple was gradually raised and began to form a part of the aneurysmal wall. At this time the tumour measured 6 inches vertically by 6½ inches across, and the ecchymosis returned.

In June the gradual increase in size of the tumour was observed, together with considerable discoloration over it, and great pain was complained of. At the end of this month redness appeared over the aneurysm, which measured 9 inches by 9½ inches. The right pupil was a little dilated, pain in the back came on, and laryngeal spasms; deep flushing and rapid subsequent pallor were also noted. The pulse remained generally about 88; the skin over the aneurysm then assumed a glazed appearance, and a continual prickling was spoken of in the chest. At the beginning of July the discoloration gradually turned to a large black-looking slough, which oozed for some days, until a final burst towards the lower part of the tumour occurred, and he then died in a quarter of an hour, having deluged his bed with blood. The last measurement was 9 inches vertically by 11 inches across.

On *post-mortem* examination the aneurysm was found to consist of two parts—one lying behind the sternum, and the other lying altogether outside the thorax. The aortic valves were healthy, but directly above them was an opening in the anterior wall of the vessel about 1½ inch by 1 inch, which led into a large aneurysmal sac, which extended forwards and downwards, being adherent to and supported by the anterior surface of the upper portion of the heart. This sac contained no clot, but its walls were lined with fibrin. Passing from this the thoracic wall was found to be perforated, the boundaries of the aperture being the right side of the sternum and

the margins of the second and third ribs, which were widely separated, the sternal end of the latter being free and dislocated forwards; both ribs were laid bare for some inches. This orifice was apparently plugged by a partially decolorised and firm clot, which was semi-adherent to the margin of the opening.

The external part of the aneurysm was in front of the sternum, which was eroded, and beneath the pectoral muscles, which were destroyed, especially on the right side, and here there was a great deal of old and recent clot. The skin over the aneurysm was thin, stretched, and hardened, the point of rupture having taken place at the weakest part.

The heart was of natural size and the valves were healthy, but the walls of the right auricle and ventricle were displaced inwards to some extent by the pressure of the aneurysm. The vessels arising from the arch were healthy, but the aorta presented some atheroma.

The treatment adopted was absolute rest, non-stimulating diet, and 30 grs. of iodide of potassium daily. Ice to the aneurysm could not be borne, and soon all remedies but morphia had to be abandoned. The oozing was successfully checked for many days with collodium and pads of lint until the final rent in the sac wall occurred.

Of 68 cases of thoracic aneurysm collected by Dr. Hayden one only burst externally; and Dr. Stokes alludes to 4 cases only in his work on 'Diseases of the Heart and Aorta.'

Dr. Sibson found that 57 per cent. of aneurysms of the ascending aorta ruptured, but of these 8 only burst externally.

*November* 19*th*, 1878.

---

## 14. *A case of three aneurysms arising from the descending aorta.*

By Hotham G. Orlebar, M.B.

Benjamin W—, æt. 29, a ship's steward, was admitted into Victoria Park Hospital on February 7th, 1879, suffering from great cardiac dyspnœa.

He stated that he had enjoyed always fairly good health. He

contracted syphilis when a lad, and for the last few years had been much addicted to drink. Twelve months previous to his admission, while in a storm at sea, he had been thrown violently against the bunk-board; he fell with his chest against this. He felt rather faint after the blow, and was examined by the ship's surgeon, and declared to be unaffected by it. Until six months ago, that is, six months after the accident, he felt no ill effects from it. At this period, however, he began to suffer from dyspnœa and palpitation, and soon afterwards noticed a pulsating tumour at the right side of sternum. The pulsation, palpitation, and dyspnœa increased steadily up to the time of his admittance into the hospital. When admitted he laboured under such dyspnœa that he had continually to sit upright in bed. The heart's action was irregular and tumultuous; the upper and lower extremities cyanosed and œdematous; there was also a general jaundiced tinge of the surface. Retching and vomiting were troublesome symptoms. The urine was scanty, Oss in the twenty-four hours, and albuminous.

On examination of the chest, the præcordial dulness was found much increased in extent, especially transversely, extending from beyond the right border of the sternum to beyond the line of the left nipple. There was a decided bulging of the dull space, and in the second and third intercartilaginous spaces to the right of the sternum was to be seen and felt a pulsating tumour. This tumour and pulsation almost disappeared after the patient had been a few days in the hospital. At the base of the heart a rough systolic murmur was audible, followed by a dull second sound. The patient died exhausted on the 22nd February.

At the *post-mortem* examination the pericardium was found to be firmly adherent to the heart. The apex of the heart was situated considerably to the left of the left nipple and below it. At the base of the heart, and slightly to the right, was situated a hard tumour about the size of a small orange, that had pressed upon the posterior surface of the sternum and slightly eroded it at the point of pressure. Above this, and still more to the right, projected another tumour with flaccid walls. This last was adherent by its extreme right border with the tissue in the third intercartilaginous space, and was doubtless that which had been seen pulsating at the patient's admission to the hospital. The hard tumour was found to be an aneurysmal sac filled with firm, laminated, partially decolorised coagula; it was found to originate from the commencement of the

aorta, above the angle of the right and posterior valve, by a circumscribed opening. The other tumour was found to originate from the right side of the ascending arch below the origin of the arteria innominata. Its cavity was free from coagula. A third small aneurysmal sac was found originating from the posterior wall of the aorta, an inch above the posterior valve; it contained partially decolorised coagula.

The heart was of large size; both ventricles, but especially the left, hypertrophied and dilated. Aortic valves thickened.

The liver was markedly cirrhosed.

Other organs congested. *March 20th*, 1879.

---

## 15. *Aneurysm of the abdominal aorta associated with disease of the aortic valves; death from uræmia.*

By Henry A. Lediard, M.D., F.R.C.S.

James C—, æt. 52, labourer, was admitted into the Central London Sick Asylum, in Cleveland Street, on June 7th, 1877. He stated that he had enjoyed good health all his life up till four years ago, when he met with an accident. A plank on which he was standing broke, he seized some support, and swinging round to save himself he bruised his side. Since then he has lost flesh and suffered from cough in winter, but kept to his work until last November, having to give up then from a darting pain which came on in his right side and prevented him from walking. There is no evidence of syphilis or family taint of any kind, and he never suffered from rheumatism.

During the last three or four months he has suffered from palpitation, and his feet have swelled for several weeks. He complains of pains in the back, across the abdomen, and down the right thigh.

The patient is a strongly-built man of above the average height, his face and lips are pale, pupils equal and contracted, arteries everywhere very tortuous; his pulse is irregular and intermittent. The

apex beat is seen and felt between the fourth and fifth ribs, just below and outside the nipple, and up and down the sternum a double aortic murmur is heard. There is pulsation in the epigastrium which seems to come from another source than the heart. On sinking the fingers into the abdominal wall, strong pulsation is felt as far as the navel and to the right of it; over this area a systolic murmur is heard, and the cardiac impulse is not synchronous with the pulsation in the abdomen, and the murmurs also are distinct. There is pain of a boring character over this pulsating area, and deep-seated tenderness. There is a systolic murmur heard all down the spine as far as the loins. The lower dorsal vertebræ are prominent, and there is pulsation felt to the right of these bones of entirely local origin, and there is great tenderness below the ribs in the right loin.

Three months later the following notes were taken:—The liver can now be felt for two inches below the ribs on the right side, the apex beat is just below and external to the nipple, the extensive abdominal pulsation is later than the apex beat and throws the liver forward, and there is now diffused pulsation over the thoracic wall below the right nipple. There is projection of the spines of the tenth, eleventh, and twelfth dorsal vertebræ, and on either side of them is heard a systolic, rough, sharp murmur, which diminishes in intensity as the stethoscope is carried upwards.

In October there was great tenderness over the right kidney, and the projected vertebræ deviated to the left side. In November he became more disabled, suffering more lumbar pain and felt a heaviness on the right side of the abdomen. In January, 1878, there was loss of sleep and appetite, and he lay always half out of bed over on his right side with the head downwards. There was œdema of the feet and face, ascites, incontinence of urine, and drowsiness, which deepened into a comatose state, and he died on the 24th. The urine was never found to contain albumen, but it could not be obtained for examination towards the end.

Percussion of the aneurysm from the front was never satisfactory, for the liver was directly over the pulsating area.

On *post-mortem* examination the abdomen was found to contain plenty of fluid, but no blood; an absence of fat was noted, and no peritonitis.

The heart was large, weighing 1 lb. 2½ oz.; the left ventricle was hypertrophied and dilated; the aortic valves were thickened and

incompetent; the aorta presented advanced atheromatous degeneration.

The lungs were firmly adherent to the diaphragm, and here the pleura was much thickened; there was a little recent pleurisy on the right side, but no effusion. The bases showed a low form of pneumonia, and the substance of the lung was soft and rather friable.

The liver was of natural size, but fatty and congested.

The kidneys were unequal in size, the left one weighing 10 oz., and the right one was small, 2¾ oz. only; their substance was healthy.

The stomach was congested and of uniform, dark purple colour, coated with purple mucus, and showed some remarkable black, sloughy-looking patches near the cardiac and pyloric orifices.

The intestines were darkly congested throughout, and coated with purple mucus; towards the termination of the ileum the congestion was associated with miliary extravasation of blood into the mucous membrane.

Springing from the highest part of the abdominal aorta, a large aneurysm was found, which occupied the upper part of the abdomen; it was supported above by the diaphragm, it rested upon the lower dorsal and upper lumbar vertebræ, and bulged backwards on either side of the spine, more especially in the right loin. It was covered in front by the liver; on either side the kidneys were thrust aside, and behind was the eroded spine, which was curved backwards to the left side.

On examining the sac more closely the diaphragm was found to be firmly adherent to its upper part, and from the lower part of the anterior surface the terminal portions of the aorta was seen to emerge obliquely, the vessel being quite healthy from this point to its bifurcation. From behind, the sac was seen to be adherent to the sides of the bodies of the vertebræ, which were entirely included in the aneurysm.

The cœliac axis arising from the aneurysmal wall was small and impervious; below it was the superior mesenteric artery, which was healthy, and arose from the tube of the aorta as it passed through the sac wall.

The inferior mesenteric and left renal arteries were also unaltered, but the right renal vessels were obliterated, a slight trace of them only being left on the aneurysm.

From above downwards the vena cava crossed the aneurysm, and was adherent to it, but uninjured.

The semilunar ganglia were found very well marked and lying in front of the aneurysm and to the left side of the branches of the aorta above mentioned.

The supra-renal capsule of the right side was found adherent, and flattened down to the right side of the aneurysm; the left capsule was free and healthy.

On opening the aneurysm the sac was found to be tough and of moderate thickness, tolerably uniform, and thinly lined with old pale clot. Within was a small amount of soft, dark, recent clot.

The bodies of the three last dorsal vertebræ were hollowed out into cup-like cavities, which were filled up with friable and decolorised clot.

The first and second lumbar vertebræ were eroded, laid bare, and presented an almost polished appearance.

The intervertebral substances were either gone or diminished in size, and altered in structure, the vertebræ in question being somewhat anchylosed; in a little longer the spinal canal would have been reached.

The atrophied condition of the right kidney was the result of the obliterated condition of the renal vessels on the right side, as well as the direct pressure of the tumour upon it. Although the kidneys were healthy in structure, yet the pressure forwards of the aneurysm upon the adherent vena cava must have produced the deeply-congested condition of the abdominal viscera noted and the supervention of uræmia, which is not commonly met with in these cases. Ascites is another feature unusually associated with abdominal aneurysm, and may have been due to the venous obstruction, as well as the valvular disease of the heart. Dr. Stokes states that there is no necessary connection between disease of the heart and aneurysm of the aorta, and that the combination is a rare one.

*November* 19*th*, 1878.

## 16. *Cured subclavian aneurysm.*

By Sydney Jones, M.B.

The specimen shown was one of cured aneurysm of the right subclavian artery, from a man who had undergone spontaneous cure of a left popliteal aneurysm, and in whom also a right popliteal aneurysm had been successfully treated by compression on the proximal side.

The history of the case is given in the 52nd vol. of the 'Medico-Chirurgical Transactions.' It was brought forward by the late Mr. Poland, the man having been for some time under the observation and treatment of Mr. Corner, of Poplar. The subject was a shipwright, was thin and spare, had never been at sea, and had not had syphilis.

In December, 1859, he applied to Mr. Corner complaining of swelling and coldness of the left leg and foot, which had existed for more than a month. No pulsation could be detected in either tibial or in the popliteal, or in the femoral, below the giving off of the profunda. He had experienced pain and stiffness in the left popliteal space, where was found a firm swelling. Slow amendment occurred, and the swelling gradually disappeared.

In February, 1861, a pulsating swelling, about 4 inches by 3, appeared in his right popliteal space. Compression of the femoral completely stopped pulsation, and by steady pressure the swelling was temporarily removed.

Early in March pressure was had recourse to. On March 18th half the aneurysm had become solid, and the tibial had ceased to beat. On April 6th, 1861, all hardness in the ham had disappeared, but patient could not walk many miles without feeling his feet cold.

The man followed his usual occupation until June, 1866, when he began to suffer much pain about his right shoulder-joint, and accidentally discovered a swelling above the clavicle. In August, 1866, he became an in-patient under my care at St. Thomas's, where the swelling was found to be due to aneurysm. It was not thought advisable to recommend any operative interference; but rest, locally and generally, with slight pressure upon the swelling, was enjoined.

In January, 1867, he came again under Mr. Corner's care; was

kept in bed and ice was applied, and a diet used of animal food and bread; but without any benefit.

In August, 1867, a leathern cup was fixed over the swelling, and secured by straps under each axilla; much benefit is said to have followed this; he had less uneasiness. He acted as shipkeeper, avoiding only laborious jobs, and lived as an ordinary working man.

In August, 1868, he felt suddenly bad; experiencing sickness and vertigo, so that he was obliged to hold on to something to prevent his falling; and on putting his hand to swelling afterwards felt no pulsation.

On the 15th of August there was slight pulsation; but the bulk of the swelling was hard.

On October 26th there was neither swelling nor pulsation. Slight impulse in radial and brachial. Temperature lower than on the left side. Sensation perfect. He resumed work as a shipwright.

In 1877, nine years afterwards, he began to show symptoms of cardiac and aortic disease; these gradually increased, and he died, æt. 56, in May, 1878. The popliteals were not examined; but the specimen showed the condition of the right subclavian. It was not so perfect as it might have been, having been put into strong spirit before the blood was washed out of it.

The following is a brief description, given by Mr. C. Stewart, curator at St. Thomas's:

"There is extensive atheroma of the aorta and an aneurysmal dilatation of the innominate and first part of the subclavian. The latter part of the aneurysm is filled with old clot, the remainder of the subclavian being converted into a fibrous cord closely adherent to the first rib. There is also a saccular aneurysm of the aorta at the point of origin of each coronary artery.

The case is of interest in that it was referred to by the late Mr. Poland as one of subclavian aneurysm *cured by direct compression over the tumour*. He wore a leather cup from August 1867 to August 1868. On the latter date he had an attack of sickness and vertigo; and afterwards the pulsation in the tumour had diminished and soon disappeared. The cure, however, seems to have been spontaneous; by the sudden accumulation of clot in the aneurysm; the sickness and vertigo being probably due to sudden change in the current of the circulation. *January 21st*, 1879.

17. *Progressive thrombosis of the veins of one lower extremity, with consecutive embolism of the pulmonary artery, from a case which had previously undergone an operation.*

By Robert Lyell, M.D.

S. C—, æt. 56, admitted into the Middlesex Hospital, under the care of Mr. Lawson, on October 8th, with a scirrhous tumour of the breast. Eight days after the breast was amputated. The patient progressed favorably for about ten days, and was then attacked with symptoms of phlebitis of the veins of the left lower extremity, apparently commencing in some superficial varicose veins as a focus. The limb was much swollen, but at the end of a week all the acute symptoms subsided, the œdema disappeared, and, the wound cicatrising healthily, she was regarded as convalescent.

On the morning of November 16th, having been previously quite quiet, and apparently asleep, she suddenly sat upright in bed shrieking, and exclaiming she was about to die. This distress lasted till death, which took place about twenty minutes after the commencement of the attack, the pulse being extremely small throughout, and the lips becoming livid.

At the *post mortem* the body was found extremely well nourished and the wound partially cicatrised. The interest, however, was centred in the condition of the heart and large vessels, and of the venous trunks of the left lower extremity. Beyond the heart none of the other viscera presented any features of importance. The former, when exposed in the thorax, presented a collapsed and flaccid appearance, whilst the trunk of the pulmonary artery, on the other hand, was distended as if by something within it, a condition which extended into its right branch, the left being evidently empty. The left lung was therefore detached, and the heart, with the right lung, removed together.

On opening the heart, all its cavities were found in condition of diastole, and contained dark liquid blood, but no coagula. In the right ventricle, just protruding between the segments of the pulmonary valve for a short distance into its cavity, lay exposed the rounded extremity of a clot, which, on slitting up the trunk of the pulmonary artery and its right branch, was found to fill the former

completely and the latter partially. It consisted of a coagulum of cylindrical shape, as if moulded by its formation in some large vessel, in thickness about the size of the little finger, and so lodged in the artery, that it lay folded upon itself, the two halves closely applied to each other in the trunk of the vessel, and the angle or extremity formed by the doubling protruding downwards through the pulmonary orifice, and being thus just visible in the cavity of the ventricle. The left half of this coagulum thus sharply folded upon itself, although in close apposition with the other half whilst undisturbed in the vessel, when detached from this, appeared to end in a free and tapering extremity, which, in position, corresponded almost exactly to the marking on the interior of the artery representing the bifurcation of the vessel, and not in the slightest degree extending into the left branch. The right half of the coagulum, however, was continuous (although the continuity had been partially severed in the examination) with the centre of a cylindrical bar of clot, which filled the bifurcation of the trunk, projecting into the right branch, and ending there with blunt, rounded extremity. The whole of the coagulum lay quite loosely in the artery, so that it could be lifted with the greatest ease, and quite intact, from its resting place. It was slightly decolorised on its surface, the latter being paler than the interior, and marked with perfect circular, transverse markings, as if being the impressions of the middle coat of some vessel in which it had been previously lodged. No valvular markings were distinguishable. When extended it measured about five inches, and, divided, its thickness was found to be composed of soft, purplish-black clot of homogeneous, non-laminated appearance.

The remaining branches of the pulmonary artery were quite empty, the lungs, however, containing a quantity of dark fluid blood, which exuded from the cut surface on pressure.

On examining the left lower extremity the positions of several of the cutaneous veins, especially of the thigh, and notably of one which ran obliquely across it anteriorly, were well mapped out by reddish-blue lines indicative of *post-mortem* blood-staining, and to the finger were to be felt hard and cord-like. The saphena, with its principal branches, the femoral, iliac, and cæcal veins, were removed and examined. All the veins of the thigh, as far as they were thus removed, were completely plugged with firm, slightly adherent coagula, the common femoral greatly distended, and its coagulum showing commencing softening. The common and external iliac

veins were contracted, their walls thickened and matted, and when slit up were found quite empty, the intima being discoloured, rough, and irregular from shreds of adherent fibrinous membrane, as if it had previously contained coagula; the inferior cava was empty and normal; the internal iliac and its branches, having been divided close to its entrance into the common iliac, were not examined.

Pathologically, the sequence of events in this case is perfectly comprehensible, the sudden death being explicable by sudden obstruction to the pulmonary circulation by the impaction of a coagulum in the trunk of the pulmonary artery, a fact already suspected at the time of its occurrence; it only remains to further elucidate the source of the clot, whether it is to be considered as a coagulum *in sitû*, or as an embolism conveyed from a distance.

With reference to the former view (inasmuch as its cylindrical shape and transverse markings point conclusively to its original formation in some vessel), it must be presupposed to have been displaced in order to assume the position in which it was found.

Completely antagonistic to this view are, firstly, the circumscribed character of the clot, its absolute limitation to the parts mentioned above, the total absence of any other coagula, either in other branches of the pulmonary artery, or in the right cavities of the heart, and, lastly, the inability to replace in any position which it might be assumed to have occupied before displacement, without injuring its continuity. Whereas, in support of the latter view, the condition of the veins affords almost conclusive argument; the left common and external iliacs were empty, and all the venous trunks below them were plugged, whilst the thickening of the coats of the former showed that they also had participated in the phlebitic inflammation, their internal coats presenting traces of the coagulum which they had presumably previously contained in the shape of films or shreds of adherent fibrin. By this we are led to the conclusion that a large coherent coagulum, being loosened and detached by the regurgitant blood-stream flowing along the internal iliac returning the blood from the limb, had been carried bodily along the inferior cava, and had become impacted in the pulmonary artery.

*November 19th*, 1878.

# IV. DISEASES, ETC., OF THE ORGANS OF DIGESTION.

## 1. *Case of poisoning by sulphuric acid.*

By NORMAN MOORE, M.D.

THE patient, a man, æt. 21, was brought to St. Bartholomew's Hospital on March 3rd, 1879. He had drunk more than half a pint of the oil of vitriol used for cleaning machinery half an hour before admission. His death took place an hour and a half after admission. When admitted, as I am informed by Mr. Holland, the house-physician, he was in great agony, but understood what was said to him, and seemed only just unable to reply. He had little or no difficulty of breathing.

The *post mortem* was made twenty-six hours after death.

On each side of the mouth was a brownish line running down the chin, and the skin around the umbilicus was of a greyish hue. The inner surface of the rectus abdominus on each side was greyish, and in parts it was almost disintegrated. The upper part of the oblique muscles was also affected. The mouth and fauces were dry and whitish, but the mucous membrane did not seem to be greatly injured. The œsophagus was greyish and firmly contracted. Its mucous membrane looked severely burnt, but was not anywhere perforated. Its muscular tissue was infiltrated by the acid, and the posterior wall of the heart exhibited a similar infiltration, being grey and hard for half its thickness. The pericardium was absolutely dry.

The diaphragm was entire but hardened and greyish, and the bases of the lungs showed a hardened tract of a quarter of an inch in depth. There was no breach in the alimentary canal above the diaphragm, but below, the walls ceased, a blackish mass being all that remained to indicate the stomach. The œsophagus ended, in fact, in a fringe of shreds. The intestines were affected right down to the rectum, the parts nearest the stomach being so tender as to fall to pieces when touched.

The liver, spleen, and kidneys exhibit various degrees of hardening.

The liver and spleen look outside like leather, and to palpation give the sensation of bags with tough, but partially elastic walls.

The bladder was contracted and empty, and also saturated by the acid.

The blood in the aorta and vena cava was changed into hard carbonised masses like pieces of bitumen.

Some of the changes in the abdominal viscera were no doubt *post mortem*, but the case is remarkable in the extent to which the inner surface of the whole alimentary canal is affected.

*March 4th*, 1879.

---

## 2. *Perforating ulcers of the ileum from obstruction after ovariotomy.*

By Alban Doran.

A. M—, æt. 26, a lady's maid, was admitted into the Samaritan Free Hospital, under the care of Dr. Granville Bantock, on November 29th, 1878.

Five weeks previous to admission she had been seized with rigors and severe abdominal pain. A practitioner who was called in to attend her, informed her mistress that the patient was suffering from typhoid fever. A fortnight later she was seen by Mr. Manser, of Tunbridge Wells, who could detect no symptoms of any specific fever, but as her temperature varied for several days between 100° and 102°, and as he found that a large fluctuating tumour filled the lower and middle parts of the abdomen, he believed that there had been an attack of peritonitis consequent on ovarian disease. In three weeks the patient was free from all pain and feverishness, and was able to walk about. She then came to London, where she was examined by Mr. Spencer Wells and Dr. Bantock, who were both of opinion that an ovarian tumour existed.

During the few days that the patient spent in the hospital before operation her temperature was generally a degree or a degree and a half above normal in the evening. On the night of the 3rd of December it reached 100·6°. The operation was performed by Dr.

Bantock on December 4th, and as I assisted that gentleman I had the advantage of seeing the condition of the intestine during lifetime. A suppurating multilocular tumour of the left ovary was discovered, containing seven pints of turbid fluid. It was very closely adherent behind to eight or ten inches of the lower part of the ileum. The adhesions were broken down by sponges, and as the raw surface of the intestines bled freely, six small open vessels were secured by fine silk ligatures. The pedicle, transfixed, and ligatured by silk threads, was returned into the abdominal cavity after the tumour was cut away. The right ovary, being enlarged to the size of a walnut, and showing signs of incipient cystic disease, was also removed and the pedicle secured by complete intraperitoneal ligature.

The patient brought up green vomit several times on the evening after operation, but on the night of the 5th of December she was quite comfortable. Temp. 99·8°, pulse 122. Two days later the temperature rose as high as 101·4°, and there was fetid discharge from the vagina, which canal was washed out with a weak solution of sulphurous acid. There was no distension of the abdomen. For a few days the temperature continued above normal, rising as high as 102° on December 10, when the rectum was washed out for the removal of a small quantity of fæcal matter which came away with much flatus. The patient frequently vomited. On the 11th, as the vomiting continued, with high-coloured urine and slight icterus, her food was discontinued and she was fed by beef-tea enemata. The abdominal wound had healed very well.

At nine o'clock on the next evening, the eighth day after operation, the patient complained of feeling of tightness across the abdomen; her temperature was then 99·8°. At 10.30 p.m. she was in a state of collapse, the pulse scarcely perceptible and temp. 100·6°. At 12 a.m. she still complained of abdominal pain, and her temperature had risen to 101·4°. She expired at 12.45 a.m.

I made a *post-mortem* examination of the patient's body fifteen hours after her death. Rigor mortis was very slightly marked. The thoracic viscera were healthy.

On opening the abdominal cavity, over a pint of perfectly liquid fæces was found diffused over the coils of the small intestines, the coats of which were much softened, tearing readily when pinched by the forceps. A coil of ileum, partly adherent to the abdominal wall by recent lymph, was gently raised, and a jet of fluid fæces imme-

diately gushed out of a perforation in its coats posteriorly. The small intestine above the aperture was filled with flatus and liquid fæces, and the remainder of the ileum below the perforated coil, as far as to within three inches of the ileo-cæcal valve, was matted together by recent lymph on the serous coat, the site of the former adhesion to the back of the cyst. This obstructed mass, much narrowed and quite empty, hung down over the promontory of the sacrum. The end of the ulcerated coil, being full of flatus, had risen so that its free border almost touched the mesentery above. Hence the intestine was sharply twisted at the point where this coil joined the dependent, obstructed mass. This complication, evidently secondary, made the obstruction complete. The perforating ulcer was nearly a foot above the twist in the ileum. The ascending colon, sigmoid flexure and rectum, were full of solid fæces.

The remaining abdominal viscera were normal, and the pedicles of the tumours were undergoing those changes which should naturally occur after the ligature. There was no pus to be found in the pelvic cavity.

The mucous membrane of the alimentary canal from the stomach to the seat of obstruction was, in most parts, deeply injected. In the ileum, towards the seat of obstruction, there were signs of inflammation along the course of the larger blood-vessels and on the edges of the valvulæ conniventes. In the middle of these inflamed streaks small elongated ulcers could be detected. The perforating ulcer was nearly circular, its edges were clean-cut without any thickening. The muscular coat was exposed and also perforated, and in the serous coat was found a hole one eighth of an inch in diameter. Perforation was commencing in several neighbouring ulcers and accidentally completed (as the specimen shows) after death, when the diseased portion of intestine was washed to free it from mucus and fæces. There was no trace of ulceration of Peyer's patches. In the ileum, below the twisted point, the mucous membrane was pale, thrown into folds, and presented no trace of disease.

The perforated portion of intestine will henceforward be found in the pathological series of the museum of the Royal College of Surgeons (No. 1201 B).

This case recalls a somewhat similar instance where perforating ulcers were found some distance above a strangulated portion of intestine, death occurring about thirty hours after an operation for the relief of femoral hernia. The case is recorded by Mr. Morrant

Baker in the twenty-seventh volume of the Society's 'Transactions.' In both cases there is a distinct history of intestinal disturbance for some time previous to operation. But in Mr. Baker's case there was sloughing; in the specimen I bring forward no slough can be found. Mr. Wells in his work 'On Diseases of the Ovaries' refers to one case under the care of Dr. Lyon, of Glasgow, where symptoms of obstruction followed the removal of an ovarian tumour. Minute perforations were found in a portion of intestine adherent to the bottom of the abdominal wound. The severe intestinal disturbance, previous to the removal of the tumour, in the patient from whom this specimen was taken, became aggravated by the complication after operation. The impaired health of the patient contributed probably in no small degree to cause the inflammatory changes in the ileum to assume an ulcerative character.

*February* 18*th*, 1879.

---

## 4. *Note on the morbid anatomy of hypertrophic cirrhosis of the liver.*

By Robert Saundby, M.D. Edin., M.R.C.P. Lond.

For a long time the French pathologists have been aware that there are cases of hepatic cirrhosis which do not conform to the dictum of Bichat, "Cet état ne se complique jamais du volume extraordinaire du foie." In 1859 MM. Charcot and Luys presented a memoir to the Société de Biologie, in which they maintained that the new growth in hypertrophic cirrhosis penetrates the lobules, is therefore intralobular, while in ordinary cirrhosis it surrounds the lobules and is perilobular. In 1871 M. Ollivier contributed a series of papers to the Union Médicale, in which he sought to establish a separate clinical identity for these cases. In 1874 M. Hayem published a paper in the Archives de Physiologie, which contained an account of two cases of hypertrophic cirrhosis with microscopical descriptions, showing that the growth invaded the lobules, and, according to this observer, followed the course of the capillary blood-vessels. A few months later M. Cornil drew attention, in the

pages of the same journal, to the numerous biliary canaliculi present in the dilated portal canals, fissures, and spaces of cirrhotic livers, especially of the hypertrophic form; an appearance which M. Cornil had described in 1871 in a case of acute yellow atrophy, which had run a somewhat protracted course. In 1875, M. Hanot wrote his inaugural thesis upon a form of hypertrophic cirrhosis accompanied by jaundice, for which he sought to establish a definite clinical and pathological position. During life the disease may be recognised, according to M. Hanot, by the history of early and persistent jaundice, the even enlargement of the liver, and the absence of ascites; anatomically, the liver is enlarged, its surface is smooth, often covered by traces of perihepatitis; the organ is tough on section, its cut surface is yellow or olive green in colour. Microscopical examination reveals, in addition to the new growth, which he describes as intralobular, a great development of biliary canaliculi in the extralobular connective tissue. M. Hanot regards this form of cirrhosis as originating in an inflammation of the bile ducts leading to obstruction to the outflow of bile, dilatation of the capillary ducts, and extension of the catarrhal inflammation to these latter, which become at first filled with cells, and finally lined with epithelium.

The doctrine of a form of cirrhosis originating from changes in the bile ducts was taught by Rokitanski, but opposed by Frerichs. In 1866 Wyss published an account of the structural changes in jaundice, and described some degree of new connective-tissue growth which, he says, never invades the lobules. In 1872 Heinrich Meyer, experimenting on animals, found an increase of the connective tissue both around the vessels and in the lobules. Dr. Beale published a case of cirrhosis resulting from obstruction of the common duct. In 1873 Dr. Wickham Legg described the results of ligature of the common bile duct in cats,[1] the operation being followed by enlargement of the liver and a formation of new connective tissue around and within the lobules he ascribed these changes not to the obstruction to the flow of bile, but to the extension of inflammation along the duct from the seat of the ligature.

In 1876 MM. Charcot and Gombault[2] published an account of the changes in the liver after ligaturing the bile duct in guinea-pigs,

[1] 'St. Bartholomew's Hospital Reports,' 1873, p. 161.

[2] "Note sur les Alterations du Foie Consecutive à la Ligature du Canal Cholédoque," 'Arch. de Phys.,' Mai—Juin, 1876.

the principal features of which were enlargement of the liver, development of new connective tissue around and within the lobules, multiplication of the biliary canaliculi, and atrophy of the liver cells. They observed that the newly formed canaliculi could be traced in certain places in direct continuity with the rows of hepatic cells. In a subsequent paper[1] they adopt M. Hanot's description of the clinical characters of hypertrophic cirrhosis with jaundice, as those of biliary cirrhosis, which is characterised anatomically by the new growth surrounding *each* lobule (monolobular), invading the lobules (intralobular), and the development of a numerous network of biliary canaliculi. As to the last appearance, M. Charcot[2] says:—"C'est là le phénomène fondamental dans la série des lesions de la cirrhose hypertrophique avec ictère, et suivant toute apparence, le premier en date, celui d'où dérivent tous les autres." On the other hand, the ordinary atrophic form is described as "portal cirrhosis;" the new growth surrounding many lobules (multilobular) not invading them (perilobular), while any development of even biliary canaliculi is exceptional and accidental, being ascribed to a local compression of a part of the ducts by the new growth.

From the above quotation it is plain that M. Charcot regards the appearance of an abundant network of biliary canaliculi as characteristic of biliary cirrhosis, and also as the evidence of a primary affection of the excretory apparatus of the bile. By previous observers, Cornil, Waldeyer, Klebs, and others, their presence had been noted in atrophic as well as hypertrophic cirrhosis; but M. Charcot thinks biliary cirrhosis in some cases becomes atrophic, and he admits their accidental presence under other conditions. When my attention was first drawn to this subject, I went through my preparations and cases, and in an article in the 'British and Foreign Medico-Chirurgical Review' for July, 1877, I said, "We believe that the evidence is incontrovertible that chronic obstructive jaundice, or the resulting inflammatory changes, causes a form of cirrhosis of the liver, and we admit the truth, at least, provisionally, of M. Hanot's three clinical features—(*a*) jaundice, (*b*) enlargement of the organ, and (*c*) absence of ascites—as characterising this special form. Moreover, from a careful review of a large number of specimens of cirrhosis, we admit that the growth differs from ordinary

[1] "Contribution à l'Étude Anatomique des differentes formes de la Cirrhose du Foie," 'Arch. de Phys.,' Sept.—Oct., 1876.

[2] 'Leçons sur les Maladies du Foie,' p. 212.

cirrhosis by extending within the lobules more frequently and to a greater extent than in the latter. But we are not inclined to admit that this new formation of canaliculi is essential or pathognomonic, but is related to certain secondary changes which may or may not be present." This opinion was founded upon old preparations, and especially on a section of syphilitic cirrhosis, in which the canaliculi were very abundant, but the evidence I have now to offer is still more conclusive, as the cases were carefully observed with reference to the points to be decided.

The first case was that of a patient who presented during life an exact conformity with the clinical description of M. Hanot (persistent jaundice, enlargement of the liver, absence of ascites). At the autopsy the liver was found to be much enlarged, smooth on the surface, tough on section, yellow coloured; there was no alteration of the external bile apparatus. The portal canals, fissures, and spaces showed a new growth of connective tissue, with much nuclear proliferation, and some appearance of newly-formed biliary canaliculi in the fissures and spaces where the lobules were most encroached upon. The new growth invaded the lobules. No network of biliary canaliculi could be seen in the portal canals, and the drawing gives the best illustration of the condition which the organ afforded.

Here, therefore, was a case which conformed in all respects to the description of biliary cirrhosis, but in which "le phénomène fondamental" was almost wanting.

The second case presented during life the clinical characters of ordinary cirrhosis, except that the liver was enlarged. There was no jaundice; ascites was present, with chronic peritonitis and perihepatitis. The liver was enlarged, weighing seventy-six ounces, and presented the common appearance of the association of fatty infiltration with cirrhosis. The drawing (Pl. XVII, fig. 2) shows numerous canaliculi in the new growth around the lobules, the hepatic cells being very fatty. This was a case of hypertrophic cirrhosis, if you please, as the liver was enlarged, but it conforms in no other particular to M. Hanot's type; its surface was coarsely granular, while the bands of connective tissue were multilobular. The ascites may be ascribed to the chronic peritonitis present, but even then the case differs essentially from all we have been told as characteristic of biliary cirrhosis, from which not the least important distinction is the absence of jaundice.

## DESCRIPTION OF PLATE XVII.

Plate XVII illustrates Dr. Robert Saundby's Note on the Morbid Anatomy of Hypertrophic Cirrhosis of the Liver. (Page 301.) From drawings by himself.

FIG. 1. Multiplication of biliary canaliculi in a portal canal and around the lobules, from a case of phthisical cirrhosis of the liver. Hartnack, oc. 3, obj. 4.

FIG. 2. Similar appearances, highly magnified, from a cirrhosed and fatty liver without jaundice. Hartnack, oc. 3, obj. 8.

Fig 1

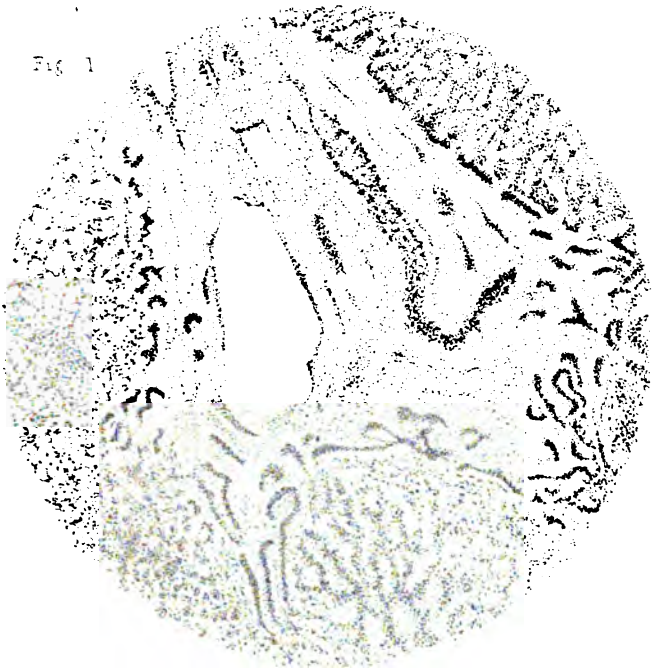

Fig 2

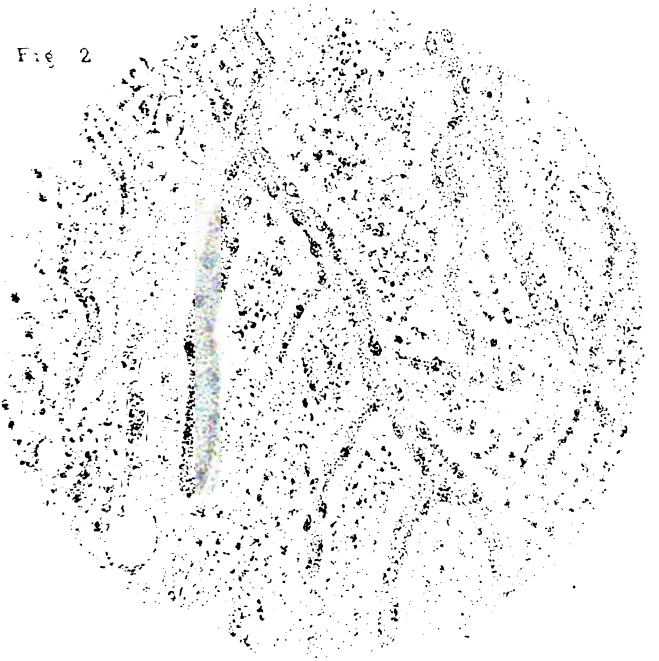

plication of biliary canaliculi as present in cases of undoubted alcoholic cirrhosis, in the cirrhotic livers of tubercular patients, and in some forms of atrophic nutmeg liver.

*February* 18*th*, 1879.

---

## 5. *Cases of abscess of liver.*

By Norman Moore, M.D.

Case 1. On opening the body the most prominent part of the liver was a whitish mass, which proved to be the wall of an abscess. This abscess extended from the dorsal to the ventral surface of the liver, and contained about eight ounces of thick pus, slightly blood-stained. The gall bladder itself was compressed, but the ducts were free. In the right lobe deep in the liver substance was a second abscess as large as an orange, and in the same near the diaphragmatic surface was a third abscess of walnut size.

The liver was considerably enlarged, and exhibited amyloid infiltration.

The colon showed several ulcerated patches, all within eight inches of the ileo cæcal valve. The largest was of the size of a shilling, and the edges of all were somewhat thickened. There was amyloid disease of the small intestine and of the kidneys.

The patient was a woman, aged 55 years, who had been in St. Bartholomew's Hospital under the care of Dr. Gee. The abscesses were not obvious during life.

The patient had lived in London, and has never been further from home than Ipswich, so that this was one of the rather rare examples of abscess of the liver in a case of English dysentery.

Case 2. The abscess was in the right lobe, and near the diaphragmatic surface of the liver. It consisted of two cavities, and had a thick wall. It contained about an ounce of thin, ill-smelling pus. Outside the abscess the liver tissue was rather soft for one twelfth of an inch, and beyond that was normal.

The patient was a man aged 21 years, who had been in St. Bartho-

lomew's Hospital under the care of Mr. Morrant Baker, who had amputated his left leg below the knee. The stump was perfectly healed, and when cut into was found to contain no pus.

The intestines were normal. The spleen and kidneys showed amyloid disease.

The probable source of the hepatic abscess was a sinus, which the patient had had for many years in the left leg.

CASE 3. The abdominal muscles were adherent to the liver, forming the wall of a superficial hepatic abscess.

The abscess was associated with pylephlebitis, for the portal vein at its entrance to the liver was completely occluded by a firm, closely adherent clot, and along its course in the liver were many small abscesses. The intermediate hepatic tissue was normal. The pylephlebitis probably succeeded, or was the contemporary of an old abdominal inflammation indicated by a much thickened and highly pigmented vermiform appendix. The patient was a woman, aged 35 years, who had been in St. Bartholomew's Hospital under the care of Dr. Andrew.

CASE 4. The right lobe of the liver was excavated by an abscess as large as a child's head. The abscess was bounded behind by the right kidney and perinephritic tissue, but its cavity did not communicate with the colon. The suppuration had penetrated the capsule, and invaded the cortex of the kidney, but had nowhere reached the pyramids. The hepatic part of the abscess was very uneven, ragged and greyish. It contained a little purulent ill-smelling fluid. Outside the cavity there was a zone of hepatic tissue infiltrated with pus, and the liver contained in every part many similar infiltrated patches, some of which enclosed fluid pus, while others were only partially softened. The gall bladder and the large ducts were unaffected.

The channel of a trocar wound was visible in the abdominal wall, and in the anterior and lateral wall of the abscess, but the liver was not at the point of puncture adherent to the body-wall. There were the appearances of general recent peritonitis. The colon was exceedingly thin, and the whole inner surface of the large intestine, except the last three inches of the rectum, was gelatinous in appearance, owing to a layer of fœcal matter lying upon a surface everywhere reticulated by ulceration.

The small intestine showed no ulceration. There was no amyloid disease.

The patient was a man, aged 29 years, who was under the care of Dr. Andrew, in St. Bartholomew's Hospital. The patient left India in good health on December 6th, 1878. Shortly before landing in England he had a violent rigor, and after landing several more rigors. He was admitted at St. Bartholomew's on March 7th, 1879, having then had dysenteric diarrhœa for a month. He never had dysentery in India. No enlargement of the liver could be felt at the time of his admission, but he had tenderness on pressure in the hepatic region. The pain was continuous, and by April 14th the signs of abscess of the liver were tolerably distinct. On April 19th the abscess was opened, and about four pints of pus let out. He gradually sank, and died on May day.

In this case the patient, no doubt, received his dysenteric infection in the tropics. As he had had ague some years before in India, it is not absolutely certain that the rigor he had before landing in England was due to the commencement of hepatic suppuration, but it did probably mark the beginning of the abscess and it is interesting to notice that the severe dysenteric symptoms did not appear till after the symptoms of abscess.

These four cases are the only examples of abscess of the liver which have occurred at St. Bartholomew's Hospital during the first half of the year 1879.

The following table shows the number of cases of hepatic abscess in each year since October, 1867, the date at which the present series of records of post-mortem examinations begins, and gives some other contributions to the statistics of this affection:

| Year. | Sex. | Age. | Seat of abscess. | Associated suppuration, &c. |
|---|---|---|---|---|
| 1867 | M. | 25 | Right lobe | Of colon; abscess opening into it; amyloid disease. |
| 1868 | M. | 24 | Right lobe | Extensive ulceration of large intestine. |
| 1869 | No case during this year. | | | |
| 1870 | M. | 47 | Two in right lobe | Extensive ulceration of colon. |
| 1871 | F. | 34 | Right lobe | No other suppuration; this was suspected to be an hydatid. |
| „ | F. | 27 | Large in left lobe, and small in right lobe | Old abscess of ovary, pericardium, and pleura. |
| 1872 | M. | 40 | Numerous | Scars of old ulcers in cœcum. |
| 1873 | M. | 30 | Right lobe | Extensive ulceration of cœcum. |
| „ | M. | 19 | Numerous in right lobe | Abscesses about spleen. |
| 1874 | M. | 37 | Right lobe | Extensive ulceration of colon, and many old scars. |

| Year. | Sex. | Age. | Seat of abscess. | Associated suppuration, &c. |
|---|---|---|---|---|
| 1874 | F. | 16 | Numerous in left lobe | Ulceration of vermiform appendix and perityphlitic abscess. |
| " | F. | 24 | Right lobe | Stone and abscess of right kidney, but no communication. |
| 1875 | M. | 13 | Numerous | No other suppuration. |
| 1876 | No case during this year. | | | |
| 1877 | M. | 27 | Four large abscesses, two in each lobe | Ulceration of large intestine. |
| " | F. | 18 | An abscess in each lobe | Two ulcers in colon. |
| 1878 | M. | 41 | Right lobe | Numerous ulcers of colon. |
| " | M. | 30 | Numerous | Pylephlebitis; ulceration of appendix vermiformis. |
| 1879 | F. | 55 | Three abscesses | Ulceration of colon. |
| " | M. | 21 | Right lobe | Sinus in left leg. |
| " | F. | 35 | Numerous | Pylephlebitis; old ulceration of appendix vermiformis. |
| " | M. | 29 | Right lobe | Extensive ulceration of large intestine. |

Since cases of abscess of the liver usually end fatally, this table, showing but 20 cases out of 2464 post-mortem examinations, illustrates the rarity of the affection in London. *May 6th*, 1879.

# V. DISEASES, ETC., OF THE GENITO-URINARY ORGANS.

## 1. *Protrusion of orifice of ureter through meatus urinarius in a female child.*

By N. Davies-Colley.

Fanny W—, æt. 18 months, was brought to me as an out-patient on October 9th, 1878. She was small for her age, and had always been delicate. For some time past it had been observed that she strained a good deal during micturition. A fortnight before she had had the measles, and three days before a protrusion had appeared at the vulva. On examination I found a soft mass projecting through the meatus urinarius, of a dingy reddish-purple colour, about an inch long, and half an inch thick. The urine was said to be clear, but latterly of an offensive smell. She retained it quite well.

On the 22nd chloroform was administered, and a careful exploration made. The flaccid reddish protrusion was readily unfolded, and ascertained to be of the shape of a funnel, the neck of which was placed within the urethra. The aperture of this funnel (see Woodcut 5) formed a circle 1¼ inch in diameter; its neck, which lay within the urethra, was not quite ½ inch in diameter, but when it was not upon the stretch, it shrank to so small a size that it did not fill up the whole of the urethra, which was not unusually large. The edge of the funnel was about an inch distant from the meatus urinarius, except posteriorly, where there was an interval of ½ to ¾ of an inch. The walls of the funnel were nearly ¼ inch thick, soft, shining, and of a reddish-purple colour, and resembled in appearance congested omentum. A probe could be passed into the bladder through the meatus, and could then be moved nearly all round the neck of the funnel, but not quite, from which it appeared that a part of the funnel grew from the posterior wall of the urethra. I introduced my little finger into the

vagina, and I could feel the os uteri in its normal position. I next passed a female catheter into the funnel. It went up about five inches towards the left side of the abdominal cavity, and gave exit to 4 or 5 oz. of very fetid pus. I then passed the catheter into

WOODCUT 5.

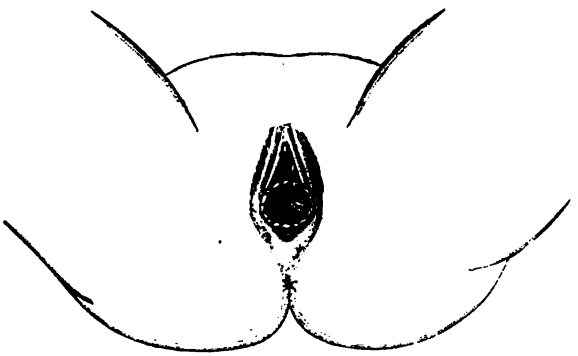

the urethra and drew off about 2 oz. of clear inodorous urine. My next step was to encircle the neck of the protrusion with two silk ligatures, in two halves, so as not to obstruct the escape of pus, and I then cut off the protruding mass.

The child appeared for a few days relieved by the treatment; she then gradually sank, and died on October 31st, nine days after the removal of the protrusion.

I am indebted to Dr. Goodhart for the account of the post-mortem examination.

The viscera generally were healthy. On removing the intestine an abscess was found in the left loin localised between the spleen and tail of the pancreas above, and the left kidney in front and below. The urethra was the size of an adult's little finger, and contained pus. It was uniformly dilated in its whole length. The kidney was converted into a series of thick sacculi with indurated walls, but there was white kidney cortex round some of the lower sacculi; they all contained pus. The organ had none of the appearances of a scrofulous kidney, but rather of one diseased by some chronic obstruction; and Dr. Goodhart believed that this had existed, and that, as a consequence of measles, suppura-

tion had occurred in the dilated cavities. The bladder was small and contained pus. At the time of the post mortem no instrument could be passed through the urethra into the ureter, as had been done during life. The vagina and bladder looked quite normal externally, and all remains of the protrusion through the meatus urinarius had disappeared. The examination of the interior of the bladder and ureter was postponed until they should have been hardened in spirit.

In January the examination was resumed.

Externally the bladder was found to be normal. The urethra was somewhat enlarged. On removing a portion of the front wall of the bladder, the mucous membrane inside was seen to be rather thick and villous, and studded with small ecchymoses, as if there had been a moderate cystitis. Around the orifice of the left ureter the mucous membrane was raised into a corrugated ridge about ½ inch high with a ragged edge. One part of this ridge was sloughy and somewhat indurated, apparently from inflammation. The rest was quite soft and consisted only of swollen mucous membrane. The lower end of the ureter itself was internally small and tortuous, and it opened into the outer and back part of an oval depression, which was smooth and apparently lined by mucous membrane. This depression was walled in by the above-mentioned ridge, and suggested to Dr. Goodhart the explanation that a renal calculus of oval shape had formerly passed as far down as the orifice of the left ureter, and had there become embedded for some time in the coats of the bladder, so as to have been partially encysted in the mucous membrane. We could thus readily account for the cystitis and perinephritis. The stone might have been at length dislodged and passed without being noticed.

The orifice of the right ureter was situated upon a nipple-like elevation the size of an ordinary pea. There was no abnormality about the right kidney or ureter.

*Remarks.*—There can be no doubt when we compare the condition observed during life with the state of the bladder after death, that the funnel-shaped protrusion removed was part of the dilated orifice of the left ureter, which had prolapsed through the meatus urinarius. The ragged ridge surrounding the orifice of the left ureter was evidently the stump left after the separation of the two ligatures, which must have been passed with the urine, as no traces of them were found in the post-mortem examination. It would appear also

that the protrusion was confined to the mucous membrane surrounding the opening of the ureter, and that there was no prolapse of the other parts of the ureter itself. At first sight the condition of the interior of the bladder conveyed the impression that it had resulted from an invagination, or, so to speak, an intussusception of the ureter into that cavity. But this view was negatived by the fact that the junction of the ureter and bladder was externally quite natural. As to the cause of the prolapse I think that no certain conclusion can be drawn. It is not unusual to find some degree of projection around the orifices of the ureters. Thus in ectopia vesicæ their openings are generally placed upon teat-like prominences of mucous membrane, and preparations exist, which show a considerable elevation of this part of the bladder. I am not, however, aware that any one has yet observed so great an elevation as must have been here present. It seems to me that this extensive out-growth, which led to the prolapse through the urethra, may have been produced by a congenital constriction of the orifice of the ureter, or by the impaction of a renal calculus. Either hypothesis would explain the dilatation of the ureter and kidney. The next step must have been that the calculus was dislodged, or that the constriction gave way, and left the opening of the ureter widely patent, and encircled by a high fold of mucous membrane. This no doubt from time to time hindered the escape of urine from the child's bladder, and caused the straining efforts, of which the mother spoke. The child's health was then depressed by an attack of measles, and suppuration occurred along the whole urinary tract. The mucous membrane became so swollen that it was expelled by a violent effort through the urethra, and the condition was established in which I first saw the child. I may add that one of the explanations given was that a villous growth had been developed around the opening of the left ureter, and had partially obstructed the passage of the urine. It might then have become prolapsed and presented an appearance somewhat similar to that described. I consider, however, that this view is contradicted by the regular shape of the protrusion, and the fact that its microscopical examination revealed only the ordinary structure of the bladder mucous membrane. *March 4th*, 1879.

---

## 2. *Cases of spontaneous disruption of vesical calculi.*

By Dr. KRAUS, of Carlsbad.
Communicated by WILLIAM M. ORD, M.D.

THE specimens now exhibited were sent to me recently by my friend Dr. Kraus, of Carlsbad, who gave me permission to exhibit them before this Society. I propose to read a communication from Dr. Kraus narrating the history of the case, and afterwards a report of my examination of the specimens.

Karlsbad, Herzog von Brabant;
13th April, 1879.

Dr. J. KRAUS.

DEAR DR. ORD.

When I saw your report on "Spontaneous Disruption of Calculi within the Bladder" I remembered a similar case I had under my care in 1874, and as I thought it might interest you to know all about it, I beg to send you the specimen with a short history of the case.

Mr. S—, a retired farmer, of Breslau, was for the first time in Carlsbad in 1873, suffering from gall stones. The man, seventy-eight years of age, even then robust and strong, was never before seriously ill, and has merely suffered now and then from constipation; he has always lived very abstemiously. He had a great benefit from his course of Carlsbad waters, and passed several gall stones after mild attacks. The urine at this time was saturated with uric acid, contained bile after each attack, but neither sugar nor albumen, and no traces of pyelitis.

In the summer of 1874 he came again to Carlsbad, suffering from kidney concretions, as his doctor in Breslau stated. He looked very well, and complained but of a dull pain in both kidney regions, and a difficulty of passing water, and of a little burning afterwards at the top of the penis. The urine, slightly acid, did not contain albumen; microscopically I found uric acid and very few pus corpuscles and cylinders. In the third week of his course the patient had a severe attack of renal colic, with most cruel pain from both kidney regions, along both ureters, down to the testicles, and to the head of the penis; on the third day he had for about ten hours

serious symptoms of uræmia, however, he got over it, and for the first time after twenty-eight hours he voided a very little thickish urine, of slight alkaline reaction, containing very little blood and pus, a good deal of mucus, and triple phosphate crystals. From day to day the urine got clearer, and became acid again. At the end of the fifth week he was strong enough to continue his course for three weeks more; and he passed at different times, with very little pain, small kidney concretions, consisting of uric acid. When he left Carlsbad he felt tolerably well, but there was still some difficulty in passing the water, owing, as I thought, to some more kidney concretions left in the bladder.

The next winter (from 1874 to 1875) I saw that patient in Brealau; he showed me, to my great astonishment, a box containing fragments of calculi; he gave me about the third part of it, and told me that his doctor had taken nearly as much as he himself had kept, so that I reckon the whole quantity of at least twenty-six to thirty calculi, each nearly of the size of a small hazel nut. He had passed all those fragments within two months after he had left Carlsbad, with more or less pain according to the size of the fragments. This man is still alive and perfectly well; no relapse of his previous diseases.

Supposing you should like to publish that case as a similar one to those already published by yourself, I have not the least objection; on the contrary, I shall be happy in having been enabled to communicate to you a case in which you will be in some way interested.

With best regards,

Yours very truly,

J. Kraus, M.D.

Dr. W. Ord.

*Report.*—The fragments submitted were about fifty in number, and varied in size from that of a No. 10 shot up to that of half a small dried bean.

They were all of a dirty grey colour. Some few—the smaller—were spherical and smooth; the greater number were evidently segmental fragments of spherical calculi, and had a ragged friable surface like dry mortar. The small spherical fragments presented in section a reddish fawn colour, and fine concentric laminar markings, with a few radiating cracks. The grey colour was limited to a very thin superficial layer, more friable than the rest.

The segmental fragments were yellowish red or dirty yellow in

section, and showed curved parallel lines, such as would belong to segmental fragments of concentrically laminated spheres. The yellow laminated portion was unconformably encrusted by an irregular layer of grey friable material, and in some of the sections cracks or fissures running perpendicularly to the lamellæ were filled in with the same friable matter.

These appearances clearly indicated that after fracture had occurred within the urinary tracts a coating of new material had invested each fragment.

*Chemical examination.*

1. One of the fragments was powdered, and a portion incinerated on platinum foil over a Bunsen's burner. It blackened without fusing, and was almost entirely incinerated, giving off a faint urinous odour.

2. The nitric acid and ammonia test gave a rich murexide reaction.

3. On heating a portion with liquor potassæ ammonia was evolved.

4. The powder was insoluble in hydrochloric acid, easily soluble in liquor potassæ.

5. Some of the friable material from the surface of a fragment was placed in water under the microscope. It was almost entirely amorphous, except that here and there a tiny bright spherule was seen. It was partially dissolved by heat, and an amorphous precipitate subsequently appeared. On the addition of acetic acid to the warmed specimen lancet-headed lozenges of uric acid appeared all over the field, and sprouted from the surface of undissolved fragments. On the addition of liquor potassæ to the powder under the microscope solution at once occurred, a transparent matrix with a few irregularly rounded markings being left.

6. The substance of the spherical calculi, and of the laminated part of the segmental fragments, gave similar reactions, save that the matrix had a stratified structure.

*Remarks.*—The examination clearly shows that the original calculus was composed of uric acid combined with a small quantity of matrix, but not at all firmly compacted; and that a deposit of urate of ammonia was superimposed on the fragments left by the rupture of the original calculus.

The second deposit was more friable, was acid in reaction, and had

no intermixture of phosphates. It was not, therefore, deposited from an alkaline urine, but from an acid urine, rich in urates, poor in colouring matter.

In three cases of spontaneous fracture which I have recorded, uric acid fragments have received a white coating of urate of ammonia mixed with phosphates, and an inference was drawn that a change from an acid to an alkaline reaction of the urine was the real cause of disruption. Here, however, we find the nuclei of calculi present, and no evidence of an alkaline era.

On the other hand, the calculi, as first formed, were very lightly compacted, and very little matrix was present. The fragments under the microscope were acted on with unusual readiness by liquor potassæ.

The second deposit was much less compact even than the first.

Now, such loosely built calculi, besides being more readily crushed by mechanical force, are likely to be more readily dilapidated by causes affecting the arrangements of their molecules.

Mr. Rainey, in his remarkable work on 'Molecular Coalescence,' has a chapter on what he calls "Molecular Disintegration." In this he describes certain small spherical bodies, which he had formed by depositing a mixture of carbonate of lime and triple phosphate in solutions of gum. These were much looser and more fibrous in their structure than similar bodies into the composition of which carbonate of lime alone entered. He goes on to state that if these calculi be removed to a fresh solution of gum, or if some of the solution of gum in which they were precipitated be evaporated, and the calculi subsequently placed in the concentrated liquor, a total disintegration of the calculi results. Here the Society will observe no new chemical influence of a solvent or decomposing kind is introduced, but the whole phenomenon rests upon a variation of the density of containing solutions.

It appears to me not unreasonable to suppose that calculi of loose consistence may be similarly affected by variations in the density of urine. In the present instance the occurrence of acid urate, lightly aggregated, encrusting uric acid, more densely aggregated and more thoroughly intermixed with the colloid matrix, is consistent with the idea of the prevalence during the latter period of a more concentrated urine.

The original calculi were evidently very numerous, the fifty fragments exhibited being only a part—about a sixth—of the quantity

passed. If, therefore, they were generally weakened in their cohesion, it is comprehensible that they may have been broken to pieces by collision with each other. That they *were* weakened in some way of the kind is strongly suggested by the fineness of their comminution. They are broken up as though by the skill of a practised operator with the lithotrite. *April 29th*, 1879.

---

### 3. *Report on specimens of spontaneous fracture of calculi within the bladder, exhibited by Mr. Croft.*

By William M. Ord, M.D.

The patient from whom the specimens were removed was a bootmaker, æt. 64, and had suffered three years before from left renal colic. For more than twelve months symptoms of vesical calculus had been present, and the urine had been often tinged with blood. He had not met with accident or shock, and, indeed, with nothing that could explain or fix the date of the fracture of the calculus.

He was admitted into St. Thomas's Hospital in great agony. The desire to pass urine was incessant, with frequently recurring paroxysms of intense pain. The urine escaped in small quantities, but not in a stream. He was not communicative, so that it was difficult to get from him anything like a clear history of his case, but it was elicited that he had passed small calculi at different times, about fifteen in all. On sounding the bladder, numerous concretions were discovered, collected at the neck of the bladder, which contained but little urine. The urine was purulent, offensive, and albuminous. An attempt was made to evacuate the bladder by Bigelow's apparatus, as the patient had a great aversion to a cutting operation. Ether having been administered, the meatus was divided; a stricture detected in the bulbous part of the urethra was dilated; but the apparatus could not be used effectually. The operation being followed by aggravation of his symptoms, lateral lithotomy was performed, and a number of calculi and fragments of calculi removed.

The patient was scarcely conscious at the time of the operation and died the next day without having rallied.

The specimens are forty in number, and are all either fragments or mutilated calculi. The largest weighs 190 grains, and would, if perfect, have weighed 230. An examination of the pieces makes it clear that they result from the disruption of three calculi. There are three masses, larger than the rest, containing each the nucleus of an oval, somewhat flattened calculus. The largest of these has also received the least damage.

A segment of an outer crust, about one sixth of an inch thick, has been chipped away about half round its equator, leaving a chasm, the floor of which is formed by the convexity of an oval mass within, and the sides of which are perpendicular to the surface of the calculus. The fracture is not new; the surfaces are roughly crusted with subsequent deposit, and the edges are a little worn. We may infer, therefore, that the fracture occurred at least several days before the extraction of the calculus.

The other two fragments enclosing nuclei are more broken, and both display the same arrangement. They have an outer crust exactly resembling the outer crust of the large calculus, a middle layer agreeing with the part visible in the floor of the fracture in the large calculus, and an oval nucleus, about half an inch long and a quarter of an inch thick, perfectly distinct from the middle layer.

The outer crust is in all purplish, and slightly tuberculated on the surface, pale yellow, or light fawn colour in section and fracture, and is tolerably hard; it is scratched by the point of a sharp knife, but does not arrest the knife. The middle layer is more friable and porous; it has a bright yellow or orange-coloured fracture, and yellow section; the knife point sinks into it with very little pressure. The nucleus is hardest of all, and is polished by the saw in section. It has a brownish or mahogany tint, and is only lightly scratched by the knife point. There is a distinct though very narrow chink of separation between the nucleus and middle layer, and a less marked gap between the middle layer and the crust; at the points of fracture, however, the separation is well marked. The smaller fragments correspond to both middle and outer layers, most to the outer. Some of them are much worn. All sections show concentric lamination. Chemically the layers all consist of uric acid, with a very little urate of ammonia, which is combined with an organic

matrix in the outer layer and nucleus, not so combined in the middle layer.

The physical constitution of the layers is far from uniform. In the outer layer and nucleus the uric acid is intimately incorporated with the matrix, so that the two form one structure, showing, under the microscope, radiating crystalline fibration and transverse laminar markings—the laminar markings taking the course of the concentric lamination visible on the surface of radial sections when viewed by the naked eye. There are no separate crystals or spheres. This arrangement is what usually prevails in firm uric acid calculi.

The middle layer consists microscopically of deeply tinted rhombohedra and rounded crystalline forms aggregated in a perfectly irregular way, as the crystals are aggregated in sugar candy. Separate rhombohedra, quite perfect, can be easily separated from the mass. This is the condition prevailing in calculi where there is little or no matrix present. It is only when a considerable proportion of colloid is associated with the uric acid that cementation and homogeneity are obtained.

The presence of this easily crushed and incoherent layer between the two harder layers offers manifestly a condition favorable to fracture when two or three calculi of about the same size and of the same constitution are present in the bladder together. They crack each other's shells like eggs carried loose in a bag. Finally, it must be noted, that the latest deposit in the larger calculi contains, besides urate of ammonia, triple phosphate, an evidence of an alkaline state of urine existing subsequent to their fracture.

*April 29th*, 1879.

### 4. *Suppurative phlebitis of the vesical, iliac, and femoral veins of the left side following cystitis.*

By W. J. WALSHAM.

MR. WALSHAM showed the bladder, urethra, ureters, kidneys, and the vesical, iliac, and femoral veins of the left side, which were removed from a patient who died under his care in the Metropolitan Free Hospital of cystitis and blood-poisoning. The interest in the specimen lay in the condition of the veins, which were filled with purulent thrombi, the result, it was submitted, of the cystitis.

Thrombosis of the pelvic veins, Mr. Walsham remarked, was not uncommon after operations on the pelvic organs, after parturition, and in patients who had died of chronic exhaustive diseases, but he had not observed such a state of the veins in conjunction with cystitis, neither was he aware that an account of any similar condition had been published.

The history of the case was briefly as follows:—A. B—, a man, æt. 55 years, was admitted into the Metropolitan Free Hospital on December 16th, with a severe compound fracture of the tibia and fibula. He had led an intemperate life, and gave a history of gonorrhœa and syphilis. There was no definite history of any affection of the bladder. The fracture, which presented nothing particularly worthy of remark, progressed favorably till Christmas week, when his bladder, unfortunately, became over-distended, a condition of which he neglected to inform the house-surgeon for two or three days. When discovered, the distension was relieved by a catheter. Cystitis, however, supervened in spite of treatment, and gradually increased in severity. Three days after the relief of the bladder, the left leg became œdematous, the œdema extending upwards to about the level of the groin. The patient now exhibited signs of blood-poisoning, but no metastatic abscesses were discovered. He died January 25th.

An examination of the body was made twenty-four hours after death, and the bladder, with the urethra, ureters, and kidneys, together with the pelvic, common and external iliac and femoral veins of the left side, were removed *en masse*. The mucous mem-

brane of the bladder and posterior third of the urethra was acutely inflamed and slightly encrusted with phosphates; the inflammation was most intense immediately behind the prostate. The muscular coat of the bladder was hypertrophied. The prostate was congested, but not enlarged. The ureters and pelves of the kidneys were dilated and filled with purulent fluid. The vesical and prostatic plexus of veins were filled with clots; the clots, however, did not extend into the veins over the upper fundus of the bladder, nor into the dorsal vein of the penis.

On the right side the clots were, for the most part, adherent to the vein-walls, and partially decolorised, but they were not purulent, and did not extend into the right internal iliac vein. No other veins on the right side were affected.

On the left side the veins coming from the neck of the bladder and prostate were, for the most part, filled with purulent thrombi, which extended through the internal iliac and common iliac veins to the junction of the latter with the common iliac on the opposite side. They also extended downwards into the left external iliac and femoral vein and many of its branches. The vein-walls and tissues surrounding the veins presented the characters ordinarily observed in suppurative phlebitis. Deep in the upper third of the thigh, in the course of the profunda vein, which was also filled with thrombus, was a large abscess, no signs of which were, however, apparent during life.

The other organs presented nothing particularly worthy of remark.

The question raised with regard to this specimen was, whether the cystitis stood in relation to the phlebitis as cause to effect. It might, of course, be said that the phlebitis occurred independently of the cystitis, as the result of exhaustion and of blood-poisoning consequent upon the compound fracture. The patient, however, up to the time of the supervention of the cystitis, did not appear particularly exhausted, and did not exhibit any signs of blood-poisoning, but up to the time of the commencement of the cystitis was progressing favorably in all respects. The fracture was granulating healthily, there was no bagging of pus around the fragments, and the glands in the groin were not enlarged. Had the phlebitis occurred on the right side it might have been attributed to the extension of a clot from the seat of injury.

Looking to the history of the case, and to the fact that the

thrombi could be traced into the small veins coming from that part of the bladder at which the inflammation was most intense, the vein mischief may fairly be regarded as consequent upon that of the bladder. Moreover, from what is known of the inflammatory causes of phlebitis, thrombosis of the pelvic veins consequent upon cystitis is a condition no other than what might be expected. The present case bears a close resemblance to the cases mentioned by Drs. Wilks and Moxon of suppuration in the pelvic veins followed by pyæmia, consequent upon gonorrhœa, without abrasion of the mucous membrane of the urethra.

It is difficult to offer an explanation why the clots on the right side should have become organised whilst those on the left became purulent. *April 29th*, 1879.

---

5. *Gangrene of the entire corpora cavernosa and spongiosum penis, probably from thrombosis of the iliac vein consequent upon rheumatic phlebitis.*

By John Gay, F.R.C.S.

G. W—, æt. 31, a cabinet maker, was admitted into the Great Northern Hospital on the 8th of March under Dr. Leared, and was transferred to my care on the 15th. He had enjoyed fairly good health, and had not, as he said, had syphilis or other form of venereal disorder, but was not robust. Six years ago he had a severe attack of scarlet fever. On the 1st of March he was attacked with acute tonsillitis, but only discontinued his work on this account for four days. He then worked in wet clothes, when, on the 8th, he was obliged to give up on account of pain in his left knee and ankle, which, by the 15th, had spread to the calf and sole. The left and then the right upper eyelid became œdematous. His skin was hot and feverish. Pulse 110, temp. 100°, and urine acid. The calf of the leg now swelled considerably, had a dusky appearance, felt brawny, and pitted slightly on pressure; whilst a few swollen veins made their appearance on the inner and upper side of the limb.

On the 17th some spots, like purpura, were observed in the neighbourhood of both elbow-joints. The pain in the calf was now severe on pressure along the course of the external saphena, and in the course of another twenty-four hours extended along the femoral vein as far as the deep perineal region. The swelling in the leg now began to subside; but the penis became distended and rigid, and the glans of a dusky hue, whilst the integuments retained their natural colour, but became in the highest degree œdematous. The respiration was hurried—26 per minute, but without abnormal chest-sounds; temp. 101°; pulse 120.

On the 19th the colour of the glans deepened into a brownish black; and a puncture gave exit to a small quantity of bloody fluid only. The integuments were still living, but the cavernous and spongy bodies had perished in their entirety, and at the end of ten days were removed as a slough. The skin shrunk, and as it became flabby, and the flow of urine over it caused ulceration, a portion was removed, enough to leave a convenient stump for the purpose of micturition.

The clinical aspect of the case is surely rheumatic, metastatic in its form, shifting about from one part to another—but principally confined in its movements to the left side of the body—from the joints to the orbital periosteum, and settling finally in the saphenous, femoral, and iliac veins, in the latter of which the blood became thrombose. The especial proneness of the external saphena to become the seat of rheumatic phlebitis is well known; but the nature of such an attack is not always, I think, recognised, and it is not unfrequently passed over as one of muscular rheumatism, until supervening pneumonia aids and corrects the diagnosis.

In the case narrated, with obstruction of the veins which conveyed the blood from the trabecular and spongy tissues of the penis, and its refusal of an outlet into the superficial veins, their venous spaces became rapidly filled to repletion, and the blood stagnant and thrombose.

In order to show the want of accommodation on the part of the tegumentary to the deep veins in the event of their being obstructed, Mr. Pearson injected a penis for me as fellows:—The dorsal artery was first injected with red wax. It ran freely into the spongy body and glans; but scarcely at all into the cavernous bodies or integuments. Two or three short and minute arteries ran up over their fibrous envelopes. The main dorsal vein was then injected

backwards with blue wax. The injection ran into the glans and spongy body, and returned by other veins on the dorsum of the organ. In the glans the injection filled four distinct plexuses, which were kept apart by partitions of dense fibrous material, which vertically intersected that body at right angles to each other.

A large vein in one crus was now injected, also backwards, with yellow wax. It rapidly filled the whole of the corpora cavernosa, and returned by other veins on its cut surface. On hardening, their trabecular tissue presented a beautifully convoluted mass of small veins—not an assemblage of distinct spaces—interwoven in the most tricate fashion, and completely occupying the fibrous envelopes.

The venous arrangement in the penis, then, resembles that in the limbs and in the heart *so far* that injection or blood cannot pass from the deep into the superficial or tegumentous system of veins. I was unable, however, in this instance, to inject the tegumentary veins; and therefore it remains to be seen, when another opportunity offers, whether the reverse will hold good; viz. that, from the superficial, the stream will run into the deep veins, according to the segment of the organ injected. In all probability this would be the case in conformity with the arrangement in other parts. Thus the currents from the *deep structures* of the penis have no outflow but through the *deep* or *systemic veins*, towards the heart; so that obstruction in these is fatal to the supplying structures, but not to their tegumentary covering. The case illustrates the essential difference between the two forms of gangrene—that from local embolism or thrombus; and the other from defective central or cardiac power. *November 19th*, 1878.

## 6. *Recto-vesical fistula, septicæmia; terminating fatally.*

By Alexander Morison, M.D.

A few cases of entero-vesical fistula in the male have been published by Mr. Bryant,[1] and others, in some of which colotomy seems to have afforded relief; but such cases are so rare, that notwithstanding Mr. Holmes's[2] attempt to indicate signs for the localisation of such abnormal communications between the bowel and bladder, the diagnosis of the exact seat of the lesion is still a difficult matter. In this case the site of the fistula was determined with so much uncertainty, that colotomy was never seriously contemplated.

R. J. B—, æt. 50, doctor of medicine; somewhat stout, but actively engaged in private practice, was a generous though wholesome liver, and especially addicted to fish eating. When about forty years of age he had phlebitic cording of the right saphena vein, but had otherwise enjoyed good health.

His family history was unimportant, except that, curiously enough, a brother, who died young of tubercular phthisis of the lungs and mesentery, suffered from entero-vesical fistula.

In September, 1874, when 47 years of age, the patient first felt some rectal discomfort after urination; and a month later he had a severe attack of pain over the pubis, and in the left hypogastric and iliac regions, but without uneasiness either in urination or defecation. In about ten days a muco-sanguineous stool, coincided with the disappearance of discomfort. A period of relief from pain, only broken occasionally by slight hypogastric discomfort, was succeeded in March, 1875, by a more severe attack of pain, which was localised just above the pubis, and in autumn of the same year urination first became painful. This now became the most prominent symptom. The pain was most severe just before and during the act, with relief after it.

In January, 1876, the dysuria continued, and the urine contained

[1] 'Med.-Chir. Rev.,' Jan., 1869.

[2] 'Med.-Chir. Trans.,' vol. xlix, p. 65.

many leucocytes. In the end of the same month, for the first time, a congeries of fine air bubbles was seen to issue from the orifice of the urethra after micturition, and to cling around it.

In March, 1876, a viscid drop entangling air bubbles was placed under the microscope and seen to be crowded with spermatozoa; and in the same month, a small portion of vegetable matter, having a faintly feculent odour, was passed per urethram, and air bubbles began to increase in size, but urination became less painful.

In April, 1876, the patient had a severe attack of vesico-rectal pain, with the passage of a small quantity of foreign matter per urethram accompanied by air. Air then ceased to pass for a few days, and again made its appearance, as if temporarily prevented from passing by swelling of the usual route, again appearing on the subsidence of such swelling.

The patient continued free from discomfort till September, 1876, when, after a hard stool, he had a severe attack of vesico-rectal pain.

In December, 1876, a little blood passed per urethram, and was followed by a mild inflammation of the left testicle, and the passage of a large quantity of flatus through the urethra. In August, 1877, blood again passed by this canal after copulation; and some hard scybalous excrement having been voided next morning, a severe right orchitis followed. While confined to bed with the latter, and apparently in consequence of lying on the back, the passage of flatus per urethram became unusually abundant, but diminished when the sitting posture was assumed.

The patient always knew when air was about to pass per urethram by feeling what he termed a "shoot" into the perineum, followed by another and another, until, as he said, some pouch seemed to be distended, when air escaped per urethram, the urethra itself becoming tender by the passage of flatus. The urethral flatus was always odourless. Urine was never known to escape per rectum. From this date till that of his last and fatal attack in December, 1878, the patient enjoyed comparative freedom from pain, and as familiarity with, had gradually bred contempt for, his symptoms, he seldom mentioned them.

I have therefore no exact notes of his condition till the second week of December, 1878, when he was apparently in robust health. He had taken a hearty lunch, and was about to visit his patients, when he witnessed the dismemberment of a cat by a pack of grey-

hounds in his garden. This so agitated him as apparently to arrest digestion, and the result was a smart attack of diarrhœa followed by his old urinary symptoms, which confined him to bed for a few days. He then resumed his duties, but continued to be uneasy and in pain; the latter gradually increased. There was tenderness on pressure between the anus and the penis, and on digital examination a swelling was detected in the position of, and in shape like, an enlarged prostate. The gland appeared to be most swollen in its left lobe, and communicated to the finger an obscure sense of fluctuation or elastic tension on this side.

I met Mr. Hutchinson in consultation, who examined him while under the influence of chloroform, and determined the same points. He also passed a catheter, as urination was much obstructed by the swelling, and then detected great thickening of the membranous urethra; so much so, indeed, that the catheter could not be felt with the finger in the rectum. During the night following this examination the patient, while out of bed attempting to urinate, said he felt something give way, or burst, in the neighbourhood of his prostate, after which the obstruction to urination appreciably diminished. A little later, about 3 a.m., he had a severe rigor, in which he became delirious, the attack being followed by fever and profuse sweating; the temperature in the axilla was 103°, and his pulse about 120 per minute. During the next two days the rigors were repeated, and I met Mr. Hutchinson again on the 25th of December, when, in addition to his other symptoms, a swelling or fulness was detected in the perineum, limited posteriorly by the anterior verge of the anus, in front by the bulbous portion of the urethra, and latterly by the attachment of the deep fascia.

On the 26th of December there were no rigors, but increasing fulness in the perineum, with œdema of the scrotum.

During the 27th he remained free from rigor, but the swelling and œdema increased, passing upwards in the direction taken by extravasated urine, and the left saphena vein became hard and painful from the groin to the knee. On the evening of the 27th he had again a severe rigor; and although no distinct fluctuation could be detected in the perineum, Mr. Waren Tay was consulted, in Mr. Hutchinson's absence, with the object of incising the swelling if thought proper. After careful examination under chloroform, it was concluded that although no distinct fluctuation was appreciable, the elasticity of the swelling, and œdema of the surrounding subcu-

taneous textures, rendered the presence of fluid probable, and its evacuation desirable. Mr. Tay likewise determined that the prostate was apparently normal. He accordingly incised the swelling in the middle line of the perineum, and immediately a thin, dark brown, almost black fluid, of an intensely feculent odour, and at least an ounce in quantity, gushed out of the wound, appearing almost as if a large vein or spongy vascular structure had been cut into. When this had escaped, the finger passed through the wound, entered a sac which passed backwards towards the rectum and forwards towards the inguinal regions.

The two following days the patient was better in every way, pulse and temperature normal, no rigors, and urination, which was again becoming more difficult as the perineal swelling increased, became easier. On December 30th the patient again had rigors, and became worse in every way. His stools, which had been fluid, increased in frequency, flatus passed profusely per urethram, and the urine became fæcal, sometimes very turbid and decidedly fæcal, and again clearer and less so. On the evening of the 30th the stools became dark-coloured, and contained numerous small clots of blood; the urine also occasionally had the same bloody character as the fæces. Early on the morning of the 31st the patient lost blood somewhat profusely, and principally from the perineal wound. After the bleeding had stopped, a clot was seen to protrude from the wound, and by the finger was felt to occupy the same cavity in the cellular tissue previously occupied by the feculent fluid. This clot, which obstructed urination and gave pain was removed by the finger and the cavity washed out. The general condition of the patient was now one of collapse; a profusely sweating, clammy skin, weak, frequent pulse, and semi-coma. On attempting to wash out the bladder with a disinfectant solution, it was noticed that not so much water returned from the bladder as was poured into it, and also that as water was poured into the catheter, clots were washed out of the perineal wound, indicating a communication of the perineal cavity with the urinary apparatus. The patient died on the 2nd day of January, 1879, eleven days after his first rigor.

*Necropsy.*—Mr. Cantlie, of the Charing Cross Hospital, kindly examined the body after death.

The left saphena vein and most of the veins in the left half of the pelvis were plugged with dark clot, as also was the dorsal vein of the penis. The intestines and stomach were distended with gas.

The sigmoid flexure of the colon was thickened and narrow. About the junction of the first and second portions of the rectum the gut was constricted by a narrow, membranous, thickened band, so that its lumen at this point just admitted the tip of the little finger. Above and below the point of tightest stricture the gut was appreciably narrowed in all for about three inches. As the rectal mucous membrane approached the constriction, and above as well as below the latter, there were several deep pits or recesses in its surface, which appeared to be caused by puckering of the mucous and submucous coats by the shrinking of inflammatory products. These pits were all blind except one, and some were roughened at their blind extremity as if by ulceration. Just above the narrowest point the probe passed into one of these recesses, entered a pouch about the size of a walnut between the rectum and the back of the bladder, and thence by a small opening in the latter, at a spot about two inches from the commencement of the prostatic canal. The walls of the pouch were apparently formed by the inflammatory matting of recto-vesical cellular tissue.

The mucous membrane of the bladder was of a slate-grey colour, and the organ itself contained a quantity of feculent mucus.

The prostate was normal.

The bulb of the urethra was quite broken down. In the membranous portion of the canal there was a large perforation about the size of a cherry stone, which communicated with a sac in the pelvic cellular tissue between the rectum and prostate, the anterior wall of which had been laid open by the perineal incision, and from which the dark feculent fluid had thus been evacuated.

There was cystic enlargement of the right seminal vesicle, while the left was normal.

The condition of the other organs was unimportant, beyond the fact of their all showing more or less fatty infiltration. There were no metastatic abscesses anywhere to be detected, but there was some recent lymph on the surface of the left pleura and both pleural cavities contained serous fluid.

*Remarks.*—The unusual nature of this case would, and did, afford scope for much discussion on points of diagnosis and etiology, but with such I shall not weary the Society. As the probable chain of events, however, I would suggest the following:

(1) Entanglement of a fish bone or other irritating material in a fold of the rectal mucous membrane.

(2) Inflammation with a circumscribed abscess in the recto-vesical cellular tissue at a corresponding point.

(3) Escape of the abscess into the bowel.

(4) Escape of flatus into the cavity of the abscess with as much emphysematous extension as surrounding inflammatory matting would permit.

(5) Communication of this recto-vesical pouch, possibly by ulceration of its vesicle boundary with the bladder, hence escape of flatus per urethram.

(6) Stricture of the rectum by inflammatory irritation in the neighbourhood of a fistula passing between the two such active structures as the bladder and rectum.

(7) Increased passage of flatus per urethram, and obstructed defecation producing scybala, in consequence of stricture of the rectum, and with this, increased distress and the irritative sequelæ, cystitis, orchitis, &c., in the genito-urinary apparatus.

(8) Owing to the final attack of diarrhœa, possibly from the escape of fæcal matter into the recto-vesical pouch aforesaid, another abscess in the recto-prostatic cellular tissue, with gradual erosion of the membranous urethra, possibly some urinary infiltration, and the left-sided phlebitis and venous plugging.

(9) Escape of the contents of this second pouch into the perineal cellular tissue, followed by septicæmia and death.[1]

(10) Wisdom after the event suggests that colotomy during a quiescent period might possibly have been curative in this case, and a deep perineal incision, guided by the staff, or puncture per rectum, beneficial during the final attack *May 20th*, 1879.

[1] When this collection was circumscribed, to Mr. Hutchinson's finger and to mine it felt like an enlarged left lobe of the prostate. After it became diffuse, Mr. Waren Tay touched a normal gland.

## VI. DISEASES, ETC., OF THE OSSEOUS SYSTEM.

### 1. *Specimens of craniotabes.*

By Thomas Barlow, M.D.

These two specimens are the occipital and left parietal bones taken from the skull of a female child, aged seven months, who had been under the joint care of Dr. David Lees and myself at the Hospital for Sick Children, Great Ormond Street. They are examples of the condition first described by Elsässer as craniotabes. Above the right superior curved line of the occiput are two spots, one the size of a linseed, the other of a Spanish bean, below this line is another, intermediate in size, and above the left external angle, coming to the margin, is a fourth spot. At these spots the bony material seems to have almost disappeared and left only a thin membrane. The hollowing out is more marked on the inner surface of the bone than on the outer, thus, on drawing the finger along the outer surface by touch alone it is not easy to appreciate all the spots.

The bone below the inferior curved line is deficient in earthy material, so that it is easily bent like a piece of cartridge paper, but it is not transparent and thin like the spots. Both these conditions are described under craniotabes. The second is much more easily appreciable during life than the first.

The parietal shows three translucent spots of craniotabes near the posterior border of the bone. The greater amount of absorption of bony material from the inner surface as compared with the outer is very marked in the spots.

Craniotabes has been so long described that I should not have thought it worthy of the Society to bring these specimens but for the sake of raising the question as to its diagnostic value. It has been claimed by Vogel as one of the earliest and most characteristic signs of rickets; but let it be noted that in the classical lectures of

Jenner on that disease it finds no place as a distinguishing feature. In the joint observations that Dr. David Lees and I have been able to make we have found it (1) not common in pure rickets, (2) not at all special to rickets, (3) very common in congenital syphilis. The child from whose skull these bones were taken was not rickety. She had very slight enlargement of the anterior ends of the ribs, on the inner surface only, but no more than I believe is physiological. She had no chest deformity, or enlargements at the ends of the long bones. She was pre-eminently a tubercular child, and was found, *post mortem*, to have tubercle, caseous and recent, of the brain, lungs, bronchial glands, and intestine.

In No. 1 of the skulls taken from children the subjects of congenital syphilis—shown this evening—will be seen also in the parietal and occipital bones spots of the circumscribed translucent form of craniotabes. *March 4th*, 1879.

---

## 2. *Specimens of disease of skull in congenital syphilis.*

By Thomas Barlow, M.D.

No. 1. This skull was removed from the body of a female child who had been an out-patient of mine at Great Ormond Street. There was a history of rash and slight feverishness in the mother in the early part of her pregnancy, not enough to cause her to lay by. The patient was an eight months child. When two months old she had "snuffles," at two and a half months slight splenic enlargement, and at three months collapse of the bridge of the nose, which later on became very marked. At nine months she began to manifest the very pronounced cachectic appearance which is so often found in syphilitic children, even after local signs of the disease have disappeared and the spleen has retreated. At this time I began to notice the head, which showed to perfection the four bossy prominences surrounding the anterior fontanelle as described by M. Parrot. I was then sceptical as to the specific character claimed for such a shape of skull, and looked upon it as being

rickety in its nature. At ten months the child died of sheer marasmus, the spleen having quite retreated, but the dirty white pallor was still marked. During the last few days only there was slight vomiting and diarrhœa.

At the *post mortem* there were no naked-eye signs of visceral disease. The skull showed on stripping off the scalp an appearance such as I have never seen in any ricketty skull. The four broad masses felt during life were of deep maroon colour, in marked contrast to the rest of the skull. The greater part of both frontals was thickened, and measured quite one third of an inch on section (*vide* Pls. XVIII and XIX). The thickening of the parietals was present not only behind the fontanelle, but extended backwards nearly to the end of the inter-parietal suture for a breadth of three quarters of an inch on one side, and half an inch on the other. Also the lower part of each parietal and a bit of the posterior part showed thickening. But the parietal eminence on each side, and an area surrounding it of the size of a crown piece, was not thickened. The suture between the right parietal and the right frontal was firmly bridged over, so that on section it was impossible to tell where the two bones joined, although on the outer and inner surfaces respectively there was slight indication of the suture in the shape of a shallow groove. Below the "parietal eminence" on the left side there were two small oval spots of craniotabes, where only a thin lamina of outer table was left, and the inner table disappeared. Another spot of craniotabes existed close to the suture of the left parietal with the occipital.

The occipital bone was thickened in its upper two thirds, but to a very much less extent than the parietals or frontals. It presented two small spots of craniotabes.

The periosteum over the thickened portions of skull was not specially thickened or vascular, or unduly adherent or the reverse.

After the cranium had been dried the outer surface of the thickened portions was seen to have a finely granular appearance as compared with the normal bone at the parietal eminence, which was quite smooth. There was no change of the inner table. The bone was sawed very easily. At one place there was indication of separation into horizontal layers with close set vertical trabeculæ between; for the most part it was light and granular in consistence.

The dura mater and brain were healthy.

The long bones were not dissected out. There was no marked

## DESCRIPTION OF PLATE XVIII.

Plate XVIII illustrates Dr. Barlow's case of Calvaria from a Child the subject of Congenital Syphilis. It shows extensive but circumscribed thickenings (osteophytes) of frontal and parietal Bones. (Page 333.)

a lith.

Mintern Bros imp

## DESCRIPTION OF PLATE XIX.

Plate XIX illustrates Dr. Barlow's case of Calvaria from a Child the subject of Congenital Syphilis. (Page 333.)

Internal surface; osteophytes affect the frontals, parietals, and to a slight extent the occipital.

There are two spots of craniotabes shown at the posterior part of the eft parietal.

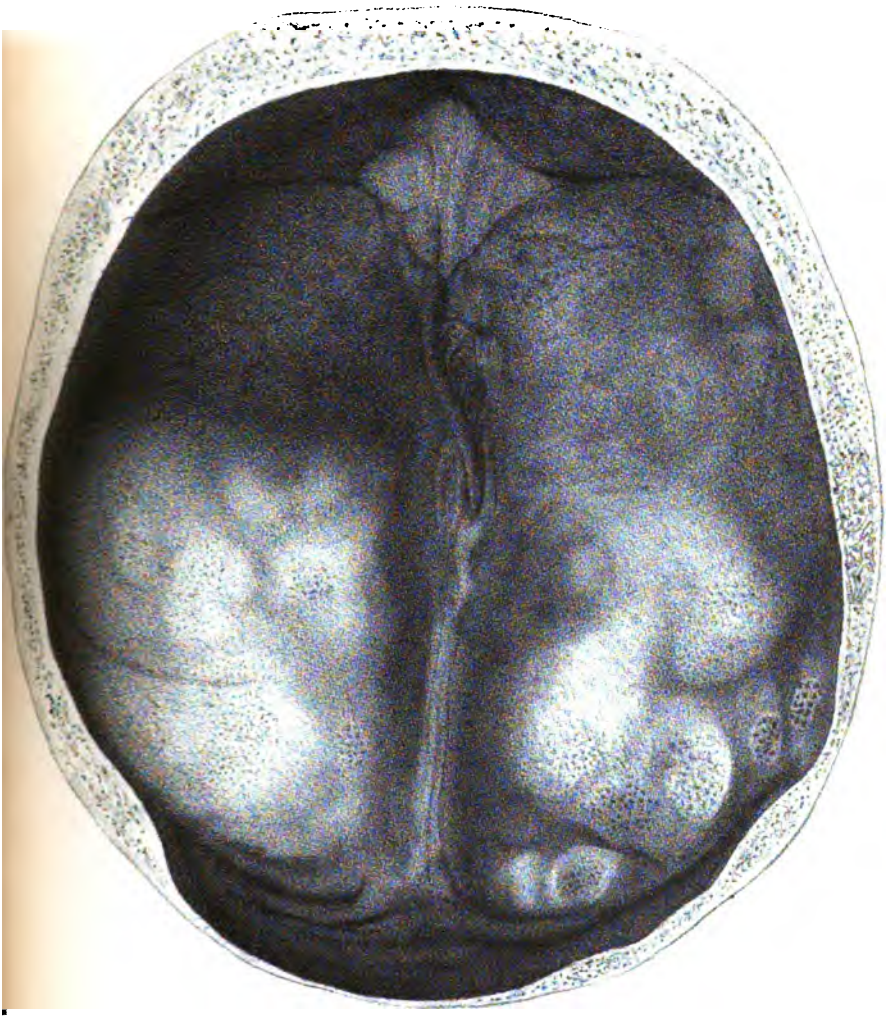

R. Mintern lith.

Mintern Bros imp.

enlargement of the ends, and the enlargements at the sternal ends of the ribs were only slight.

No. 6. This skull, taken from a child aged eight months when he died, shows many similar characters to those found in No. 1, but in less degree. On removal of the scalp slight maroon-coloured eminences were seen in front of the fontanelle. On stripping up the periosteum, which was a little thicker and more vascular than usual, these eminences were found to consist of granular spongy bone-material, very sharply defined at the lower and outer parts of the frontals from smooth healthy bone. There was premature synostosis of the two frontals. The thickness on section, taken at the spot where the inter-frontal suture ought to have been, was nearly one third of an inch. Here three horizontal layers at least could be made out with trabeculæ between.

On the parietals there were no definite bosses just behind the fontanelle, but behind the anterior margin of each was a narrow band of raised granular bone becoming slightly massed up behind the lower anterior angle. There was also a thin deposit on each side running parallel to the sagittal suture at a little distance from it. This deposit expanded out posteriorly. In front of the lambdoidal suture on each side, but to an unequal amount, there was also massing up of granular bony material. The parietal eminences were perfectly smooth.

The occipital to a slight extent was thickened a little below the lambdoidal suture.

In both parietals and frontals it may be stated that the thickenings, though in a rough sort of way symmetrical, were by no means absolutely so either in thickness or outline. The broad sinuous pattern produced by these osteophytes is quite remarkable, and differs entirely from the surface of a healthy infant's skull.

The only important visceral changes to be noted were some smooth, skimmed milk-like opacity of the pulmonary pleuræ, and very decided enlargement of the spleen, the substance softer than usual, and the capsule showing two small opaque patches on it.

It is important to state that the chest was not at all deformed either vertically or transversely. There was no beading on the external surface of the ribs, and to no more than a physiological amount in one or two of the lower ribs on the inner side. In fact rickets in this child could be absolutely excluded.[1]

[1] Slight internal beading of ribs, especially of the 5th, 6th, and 7th, is, I

The full history of this child I did not obtain until after his death. It was as follows:—He had been born "with a cold," and when fourteen days old had "thrush," which extended from the nates to the toes, and lasted several weeks. For a time it was said that the child was "tender" when his knees were touched. He had been from the first suckled by a wet nurse, who brought him to the Children's Hospital when he was five months old. At that time there were no signs of congenital syphilis so far as the skin was concerned. He had splenic enlargement, a certain amount of pallor, some purpura, a little bronchitis, and was passing one to three greenish stools daily. He had no specific treatment. He remained *in statu quo* for a while, and died rather suddenly, the immediate cause not being quite clear. Like case No. 1 I have now no doubt that he suffered from the syphilitic cachexia which supervenes after many of the local signs have subsided. It is important to note that the child having been suckled from the beginning by a woman whom, as far as we could see, was healthy, the ordinary cause of rickets could be excluded, and as I have stated the *post-mortem* appearances also excluded rickets. We had not noticed anything special about the head until at the *post mortem* we observed before the removal of the scalp some "bumpiness" of the frontal in front of the fontanelle. This was a very different thing, as will be seen from the specimen, from the great square forehead observed in some rickety children of two years old and upwards. Such an elevation, corresponding as it was proved with so much thickening, and with premature bridging over of the interfrontal suture, and especially taken with splenic enlargement, would in future lead me to treat a case as congenital syphilis even if the early history should be wanting.

No. 3. This skull was taken from a female child æt. 3½ months when she died. There are no eminences around the fontanelle, but the anterior part of each parietal shows a sinuous band of slight thickening where the bone has a stippled surface in contrast with the smooth parietal eminences. The frontals are stippled over a

believe, physiological. I have found it even in several inspections of stillborn children. Slight external beading in these ribs is also very common in healthy children who have been mainly fed by the breast. With respect to thoracic evidences of rickets it appears to me that the vertical groove on each side external to the beads, and the transverse groove corresponding with the attachment of the diaphragm slightly more marked on the left than the right side, are the signs to which weight should be given.

larger area than the parietals, but still only to a slight extent. The bone is, however, thickened and shows several horizontal layers. The changes are so slight that one would hardly have noticed them except in connection with the other specimens, comparison with which will show that they are like in kind though less in degree. Other syphilitic changes found in this child were two gummata in the liver, thickened opaque patches on the capsule of the spleen and disease of the basilar artery.

The history gave the child's illness as beginning at one month old when she had an eruption which, from the hands and feet, peeled off like fish scales, but which, on the hands and body, was followed by small discharging sores.

When first brought to the Children's Hospital, at 3½ months old, she had a collapsed root to the nose, the café au lait complexion and small ulcerating skin lesions on the head, trunk, and nates, and was extremely asthenic. The next day she died.

No. 4 is a piece of one parietal removed from the skull of a child aged about 12 months, by Mr. Day, Resident Medical Officer of the Infirmary for Children, Waterloo Road to whose kindness I am indebted for the loan of the specimen.

The bone resembles very much in characters the first specimen shown, but is more differentiated. The outer layer is granular and spongy, there are several horizontal layers with vertical trabeculæ between; the inner plate is normal.

Mr. Day has told me that the same condition obtained in the frontals and the occipital. There was no definite visceral disease. Though marasmic and anæmic the child was not rickety, but from the condition of the bones of the skull Mr. Day was led to believe that she was syphilitic. He was unable to get any history of *any* kind from the parents, and he had not seen the child during life. This specimen therefore cannot be brought forwards as a proof of the specific nature of the lesion, though, from the resemblance of this to the other specimens I have no doubt as its being an example of the same disease.

*Remarks.*—Disease of the cranial bones in infantile syphilis has been studied by Wegner and others in Germany, and by Taylor in America, but M. Parrot was, I think, the first to draw attention to it as a definite lesion to be recognised during life, and it was to a resumé of his researches given in 1877, at the Havre Medical Congress that I owe my knowledge on the subject. He then occupied

himself mainly with the hypertrophic forms of congenital syphilitic disease of the cranial bones. Briefly his main propositions were these:—At variable periods chiefly in the first two years of life osteophytic growths appear on the outer surface of the cranial bones. They appear in definite positions, viz. at the boundaries of the anterior fontanelle on the frontals and parietals extending backwards to a variable extent parallel to the sagittal suture.

At the outset they are lens-shaped elevations of a red or violet colour; porous in character and grooved by vascular channels. They may gradually extend and cover the greater part of the cranium leaving, however, the parietal eminences intact. In their progress these osteophytes not unfrequently bridge over the sutures and thus cause a premature union. By the superposition of successive layers the cranial wall may become greatly increased in thickness. The new bony material is developed from the deeper layer of the periosteum and instead of there being true bone corpuscles with canaliculi and arranged around Haversian canals there are spaces with connective tissue corpuscles furnished with a certain number of prolongations which communicate with one another, and with the medullary spaces.

M. Parrot has described, also, an atrophic lesion of the bones of the cranium, in which there is what he styles a gelatiniform transformation of the bony material. This I have never seen, but I have once made a *post mortem* on a syphilitic child, aged four months, in whom there were true ulcerating nodes of the cranium, and their characters were altogether different from those of the osteophytes here shown. There had been during life doughy swellings in several areas over the frontals, parietals, and temporals. Some receded; some suppurated. At the *post mortem* all stages were seen. In one or two areas there was great swelling and vascularity of periosteum, which stripped off easily from the bone. In other places very slight superficial worm-eaten ulceration of bone, and in others destruction of bone down to the dura mater.

To call the diseased condition which I have shown in these skulls periostitis seems to me a misnomer. Although no doubt originating in the deeper layers of the periosteum, it is really a hyperostosis depending on an altered pattern of nutrition, and not in the ordinary sense an inflammation, as the case I have just narrated certainly was.[1]

[1] So far as I have observed these cranial osteophytes (to adopt M. Parrot's term) are not attended with any tenderness on pressure.

It is only fair to state before concluding this paper that M. Parrot's investigations on the skulls of infants seem to me to harmonise with the observations made twenty-five years ago by Mr. Hutchinson on the physiognomy of older children who are subjects of congenital syphilis. After the fontanelle has closed, and the fore part of the skull become more developed by the time of the second dentition, it is easy to see how the broad prominent frontal to which Mr. Hutchinson referred as associated with pegged incissors, and interstitial keratitis may have developed out of such a condition as is shown in specimen No. 1. *March 4th*, 1879.

---

## 3. *Les lésions osseuses de la syphilis héréditaire.*

By M. Jules Parrot.

(Introduced by Dr. Thomas Barlow.)

La syphilis héréditaire attaque avec une prédilection manifeste, d'une part, la peau; c'est à dire l'organe le plus superficiel, et le plus sensible; de l'autre, le squelette, qui est profondément enfoui dans les chairs, et dont la sensibilité est peu marquée. Les viscères ne viennent, au point de vue de la fréquence des lésions, qu'après le tégument externe et les os, et j'ajoute, bien loin derrière eux.

Je m'occuperai exclusivement des altérations du système osseux. Ce que l'on en sait date d'hier, bien qu'elles soient très fréquentes, très nombreuses et très caracterisées; et l'on se demande: comment elles ont echappé si longtemps, aux investigations des pathologistes? A cela, je ne trouve qu'une explication; c'est que de tout temps, on les a confondues avec celles du rachitis. Depuis Glisson, qui l'a si bien etudié, ce mal n'a cessé d'absorber à son profit, presque toutes les affections du squelette des enfants du premier âge. Subissant cette destinée commune, les altérations osseuses causées par la syphilis héréditaire, ont été prises, et le sont encore chaque jour, pour du rachitis. Faut il s'en étonner, si l'on songe que la syphilis conduit fatalement au rachitis, et qu'envisagé de la sorte ce mal, ne constitue pas une entité pathologique, mais simple,

ment un âge, un état particulier, une modalité de la syphilis osseuse due à l'hérédité; si bien que ce n'est plus,—suivant la confusion ancienne, que je rappelais tout à l'heure,—le rachitis qui absorbe ces altérations syphilitiques des os; c'est au contraire la syphilis, qui dans son immense processus, englobe le rachitis; ainsi descendu, du rang de maladie, qu'il occupait jusqu'ici, à celui d'une simple affection syphilitique.

Avant 1870, quelques observateurs, parmi lesquels, je citerai MM. Desmares, Mayr, Lewin, Fournier, Ranvier, Bargioni, avaient publié des observations isolées, d'alterations osseuses trouvées sur les enfants atteints de syphilis héréditaire; mais c'est Mr. George Wegner, qui le premier, a appelé tout spécialement l'attention sur ce point de pathologie, par un mémoire publié dans les 'Archives de Virchow,' pour 1870. Il n'y a décrit qu'une des formes du mal: celle que j'ai qualifiée d'atrophique; et s'est attaché à peu près exclusivement, aux modifications qui se passent aux extrémités de la diaphyse des os longs. Il y a commis aussi quelques erreurs dues à l'insuffisance des faits observés. C'est ainsi qu'il y donne le décollement des epiphyses, dont le siège est mal précisé, comme a peu près constant; tandis qu'en réalité, il constitue une exception; qu'il y consideré la suppuration osseuse comme faisant partie de l'evolution morbide, alors qu'elle est un epiphénoméne excessivement rare et véritablement traumatique.

Quoi qu'il en soit, le travail de Mr. G. Wegner est le premier en date; et ce n'est que deux ans après lui, que je publiai dans les Archives de Physiologie, mon mémoire sur la 'Pseudo-paralysie causée par une altération du systême osseux, chez les nouveau nés atteints de syphilis héréditaire.'

Depuis, l'on a fait connaitre un assez grand nombre d'observations, et quelques études plus complétes. Je citerai parmi les auteurs, MM. W. Waldeyer, et Kubner, M. Charrin, M. Birsch Hirschfeld, M. Haab, Dr. Th. Barlow, Dr. Lees, Dr. W. Taylor de New York, qui a fait une importante publication sur les lésions syphilitiques du systême osseux chez les enfants du premier âge. Enfin je signalerai tout spécialement les interessantes recherches de Mr. Jon. Hutchinson sur les alterations du systême dentaire, bien antérieures à tous les travaux que je viens de mentionner.

A partir de 1872 ce sujet n'a cessé de me préoccuper, et à diverses reprises j'ai fait connaitre les resultats nouveaux de mes investigations. C'est leur ensemble que je vais exposer aujourdhui

devant les honorables membres de la Pathological Society en montrant à l'appui, quelques pièces typiques de ma collection particulière.

Pendant longtemps j'ai considéré les lésions osseuses comme constantes, chez les enfants atteints de syphilis héreditaire; aujourdhui je ne le pense plus; et depuis qu'à l'aide des cicatrices que les syphilides cutanées laissent à leur suite, j'ai appris à connaitre la fréquence des alterations de la peau, je suis assez disposé à admettre que celle ci et la squelette, sont atteints à peu prés dans les mêmes proportions; c'est à dire dans l'immense majorité des cas mais non toujours. D'ailleurs, de ce que très exceptionnellement, l'autopsie ne révèle aucune lésion actuelle des os, l'on ne peut conclure qu'ils n'ont pas été touchés antérieurment, ou qu'ils ne le seront pas dans la suite; aussi, je reste convaincu que si ma première impression n'est pas la vérité même, elle en est très voisine.

Les altérations syphilitiques du squelette sont excessivement variées, et déterminent dans la forme, la couleur, la consistance et la structure des organes atteints, des changements si considerables, que de prime abord, leur classement semble très difficile.

Cependant la comparaison d'un grand nombre de faits, revéle entre ces lésions, très eloignées d'apparence, des points de contact et de véritables traits d'union; et permet de les classer d'une manière methodique et simple.

Le meilleur moyen de ne pas s'égarer dans cette étude, est de ne jamais perdre de vue l'âge des malades, qui est aussi celui de la maladie.

Il est rare que le squelette tout entier soit atteint; et certaines parties le sont beaucoup plus souvent que les autres. Ce sont: les os longs des membres et les maxillaires; puis ceux de la calotte cranienne, les côtes, les omoplates, et les iliaques. Les vertèbres et les différentes pièces du pied et de la main, sont touchées moins frequemment.

Ici je ne m'occuperai que des os des membres, notamment de l'humerus et du tibia; ainsi que du crane. Leurs lésions ont un siège et une apparance caractéristiques. Elles sont de deux sortes principales. Les unes consistent dans l'atrophie des tissus préexistants, les autres, dans le dèveloppement de productions nouvelles.

*Atrophie.*—Elle revêt deux formes. La première de beaucoup la plus fréquente, existe également au crane et aux membres. Je

l'ai qualifiée de Gelatiniforme ; parce qu'un effet, les parties atteintes, en l'aspect et la consistance d'une gelèe de fruit très aqueuse.

Elle se marque tout d'abord, par une modification de la teinte normale, qui varie, du grenat au rose, et du citron foncé au maïs clair ; ces diverses nuances pouvant d'ailleurs, se rencontrer sur le même os. La moëlle est brillante, transparente, et l'on y constate une diminution graduelle des medullocelles, qui finissent même par disparaitre tout à fait ; et l'on ne trouve plus qu'une trame vasculo-fibrillaire, et beaucoup d'eau. Lorsque les parties dures sont envahies, elles se décalcifient assez rapidement ; les lamelles spongieuses subissent une véritable fonte et sont remplacées par de larges espaces, ou l'on trouve un tissu, qui a l'apparance et la constitution histologiques qui viennent d'etre indiquées pour la moëlle alterée.

J'appelle la seconde variété d'atrophie *chondro-calcaire*. On sait qu'entre la diaphyse osseuse et le cartilage, il y a normalement une couche de cartilage incrustée de sels calcaires. Je la qualifie de *chondro-calcaire* ; et M. Ranvier *d'ossiforme*. Elle est très mince, puisqu'elle ne dépasse pas 1 millimètre. Chez les syphilitiques elle prend une epaisseur inusitée et per toute regularité dans ses limites.

Le tissu chondro-calcaire, quand il existe dans ces proportions, dénote un arret dans l'ossification. La partie du cartilage, voisine de la diaphyse, au lieu de se transformer rapidement en os, reste à l'état de cartilage, mais de cartilage durci, eburné, par la présence de sels calcaires. Les vaisseaux disparaissent ; et au lieu des ostéoplastes qui caracterisent le tissu osseux, l'on n'y trouve que les capsules cartilagineuses, plus ou moins alterées et remplies de corpuscules nucléaires.

Le tissu malade s'étend du cartilage vers la partie spongieuse de l'os dont il diffère, par une densité, une friabilité plus grandes, et une couleur blanche, analogue à celle de la craie, qu'il rapelle à beaucoup d'égards. Quelque fois, il se présente en noyaux isolés, au milieu des lamelles spongieuses ou bien au centre d'une masse gelatiniforme ; car les deux sortes d'atrophie existent en même temps et dans la même région. L'une et l'autre elles ont pour effet de diminuer la solidité des os qu'elles atteignent.

Le tissu chondro-calcaire, en effet, est beaucoup plus friable que l'os normal ; et il me semble inutile d'insister sur la mollesse de la matière gelatiniforme. Chacune de ces alterations peut donc déter-

miner, et détermine en realité, la brisure des os ; et quand elles se trouvent réunies, ce résultat est à peu près certain.

Cette brisure des os, qui s'eloigne à bien des égards de celle que l'on observe à la période rachitique de la syphilis, en différe surtout par son siège. Tandis en effet, que dans le dernier cas, elle a lieu à peu près à la région moyenne de l'os ; dans l'autre, elle se fait non loin de l'epiphyse ; tantôt à 1 ou 2 millimetrès, tantôt à 1 centimètre du cartilage ; ce qui est en rapport avec la place où se developpent les lésions atrophiques qui le causent.

Lorsque la séparation des fragments est complété ou même très avancée, leur frottement produit une irritation, et parfois des abcès internes et peri-osseux ; et des arthrites suppurées.

Ces brisures ont des conséquences cliniques pleines d'interet et peuvent etre diagnostiquées durant la vie. Elles produisent en effet une impotence tout a fait spéciale, que j'ai qualifiée de *pseudo-paralysie syphilitique* ; parcequ'elle simule les paralysies d'origine nerveuse ; et qu'elle a été souvent confondue avec elles. Les petits malades sont dans une inertie, dont le degré varie avec celui de la lésion. Dans quelques cas, elle est difficile à constater ; dans d'autres elle est absolue. Il-y-a peu de douleur. D'ordinaire, les membres thoraciques sont appliqués de long du tronc en pronation. Les pelviens sont allongés, contrairement à ce qui a lieu à l'etat de santé et quand on souleve l'enfant, ils pendent et oscillent à toutes les secousses.

Les muscles répondent complétement aux excitations electriques. Lorsqu'il y a des abcès ou un déplacement notable des fragments osseux, on constate des saillies, situées au voisinage des articulations. Il est possible dans quelques cas, en agissant sur les membres impotants, de produire une véritable crépitation. Ce phénomène, joint à la conservation de la contractilité musculaire, suffit à établir le diagnostic.

La seconde forme de l'altération syphilitique du squelette, celle que j'appelle ostéophytique est de beaucoup la plus frequente. Elle est essentiellement constituée par le développment à la surface des os, de produits nouveaux, qui dans des proportions diverses, modifient leur volume et leur font subir des déformations variées, mais véritablement typiques. On y doit considérer deux variétés, suivant que le tissu présente une dureté osseuse, ou bien qu'il est fibro-spongoïde.

Je qualifie la première, qui peut exister à tous les âges, *d'ostéoïde ;*

et la seconde, qui ne se développe jamais que chez les sujets qui ont dépassé cinq ou six mois, de *rachitique*.

A ces altérations principales s'en rattachent d'autres, que je decrirai incidemment, mais dont il faudrait bien se garder de faire le point de départ de sous-divisions, car on le faissant, on s'exposerait à une facheuse confusion. Elles sont le resultat d'un travail morbide accessoire, qui s'accomplit à coté du principal, par lui et à cause de lui.

Les ostéophytes, quelles que soient leur consistence et leur structure, sont soumis à des regles topographiques à peu près constantes. Parmi les os des membres ceux dont l'altération a le plus de fréquence et de regularité; sont d'abord l'humerus et le tibia, qui méritent une place tout-à-fait à part; puis le fémur et le cubitus. Lorsque le squelette tout entier est altéré, ces os sont beaucoup plus affectés que les autres; et quand la diathèse n'a pas une grande puissance, il peut arriver que seuls ils soient malades.

Sur l'humérus sans exception, comme on le constate aisement, à l'aide d'une coupe antero-postérieure faite suivant la longueur de l'os, c'est la partie inférieure de la diaphyse qui est atteinte; et d'une manière d'autant plus accentuée, que le point est plus rapproché du cartilage. Elle va s' atténuant vers le haut. Je l'ai vue, dans un certain nombre de cas, engainer complétement la diaphyse. C'est en arrière que l'epaisseur de l'ostéophyte est le plus considérable. Elle peut varier d'un demi, à deux et même trois ou quatre millimètres; sur le tibia, l'ostéophyte se développe d'une manière très fréquente, si non exclusive, sur la face interne; et il a sa plus grande épaisseur à la région moyenne de cette face. Pour le voir nettement il faut couper l'os suivant la diaphyse et transversalement. Le siège de prèdilection de l'osteophyte, est; pour le fémur, la région antéro-externe; pour l'omoplate, les fosses sus- et sous-épineuses; et pour les os des iles, la fosse iliaque externe. Les autres os longs ne présentent aucune particularité notable, car le siège des ostéophytes y est beaucoup moins fixe. Cependant, d'une manière générale, il est permis de dire, que les couches pathologiques sont surtout epaisses et engainantes, du coté de l'extremité diaphysaire qui s'accroit le moins rapidement; telles par exemple, que la supérieure, pour le cubitus et le radius. Parfois l'ostéophyte est uni si intimément a la surface diaphysaire, que l'on eprouve une certaine difficulté à l'en distinguer. Mais dans le plus grand nombre de cas, la ligne de démarcation est assez nette, et s'élargit même, en

une veritable rigole médullaire. Ce qui le caractérise surtout, c'est sa structure, apparente à l'œil nu. Il est en effet constitué par des trabécules, qui ont une direction perpendiculaire, ou très légèrement oblique, à l'axe de la diaphyse. Il peut n'etre constitué que par une seule couche, mais dans beaucoup de cas, l'on y en distingue plusieurs, qui différent par leur coloration, leur texture; et qui souvent, sont separées les unes des autres, par des sillons ou des rigoles médullaires dans les quels on distingue habituellement de petites trabécules transversales, restes incontéstables d'une couche ostéophytique à la quelle s'est sustituée de la moëlle. Le périoste presque toujours épaissi, et parfois d'une manière très notable, est appliqué sur l'ostéophyte, et lui adhère d'autant plus fortement, que la structure de celui ci s'éloigne davantage de celle de l'os. Le siège constant des ostéophytes permet de les reconnaitre durant la vie, et d'en faire un élément très précieux de diagnostic, car il n'est aucun autre état diathésique qui puisse leur donner naissance. Le procédé d'exploration est très simple. Pour l'humerus, il suffit de saisir son extrémité inférieure entre deux doigts; de manière à ce que, l'un soit appliqué sur la face antérieure, et l'autre sur la postérieure. Alors, lorsque les enfants ne sont pas trop gras, ce qui est le cas le plus habituel, on constate que cette extremité, dépasse en épaisseur ses limites habituelles. Pour le tibia, il faut promener la pulpe du doigt le long de sa face interne; qui au lieu d'etre plane, presente une sorte de voussure.

Voici en quelque mots, quelle est la structure des ostéophytes; et c'est ici qu'intervient la distinction que j'ai établie plus haut, entre les *Osteoïdes* et les *Rachitiques*.

Les premiers peuvent exister à tous les âges; mais avant 6 mois on ne rencontre qu'eux. Ils sont constitués par des trabécules plus ou moins regulières et multipliées, reliées les unes aux autres, dirigèes perpendiculairement à la diaphyse; infiltrèes comme elle, de sels calcaires en grande quantité, et entourées de moëlle. Ils ne different de l'os normal, que par une coloration plus jaune ou plus rosée; et surtout, par une friabilité plus grande et la facilité avec la quelle on peut les traverser avec une pointe, ou les couper. Le microscope montre qu'ils n'ont pas une structure systematique comme l'os vrai; l'on n'y voit pas, comme dans ce dernier, des ostéoplastes, regulièrement disposés dans la substance fondamentale, autour des canaux de Havers; ce sont des corpuscles triangulaires ou polygonaux, rappelant les corpuscles étoilés du tissu conjonctif, anastomosés à l'aide de

prolongements qui les relient au périoste d'où ils émanent, et à des corpuscles analogues, qui existent dans les espaces médullaires. Dans la forme spongoïde ou rachitique, qui est trés exceptionnelle avant l'âge de six mois, l'osteophyte est constitué par le tissu, que M. Jules Guérin et après lui M. Broca, ont qualifié de spongoïde. Il est presque blanc et d'apparance nacnée ou légèrement jaunatre. Sa structure est essentiellement fibroïde. Il est plus vasculaire et contient peu de moëlle. A les deux formes principales il faut ajouter un grand nombre de varietés intermediaires, dues à ce que l'ostéophyte au lieu d'etre simple, est composé de plusieurs couches de structure et de consistence variables, mais toujours disposées de telle sorte, que les plus dures, celles qui contiennent le plus de sels calcaires, sont les plus centrales, c'est à dire les plus rapprochées de la diaphyse, tandis que les plus spongoïdes, les plus dépourvues de sels calcaires, se trouvent à la périphérie, immédiatement sous le pèrioste. Et l'on peut voir, grace à cette disposition que la seconde forme dérive de la première; puisqu'entr'elles, on saisit une série d'états intermédiaires, qui conduisent insensiblement de l'une à l'autre.

Pendant ce temps, la diaphyse est peu modifiée chez les sujets très jeunes, dont les ostéophytes sont osteoïdes; mais chez les autres, elle se décalcifie, se décompose en lamelles paralléles, par le developpement de sillons remplis de moëlle; enfin elle peut subir la transformation spongoïde, et devient alors, excessivement legère, poreuse, friable; et lorsque, par la macération, elle a perdu ses parties molles, elle n'a pour ainsi dire ni poids ni forme.

Avec les ostéophytes ostéoïdes, le cartilage est peu modifié; seule, la couche chondro-calcaire, est plus épaisse, plus apparente; mais à mesure que le mal tend vers la forme Rachitique, la couche chondroïde augmente, finit même par prendre des proportions considérables, se remplit de bourgeons émanant du tissu spongoïde diaphysière et se vascularise d'une manière très marquée.

Il en resulte une tuméfaction parfois énorme des régions articulaires des os; et c'est la, l'un des meilleurs indices, de la forme rachitique de la syphilis héréditaire.

Ces altérations du squelette entrainent de graves conséquences. La décalcification, la lamellisation, la transformation spongoïde, diminuent, et même font disparaitre sa solidité, et le rendent impropre à remplir sa fonction principale, qui est, la résistance et la rigidité. De là des flexions, des torsions, des brisures, partielles, ou

des fractures totales, des déformations de toute sorte, des membres, de la colonne vertebrale et du thorax.

Il s'en suit, dans les fonctions, des troubles, parfois considèrables. La marche est retardée ou impossible, les mouvements des membres supérieurs, sont difficiles. Des attitudes vicieuses se produisent. La respiration est pénible par suite de la flexibilité et de la brisure des côtes et du peu de résistance qu'oppose la cage thoracique à l'action de la pesanteur. En un mot, il-y-a un état d'impotence, qui dans les cas où le mal est extrême, acquiert des proportions dangeureuses.

Tant que la diathèse est en activité, les ostéophytes, s'accroissent à la periphérie, tandis que souvent, ils sont détruits au niveau des parties préformées et remplacés par de la moëlle. Dans la période de réparation, quand tout tend à rentrer dans l'ordre, en même temps, que l'os primitif, avec lequel ils ne font plus qu'un, et dont ils suivent le mouvement nutritif, ils tendent à prendre toute la structure toutes les apparences, tous les attributs de l'os sain ; et cela à l'aide d'une série de tranformations assez simples.

Dans le plus grand nombre de ces changements que favorise activement, l'évolution si rapide du squelette à cet âge, toute trace du mal disparait, mais il n'en est pas toujours ainsi ; et il est des sujets sur les quels restent des marques indélébiles. De ce nombre sont : les torsions, les courbures, les fractures, avec toutes leurs conséquences ; et même les ostéophytes, notamment quand ils ont pour siège les os du crâne.

Le crâne subit les altérations qui viennent d'etre décrités, mais dans des proportions et avec des particularités qui lui sont progres.

L'atrophie gélatiniforme y est rare, cependant on la constate chez quelques enfants très jeunes ; et je suis assez disposé à croire qu'elle peut débuter dans la vie intra-uterine. Elle commence, sans exception, par la périphérie c'est à dire sous le périoste, et n'arrive jusqu'à la dure-mère, que dans des cas très rares et lorsque le mal est intense et rapide. Je n'ai vu cela qu'une fois et, au niveau de la perforation, il s'était développé une méningite partielle. Le plus souvent, la lésion qu'elle soit circonscrite ou diffuse, n'est jamais très profonde. Pour la bien apprécier, il faut faire secher la pièce immediatement, ou après macération. On voit alors que les surfaces atteintes ressemblent à du bois ou à du drap, qu' auraient rongé des vers.

Plus rarement la perte de substance parait avoir été faite à l'emporte-pièce. Tous les os de la calotte cranienne peuvent etre atteints. Le diagnostic de cette lésion ne peut être fait durant la vie.

Les ostéophytes craniens ont un grand intéret pratique. On ne les s'observe jamais en même temps que l'atrophie gélatiniforme; et ne se développent que chez des enfants plus âgés.

Ils se montrent à peu près exclusivement à la périphérie; et au début, en des points toujours les mêmes; à savoir: les régions péribregmatiques des frontaux et des pariétaux. Plus rarement, ils commencent à se développer sur les temporaux. Ils sont très rares sur les voûtes orbitaires et l'occipital. On ne les y observe que lorsque le mal a une grande intensité.

Ce sont d'abord des saillies lenticulaires, rouges, violettes ou grisatres, se detachant d'une manière très nette, sur la table externe, poreuses et spongoïdes, quelquefois dures, très rarement lisses, comme l'os normal.

Les ostéophytes craniens, s'étendent peu à peu de leur point d'origine aux parties voisines, soit en s'allongeant, ou bien encore en prenant la figure d'un croissant. Les bosses frontales et pariétales sont les derniers régions envahies, mais il peut se faire que finalement elles le soient; alors la calotte du crane tout entiére est couverte par l'ostéophyte. Les sutures elles mêmes sont soudées ce qui modifie beaucoup le developpement et les dimensions de la boite cranienne. L'épaisseur des ostéophytes augmente, et, dans les points les plus malades, peut atteindre deux et même trois centimétres.

Quand la puissance diathésique est épuisée, le tissu pathologique devient plus dur plus dense, par le retrécissement de ses espaces médullaires et par l'accumulation d'une nouvelle quantité de sels calcaires. Dans quelques cas le poids du crâne dépasse notablement, la moyenne physiologique.

Les ostéophytes craniens sont propres à la syphilis héréditaire. Ils déterminent des déviations morphologiques presque toujours appréciables pendant la vie. Parmi ces formes anomales, il en est une très commune et tout-à-fait caractéristique. Elle consiste en la présence de deux ou de quatre mamelons, disposés autour du bregma et separés par deux gouttières en croix, l'une transversale qui suit la suture coronale; l'autre antéro-postérieure, dirigée suivant la sagittale. Lorsque ces mamelons, sont très saillants et suffisamment étendus, il en résulte un état typique. J'ai qualifié de *natiforme*, le crane ainsi déformé, à cause de la ressemblance que présentent ses saillies, avec les organes, qualifiés par les latins de *Nates*.

La soudure prematurée des sutures, détermine la sallie de la

region bregmatique et un arret, du développement encephalique d'où peut résulter l'idiotisme comme je l'ai observé une fois.

A sa période spongoïde la syphilis héréditaire, détermine encore d'autres modifications du crane. Je veux parler de la *Plagiocephalie* et du *Craniotabes*.

La Plagiocephalie ne peut se produire indépendamment du décubitus habituel sur un même côté ; mais la syphilis favorise son développement. Le craniotabes lui aussi a pour cause, première la déclivité prolongée d'une région du crane ; et durant la vie extra-utérine, on ne l'observe jamais en dehors du rachitis syphilitique. Lorsque sur le crane, il-y-a en même temps, ce qui n'est pas rare, des ostéophytes et des pérforations tabetiques, ces deux lésions existent toujours, dans des points diametralement opposés.

Tandis en effet que les premiers occupent les régions du crane qui pendant le décubitus, sont les plus élévées ; les perforations, au contraire, se trouvent dans la partie la plus basse, celle qui est soumise le plus directement, à l'action de la pesanteur.

La connaisance des altérations craniennes resultant de la syphilis héréditaire, m'a permis d'établir deux points de pathologie historique.

Le premier, c'est que la syphilis existait dans certaines régions de l'Amérique du sud, avant la conquête Européenne. La vérité de cette proposition est incontestablement demontrée par trois pièces. Deux appartiennent au musée de la société d'anthropologie de Paris, ce sont des cranes de jeunes enfants trouvés par M. le Docteur Destruges, à Guayaquil (équateur) avec des objets franchement Américains. Ils portent sur le frontal et les parietaux, des ostéophytes osteoïdes, en tout semblables à ceux que j'ai fait connaitre.

Le troisième est un crane d'adulte, faisant partie des collections du museum, il a été trouvé a Chancai à quelques lieues au nord de Lima (Perou). Les objets de la sépulture qui l'a fourni, d'après l'avis des archéologues les plus compétents, ne présentent aucune trace de l'influence Espagnole ; et tout porte à croire, suivant l'opinion de M. Ernest Hamy, que les hypogées de Chancai sont sensiblement antérieures à Pizarre.

Le second fait-historique, est l'existence de la syphilis a l'époque, où les hommes des Dolmens, habitaient le centre de la France.

Grâce à l'obligeance de M. le Docteur Prunières de Marveyols, au quel on doit tant d'intéressantes découvertes anthropologiques, j'ai pu

examiner trois fragments de cranes de jeunes sujets, provenant des Dolmens de Cauquenos et de Bourzassac dans la Lozère j'y ai constaté l'existence d'osteophytes, en tout semblables à ceux que produit aujourdhui la syphilis héréditaire, et qui ne peuvent laisser aucun doute, sur l'existence de la maladie, dans ces temps reculés.

Il me resterait à parler des altérations du systême dentaire; mais sur ce dernier point, je dois l'avouer, mes études ne sont pas encore suffisamment avancées. Toutefois, elles me permettent d'affirmer l'importance et la justesse des observations qu'a faites sur ce point de pathologie, l'illustre Président de la société pathologique, Mr. Jonathan Hutchinson. *May 6th*, 1879.

---

## 4. *On lesions of the cranial bones in congenital syphilis (illustrated by three living cases).*

By T. Barlow, M.D., and D. B. Lees, M.D.

Cranial syphilis in infants, in its early stages, is marked by local thickenings of the bones of the skull, causing firm rounded "bosses," very evident to touch, and often to sight. These thickenings are found especially along the cranial sutures, and often arranged symmetrically around the anterior fontanelle. The centres of ossification are usually spared at first. In a later stage the bosses coalesce into a uniform thickening of a large part of the skull. These conditions are found by no means rarely amongst the out-patients of a children's hospital. We have brought to the Society this evening three cases, typical examples of the disease in its different stages, in order to afford a clinical illustration of the remarks and pathological demonstrations of Professor Parrot, to whose writings we are chiefly indebted for our knowledge of the subject.

In an article in the 'Centralzeitung für Kinderheilkunde,' for April 1st, 1879, in which Professor Abelin, of Stockholm, gives an elaborate account of the syphilitic inflammation of the ends of the long bones to which Mr. Parrot and others have drawn attention, the syphilitic bone changes of the skull are dismissed in a single

sentence with the assertion that they cannot be demonstrated during life. We hope that the following three cases, taken in connection with M. Parrot's specimens, will show conclusively the inaccuracy of this statement.

CASE 1.—Henry P—, æt. 8 months, is the first child of his parents. At his birth he was found to have a rash on the anal region; this rash lasted four months. At three months old he began to have nasal catarrh; this lasted a month. His head has always been bald. He used to cry much at night. He was brought to the Hospital for Sick Children when he was three months of age, and was there treated by inunctions of mercurial ointment. After seven weeks' treatment he seemed so well that his mother ceased to attend. A month ago he was brought again to the hospital. He now presents the following points worthy of observation:

*Hair.*—Some long hair growing from site of fontanelle,—the rest of the head almost bald, leaving only fine weak hairs.

*Skull.*—On passing the hand lightly over the top of the child's head, one feels that the fontanelle occupies a hollow between four rounded solid eminences, each belonging to one of the bones which help to form the fontanelle, thus occupying the posterior superior angle of each of the frontals, and the anterior superior angle of each of the parietals. From these eminences the thickening will be found to extend some distance along both the interparietal and the frontoparietal sutures. The frontal and parietal eminences themselves are unaffected. The posterior part of the parietals presents the condition known as "craniotabes." Over nearly the whole of a zone, about two inches deep, which passes round the back of the head almost from ear to ear, the bone yields to gentle firm pressure, feeling like parchment beneath the finger. This condition involves chiefly the parietals and the edges of the occipital, but it may also be felt in the squamous bones, and quite low down in the occipital.

*Other symptoms*, some of which are certainly syphilitic.—The child snuffles, has a *café au lait* tint in its complexion, and its voice is not clear. The spleen is much enlarged, reaching to below the level of the umbilicus. The liver reaches to two fingers' breadths below the costal margin. There is a gentle systolic bruit over the apex and surface of the heart, without any symptoms of congenital heart disease. The ophthalmoscope reveals nothing abnormal. There are decided swellings at the junction of the ribs with their cartilages,

but no distortion in the shape of the chest. There is no enlargement of the epiphyses of the long bones.

The condition above referred to under the name of craniotabes deserves a further remark. It is usually held that the thinning of the skull in spots or larger areas, to which this title has been given, is a symptom of rachitis, especially in its earlier stages. In our experience this condition is by no means common in pure rickets, and the most pronounced examples of it that we have seen have occurred in syphilitic children. Considering how easy it often is to overlook latent syphilis in children, we are inclined to suggest that this symptom also may in many cases be a part of the syphilitic cachexia.

CASE 2.—Oliver K—, æt. 2 years and 3 months, exhibits a later stage of syphilitic affection of the cranial bones, in which local, rounded, hard swellings have given place to a diffuse thickening of the skull. His head is massive, and no local "bosses" are to be detected except that each temple is roundly prominent. On each side of the head in front of the ear, a vein lies in a deep groove in the thickened bone. There is no "craniotabes." The hair is scanty over the whole scalp.

*Other syphilitic symptoms.*—Both tibiæ are considerably thickened in their upper two thirds. There are furrows at both angles of the mouth resulting from sores when a baby. The boy snuffles, and has done so since five weeks old. He is not ricketty, the chest is well formed, and there is hardly any "beading" to be felt.

The *history* is interesting, especially with reference to the lesions of the osseous system. At five weeks old he began to snuffle and had a rash about the anus and elsewhere. The skin peeled off his palms and soles. At three months one of the elbows become hot and swollen, and the arm was allowed to hang motionless. This symptom lasted two weeks, and was followed by an exactly similar condition in the other elbow. About a week after, the second elbow recovered; both knees were hot, swollen, and bent up.

At twelve months old the right tibia below the knee became hot and swollen, the skin over it being tense and shining. This condition lasted several weeks. Soon after the right tibia recovered, the left tibia was affected in exactly the same way, and continued inflamed for several weeks.

The child had cried much all his life, and especially when the bones were hot to the touch.

When his mother, Mrs. K—, saw the child Henry P— (Case No. 1), she volunteered the statement that her boy's head had exactly resembled Henry P's when he was a baby.

Case 3.—Alice C—, æt. 9 years and 7 months, is at present under the care of Dr. Gee, at the Hospital for Sick Children. Although no history of rash or "snuffles," can be obtained in this case, the family history is significant. Of the six brothers and sisters, two were stillborn and three were seven-months babies who died very early.

This patient is very stunted in her growth. She has double interstitial keratitis, deafness, and typical pegged upper permanent incisors. She has great prominence and thickening of the frontals, also "massing up" of the parietals at some distance from the suture. She is brought along with the other two to show how the natiform type of skull, described by M. Parrot, in infantile syphilis, gradually passes into the shape described by Mr. Hutchinson, as often associated with pegged permanent incisors and interstitial keratitis in syphilitic children of later age. *May 6th*, 1879.

---

## 5. *Incipient synovitis in hip-joint.*

By Arthur E. Barker.

The points of interest presented by this specimen are briefly as follows.

The anterior part of the capsule is of a rich red colour throughout its whole thickness. Before removal from the body, it was of a deep purple, as seen on lifting the muscles covering the joint. On opening the capsule the synovial membrane around the neck was also found of a purple colour, as also that covering the ligamentum teres and about the cotyloid notch. That on the walls of the cavity was also injected, but chiefly on the anterior aspect. In front of the neck the synovial tissue formed a little fringe about half an inch long, with a small appendage attached by a pedicle to its free margin. This small body was about the size of a melon seed. A

similar fringe and body were attached to the acetabular margin posteriorly. These both illustrate very well the mode of formation of loose bodies in joints. There was very little more synovium than usual. The cartilaginous surfaces of the joint were perfectly smooth and healthy, but at the margin showed commencing chronic rheumatic arthritic change. In the medullary canal there was an appearance as of chronic osteomyelitis, the marrow being of a deep brownish-purple colour down to within about three inches of the knee-joint. The latter contained a large quantity of pus, and in the head of the tibia there was an abscess about the size of a small walnut, not communicating with the joint, however.

The clinical features of the case are as follows. Up to a year and ten months ago, patient enjoyed good health. At that time she got wet feet and caught a violent cold, afterwards suffering from severe rheumatic pains in her joints. Immediately after this the left knee became swollen. Was under the treatment for this four months. At that time the knee was considerably swollen, but not constantly.

The patient came in moribund, showed no signs of septicæmia or pyæmia. The temperature never rose for the eight days she was in hospital above 100·2, and its average was 98·2. She died apparently of exhaustion from knee disease and four bedsores combined. The internal organs were healthy.

It may be said that the other hip and knee and both shoulder joints, showed well marked chronic rheumatoid change, but were not congested. *February 4th*, 1878.

---

## 6. *Acute disease of the hip-joint.*

By John H. Morgan.

The patient from whom the specimen was taken was a boy. A. T—, æt. 5 years and 7 months, who was admitted into the Hospital for Sick Children on November 23rd, 1878, under Mr. Thomas Smith, on account of disease of the left hip-joint. He was

the third child of his parents, and there were four other children in the family alive and well. One child had died of bronchitis. The mother was healthy, and there was no history of phthisis in the family.

Four months before admission he had been observed to limp, but a month previous to this he had complained of pain in the left side. There was no history of any fall or blow. He became an out-patient under Mr. Owen, who found early disease of the left hip-joint, and he was treated with a stirrup and weight, which were properly applied by one of the ladies of the hospital.

On admission, the left thigh was flexed on the pelvis and the leg on the thigh; all attempts at moving the joint were resisted. When examination was made under chloroform the head of the bone was found to be dislocated upwards, flexion and inversion were possible, but eversion and abduction could not be effected. The measurements from the anterior superior spine to the inner malleolus were on right side, 16½ inches; left side, 15¾ inches.

It was intended to reduce the dislocation under chloroform and to retain the limb in position by means of a long splint, but the boy suddenly showed symptoms of fever, which developed into those of tubercular meningitis. On November 27th his temperature which had been irregular since his admission, rose suddenly, and the patient became semiconscious, irritable, and plucked at the bed-clothes. In the afternoon he became more restless, the left angle of the mouth was drawn down, slight convulsions were followed by coma. Next day the symptoms of tubercular meningitis were more marked, and he died on the fifth day from their first appearance.

The *post-mortem* examination was performed by Dr. Abercrombie, to whose notes I am indebted. The brain was found to be in the usual condition noticed in these cases. The pia mater was much thickened especially at the base, in the subarachnoid space and around these medulla, and in these situations it was crowded with tubercles. The lungs were studded throughout with grey miliary tubercles, and their lower lobes were congested and somewhat œdematous. The spleen was spotted with grey tubercular deposits which in some places had become yellow nodules of caseous matter. The liver also presented many miliary deposits. The glands at the head of the pancreas as well as the mesenteric glands were enlarged and caseous. The kidneys were healthy.

The left hip-joint was removed with the contiguous parts. The

muscles around the joint were red and showed no sign of wasting or of degeneration. One caseous gland, the size of a small almond was found lying below Poupart's ligament embedded in the muscles. The joint was opened by a vertical incision through the capsular ligament in front, and the head of the femur was then seen to be dislocated upwards and resting on the upper surface of the cotyloid ligament and above the rim of the acetabulum. At the point of contact the head of the bone was slightly flattened, as was also the corresponding spot of the os innominatum and of the cotyloid ligament where the bone had rested. Further displacement upwards of the head of the femur was prevented by the capsular ligament which was stretched tightly over it and thus prevented muscular action from drawing the bone further upwards, while beyond appearing slightly hypervascular its structure seemed to be unaltered. The cartilage covering the head of the bone had lost the shiny glistening look of health, but to the naked eye it did not appear thinned or eroded. The ligamentum teres was almost entirely destroyed though there remained just sufficient traces of its fibres to show that it had not been congenitally absent. These were attached to the head of the femur and amongst them were round perforations of the cartilage through which the now atrophied vessels had passed to nourish the ligament. On the acetabular surface little or no trace of the ligament or of its attachment could be perceived. The cartilage lining the acetabulum was apparently in the same condition as that covering the head of the femur.

The synovial membrane lay in a mass at the bottom of the cavity torn and wasted. It remained attached to the lower part of the acetabulum and to the edges of the cartilage covering the head of the bone. In appearance it resembled a mass of red granulations, it was very vascular and with a common lens the specks which caught the light resembled small deposits of tubercle. Round the margin of the head of the bone the membrane was softer and more vascular than in other parts; and in this situation there were three or four small rounded perforations of the cartilage through which a fine probe easily passed into the cancellous structure of the bone which was found to be soft and vascular. On opening the joint a very small quantity of bloody serum escaped, but this did not appear to be purulent.

Microscopical examination shewed the synovial membrane to be converted into a mass of cells resembling those of granulation tissue

embedded in a loose connective structure. Among these were to be seen numerous giant-cells which appeared to send out processes which became continuous with the connective tissue of the membrane. The free surface of the cartilage was eroded in an irregular manner, so much so that there were in many places deep pits running down towards the bone. The cells at the surface were numerous and crowded with nuclei, while the hyaline intercellular substance was broken down. Further from the surface the cells were fewer, elongated, but contained numerous nuclei.

This case was a good illustration of at least one rare point in hip-joint disease, viz. true dislocation of the head of the femur from the acetabulum. Mr. Holmes points out in his work on the surgical treatment of children's diseases the rarity of this affection and describes the usual condition of the parts in which there is given the appearance of dislocation. Some portion of the acetabulum and more or less of the head of the femur are generally found to be absorbed and the bone is drawn upwards by muscular action so as to bring the trochanter to a relatively higher position which thus gives the appearance of dislocation. In the present instance there was no absorption either of the head of the bone or of the acetabulum and the dislocation so far as it had taken place was due to the absence of the restraining influence of the ligamentum teres, and that it had not gone further resulted from the sound condition of the capsular ligament. It is true that cases are met with of healthy subjects in which the ligamentum teres is congenitally absent, but that it was not so in the present instance seems evident from the traces of it which remained and from the condition of the cartilage at the point of connection of the ligament with the head of the femur. Had the intended treatment been pursued the head of the bone might easily have been replaced and anchylosis without loss of substance might have ensued. Two such results are mentioned by Mr. Hilton in the 14th of his lectures on rest and pain.

The specimen also forms a good example of disease confined to the synovial membrane and the ligamentum teres. Whether disease of one was consequent on disease of the other or whether they were simultaneously affected, there was no evidence whatever to show. All that remained of the synovial membrane was considerably degenerated while of the ligamentum teres there existed but the barest trace. What was the origin of the disease? Setting aside injury as a cause, of which there was no history, does not the condition of

the other organs point to a general outbreak of tubercle nearly simultaneous with the commencement of the symptoms of disease of the hip-joint? And is it to be affirmed under such circumstances that a synovial membrane may not be just as likely a seat for this deposit as the tissue of the lung or of the spleen? The question of the nature of tubercle is still far from settled and if it be dependent on the presence of "giant-cells" there can be no doubt that these are found to exist in a typical form in synovial membranes affected with so-called strumous disease. *December 3rd*, 1878.

---

### 7. *Osseous tumour of superior maxilla.*

By James F. Goodhart, M.D., for Branford Edwards.

C. S—, æt. 21, was admitted into the Ipswich and East Suffolk Hospital on November 28th, 1870, under the care of Mr. Branford Edwards. His account was that "she is a well-nourished, healthy-looking young woman. There is a large tumour occupying the right side of face, partly occluding the right eye and implicating the whole of the right superior maxilla, which appears to be equally distended in all parts. The tumour is even, hard, and bony to the touch; within the mouth the right side of the hard palate is seen to be much, but evenly, enlarged at the junction of the two palatine processes; and there is a ridge, apparently of bone, extending slightly into the opposite side. As the tumour is slowly but steadily increasing she has determined, and is advised, to have it removed by extirpation of the superior maxilla of that side. Her past history is that when three years of age she fell down stairs and received a heavy blow on the right cheek. The tumour has existed from her earliest recollections; for the last four or five years the right nostril has been occluded. The growth has proceeded slowly till the last year, since then it has increased much more rapidly; there has never been any pain connected with it. Her mother is alive and healthy; her father, I am informed by Dr. Rose, was what is generally called acutely strumous, and died with strumous disease in all parts of his body. She has never suffered from enlarged glands or other indications of struma; there is no glandular enlargement at the present time.

The operation was performed on December 12th, 1877, great difficulty was experienced in sawing through the hard palate, and a small portion of the bony ridge before mentioned was left on the opposite side.

Ten days after the operation she went through a most severe attack of erysipelas, but ultimately perfectly recovered."[1]

The tumour when removed proved to be dense and osseous, occupying the antrum. It affected also the hard palate, which was much thickened by it, and this thickening extended well across the median line. So that the saw in dividing the bone along the median line appeared to have left behind a considerable piece of the tumour. Section of the tumour showed a dense cancellous tissue, containing a quantity of vascular marrow, and on scraping it and putting the resulting material under the microscope large quantities of myeloid cells were found. But after preparation in chromic acid, &c., these appear to have been displaced, and the tumour can now only be described as one of rather porous bone.

I was at first disposed to call the tumour myeloid, but bearing in mind the fact that the whole of the disease was not removed, that no return has taken place as yet, and that the progress of the case is slow, it is more probable that it is an osseous tumour of the superior maxilla, and that the myeloid elements indicate that its growth was actively progressing. The clinical history is in accord with this view.

I have examined and described a case in some respects very similar to this in the 'Guy's Hospital Reports' for 1873-4, 3rd series, vol. xix, p. 113, *et seq.* That case, recorded by Mr. Bryant, had grown round a retained tooth, and, as in the present instance, there was a general thickening of the palatine plate of the superior maxilla extending across the median line. In the same way much of the thickened tissue was left behind, but neither has any return taken place. So that I am now disposed to look upon both as examples of a disease intermediate between inflammation and tumour, and perhaps early cases of that curious affection, leontiasis of the bones of the face, of which a remarkable example is already published and figured in our 'Transactions,' but of which the pathology is quite unknown. *October 15th*, 1878.

[1] Mr. Edwards writes, "I have seen her at intervals since, and she is at the present time, June 8th, 1879, eighteen months after the operation, in excellent health; there is no appearance of recurrence, neither has the ridge, 'evidently a part of the tumour,' left on the opposite side, increased."

# VII. MORBID GROWTHS.

## 1. *Rodent ulcer.*

By W. Tilbury Fox, M.D., and T. Colcott Fox, M.B.

In submitting to the Society a series of microscopical specimens of *rodent ulcer*, we wish to furnish additional evidence in support of the opinion that the disease is only a phase of *epithelioma*, and so to dissipate what we think is the erroneous prevalent opinion concerning the ulcer, and also to demonstrate the main primary origin of the growth in this particular phase from the external root sheath of the hair follicles, *i. e.* from the involuted layer of the rete mucosum.

In order to prevent any confusion, it may be well perhaps to remark that the disease we understand as rodent ulcer is that so well distinguished clinically from the chaos of syphiloderms, lupus, and other growths by Arthur Jacob in 1827, and hence known as *Jacob's ulcer* in Ireland. It was distinguished clinically also in the clearest manner from other "cancroïdes" by Lebert,[1] and later was described and specially reported on respectively by Sir James Paget, and Mr. Jonathan Hutchinson,[2] and by Mr. Charles Moore.[3]

The opinion prevalent in Great Britain that rodent ulcer is not a phase of epithelioma, but is an untractable, ulcerating, non-cancerous growth, *sui generis*, is due to the teachings of Sir James Paget and Mr. Hutchinson, who carried out their observations

[1] 'Traité pratique des Maladies Cancéreuses,' &c., 1851.

[2] 'A Clinical Report on Rodent Ulcer,' M. T. and G., 1860 (references to Jacob's paper and the writings of Brodie, Hawkins, &c., given).

[3] 'Rodent Cancer,' 1867. N.B.—See also three cases reported by Dr. Byrom in the 'Dublin Medical Journal' for 1843, vol. xxii, in a paper on "Malignant Diseases of the Head and Face;" and two cases from Mr. Hutchinson's "Clinique" in the 'Lancet' for August 23rd, 1873.

before the present improved microscopical examination was possible. The clinical distinctness of the growth was recognised, as it is now, but these teachings added also histological evidence. Thus Sir James Paget said, "it has been confounded with many different forms of cancer, yet it is distinct from them in structure as in history," and he considered that the growth was composed of a granulation tissue. Mr. Hutchinson argued against the cancerous nature of rodent ulcer on clinical grounds, and could find microscopically "none of the elements of epithelial or scirrhus cancer," but thought the growth consisted of "fibroid tissue in which were embedded nucleated exudation cells." (See Woodcut in the 'Report.') Lebert in 1851 (loc. cit.) described rodent ulcer as one of the forms of "cancroïde," both from a clinical and histological point of view. He found no essential difference in the structure, *i. e.* this class of growth commenced as an hypertrophy of the epidermis, and was succeeded by an epidermic infiltration of the deep dermis.

In 1865 Professor Thiersch, of Erlangen, published his work on 'Epithelial Cancer,' in which he treats of rodent ulcer as *flat or superficial epithelial cancer*. He inferred that the growth originated in the sebaceous glands, and he noticed (though he worked at comparatively late stages of the growth) the constant association of masses of disease about the hairs (see his plate iv). In 1867 Mr. Charles Moore's well-known clinical essay was published, in which he advocated the epitheliomatous nature of the disease. On page 13 is the statement that "I have found parts of the diseased substance, presenting a minute textural composition, precisely answering to that of the epithelial form of cancer," and he adds that Mr. Hulke confirmed this point in one of his cases in which the eye was involved. In 1877 Mr. Hulke, in the Pathological Society's 'Transactions,' describes rodent ulcer of the face as an heterologous growth, composed of cells pretty closely resembling rete cells, and being arranged in cylinders and bud-like masses (glandiform arrangement), with increase of proliferating leucocytes on the borders, from which the growth is probably recruited; near the surface he found epithelial scales. In a clinical lecture in the 'Medical Times and Gazette,' 1878, the same observer, in recording his still more extended experience, remarks:—"The rodent sore we (*i. e.* the Middlesex Hospital surgeons) regard as a variety of epithelioma; with the most typical examples of this it is connected

clinically by intermediate cases ( . . . ), and anatomically by the frequent presence in some parts of every phase of cell, between those resembling the tissue of the rete mucosum and the large flat scales abounding in the most typical epitheliomata."

The specimens upon which our observations are founded were obtained from three cases that we selected from a number of others, which came under our notice in practice, as likely to present certain special conditions which we hold must exist in order that the origin of the disease may be satisfactorily discovered. These conditions are, that the material for examination should be furnished not only from undoubtedly typical cases, but from the disease in its *earliest stage*, *i. e.* before the growth has spread widely in the tissues or been interfered with by treatment. We selected one specimen of disease to which treatment had not till then been applied, a second from a nodule which recurred in the immediate neighbourhood of the primary seat of origin, and a third from the newly-formed edges of a recurrent growth in a new area, after removal some time previously of the primary tumour. Where the disease is extensive and has set up considerable irritation in the adjoining tissues, *e. g.* rete, sweat, and sebaceous glands, or has been interfered with by treatment, it is not surprising that the primary anatomical seat of origin of the disease is missed, and that nothing more than what are called indications of its probable origin can be determined.

The histories of our cases are as follows:

Case 1.—J. B— gives the following account:—About the year 1860, *i. e.* eighteen years ago, when he was only twenty-eight years of age, he noticed a tiny blood speck on the side of his nose, where previously the skin had been quite healthy. It was so small as to be unnoticeable to others, but as the patient was very particular about his appearance the little spot annoyed him, as he found that he scratched and kept it sore with the friction of the towel in washing. He is sure there was no distinct pimple at this time. The excoriation increased in size slowly, and after some months he showed it to a medical man, who said it was "nothing." Again, after some months interval he consulted Mr. Clements, of Shrewsbury, who freely cauterised the place, and ordered him to take cod-liver oil. After that the sore partially healed, but never completely, and the scab began again to increase. In 1865 J. B— went to Nice to live, and there had it cauterised again; and later on M. Ricord in Paris saw it, and cauterised it for the third time, prescribing at

the same time arsenic and cod-liver oil. In 1866, when the area of scar and active disease together were about the size of a fourpenny bit, it was cauterised very freely for the fourth time, and, after undergoing similar treatment at the hands of several eminent London surgeons, including the late Mr. Startin, J. B— eventually consulted Dr. Tilbury Fox in 1872. The recurrent growth was now freely removed by the knife and the wound cauterised, but the disease reappeared after some years at the circumferential edge of the cicatrix, and in 1878 it was once more very freely removed by the knife and caustics. It was from the commencing recurrent disease at its outer edge that the specimens exhibited were prepared, and it may be added that the diseased area and cicatrix at the last operation might almost be covered by a shilling, though somewhat irregular in shape, and the disease was quite superficial.

Case 2.—Ellen W—, æt. 60, states that she remarked the disease first as a glossy white nodule, which was quite free from pain or irritative sensations, just to one side of the bridge of the nose. It continued in this state for some weeks, and she then (1866) consulted a medical man in Dublin, who pooh-poohed the importance of the matter. During the following spring the growth was troublesome, unsightly, and bled somewhat at the slightest touch. It was temporised with, and until the summer of 1868 the most severe remedy applied was lunar caustic. She then consulted M. Simon, and later M. Nélaton (both of Paris), the latter of whom recommended thorough eradication with Vienna paste. Still, after two successive attempts, the disease recurred each time just below the existing cicatrix, and in 1869 she consulted Dr. de Rubaix, of Brussels, who excised the growth. In the spring of 1870 there was again a recurrence, but now above the cicatrix, *which was about the size of a threepenny bit*, and Mr. Startin thoroughly cauterised the nodule. As the disease still again recurred as a nodule about the size of a pea still higher upon the nose, E. W— placed herself by Dr. Leared's advice under Dr. Tilbury Fox's care, and the nodule was excised and the wound thoroughly cauterised.

Case 3.—W. F—, æt. 57, states that the growth appeared some three or four years ago as a small white pimple at the junction of the right cheek with the upper part of the ala nasi. He squeezed and so excoriated the pimple, and it has never healed since, but increased slowly and steadily. When seen in July, 1878, there was a perfectly typical rodent ulcer, the size of a sixpence, with a hard,

raised, rolled edge, sharply defined from the healthy skin, and enclosing a slightly depressed, smooth, non-discharging, commencing ulcer. The growth had never been interfered with.

No one will question, probably, that these three cases were undoubted specimens of what we English mean by rodent ulcer.

We are anxious to add one word here in reference to a clinical feature of importance sometimes observed in the early stages of rodent ulcer, to which, we believe, attention has not been prominently directed. It is that about the advancing edge the mouths of the sebaceous glands are observed to be more distinctly visible than usual and plugged by sebaceous matter, and they sometimes stud the part just as in lupus erythematodes. In some cases there is a distinct seborrhœa mixed up with the growing edge. The explanation of this condition will, we believe, become apparent presently.

We now proceed to speak of the general minute characters of the growth. Probably most of the Members will be cognisant of the admirable monograph of Dr. Collins Warren, of Boston, U. S. A. (1872), embodying the results of his rechearches on the histology of this disease. We find, generally speaking, that so far as the microscopic appearances of the *fully developed disease*, we confirm almost entirely the accuracy of his statements.

Firstly, with regard to the type of cells forming the growth, Dr. Warren, who considers rodent cancer a phase of epithelial cancer, says, and we quite agree with him, that there is a general resemblance in the character of the cells in all cases of rodent cancer, particularly in their small size and uniform appearance. The cells are epithelial in type, and resemble young rete cells, but their protoplasm takes staining by reagents very faintly, so that their outline is very indistinct, indeed, the cells appear to be fused together in very many instances. The nuclei are about the size of leucocytes, and are oval or rounded, coarsely granular, and, as Dr. Thin has remarked, relatively much larger than in rete cells. The exceptions to the uniformity are that the bordering cells of the columns of new growth are columnar in shape, and we find the cells in the alveolar form of rodent cancer (Pl. XXII, fig. 6, *b*) to be larger and exhibit more variety of shape, many being pear-shaped and tailed, especially in the outermost layers of the acinus-like groupings. The cells do not present evidences of activity and multiplication. Dr. Warren figures a solitary instance he met with of large squamous epithelium

in the growth. We have found none so distinct as he figures, nor are any prickle cells present.

Secondly, Dr. Warren notes that the new growth of cells, which he thinks are developed from leucocytes, disposes itself in two main forms, viz. an *alveolar* (Pl. XXII, fig. 6) and a *tubular* arrangement (not figured). These phases are well marked in the specimens we exhibit, and they present a striking difference of appearance under the microscope. Dr. Warren explains this variation as due to a difference in the mode of growth, thus, in the *alveolar* form leucocytes escape in great numbers from the vessels in the immediate neighbourhood of the growth, and crowding round each vessel push away the neighbouring connective tissue, so that there is *a network formed of tracts of leucocytes arranged in defined clusters.* These leucocytes, influenced by the presence of the neighbouring cancer, are gradually converted into cancer cells, and so the growth spreads in these tracts to form the alveoli, compressing the central blood-vessels to a fibrous thread as it goes. In the *tubular* form, on the contrary, in which he recognises the tubular type of epithelial cancer, the leucocytes, as they escape from the blood-vessels, *infiltrate the tissues* promiscuously, and arrange themselves near the growth between the connective-tissue fibres in rows.

We have been quite unable to trace any such differences in the process of growth in our specimens. The contrast in appearance between the two forms is here greatly enhanced by the striking development of stroma in the alveolar form (Pl. XXII, fig. 6 *c*). It is also remarkable that in the alveolar form "globes épidermiques" are comparatively common (Pl. XXII, fig. 6 *a*), at any advanced stage of the growth particularly, whilst in the tubular form they are certainly very much rarer, owing no doubt to the greater resistance offered to the cell-growth, where there is much stroma present. The Society will recollect that in a paper read this session Dr. Thin denied the existence of these nests in rodent cancer, and explained their apparent presence here and there by the fact that collapsed hair-sheaths and gland ducts simulated nests. But the nests (Pl. XXII, fig. 6; Pl. XXI, fig. 4) we show to-night are far too numerous to be thus explained, and we think the specimens must definitely settle the point that they do really exist, though from the small size of the cells and the degree of activity of the disease in this form of epitheliomatous growth the nests differ somewhat in appearance from those in ordinary epithelioma, and they are certainly far less nume-

rous, and perhaps sometimes absent altogether (Pl. XXI, fig. 3). We have found also that, even in the earliest stages of the disease, if the massive processes of growth (Pl. XX, fig. 2) be examined with a high power, it will often be noticed that the cells tend to arrange themselves in concentric lines, so as to form whorls of cells (Pl. XXI, fig. 4). It evidently only requires a very little more pressure and active growth to convert these whorls into the "globes épidermiques" of the more active phases of epithelioma.

We have not found any glands affected primarily in our specimens, and usually they may be seen in the immediate vicinity of the cancer in its early stage quite healthy. The hair follicles appeared as if unaltered in Dr. Warren's specimens, except where actually embedded in the growth, and then the shafts fell out and the holes collapsed. He states, however, that in one case there did appear to be a direct communication between the hair-follicles and the epithelial cylinders, but he adds that it was an unsatisfactory specimen for observing this point (Case 4, p. 28).

He found in several cases the *apparent* connection only of the cancer with the rete. In some instances it was thinned and the papillæ obliterated, in others it was much hypertrophied, but no processes were found growing down to take part in the cancer mass. We can quite corroborate these observations. In no specimen have we found the rete (apart from the hair-follicles) taking an active or essential part in the disease, though it may be much hypertrophied and distorted owing to the increased vascularity and irritation of the leucocytes crowded on its edge. So also, on the other hand, the rete may be compressed and atrophied by the pressure of the approaching growth and the cutting off of the blood supply.

Whilst we agree, then, in the main with Dr. Warren's views, we have some additional particulars of importance to add which throw light on the *actual anatomical origin of the disease*. The specimens and drawings illustrate these points. We find the disease in those cases we have examined to start from the external root-sheath of the hair, from any part of it, and from one or more foci (Pl. XX, figs. 1, 2; Pl. XXII, fig. 5), and this point is most clearly demonstrated in the sections from J. B.'s case; but examining more advanced cases by the evidence derived from this and Case 4, the whole process seems quite clear to us. Buds sprout out from the hair-follicles in solid processes (and the *hairs* then drop out usually), pushing the tissues *en masse* and indiscriminately before them. Some of the masses grow

downwards and others horizontally, or even upwards, in close proximity to the rete, and then spread along its under surface. As a consequence of the irritation produced by the growth of the cancer, there is a greatly increased blood supply *in the neighbourhood*, new capillaries are formed, various structures may hypertrophy, and crowds of leucocytes escape into the perivascular sheaths, and eventually seem to infiltrate the whole tissues. The leucocytes wander between the rete cells and incite some overgrowth of that part of the skin, but, as we said before, the rete proper does not appear to take any primary part in the cancer growth. As the latter extends, its massive rounded buds are split up into finer processes (which are always fringed by a narrow zone of leucocytes) in order to push their way and grow in the directions of least resistance, *i. e.* along the regions where the leucocytes are congregated in the lax tissue, and so between the already compressed bundles of connective tissue. As the growth necessitates the shutting off of the blood supply to, and compression of, the textures, so we find the glands and other tissues may become compressed and atrophied. Whether the cells of epithelial type in the glands or elsewhere eventually take on the cancerous growth it is difficult to determine in many cases. It should be remembered, however, that the sebaceous glands are developed from the external root-sheath of the hair-follicle.

In the *alveolar* form, at any rate in the specimens we show, the connective tissue remains to a large extent, and forms a notable amount of stroma, simulating scirrhus (see Pl. XXII, fig. 6). We find no evidence that the growth spreads along any system of vessels, but rather that it honeycombs its way along the areas of tissue lying between the network of vessels, probably both of the blood and lymphatic class. Specimens that have been soaked for a long time in weak carmine solutions, we think, show the capillaries, cut transversely and longitudinally, lying between the ramifying and inosculating cancer processes. These vessels appear as clear spaces bounded by delicate red lines, which lines we take to be the "limiting membrane" of the cancer masses mentioned by Dr. Thin. There is also a very regular general aspect of the cancer growth under a low power, which forcibly suggests a development in accordance with the territorial distribution of blood-vessels. The latter, indeed, can be often traced in the cancer mass by the presence of packed yellowish corpuscles.

In these specimens we have not found any cancer cells wandered or lying beyond the main mass and presumably infecting the leucocytes (see the *Postscript*). The cancer masses push their way by the multiplication of pre-existing epithelial cells at the free border of the processes, as, for example, in the hyperplasic rete in psoriasis. This is clear from the evident activity of these cells. But that the leucocytes also play an important part is also probable, if one may judge from the crowding of them round the epithelial processes, their variation in size and shape, and their presence actually between the epithelial cells.

If we are to speculate as to two very important characteristics of this phase of epithelioma, we should say that the non-implication of the lymphatic glands, and absence of secondary infiltration of internal organs were due, *firstly*, to the excessive slowness of the process of growth, and to the very slight activity and absence of wandering of the cells; and, *secondly*, to the obliteration of both lymph and blood-vessels as the growth progresses.

It is the soil on which the epithelioma occurs which mainly determines its activity, and causes such a wide difference in the clinical history of the rodent ulcer of the nose and the epithelioma of the lip. "Were we to take into account every variation in colour and texture, we should find it difficult to get any two epithelial cancers, taken from different parts of the cutaneous and mucous systems, which could be viewed as growths of an absolutely identical character, so great is the influence of the parent soil, especially in the case of epithelial cancer" (Rindfleisch).

Lebert says: "On trouve tous les passages entre les cancroïdes cutanés qui offrent l'apparence la plus maligne, et les affections dont l'innocuité ne saurait être révoquée en doute."

A large body of *clinical evidence* might be collected, were this the place for it, in support of our views, such as the assumption of a typically epitheliomatous form by what was, at a prior time, a typical rodent ulcer (Moore, G. Lawson). The variation in activity and appearance of rodent ulcers and epitheliomata at different stages, and on different soils, the divergence of opinion as to the occurrence of rodent ulcer elsewhere than on the upper two thirds of the face, and so on. *December 17th*, 1878.

*Postscript.*—Since the foregoing paper was read we have had an opportunity of examining, in three additional cases, the *earliest*

stage at which rodent ulcer comes under the notice of the medical man, and we add here a note of the histories of the cases, and the results of our examination of the morbid growths.[1]

CASE 4.—H. B—, æt. 63, has had a small warty growth for some years near the nose, just below the inner angle of the eye. He cannot tell its exact duration, as he took no notice of it till lately. Within the last few months it has begun to show signs of activity, and is evidently steadily increasing.

CASE 5.—Miss B—, æt. 68, has had, for about four years, a small warty growth beneath the lower lid of the left eye. Within the last six months it has changed its character and begun to grow. Its surface has lately become cracked, and discharges a little thin matter.

CASE 6.—L—, æt. 61, noticed a rough, scaly nodule forming about six years ago. It was accompanied by slight itching, and after a time got painful on being touched. About a year ago a little ulceration appeared in the centre of the nodule.

In Case 4 we found an overgrowth of the rete. This structure was somewhat hypertrophied throughout, but the marked seat of the new growth was at certain intervals, viz. where the involutions to form the hair-follicles and sweat-ducts took place (see Pl. XXII, fig. 5). The hair-follicles were especially overgrown, and the new cells of the growth were smaller than the ordinary rete cell, and resembled the rodent ulcer cell, as already described. The sebaceous glands and sweat coils were quite healthy. There was an engorgement of the vessels, and a copious out-wandering of leucocytes in the œdematous tissue around the new growths, becoming more closely packed immediately on the borders of the latter. Under a low power the distribution of these out-poured leucocytes in the upper part of the corium showed the limitation of the diseased process to the rete, and especially the follicular part. The leucocytes acquired all varieties of shape, and took logwood staining deeply. Many were seen wedged in between the epithelial cells on the borders of the growth. Amongst the leucocytes of the corium tissue were seen a few larger, faintly stained, rounded or oval cells, quite indistinguishable from the large nuclei of the epithelial cell

[1] We are greatly indebted to Mr. George Lawson for giving us two of the growths (Cases 4 and 5), and we must also express our thanks to Mr. Amphlett for helping us in the preparation of many beautiful specimens.

of the new growth. This specimen marks extremely well the assumption of cancerous nature by a wart which has passed through a transitional active stage.

Case 5 was an example of the *alveolar* or scirrhus-like form of growth, and like the other specimen (Case 2) occurred in a woman. The amount of disease found was very slightly greater than in Case 4. It is interesting as showing that this phase of structure is assumed from a very early period in the history of the growth. The general surface of the rete certainly does not participate in the growth until the approach of the latter irritates and involves it. The heterologous growth here, too, starts more especially from the hair-follicles, but the upper part of the sweat-ducts are also concerned. The sebaceous glands and sweat coils were not implicated. A commencing whorled arrangement of cells was noticed, as in Case 2.

Case 6, when microscopically investigated, exhibited the appearance typical of epithelioma. The epithelial cells were here larger and more squamous, and the "nests" were well marked; still, the specimen might very well be taken as a connecting link between some of the other cases and an epithelioma of the lips. The growth was limited to the rete and its involutions, and the sebaceous and sweat glands were unaffected.

We, of course, hold, from our point of view, that this typically epitheliomatous structure is nothing more than we should occasionally expect to find in growths in this region diagnosed as "rodent ulcer," and we may quote here the experience of Charles Moore that, "in the early stage of a case of epithelial cancer of the face it is not easy, if it were possible, to distinguish it from the rodent disease," and he adds that epithelial cancer (as distinguished from rodent) *almost exclusively* springs up about the face at the junction of the mucous membrane and the skin, and that you cannot distinguish the two until an infection of the glands takes place.

*April 20th*, 1879.

## DESCRIPTION OF PLATE XX.

Plates XX—XXII illustrate Drs. Tilbury and T. C. Fox's Observations on Rodent Ulcer. (Page 360.) From drawings by Mr. G. Pearson.

Both figures represent sections of nodules removed from the recurrent growth at the edge of the red cicatrix in Case 1 (J. B.).

FIG. 1. *a*. Hair projecting from diseased follicle. *β*. Surrounding tissues the seat of active hyperæmia. γ. Sprouting diseased masses of hair follicles which have become confluent. *δ*. Normal sebaceous glands. (Pillischer, $\frac{2}{3}$ obj., 3 eye-piece, tube out.) × 96.

FIG. 2. *a*. Diseased hair follicle. *b*. Epithelial mass sprouting into the corium from the hair follicle. *c*. Same, isolated in the preparation of the specimen. *d*. Area more highly magnified in Plate XXI, fig. 4. (Pillischer, $\frac{2}{3}$ obj., 3 eye-piece.) × about 70.

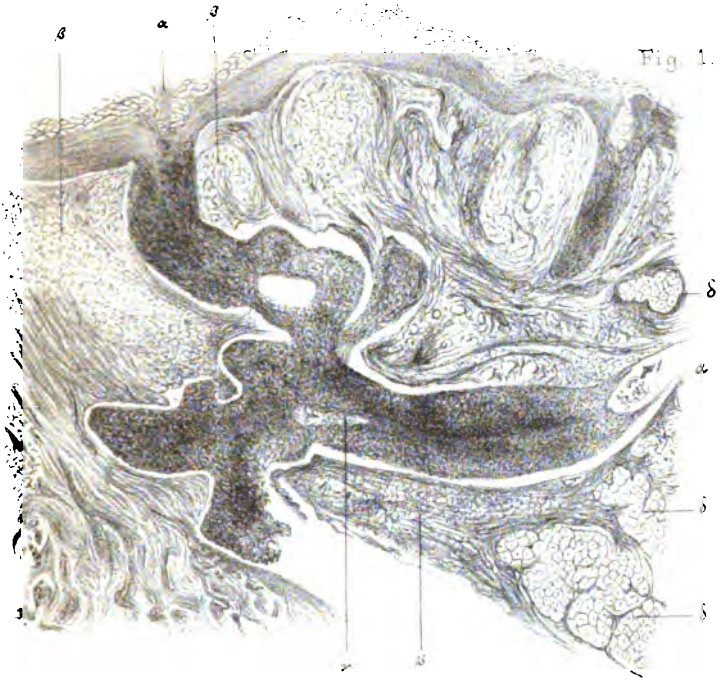


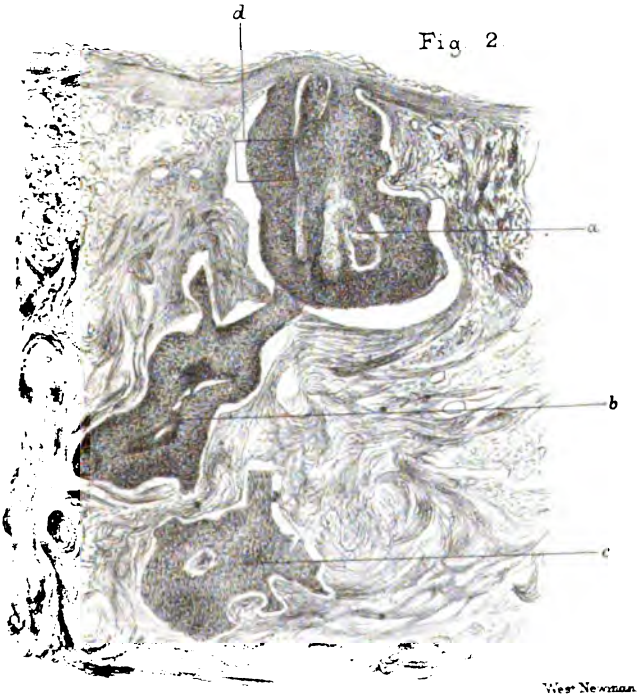


West Newman & Co. imp.

## DESCRIPTION OF PLATE XXI.

The figures represent sections taken from a nodule in Case 1 (J. B.).

FIG. 3. *a*. Hair follicles cut across from which the growth has originated. (Pillischer, $\frac{2}{3}$ obj., 3 eye-piece, tube in.) × 75.

FIG. 4. Portion *d* of Plate XX, fig. 2, to show the cells commencing to arrange themselves in whorls. (Verick, obj. 7, eye-piece 1, tube out.) = × 400.

Fig. 3.

Fig 4.

West Newman & Co. imp

## DESCRIPTION OF PLATE XXII.

FIG. 5. Section of the earliest stage of rodent ulcer (Case 4), showing (*a*) the overgrowth of the epithelial layer; (*b*) the non-implication of the sweat and sebaceous glands; (*c* and *d*) the engorgement of the upper part of the corium, marking out the area of diseased activity. Pillischer, $\frac{2}{3}$ obj., 3 eye-piece, tube out.) × 96.

FIG. 6. A section from a recurrent nodule in Case 2 (Ellen W—), to show the "globes épidermiques" (*a*) which are met with in some phases of the growth; *c* is the stroma enclosing (*b*) the loculi, and together constituting the "alveolar" or scirrhus-like phase of growth. There is great variety in the size and shape of the epithelioid cells. (Verick, obj. 3, eye-piece 1, tube out.) × 160.

Fig. 1.

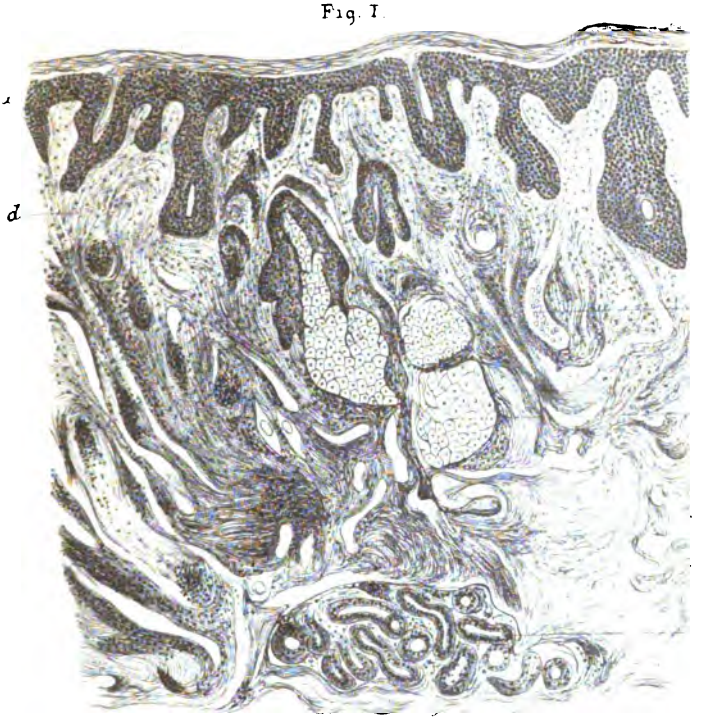


Fig 2

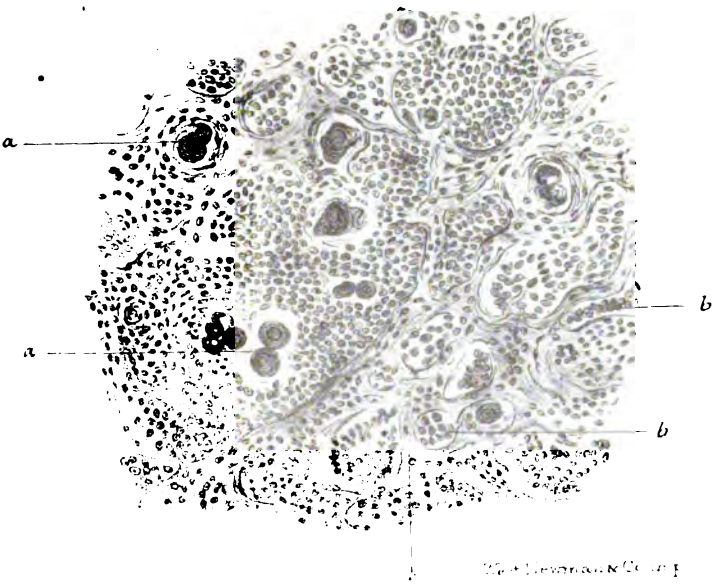

## 2. *Cancerous ulcer of the face.*

By Edward Bellamy and Alfred Sangster, M.B.

E. B—, a gentleman, æt. 46, a fine powerful man, with no cachexia, came to Mr. Bellamy in July, 1878, with a large ulcer involving the whole of the left side of the nose and a portion of the adjacent cheek. The septum narium was gone, and there was evidently extension of the disease within the nasal fossæ. The ulcer, which was very succulent in appearance, had bled freely at intervals, and at the time when first seen emitted a horribly offensive discharge. The edges were abrupt and crater-like in places, and there was much surrounding inflammation.

Six years previously he had consulted Sir James Paget, Sir Wm. Fergusson, Mr. Hutchinson, and others concerning a small painful knot in the site of the present mass, and they all advised its immediate excision. This advice, however, was not acted upon, and latterly the patient had been under homœopathic treatment, part of which seems to have consisted in inefficient cauterisation, and thereby possible aggravation of the mischief. After consultation with Mr. Hulke and Mr. Sangster in November, 1878, I removed the entire mass, including the nose, a portion of the cheek, and some of the skin of the forehead, with the knife, afterwards destroying as much of the nasal fossæ as seemed to be involved with Paquelin's thermocautere.

Recurrence has since taken place. Material for examination was taken from different parts of the ulcerating mass after its removal.

Microscopical examination of vertical sections through its advancing edge showed that the disease was essentially epithelial in character. The cells composing the new growth contained large, oval or round, deeply-stained, granular nuclei, with one or two point-like nucleoli. They followed no definite arrangement, and were somewhat loosely packed in the meshes of branching fibrous trabeculæ (Pl. XXIII, fig. 1 *c*). Scattered among the epithelioid cells were free nuclei undergoing division. Where the new growth was not ulcerating to the surface, the Malpighian layer which still covered it showed great irregularity, but only slight hypertrophy (Fig. 1 *a*); and there did not seem to be any structural

continuity between the compact Malpighian cells and the loosely arranged epithelioid cells below. As the sounder structures were approached the hypertrophy of the Malpighian layer decreased, but its irregularity was still marked, mainly owing to the distortion and distension of hair-follicles choked with epithelial *débris*. The sebaceous glands at the margin of the growth were very large; it is difficult to say whether they were larger than those usually found in this situation (cheek). Some of them showed peculiar changes. It is well known that in logwood-stained sections of normal skin, each lobule of a sebaceous gland is bounded by a thin zone of deeply-stained cells, which have not undergone sebaceous change; the remainder of the lobule being occupied by cells having a peculiar reticular appearance, due to the pushing aside of the protoplasm by sebaceous material. Occasionally, in the sebaceous glands of the specimens under examination groups of cells were cut off, so to speak, apparently by the advance of fibrous processes from opposite sides of the lobule. The cells in the centre of these groups retained their reticular appearance, while those towards the periphery became flattened and arranged concentrically, giving an appearance somewhat simulating that of epithelial "nests." Though often enclosed by the advancing new cell growth the real nature of these "pseudo nests" was clearly traceable. The cells lining the tubules of the sweat-glands in the neighbourhood of the new growth showed degenerative changes. There was much inflammatory cell infiltration, especially at the margin of the new growth and beneath the rete Malpighii (Fig. 1 *b*). Although a tendency to "capsular lamination" was seen in places such as occurs under almost any pathological condition favorable to the rapid increase of epithelial cells, there were no true nests to be found ("globes epidermiques") in any section (fifty examined) of material from different parts of the growth.

The extreme chronicity of the disease (six years), its tendency to infect locally, and not through the glands, together with absence of "globes epidermiques," are points of interest as relating to the diagnosis.

Compare 'Anatomy and Development of Rodent Ulcer' (monograph), Collins Warren, Boston, 1872; Billroth, 'Surgical Pathology,' vol. ii, Sydenham Society, pp. 465, 487; "Pathological Histology of Rodent Ulcer of Scalp," by G. Thin, M.D., 'Trans. Path. Soc. Lond.,' 1878, p. 241. *March 4th*, 1879.

## DESCRIPTION OF PLATE XXIII.

Plate XXIII illustrates Mr. Bellamy and Mr. Sangster's Case of Cancerous Ulcer of the Face. (Page 371.) From drawings by Mr. Sangster.

FIG. 1. Vertical section through the advancing edge of the growth, showing (*a*) Rete Malpighii somewhat hypertrophied; (*b*) inflammatory cell-infiltration at the margin of (*c*) epithelial new growth. Hartnack, oc. 3, obj. 4; tube out.

FIG. 2. The new growth highly magnified; showing cells and nuclei in the meshes of fibrous trabeculæ. Hartnack, oc. 3, obj. 8.

Fig. 1

Fig. 2



Wm. Swain & Co. Imp.

*Report of the Committee on Morbid Growths on Mr. Sangster's and Mr. Bellamy's specimen of cancerous ulcer of the face and nose.*—Mr. Sangster's microscopic sections exhibit well the conditions which he has described, namely, closely-packed epithelioid cells having large oval nuclei, and contained in the meshes of fibrous trabeculæ. The Malpighian layer of the epidermis is much thickened, and the sebaceous glands are hypertrophied, but no connection can be traced between the new cell growth and these structures, nor can we trace any connection between the new growth and the hair-follicles and sudoriparous glands. There are no forms which deserve the term "cell nest." The general characters are similar to those described by Dr. Thin and Dr. Warren, of Boston, in some cases of rodent ulcer, particularly in respect to the small size of the cells of which the new growth is composed, and the absence of cell nests. The disease appears to us to be too far advanced to afford good material for working out the origin of the new growth.

JAMES F. GOODHART,
HENRY T. BUTLIN.

---

## 3. *Further illustrations of the histology of rodent ulcers.*

By GEORGE THIN, M.D.

I HAVE recorded, in the twenty-ninth volume of this Society's 'Transactions,' the microscopic appearances seen in two cases of rodent ulcer. In regard to one of them—that described as a cancerous ulcer of the skin of forty-three years' duration—although the term rodent was not used in the title of the paper, I expressed my belief that the case was typical of this disease; my opinion being founded on the fact that clinically the ulcer possessed the chief characteristic features of this affection of the skin, and also that histologically it was identical with the second case which had been diagnosed, before operation, as a rodent ulcer. This opinion has been confirmed by the results of an examination of two additional cases of rodent ulcer; the histological elements in all the four cases having been found to be of the same nature. The clinical history of

the first of these two new cases is thus given in the 'Records of St. Bartholomew's Hospital.'

"M. B—, æt. 54, was admitted to St. Bartholomew's Hospital November 20th, 1877, on account of a small hard ulcer on the left side of the nose, extending to the adjacent part of the cheek. The ulcer measured one inch by half an inch. It was fissured close by the ala nasi, being covered elsewhere by a dark green irregular scab. Beneath the scab it was of a deep red colour. Its outer border was nodulated. At its upper border there was thin red scar (?) tissue. There was some induration about the base, but not very much.

"Four years ago a little wart formed by the side of the nose, the upper lip of that side being at the same time swollen on account of inflammation of the eye-tooth. The wart very slowly increased in size. A year ago caustic was applied to it, after which it seemed for a time better, but soon began to grow much more rapidly than before. The general health has been good, and there is no family history of cancer or tumour. The ulcer was removed by the knife, by Mr. Morrant Baker, on November 24th. The patient soon left the hospital and was seen several months afterwards still quite well."

Microscopical examination of sections carried through the border and surface of the ulcer showed that the edges of the sore contained a luxuriant cell-growth. The nodules in the border were formed by the bulging towards the surface of large cylindrical and ovoid masses of this growth, similar to those which I have described and figured in the last volume of the 'Transactions,' from the ulcer removed by Sir James Paget, there being in the present case also a distinct "ridge," although it was not so pronounced as in the former one. The connective tissue of the papillary layer was displaced, and eventually became obliterated by these growing masses.

The large cell-masses near the surface sent out cylindrical buds which, in some cases, encircled the blood-vessels, and the more resistant epidermic structures of the skin. When these fall out, a hole with even edges is left in the centre of a mass. No true epidermic structures were formed by the cells of the masses.

In some of these cell-masses, where the cellular elements have been displaced, a distinct membrana propria is brought into view (see Plate XXIV, fig. 8 *a*). The cells of the growth are characterised by a well-marked nucleus, which stains deeply in logwood, and a delicate homogeneous cell-substance which it is difficult to detect in

## DESCRIPTION OF PLATE XXIV,

### Illustrating Dr. Thin's further illustrations of the Histology of Rodent Ulcers. (Page 373.) From drawings by himself.

FIG. 1.—From a section through the nodule in the lip in Mr. Lister's case. *a*. "Glandiform" cell-growths amongst the muscles. *b*. Muscular fibres. *c*. Connective tissue. × 45.

FIG. 2.—A part of Fig. 1, more highly magnified. *a*. Lymph corpuscles (exudation cells). *b*. Part of the membrana propria brought into view by being separated from the investing connective tissue. *c*. Connective tissue. *d*. Section of "glandiform" growth parallel to its long axis. *e*. Nuclei of the cells of the growth. *m*. Nearly transverse sections of muscular fibres. × 260.

FIG. 3.—From the border of a large cell-mass. *a*. Membrana propria laid bare by displacement of the cells of the mass. × 260.

FIG. 4.—From the submucous tissue of the lip (rodent ulcer of the nose). *a*. Large cell-masses near the surface. *b*. Smaller cell-masses extending to the muscles. *c*. Connective tissue. *m*. Muscular fibres. × 45.

FIG. 5.—Rodent ulcer of the cheek (to show mode of formation of the so-called "tubular variety"). *a*. Epidermis. *b*. Connective tissue. *c*. Part of a large cell-mass with a hole in the centre, formed by strangulation and disappearance of connective tissue. *d*. Island of connective tissue beginning to break down (completely surrounded, but the drawing does not include sufficient of the section to show it). × 45.

Fig. 1

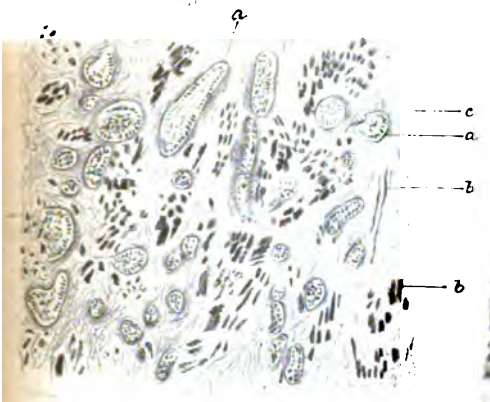


Fig. 2.

Fig. 3

Fig. 5

Fig. 4.

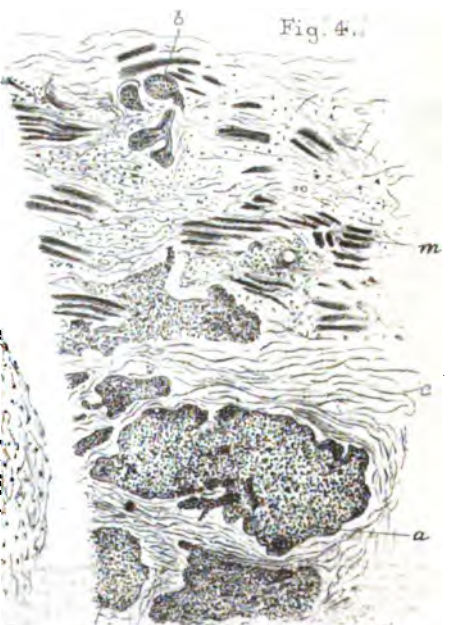


West Newman & Co. imp.

sections or to isolate. A successful attempt at isolation showed an absence of the so-called "prickles" of the prickle cells of the rete mucosum. (The *epitheliomes tubulés* of Cornil and Ranvier answer to the description of rodent ulcer. These authors, in their 'Manual' (p. 277), state that prickle cells can be isolated from the masses which have begun to undergo cadaveric decomposition.) The cells break up in the centres of the larger masses by disintegration and liquefaction. In no instance did I detect in them signs of enlargement or horny degeneration.

Remnants of the cell-masses were lodged in the tissue forming the surface of the ulcer. In the edge of the ulcer, at parts where the growth was most active, smaller patches had penetrated to the middle strata of the cutis. Over certain parts of the tissue forming the border of the ulcer, the rete mucosum was thicker than usual, whilst over the "ridge" it had in many places become very thin. It had nowhere undergone the peculiar changes characteristic of epithelioma, and even where an ascending column of the new growth had come in contact with an interpapillary projection of the rete mucosum, the line of contact was always defined by the different nature of the cells. The sebaceous glands and hair-sheaths were either normal or the seat of degenerative changes. The sweat glands were mostly in their ordinary condition, but in one section a coil was found similarly changed to that figured in Plate VII, fig. 5, vol. xxix of the 'Transactions.' In some parts of this coil the lumen and bounding cells were normal, whilst in other parts of the tube the lumen was blocked and distended with a homogeneous mass. At one part the distension was equal to that shown in fig. 4, Plate VII, in the volume just referred to, although no homogeneous mass was found within it. (It might have been present and have fallen out whilst the section was being cut.) The sweat apparatus was, therefore, in this instance the seat of new growth, the walls of the distended tube being formed by a complete epithelial sheath. The area of the coil was infiltrated with exudation cells. The position of this sweat coil was external to the area of the masses of new cell-growth, and its excretory duct could not, therefore, have been occluded by them.

Ulceration was effected by the vascular connective tissue being obliterated between the cell-masses and the epidermis, and the consequent destruction of the latter.[1]

[1] In this case, in some of the larger cell masses in the ridge, there was a large

CASE 2. Mr. S—, a ship broker, æt. 41, married, with a healthy personal and family history, applied to Mr. Lister for advice.

In 1854, when he was seventeen years old, a sore was noticed at the side of the left nostril. There was a pimple which he scratched. This pimple persisted, but it remained very small till ten years ago, when it began to enlarge, being at that time about ⅛ inch in diameter. In 1869 it began to make its way round the nostril into the nose. He was seen at this time by Sir James Paget, who cauterised the part. A small sore, which continued to break out at intervals, remained.

He did not notice any hardness until eighteen months ago, since which time it has been growing rather rapidly. Communication with the mouth took place three months ago during an attack of erysipelas. No healing was at any time observed.

It is noted that at the time he applied to Mr. Lister, the patient was a small wiry man, thin, but muscular and healthy. There was a tumour involving the side of the nose and upper lip, distorting and displacing the nostril and drawing up the left part of the lip so as to expose the teeth. The swelling was very hard. There was a separate nodule near the middle line of the upper lip which did not affect the skin, and was not ulcerated. There was communication between the nostril and the mouth in front of the alveolar border in the track of which the probe passed down to the bone.

A sketch of the parts made by Mr. Godlee (to whose notes, kindly placed at my disposal, I am indebted for the above account of the case) shows that the ulceration into the nostril was slight as compared with the area of swelling. Separate portions of the nasal ulcerated surface and of the swelling in the upper lip were given me for examination, after an operation by Mr. Lister.

Microscopic examination of the part from the nose showed that large, irregularly shaped cell-masses, deeply situated in the skin, extended to a considerable length from the ulcerated border. For some distance the connective-tissue bundles of the cutis were entirely replaced by cell masses embedded in amorphous granular matter in

round aperture in the centre of the mass, whilst in others there was no trace of it. To such hollow cell masses Thiersch applied the term tubular, and he speaks of a "tubular variety" of flat epithelial cancer. I can see nothing in these appearances, which are accidental in their nature, to warrant the idea that there is any such variety. I find in the above case that the masses are "tubular" at one part and solid at another.

which numerous elastic fibres and blood-vessels were observed. Towards the extreme border of the swelling, the cutis tissue presented its ordinary characters, but at different parts of its thickness small, elongated, more or less cylindrical cell-masses had formed.

The cell-masses were always limited by a definite border. The cells of which they were composed were conspicuous chiefly by their nuclei, the cell-substance being rarely distinguishable. The nuclei, although varying somewhat in shape, were of a tolerably uniform size. All the specially distinctive characters of epidermic cells were wanting in them. The cells and cell-masses were identical in every important character with the cases I have previously described, but in this case, as there was not the same luxurious growth in the papillary layer, the "ridge," with the peculiar cylindrical and ovoid masses which compose it, was wanting.

Sections through the hard nodule in the upper lip showed the presence of cell-masses in two forms. In the submucous tissue large irregular masses with a tendency to a circular or ovoid form were seen in section (Pl. XXIV, fig. 4 *a*). The cells that composed those masses were similar to those found in the diseased tissue of the nose. Deeper amongst the most superficial muscular fibres the masses were much smaller, whilst deeper still and in the centre of the lip they had acquired a specific and highly characteristic form. They were scattered amongst the groups of muscular fibres as so-called "glandiform" structures, being chiefly seen in section as circular and elliptical growths according to the relation which the plane of the section bore to their axis (Pl. XXIV, figs. 1 and 2, Woodcut 6). Two appearances peculiar in a more or less marked degree to the cell-growths in this disease were seen in those now being described, the presence of a membrana propria and the tendency of the peripheral cells to assume a columnar form and arrangement being prominently shown. The presence of the membrane could be distinguished in nearly all of them, whilst the columnar form of the cells was best seen in those growths that had advanced to a certain thickness.

None of the morbid growths observed in the nose or in the lip were seen to originate in the epidermis or in the glands of the skin.

The presence of fine elastic fibres in the cell-growth was detected in the masses in the submucous tissue. They were continuous with elastic fibres in the adjacent connective substance (Woodcut 8, p. 381).

The results obtained by the examination of these two cases, taken in conjunction with those found in the two cases recorded in the preceding volume of the 'Transactions,' may be thus summarised.

WOODCUT 6.

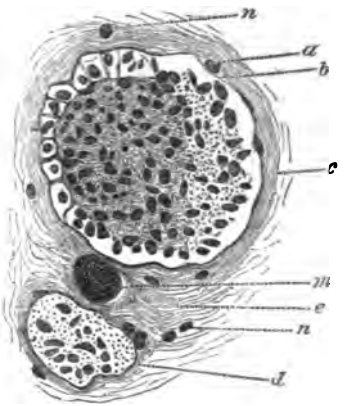


From the nodule in the upper lip. *c* and *d*, "glandiform" structures in transverse section; *a*, lymph-cell enclosed in a cavity formed by a splitting of the membrana propria at *b*; *e*, connective tissue; *m*, muscular fibre; *n*, lymph-corpuscles in the connective tissue. × 260.

In two cases out of the four there was a peripheral ridge produced by an exuberant cell-growth in the papillary layer of the cutis. In none of the four cases did any morbid growth take place in the rete mucosum, root-sheaths of the hairs, or sebaceous glands.

In two cases, sweat glands were found to be the seat of morbid changes, the chief of which consisted in dilatation and new cell-growth, in one case a mass of newly-formed cells occupying the lumen of the tube.

The new cell-growth in the sweat glands was not traced in direct continuity with the specific cell-growth of the disease.

The distinction of an alveolar and tubular variety in rodent ulcer (flacher epitelial krebs) by Thiersch is not borne out by these cases. In Mr. Baker's second case, tubular and solid cell masses were found side by side, and the holes which in section give the impression of tubes could be traced in actual formation. Buds from the cell masses, after growing outwards for a certain distance,

send out projecting points which meet and enclose portions of connective tissue (Woodcut 7).

WOODCUT 7.

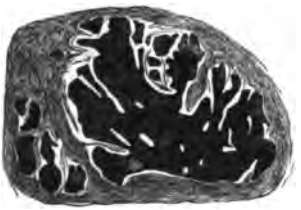

Cell mass from a rodent ulcer of the cheek. × 14.

When these enclosed portions have had their blood supply cut off, the fibrillated connective tissue disintegrates and finally disappears. If the hole thus left is far removed from the border of the mass, it does not seem to fill up by new cells of the characteristic growth (see also Plate XXIV, fig. 5).

The cells of the new growth have distinctive characters and differ from those found in epithelioma in other respects than dimensions. The nucleus is of a fairly uniform size. The varying forms in which it is found probably depend on the varying effects produced in different cases by the hardening fluids employed to prepare the tissue for examination. In my preparations the nuclei were invariably entire.

The cell-protoplasm is comparatively scant in amount, is scarcely or not at all granular, and if it has a cell-wall, the latter, except in the border columnar cells, is, as a rule, too delicate to resist even the most careful treatment by solutions of bichromate of potash. In Sir James Paget's case I hardened a piece of the ulcer in osmic acid. The nuclei in the sections made of this piece were in excellent preservation, but the cell substance was not better preserved than in the bichromate preparations of the same ulcer. The resisting power of the cells appears to vary in different cases. Although all the specimens I examined were hardened in the same manner, the cells in the preparations in Sir James Paget's case were better preserved than in any of the others. This difficulty in hardening the cell substance has induced Dr. Collins Warren to entertain the erroneous idea that the cell-masses are constituted by nuclei imbedded in an undivided mass of protoplasm. If care is taken it is possible to isolate some of the cells, and it is then seen that there is

a thin transparent plate of cell substance, with a well-defined border round the nucleus.

These remarks apply to the ordinary cells of the masses. The columnar cells which form the border row are more resistant. Yet in most of the preparations of the three last cases, their size and shape is only indicated by the arrangement of the nuclei, and by faint regular lines seen in deeply stained sections. What after my own experience and an examination of all the plates hitherto published in reference to this subject, I cannot but regard as highly satisfactory and exceptional preparations of these cells were those made from the specimen in Sir James Paget's case, and from one of which, fig. 2, Plate VII, vol. xxix, was drawn. In that case the nucleus, cell-substance, and cell-wall of the columnar cells were very distinct.

The cells have certain negative qualities which distinguish them from the cells of epithelioma and which are independent of their relative size. They never enlarge into the flat horny cells, characteristic of the latter disease, never become "prickle" cells, at least as observable after the use of ordinary reagents, and never form the so-called "nests," or globes epidermiques (so long as this term is limited to special changes in newly-formed cancerous epithelium). A chemical difference is brought out by the employment of eosin. The readiness with which the cells of the epidermis are coloured a deep orange red by this staining agent, proves that they contain a substance for which it has a special elective affinity. The newly-formed cells in epithelioma are similarly stained by eosin, but the substance which is so rapidly and deeply stained by this dye in cells of the epidermic type does not exist in the epithelial cells of rodent ulcer.[1]

The softening which takes place in the centre of the larger cell-masses is produced by mucoid disintegration and liquefaction of the cells.

[1] When the ascending edge of the new cell-growth has come in contact with the small cells of the lowest layer of the rete mucosum or the border of the external root-sheaths of the hairs it is sometimes difficult to detect the line of separation, and scattered through the various works and memoirs on cancer drawings are found in which the cell-growths of what is evidently rodent ulcer are made to show a continuity with the epidermis. With sufficient care this confusion of the line of contact of the two elements can be avoided. For this purpose I recommend the use of gum in the ordinary manner to prevent shrinking, and a careful use of eosin and logwood in staining the sections.

Another peculiarity in these cases seems to be the small amount of cell-infiltration and disorganisation in the connective tissue of the corium, as compared with what occurs in epithelioma. Sometimes the amount of cell-exudation in the neighbourhood of growing masses of even considerable size is very slight, especially in the deeper strata of the cutis, and when, in the connective tissue between the exuberant growths in the papillary layer, an abundant cell-infiltration is found, the area so affected does not extend far beyond the limits of the new cell-growth.

Small localised areas of very abundant cell-infiltration are found in and immediately below the cutis, and in badly hardened tissues. I believe it would be sometimes difficult to distinguish them from the specific cell-masses.

The nucleus of the ordinary exudation-cell does not differ very greatly in size and staining capacity from that of the specific cell in question, but the want of a well-defined border in the masses of exudation-cells, and their irregular arrangement, ought to be sufficient to prevent their being confounded with the epithelial masses.

It is impossible to discuss the problem of the source from which the individual cells in the cell-growths of rodent ulcer are derived without opening up disputed questions regarding the mode by which epithelial cells are developed in healthy and morbid tissues, and this I shall avoid. Two facts are, however, to be noted in this connection. In my preparations I found the nuclei of the cells of the growth invariably entire. In the immediate neighbourhood of the border of the growth leucocytes, in greater or less numbers, were usually to be found. Sometimes the leucocyte was in actual contact with the investing membrana propria, and in several instances (see, *e.g.*, Woodcut 6) it was found in a cleft of the substance of the membrane itself.

In two of the cases elastic fibres could be traced into and through the cell-masses (Woodcut 8).

In my previous paper in the 'Transactions' (vol. xxix) I expressed my belief that rodent ulcer is an adenoma of the sweat glands, founding my opinion on the fact that the only seat of abnormal growth in a pre-existing epithelial tissue which I had observed was in the sweat glands in one of the cases, and because I recognised the morbid growth in Verneuil's case of adenoma of the sweat glands as of a like nature to that observed in my cases. This opinion is, I believe, corroborated by the fact that in

two more cases of the disease, the only epithelial structures I have found the seat of growth are again the sweat glands, although, this time also, in one only of the cases. The structures in which the first abnormal departure from a healthy condition has taken place having disappeared by ulceration, it seems to me that great weight is to be assigned to evidence that the sweat glands in rodent ulcer are prone to take on morbid action, even when they are not in actual contact with the cell-masses which constitute the essential element of the disease.

A critical examination of the work done by previous observers in the same field will show how far it bears out, or is opposed to, my opinion.

Dr. Jacob gave an accurate description of the affection as "an ulcer of a peculiar character which attacks the eyelids and other

WOODCUT 8.

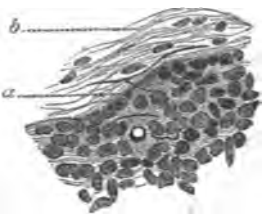


From rodent ulcer of the nose. *a*, border of epithelial mass; *b*, connective tissue. Elastic fibres penetrate the mass. × 260.

parts of the face," in 1827; but the first account of it as a morbid cellular growth, of which I am aware, is contained in the standard work by Thiersch on 'Epithelial Cancer,' published in 1865. Up to that time, although painstaking observations had been made in England to discover a cause for the local malignity of the ulcer, nothing had been found. I can only account for this by taking into consideration the perishable nature of the cells. The methods which were found reliable in isolating, and bringing under observation, the strongly developed cells of epithelioma, with their epidermic characteristics, failed to show the delicate, soft, cellular elements of the rodent ulcer.

Thiersch[1] divides epithelial cancer of the face into two classes:

[1] 'Der Epithelial Krebs, namentlich der Haut.' Von Dr. Carl Thiersch, Leipzig, 1865.

penetrating or infiltrating epithelial cancer and flat epithelial cancer. The cases of the latter, or "flat" cancer, given in his book correspond perfectly in their clinical aspects with the rodent ulcer of English surgeons, and he recognises the identity. Contrary to the views then held by English surgeons, he found on microscopic examination "that in addition to a vascular stroma of the character of granulation tissue, a second histological element is represented. In the border of the ulcer there are groups of cell-masses, alveolar in their arrangement, and in immediate connection (*Zusammenhang*) with the Malpighian layer. The cells are of the size and colour of the cells of the Malpighian layer, are mostly round or polygonal, but not flattened. They lie evenly and close to one another, older and younger cells being indistinguishable. The cells which bound the wall of the alveolus are mostly columnar in form, and are arranged with the long axis of the cell perpendicular to the wall. They lie immediately on the connective tissue, there being no homogeneous membrane between. The connection with the wall is a loose one."

The above description refers specially to his Case 1. In the plate in his 'Atlas,' in which the microscopic appearances seen in this case are figured, it is stated that certain cell-groups therein depicted must be considered on account of their position and shape as degenerated sebaceous glands.

Similar statements and terms are applied to other cases described and figured in the book and 'Atlas.'

We find, therefore, that Thiersch recognises the cell-growth of rodent ulcer as composed of groups of cells of uniform size, arranged in alveoli. In regard to their source, he states that they are found in connection with the rete Malpighii and in the situation and of the form of the sebaceous glands. On the latter point I have been unable from my preparations to verify his statements, and have, therefore, all the more carefully sought for evidence in his 'Atlas' to confirm them. Such evidence is, in my opinion, not to be found there. There is no appearance figured which connects either the rete Malpighii or the sebaceous glands with the cell-masses. Mere contact, such as I have frequently found in my own preparations, between a cell-mass and a part of the rete mucosum in itself proves nothing. The position and form of the masses which are supposed to identify them with the sebaceous gland are simply the position and form which any luxuriantly-growing cell-mass in the papillary layer of the cutis must necessarily assume. Not only is there no direct transi-

tion between a sebaceous gland and a cell-mass figured, but there is no drawing which shows any active change at all in the sebaceous glands. The failure to detect a homogeneous membrane between the cells and the connective tissue must be attributed to the methods employed.

In Plate ix, figs. 1 and 2, of his 'Atlas,' the same author gives drawings of sections from a case of "flat epithelial cancer of the skin of the temple, taking origin in the epithelium of the sweat glands." A tumour as large as a pigeon's egg, ulcerated on the surface, situated in the skin, and only slightly movable over the bone, was excised but not examined. Three months afterwards relapse and another operation, the growth being this time examined microscopically. The chief constituent of the nodules is stated to have been enlarged and partly degenerated coils. Another relapse and operation within two months. Still another relapse, and death eight months afterwards from meningitis of that side.

The microscopic appearances shown in the Plate are those seen in preparations from the nodules of the first relapse. Fig. 1 shows a gradual, but unbroken, transition from normal sweat glands to coils with an exaggerated lumen. Nearer to the diseased mass the lumen of the glandular structures becomes scarcely observable, and there is an unbroken transition from these latter to cylindrical and rounded masses of cells without any lumen at all. It is to be remembered that in the large cell-masses of rodent ulcer Thiersch recognised no membrana propria. In the present instance it is stated "that as the lumen of the anastomosing cell-growth disappears so also does the wall of the glandular tube, and the morbid growth comes into immediate contact with the surrounding connective tissue."

The cells had a relatively large nucleus, and averaged about the size of those of the Malpighian layer.

Thiersch places this case intermediately between epithelioma and rodent ulcer as regards the grouping and individual characters of the cells.

I invite special attention to this case, because I believe it to yield evidence in support of my opinion, that in all probability rodent ulcer is an adenoma of the sweat glands in which the transition from the originally altered glands has been destroyed by ulceration before an opportunity has been given to make a microscopic examination.

If the cell-masses *g*, *g*, fig. 1, and *b*, *b*, fig. 2, in Thiersch's Pl. ix, be compared with cell-masses figured by him in his other plates,

which illustrate the histology of rodent ulcer, and with the cell-masses figured by me in the present and the preceding papers, I believe it will be difficult to observe any distinguishing characteristic between them; whilst the fully developed cell-masses in Thiersch's recognised case of adenoma of the sweat glands have none of the distinguishing characters of epithelioma which arises from epidermic structures. The peculiarity of this case I believe to be that all the transition stages between the slightly affected sweat glands and the fully-developed masses were observed. This may be perhaps explained by the rapidity of the cell-growth and the relatively rapid yielding of the surrounding connective tissue in this particular instance.

The cells of the growth in this case are unfortunately not figured on a scale sufficiently magnified to judge of their nature, but the description given that they have a relatively large nucleus and are of the size of those of the Malpighian layer, is similar to the description given by the same author of the cells in the morbid growth of rodent ulcer.

To sum up my views regarding the information to be derived from a study of the very valuable plates in the 'Atlas.' Thiersch has there shown once and for all that there are two different kinds of epithelial cell-growth in the skin. In one kind—penetrating epithelial cancer—the new growth takes its departure in the rete mucosum of the epidermis. In the other kind—flat epithelial cancer (rodent ulcer)—he has, in none of the cases he recognises as such, shown how the cell-growth took its origin.

In a case described as epithelial cancer, taking its origin in the sweat apparatus, the evidence that the morbid growth begins in the sweat glands is unmistakable. In this case I hold that the cell-masses, as figured in the 'Atlas,' are not to be distinguished from those of rodent ulcer.

Thiersch relates (op. cit., p. 167) that in a solitary case he has found flat epithelial cancer of the nose associated with affection of the glands and secondary cancerous deposits in the spleen, the cells in the spleen being flattened and forming concentric nests. If the diagnosis in this case be accurate, we have testimony that the cells of rodent ulcer may, in rare instances, produce constitutional infection by metastasis as well as those of ordinary epithelioma. But I cannot consider the case established as one of rodent ulcer. The author insists on the absence of "nests" in this case. The absence of these "nests" is not, however, an infallible criterion

in judging whether a growth is epitheliomatous or rodent. It is stated "that at many parts sharply-defined epithelial masses were not to be seen, but that young cells and nuclei lay closely pressed against each other, the distinction between stroma cells and epithelial cells being not possible. The adjacent cutis-border showed numberless young epithelial formations which, taking their origin partly from the lanugo-hair glands and partly from the rete mucosum, penetrated downwards into the stroma." The description, it appears to me, applies much more closely to a case of epidermic epithelioma than to rodent ulcer, and this is just one of those instances in which the elective properties of the staining agents recently employed in microscopical research may be advantageously used in making an otherwise difficult histological diagnosis.

Mr. Hulke (Pathological Society's 'Transactions,' vol. xxii) has reported on the histological appearances in five cases of rodent ulcer, and has recognised the cylindrical and bud-like forms of the cell-masses. He described the sub-columnar form of some of the cells and their occasional glandiform arrangement. An examination of Mr. Hulke's drawings seems to me to afford striking evidence of the difference between the cell-growth in rodent ulcer and in the epidermic epithelioma.

Dr. Collins Warren, of Boston, in the Boylston Prize Essay for 1872, has reported on five cases of Rodent ulcer. This investigator concludes that the cases of rodent ulcer were forms of epithelial cancer, and that they differed from the forms of epithelial cancer of which cancer of the lower lip is the type, in the small size of the epithelial cells; so far following Thiersch. He, however, makes statements which receive no support from the cases examined by Thiersch, Mr. Hulke, and myself. He found that the cells of the growth have a tendency to form themselves in the centre of the masses into the well-known epidermic balls, and that the edges of the masses were lost in smaller cells of an indifferent character, and this, although he states "that at certain parts of the edges of these cell structures the cells resembled cylinder-epithelium, reminding one of the shape and arrangement of the epithelium immediately surrounding the papillæ of the skin." "As we approach," he remarks at another place, "the periphery, cells of an epithelial character become fewer in number, and those which predominate here resemble the small round cells which are so frequently found in all morbid growths."

No such epidermic balls were to be seen in my sections nor are

they to be found in those figured by Thiersch and Hulke; although in some of my sections partially broken down epithelial structures belonging to the normal tissue—usually the remains of a hair follicle—at first sight, seemed to resemble them. I cannot help thinking that this must be the explanation of the "balls" which were found in Dr. Warren's cases.

Dr. Warren seems further to have been unsuccessful in preserving the well-defined border of the masses, and in distinguishing between the occasional clusters of exudation-cells and the true morbid growth. The limits between the two are, in reality, strictly defined, —leaving out of account the occasional leucocytes which are found in and about the membrana propria—and there is no such transition in the character of the cells towards the centre of the masses as Dr. Collins Warren describes. With the exception of the columnar border cells, all the others retain a fairly uniform size and appearance until they break down. *October 15th*, 1878.

---

## 4. *A case of multiple (lymphoid?) tumours, some of which disappeared under observation.*

By James Gairdner, M.D., and Joseph Coats, M.D.

(Introduced by the President.)

The following case was under the care of Dr. Alexander Thomson, Dumfries, and was seen, in consultation, by Dr. Gairdner, Glasgow. Certain of the structures were sent, after death, to Dr. Joseph Coats, Glasgow, who reported on them. The clinical part of the ensuing report is made up from notes by Dr. Thomson, Dr. Gairdner's report being included.

Mr. G—, æt. 52, was in robust health till a year or fourteen months before he was seen by Dr. Gairdner, which was at the end of July, 1878. The first divergence from health was the occurrence of tumours under the skin in different parts of the body. So far as he can recollect they first appeared on the abdomen, between the umbilicus and the crest of the ilium, next on the head, and then on

the shoulders. Pain accompanied the appearance of them, and the patient's attention was thus attracted to each fresh nodule. The pain is described as often of a severe and tearing character. As the tumours reached their full size the pain gradually diminished, and the attention was thus diverted from them. When, after a time, attention was again paid them, it often happened that they had disappeared. In some cases they were not lost sight of, but were seen gradually to diminish in size, and often so rapidly that a few days made a distinctly appreciable difference. This went on for six or seven months, the patient always hoping that as "his enemies" came and went, they might some day disappear altogether. This hope was vain, and the patient began to experience a certain languor, with loss of the former keen appetite.

About this time Dr. Thomson saw him for the first time. He found him on the whole vigorous, with little appreciably wrong except the tumours.

It is important to observe that about this time Dr. Thomson's attention was particularly directed to one of these tumours, which was stated to be among the first that had appeared. It had its seat in the abdominal wall, immediately above the crest of the ilium, near the anterior superior spine. It was the largest of any observed in the whole course of the illness, measuring about four inches by three. Dr. Thomson's first impression was that it was a fatty tumour, and it must have been tolerably well defined, as he concluded that it could be cut out. This tumour was examined at intervals for a month or two, and latterly it did not seem quite so large as at first. It was not seen again for about two months, and when looked for not a trace of it could be found. Dr. Thomson's impression is that other tumours came and went in the same way, but there is no other in which the evidence is so distinct as in this one.

The above account brings the case down to about ten months from the onset of the disease, and about two months from its termination. By this time the general health showed decided symptoms of failure, with loss of flesh and impaired appetite. Two weeks later there was a sudden attack of sickness with hiccough, but without vomiting. Again, another two weeks later, there was sickness and vomiting and hiccough, with a severe spasmodic pain, extending from the region of the left kidney to the umbilicus, or a little below it. These symptoms suggested a calculus in the ureter, but the urine gave no indications. The urgent symptoms abated in

about twenty-four hours, but the hiccough continued, in a lesser degree, for some time.

The patient continued in an unsatisfactory state for some weeks; there was occasional sickness and vomiting, with hiccough, and a pain occurred in the right side similar to that described above in the left, but less severe. There was again slight improvement, but not of a satisfactory character. Slight hiccough showed itself from time to time. About this time (July 27th, 1878) he was seen by Dr. Gairdner, who made the following note:

Glasgow; August 2nd, 1878.

I had an opportunity a few days ago of seeing, in consultation with Dr. Alexander Thomson, Mr. G—, of Dumfries, and as the facts of the case seemed to me extraordinary, and beyond the scope of my own previous experience, as well as of such reading as I have been able to bring to bear on the subject at short notice, I think it desirable for future reference to indicate briefly, in writing, the points which struck me most in an hour's visit, leaving to Dr. Thomson to fill up any deficiencies or rectify any errors of statement.

Mr. G— is the subject of a large number of tumours distributed over various parts of his body, but of the exact proportion in which they are so distributed I cannot profess here to give any account.

The presumption, of course, arises that these multiple tumours are of similar nature and origin, and there is nothing in their external characters to contradict this view of them, except what will appear in the following notes. As regards their influence on the general health, it must be admitted that Mr. G— has lost weight considerably, and that he is somewhat exhausted with pain and anxiety; but I do not think that any one would readily pronounce him, *primâ facie*, the victim of any special, or of any malignant, cachexy. There is no direct evidence of the existence of any of the tumours, or of any disease, in the internal organs.

The tumours may be roughly divided into the immediately subcutaneous, and those which are more or less loosely attached in the connective tissue. The latter class comprises the more considerable tumours in point of size. The largest I actually handled seemed to me about $2\frac{1}{2}'' \times 1\frac{1}{2}''$, and it was, like most of the others of its class, quite devoid of any special attachment to skin, muscle, fascia, bone, cartilage, or, in fact, to any anatomical structure which could be identified from without. *Form*, in the main, globular or ovoid;

*feeling to the hand*, like a sarcoma, or perhaps a firm fatty tumour; *not* cystic; *not* so firm as a fibroid, but well defined, apparently homogeneous, and with nothing of the peculiar density and indefinitely encroaching character of scirrhus.

What I have called the immediately subcutaneous class of these tumours I define thus:—They are so much in connection with the deep layer of the skin as to raise a question of their having originated in the dermoid tissues or in some of their appendages. Such of these tumours as I examined are commonly not more than the size of a horse bean, and they suggested to me, in some instances, the appearance as described both of molluscum simplex and of the painful subcutaneous tubercle or neuroma.

Molluscum contagiosum of Bateman is quite familiar to me, and I looked, of course, for the evidences of a follicular origin, as in that disease, but failed to detect them. One or two presented obscure indications as of a *punctum* or closed orifice, but I suspect they had been possibly interfered with, as I was told that one or two had been punctured with a needle, and that some serous juice had escaped. Most of these small subcutaneous tumours distinctly adhered to the skin, which was stretched over them, smooth, and a little discoloured, verging towards bluish; but they were not very prominent, not pendulous, not at all disposed to ulcerate, and had certainly not the exquisitely painful character of the growths first described by Mr. Wood. There were no greatly dilated veins in the neighbourhood of these tumours, and no evidences of obstructed lymphatics; nor did they usually occupy the sites of the principal glandular or vascular areas.

Notwithstanding the remark above as to the absence of the exquisite pain on handling proper to the subcutaneous neuromata, it must be taken as a fact that the growth of these tumours has been, on the whole, attended by considerable pain—not very definitely localised, indeed, and by no means always in the tumour itself, nor yet radiating from it in the direction of any particular nerve-area. Nor could I ascertain, in the course of examination (but I admit not an exhaustive one), that the *history* of pain in any way pointed to pressure on nerve-trunks, *i.e.* it was not associated with numbness or tingling, &c.

My attention was particularly attracted by one of the tumours in the loose connective tissue of the scrotum. Though of the smaller kind (not so big as a horse bean) it was quite distinct in its outline

and form; not at all painful on pressure; easily moved about, and certainly not connected either with the cord or epididymis, which were quite normal. This tumour had no close connection either with skin or dartos. But the most curious fact of all about these tumours, and to me so curious as to put them altogether beyond the range of my pathological information and reading, is the fact, well-attested, as I believe, both by the patient and Dr. Thomson, that in the course of the long history of their evolution and gradual multiplication, many of them, or at least a sufficient number to place the fact beyond doubt, have absolutely disappeared, without leaving any trace of thickening or morbid alteration. One site was pointed out to me on the left side, not far from the anterior superior iliac spine, where the abdominal wall had been occupied by a tumour one half larger than the largest described above, and of essentially the same character. The growth of this tumour had been attended by much pain (I think Dr. Thomson said *more* pain than any existing tumour). But on careful examination I could detect no trace of it remaining.

Of the recognised varieties of tumour the following only seem to me to present characters in common with any of the growths here described, and none of them can be said to correspond accurately with the description here given in all points: Lipoma, adenoma, lymphoma, sarcoma, neuroma.

Some of the more superficial tumours, separately considered, might pass for molluscum or some kind of follicular outgrowth; but the deeper class could have had no such origin, nor were they, I think, distinctly glandular.

Dr. Gairdner suggested that as a present remedial measure iodide of arsenic might be tried, in doses of $\frac{1}{12}$th gr. *ter die*, in pill, if found to be well borne by the stomach; and as further tending to throw light on the case, that an opportunity should be had, if possible, for excising one of the smaller and more superficial growths with a piece of skin, to be sent to Sir James Paget or other first class authority for opinion, along with a statement of the facts. The rapid sinking of the patient prevented this suggestion from being adopted.

On August 3rd it was noted by Dr. Thomson that there were at least thirty tumours distinguishable in or under the skin. "Of these—

"Five are on the scalp, and have every appearance of the ordinary sebaceous tumour. None of them is prominent, or exceeds ½ an inch in diameter.

"There are seventeen on the body, from the root of the neck to the level of the nipples. More particularly, there are—

"Three on the right side, in the triangle above the clavicle, two being deep, and one near the skin. The largest is 2 inches in diameter.

"Five about the shoulders, scapula, and clavicle; the largest ½ an inch in diameter.

"One on the left side, an inch above the middle of the clavicle, is 1½ inch in its largest diameter, and very distinctly lobulated.

"One over the clavicle, an inch from the acromion, measures ⅓ of an inch in diameter.

"Five in a row, extending from a point 2 inches external to the left nipple to the posterior boundary of the axilla.

"Two over the pectoral muscle; lobulated.

"Besides these there are twelve described in different parts of the body.

"One on the front of the right arm, 4 inches below the shoulder-joint; the skin free; firmer in its deep attachment.

"One in the abdominal wall to the left of the umbilicus, and 3 inches upwards and outwards from it.

"One over the middle of Poupart's ligament on the left side.

"One in the scrotum; attachments very loose; the size of a small bean; surface regular.

"One on the right thigh, over the vessels, 3 inches below Poupart's ligament.

"One a little above the external condyle of the right femur.

"One over the tendinous portion of the right gastrocnemius.

"One inside the internal hamstrings of the left leg, 3 inches above the knee-joint.

"Four near the middle of the back, two to the right, and two to the left of the spinous processes, and about 3 inches from them.

"In all there are thus enumerated no less than thirty-four tumours. The largest is about 2½ by 2 inches, and situated on the back over the short ribs, and about 3 inches from the spinous processes. There has been a good deal of pain in this one for some time till a few days ago, and a feeling of sickness accompanied the pain."

These tumours varied in size from the dimensions of a split-pea to 2½ by 2 inches. A large proportion of them were from a ½ to ¾ of an inch in diameter, or about the area of a shilling piece. They varied also in their relation to the skin. Some, and chiefly the smaller, were near the skin, and these generally presented a bluish aspect. Others were deeper, and allowed of the skin being moved freely over them, but at the same time produced a distinct projection. A third class were only to be detected by manipulation, having a still deeper seat.

The general health of the patient continued to fail. He lost flesh rapidly, was languid, drowsy, and low spirited, had little appetite, was frequently sick, and never entirely free from hiccough. From this period he rapidly sank. There was no distinct pain, but sickness, vomiting, hiccough, were very troublesome, and it became probable that there were internal tumours. Death occurred on August 10th, the hiccough being a very troublesome symptom to the end.

A *post-mortem* examination was made by Dr. Thomson and Dr. H. L. Norris. In addition to the tumours in the skin and subcutaneous tissue there were a number of growths in the abdominal cavity, many of them being in connection with the intestine. Several of these tumours were removed and forwarded to Dr. Joseph Coats for examination. He reports as follows:

1. Right kidney and suprarenal capsule.—The kidney is normal in size and general appearance. In its fatty external capsule there are several groups of tumours, the individual growths being of comparatively small size, and simply replacing certain portions of the fatty capsule. The suprarenal capsule is present, and has simply been opened up (in removing); there are no proper tumours in its substance.

2. Left suprarenal capsule.—This consists of a flattened globular mass, about 3½ inches in diameter. On section it is seen to be composed of a tolerably firm external portion, and a softened broken-down interior, very like softening blood clot. At one or two places in the external wall a soft rounded tumour appears. In the external wall of this mass the microscope reveals in some places collections of cells of a comparatively large size with granular contents, and many of them of a brown colour. These cells closely resemble those of the suprarenal capsule. The internal portions of the mass have a structure similar to the other tumours, to be described further on.

3. Tumour found below right kidney, and behind cæcum.—It consists of an irregular globular mass, 2½ inches in diameter, and composed partly of soft tissue and partly of broken-down hæmorrhagic material.

4. A small portion of small intestine with a partially pedunculated tumour, the size of a half cherry, projecting from the internal surface.

5. A piece of small intestine with a rounded tumour about ¼ of an inch in diameter, situated in the mesentery, but close to the attachment of the intestine. The tumour partially bulges against the intestinal wall.

6. A piece of intestine with a rounded pedunculated tumour, 1¼ inch in diameter, projecting from the mucous membrane, and filling the calibre of the gut.

7. A small tumour from the transverse meso-colon.

8, 9, 10, 11. Tumours, mostly of small size, from the subcutaneous tissue. One of them is of an elongated shape, and measures about 2 inches in length.

All the tumours are soft in texture, and nearly all of them are broken down and mixed with blood clot. On microscopic examination they are found to be mainly composed of round cells with a very slightly developed reticulum. The cells are as a rule rather larger than red blood-corpuscles, their average size being about $\frac{1}{3200}''$, but with considerable variations. The cells are occasionally mixed with the remains of the tissue of the part, such as fat, fibrous tissue, smooth muscle.

The great tendency to breaking down and to hæmorrhage is a striking feature in most of these tumours, and may possibly explain the disappearance of some of them observed during life.

*April 29th*, 1879.

*Report of the Committee on Morbid Growths upon Dr. Gairdner's specimens of multiple tumours.*—The pieces submitted to us for examination comprised two large lobulated masses with soft and blood-coloured interior, but with a moderately firm and thick capsule; two pieces of skin, each with a small nodule beneath them; a pedunculated polypoid growth from some part of the small intestine; a large mass surrounding and imbedding the right kidney and suprarenal capsule, but apparently not involving either, and some smaller pieces which appeared to be

peritoneal and subperitoneal growths. All these parts were examined with the exception of the two large masses, which were too soft to promise any satisfactory result; and we may say of all that they were not in good condition for microscopical examination.

As regards the ultimate element of these growths there is a remarkable uniformity in all. They are composed of small, round, nucleated cells, closely but very regularly arranged in a structureless protoplasm. In no part is there any reticulum such as is found in lymphatic tissue, but in some places there is evidence of a rough or unnatural process of organisation, as shown by the elongated form of some of the cells, and even by the presence of fibroid tissue. They therefore correspond in all respects to the less pronounced forms of round-cell sarcoma, the granulation sarcoma, and, perhaps, glio sarcoma. But we must also add that tumours, with similar histological characters, have been called lymphomas ('Path. Soc. Trans.,' vol. xxi, p. 384), though upon the histological evidence it is not easy to see the grounds for this; and we consider that, microscopically, these growths are round-cell sarcomata. The kidney—the only one of the solid viscera submitted to us—was healthy.

Two special points strike us as of interest, from an examination of these specimens.

First, we notice that most of the growths are encapsuled, but to this we must add that, besides the larger encapsuled masses, there are many local collections of similar cells, discovered by the microscope, nearly always round the blood-vessels, which are not limited at their circumference, and which make it probable that diffusion or infiltration might have become one of the predominant characteristics of the growth eventually. In the case of the polypoid mass from the intestinal wall the growth and muscular fibre are so blended, that it is already impossible to distinguish the limits of the one or the other.

Secondly, the growths are all remarkable for the large size of their blood-vessels—or, rather, blood-channels. In vertical section many of the nodules are permeated by large tortuous passages formed by tubular systems of cells, which remind us somewhat of the splenic structure, and of the perivascular systems elsewhere. A transverse section in like manner shows a large central channel, with no definite limiting membrane in many places, but in some with a distinct membrana propria and endothelial lining, or even a fibrous wall of some thickness, and around it a circular column of

cells very closely arranged. Some of these spaces contain blood-clot. Such a structure as this suggests to us a very plausible hypothesis for the rapid disappearance of these tumours during life. When we remember how rapidly the spleen will enlarge and subside, and that this is in part due to swelling of the follicles and multiplication of its lymphatic elements, there is no great improbability in the view that growths, with a structure such as these exhibit, with their large blood-channels which have no limiting membrane between them and the surrounding cells, loosely held together, should subside as it were spontaneously. And we venture to suggest, as a step towards the confirmation or otherwise of this notion, that in the future the blood of all such cases should be most carefully examined, particularly during the subsidence of the tumours.

JAMES F. GOODHART,
HENRY T. BUTLIN.

---

## 5. *Sequel of a case of multiple round-celled sarcoma in a boy (lympho-sarcoma).*

By HENRY T. BUTLIN.

THE boy, who was exhibited last session to the Pathological Society, and who was suffering from sarcomatous tumours in several parts of his body, died on the 10th of August of the present year. The day after he was seen by the members of the Society, two tumours, one in front, and the other at the back of the chest, were removed by Mr. Holden. They presented exactly the same general and microscopical characters as those which had been previously examined (vol. xxix, pl. v). For some time the wounds healed well, and the boy appeared likely to make a good recovery from the operations; but within a few weeks a tumour began to form in the right forearm, apparently in connection with the ulna, which rapidly increased in size. And soon a small tumour formed in the right arm, deep between the muscles. Shortly afterwards sprouting masses sprung up in the operation-wounds, which were

still unhealed. And then the glands in each axilla began to enlarge and rapidly attained a considerable size. During the whole of this period the tumours which had previously existed continued to increase in size, not excepting the right testis, which had even diminished in size before, but which now very slowly enlarged. The sprouting masses in the operation-wounds grew into large tumours; the tumour of the forearm ulcerated, and finally sloughed out, leaving a cavity large enough to thrust one's fist into. The boy became weaker and weaker, until at last he sank, worn out by exhaustion.

The autopsy was made during my absence from town, but portions of the different tumours were preserved and examined microscopically. All the tumours which were cut into presented similar general characters to those which had been removed, and the testes were similarly diseased. There were no tumours in any of the viscera of the chest and abdomen; but a chain of enlarged glands ran along the brim of the pelvis on each side nearly to the sacrum. These glands presented the same general characters as the tumours but those on the right side were much larger than those on the left side, and terminated in a large mass, which descended deeply into the pelvis around the rectum, the wall of which was extensively implicated by the disease. Microscopical examination of the recurrent masses, of the enlarged glands, and of the testes, gave precisely the same results as before, except that there was a greater quantity of reteform tissue than was observed in the first and second tumours, so that the sections gave rather the idea of lympho-sarcoma than of round-celled sarcoma.

I still believe that most of these tumours were separate outbreaks of the same disease, and did not stand to each other in the relation of primary and secondary tumours. Even the tumours of the testes seem to be due to a separate outbreak of the disease, for, although the testes are tolerably frequently the seat of primary growths, they are exceedingly rarely affected by secondary carcinoma or sarcoma.

Three new features are observable in the case since last it came before the Society. First, recurrence of the disease *in situ* after removal; second, affection of the lymphatic glands; third, the escape of the internal organs.

With regard to the first of these points, it may be said that the two tumours last removed were not so thoroughly removed as the earlier tumours. My impression is, however, from careful observa-

tion of the removal in each case, that the operation was more complete in the last cases than in the first, partly because the first tumour was difficult to remove on account of its situation (parotid region), and partly because the nature of the disease was better known, and recurrence was more dreaded after the later operations. I can only account for this recurrence by believing that the disease had become more malignant in its later stages, and that this recurrence was an expression of that greater malignancy.

Affection of the lymphatic glands, although not common in sarcoma, is nevertheless not so rare that it can be regarded as extraordinary in the present instance. The only remarkable point is, that a disease which possessed the power of attacking the lymphatic glands, and producing in them secondary formations, should have delayed so long the manifestation of that power. Here, again, one must fall back upon the theory of increased malignancy with increased age of the disease.

And one cannot help believing that, although the internal organs escaped infection, this would not have been the case had the disease lasted longer. Just as recurrence *in sitû* occurred late in the history of the disease, and as the infection of the glands was delayed until the disease had nearly terminated the patient's existence, so possibly was the more distant infection through the blood reserved for a still later period, which was never reached, owing to the patient falling a victim to the exhaustion produced by the drain of the external and glandular tumours.

The diminution in size of the testis may possibly be explained by associating it with the very considerable enlargement of the lymphatic glands on the right side of the pelvis. It seems as if these glands had made a partially successful attempt to relieve the testis of its disease, and in that attempt had themselves fallen a prey to the tumour infection, which, probably, would have extended from gland to gland in the lumbar region, had it not found a kind of outlet in the large mass which descended into the pelvis.

*October* 15*th*, 1879.

## 6. *Sarcoma of the scapula in an infant, followed by multiple sarcomata in various organs and tissues.*

By JOHN H. MORGAN.

THE mother of this child stated that she was 45 years old, and had enjoyed good health. Her mother is still alive, and her father died at the age of 66 from some affection of the brain. Her husband is a healthy man and is still living. They have had thirteen children, nine of whom have died of various complaints at early ages. One died of inflammation of the lungs, one of gastric fever, two or three have died in convulsions, one of these being the twelfth child, who was also observed to have some hard lumps in the skin at the time of its death.

The patient was the thirteenth child, a male, and when born, appeared healthy and particularly well nourished and strong. When four weeks old, the mother noticed a small lump over the left shoulder, and brought the child to me, supposing that it had suffered some rough handling on the part of the nurse.

There existed over the acromion process of the left scapula a hard, firm, immovable lump, about the size of a nut, to which the skin was not attached. There was no discoloration, no crepitus, apparently no pain or other evidence of injury.

Three days after this the lump was considerably larger, and another of a similar character appeared at the lower angle of the left scapula. The child was observed to be a good deal wasted, and was constantly hungry. Its motions were somewhat foul and frequent, but of ordinary consistency. The urine passed was normal, never showing traces of blood. In the course of two or three days several small tubercles appeared in the subcutaneous cellular tissue of the back, chest, and abdomen. The two lumps already noticed increased in size, and the child showed more evident signs of wasting rapidly. It had no cough, and slept constantly, but continued to display enormous appetite. It was too feeble to allow any thorough examination, but as the rest of the body wasted, the abdomen was observed to become more and more distended. The child continued to grow feebler but lingered for three weeks, when it became comatose, and died five weeks after the original tumour

was first noticed. No urine was passed during the last twenty-four hours.

I made an examination twelve hours after death. The body was very emaciated, and the abdomen greatly distended.

A large, hard tumour, the size of a pigeon's egg, was attached to the upper part of the left scapula. Over it the skin was freely movable, and it appeared to grow from below the periosteum of the bone, and was covered by a thin, shiny, fibrous capsule. On section it was firm and consistent throughout, no degenerative changes having taken place. In every respect similar, was a smaller tumour which was attached to the apex of the same bone, and there existed in the subcutaneous tissue of the whole trunk numerous small scattered tubercles of the same nature.

The lungs were perfectly healthy.

There was no disease of the pericardium, but the heart was enlarged and distended by three larger and several smaller nodules of secondary deposit. The three larger masses projected eccentrically so that the cavities of the viscus were not encroached upon. They were about the size of small filberts, one projecting from the right side of the apex, another from the upper part of the right ventricle, and another from the posterior aspect of the left ventricle. On section they were yellow in colour, softening towards the centre, and freely supplied with blood-vessels around the margin. In appearance they closely resembled a secondary encephaloid deposit of the liver. They were entirely confined to the muscular tissue, the mucous membrane of the heart and the visceral layer of the pericardium being smooth and natural.

On opening the abdomen, the intestines were found firmly adherent to a large round mass, which sprang from the back of the cavity and protruded considerably to the left of the median line. This mass was the right kidney much altered and enlarged. It measured five inches vertically, and three inches on horizontal section, and it had projected in every direction so as to occupy the greater part of the abdominal cavity. The upper part was converted into a large irregular mass, soft and vascular, and broken down in the centre, resembling in appearance an encephaloid deposit, which had destroyed all the glandular substance of the upper half of the kidney. The lower half was filled with several smaller masses of a similar nature, but in this part of the gland the calyces were seen to be much enlarged, and into them projected the distended pyramids.

The exterior of the organ was smooth, only slightly nodulated, and the whole resembled in shape a good-sized pear. A similar state of things existed on a much smaller scale in the left kidney, in which there were deposits in the upper and middle parts, the calyces were similarly dilated, but there was more of the secreting structure left. The external surface was irregular and covered by numerous nodules of deposit. On this side also the supra-renal capsule was filled with numerous small masses of encephaloid material. The ureters and bladder showed no traces of disease. The spleen appeared to be healthy, and in the liver were a few scattered patches of encephaloid deposit, similar in appearance to those found in the other organs.

Several microscopic sections were made of the original tumour, and in all there appeared to be densely aggregated masses of cells, for the most part round or oval in shape, but occasionally elongated into a spindle-shaped variety. Each contained a nucleus, in some were nuclei and a nucleolus; they also contained granular matter, and had well-marked outlines. These cells were contained in a structure which was in some parts delicately fibrillated and in others granular, but there was no alveolar structure as seen in a carcinoma, nor were there any myeloid cells. The vessels were large and plentiful.

At the margin of the tumour was seen a thin covering of periosteum, and near it the cells varied much in size and form, while in the central parts of the tumour they were rounder and more regular both in size and shape. In many parts of the sections the nuclei and cells were elongated and showed a tendency to become arranged parallel to one another, and in such places there was more evidence of a fibrillated stroma; the irregularity of the form of the cells, and more especially of those in proximity to the fibrous investment, seemed to show that the tumour was growing under considerable pressure.

The growths in the other organs were generally so soft as not to allow of any satisfactory examination, but one of the smaller was taken from the liver, and presented under the microscope the main characteristics of the original tumour.

The interesting features of this case lie in the very early age of the patient in whom it occurred, and in the selection of organs in which the growth was repeated, or, perhaps I should say, multiplied.

I have been unable to lay my hands on any case in which a similar growth has been observed at so early an age, though I think

it possible that many of those tumours which were formerly described as cancerous would turn out on closer investigation to bear some of the characters which belong more correctly to the group of the sarcomata, and cases of so-called congenital cancer have been not unfrequently described.

Mr. Travers has figured a specimen of congenital encephaloid of the eye, observed by himself and Sir Astley Cooper when the child was eight months old, in which the eyeball at birth was as large as a walnut, and, as since that time so many cases resembling encephaloid, but classified now as gliomata, have been observed, this may have been a case of this sort occurring congenitally.

Mr. Carter has described a case of glioma, in which he removed the eyeball, occurring in a child of three months, which died of the disease, extending to her brain three years after, the disease having meantime recurred in the remaining eye.

Three years ago Mr. Walsham exhibited a specimen to the Society of a tumour taken from the clavicle of a boy aged ten, the microscopical characters of which seem to have been very similar to those in the present instance; and the same gentleman exhibited last year the leg of a child, aged five months, which had been amputated on account of a large tumour, which proved to be a spindle-celled sarcoma, growing from the intermuscular fascia of the back of the leg.

The number and size of the blood-vessels accounted for the widespread and rapid dissemination of the malignant deposit, but although, as was observed in a case which Mr. Butlin communicated to the Society last year (vol. xxix, p. 211), the tumours recur in very various organs, it is noteworthy that the lungs which, as observed by Billroth, are most frequently affected secondarily in these cases, were, in the present instance, perfectly free from disease, while the kidneys and heart are perhaps the organs least seldom found to be the seat of secondary deposit.

There can be little doubt that the tumour of the scapula was the earliest to be developed. Firstly, because the subperiosteal tissue is a favourite seat for such growths; and secondly, had the growth originated in any of the organs in which it was afterwards found to exist, the general wasting and the abdominal swelling must have taken place earlier. Even had the diagnosis of the tumour been more certain, the situation in which it was found and the extreme youth of the patient would have rendered any idea of removal futile,

while the rapid dissemination of the morbid deposit points to the hopelessness of such an undertaking even had these circumstances been more favorable. *December 3rd*, 1878.

---

## 7. *Subperiosteal sarcoma of femur.*

By JOHN H. MORGAN.

THE child from whom this tumour was removed was brought to me as an out-patient at the Hospital for Sick Children. When first seen she was three and a half years of age; a nervous, delicate child. The father was over sixty years old, and an invalid from gout. The mother was a healthy young woman with a good family history. Five months before being brought to me the child had been unable to walk on account of pain in the right leg. This improved for a short time, but not long afterwards she complained of pain in the right knee, and soon after this the thigh above the knee was observed to be swollen. She was then taken to the Samaritan Hospital, where the nature of the affection was diagnosed by Mr. Doran. When first seen by me the right thigh was considerably enlarged—measuring eleven inches—as compared to the left, which measured eight at a corresponding point. The tumour was hot on the surface, and the subcutaneous veins were large and numerous. The swelling was confined to the lower part of the thigh, was of a pyriform shape, and presented an even surface. There was pain on pressing the inner condyle of the femur. No glands were enlarged in the groin or abdomen, and the knee-joint was not involved, and moved freely and painlessly. Occasionally the child suffered paroxysms of acute pain in the swelling, which seemed to occur about once a fortnight, and to last for one or two days. There was an indistinct sense of fluctuation in the swelling, but there was no part in which fluid could be detected. In the course of two months the circumference of the thigh had increased an inch and a half, and the sudden accessions of pain became more frequent.

After consultation with Mr. Smith I made an exploratory incision under antiseptic precautions, and found the tumour enclosed in a firm capsule, but of soft, vascular nature. Some was removed, and, examined under the microscope, showed all the characters of a rapidly growing sarcoma. This operation was followed by a good deal of hæmorrhage, but the child suffered no pain, and in a few days had quite recovered. On the fourth day following I amputated the limb at the hip-joint in the usual manner. The aorta was compressed by the thumbs of a colleague, and the vessels of the anterior flap were secured before cutting the posterior. A very small quantity of blood was lost, and the child left the table with a fair and perceptible pulse. The wound was not dressed antiseptically, but a drainage-tube was carried through it from the extreme points of the incisions. On the thirtieth day the child was taken down to enjoy a treat in one of the other wards, and this caused her to catch an attack of bronchitis, from which she suffered for some days. With this exception she made a quick and thorough recovery from the operation. At the end of seven weeks she was able to be taken to her home with the wound very nearly healed. In a short time this was quite healed, and the child has since remained in good health, and has gained flesh.

The femur measured nine inches in length, and the shaft of the bone had an anterior curving as if from rickets. The head of the bone, the epiphysis of the trochanter, and the epiphysis of the lower extremity were hypervascular, but otherwise sound, and were not affected by the growth, which was entirely confined to the diaphysis and its periosteum. Round this portion of the bone the growth was developed in a pyriform shape, with the apex upwards. About an inch from the trochanter the periosteum commences to separate gradually from the bone, and, entirely enveloping the tumour, is continuous below with the periosteum of the lower epiphysis. Although surrounded by fat and degenerated muscular tissue the periosteum was throughout thick, but of the normal colour and vascularity. At the upper part it has taken on healthy action, and for about an inch it has been converted into a ring of bone, which thus encloses the uppermost part of the tumour, and is continuous with the shaft of the bone above and with the periosteum below. From this covering of the tumour can be seen processes of thin fibrous tissue running vertically down to the surface of the bone, with which they appear to be loosely connected by means of the

blood-vessels which enter it. These fibrillæ form spaces in which the cells of the tumour are contained, and they could be easily detached from the bone but not from the périosteum.

Such was the general arrangement of the tumour as it appeared on its anterior aspect, but posteriorly, at the part corresponding to the popliteal space, the shaft of the bone, which is otherwise continuous, and to all appearance normally developed and nourished, has been encroached upon by the new growth. Here the tumour has invaded the compact tissue of the bone, and has exposed the medullary canal. In this part, as might be expected from the vascularity and the loose cellular tissue of this region, the growth has been most active. Its only irregularity of surface is presented by a sort of lobe, which projects backwards into the popliteal space. This lobe is composed very largely of calcareous matter, which is freely scattered through the mass of the growth in this region.

Under the microscope sections of the growth showed, for the most part, the characters of a round-celled sarcoma enclosed in much fibrous tissue, and very fully supplied with blood-vessels. The cells are mostly round, with dark nuclei, but in some parts are of the spindle-celled variety. Sections from that part of the tumour which occupies the popliteal space show numerous spiculæ of true bone-tissue embedded in a mass of round cells. In other parts bone-corpuscles are developed in the fibrillæ in which the mass of the growth was enclosed. *April 29th*, 1879.

---

## 8. *Recurrent fibroid tumour of the scapula.*

By Christopher Heath.

Mr. R. V—, æt. 18, first came under my notice in August, 1875, with a swelling of the right shoulder, thought to be caused by the "kicking" of a gun. A year later the swelling was more defined, concealing the head of the humerus and coracoid process. In April, 1877, the tumour had increased, and gave pain, and in May I removed it, when it proved to be a fibroid tumour connected

with the coracoid process, apparently originating in and taking the place of the pectoralis major muscle.

In February, 1879, the patient consulted me again, when I found that he had enjoyed good use of the arm, but had latterly noticed an enlargement in the axilla and neck. I found a small recurrent growth over the coracoid process, and a larger mass in the axilla, fixed to the scapula and moving with it. There was another mass in the posterior triangle, which was painful on pressure, but did not apparently involve the main vessels or nerves. Upon consultation with Mr. Erichsen it was agreed that removal of the scapula should be performed, and this was done on February 15th, 1879, with but little loss of blood. The patient, however, never rallied completely, and died early on the 17th.

The preparation included the entire scapula with the muscles attached to it, and the outer half of the clavicle. The tumour was principally upon the ventral surface, where it almost completely replaced the muscular fibres of the sub-scapularis. The same thing had occurred in the supra-spinatus and to a smaller degree in the infra-spinatus. The fibres of the latissimus dorsi were also considerably affected. *February 18th*, 1879.

*Report of the Committee on Morbid Growths on Mr. Heath's case of removal of the scapula.*—The specimen handed to us consists of the scapula and the outer third of the clavicle with parts of the muscles attached to these bones. Large rounded masses of a new growth have infiltrated many of these muscles, consisting of some separate and other confluent nodules, very firm in consistence, and white on section. The muscles principally affected are the sub-scapularis and the supra-spinatus; the masses of tumour in these two muscles are connected together over the upper border of the scapula, and project both in front and behind the clavicle. Some nodules exist in the teres muscles, but apparently none in the infra-spinatus. The growth is in close contact with the clavicle, but neither of the bones is, so far as we can see, affected.

The structure of the growth is that of a fibro-sarcoma, consisting in parts of moderately well-developed fibrous tissue, in parts of interlacing bundles of rather small spindle cells. The more cellular part is shown in the accompanying drawing.

MARCUS BECK,
RICKMAN J. GODLEE.

## 9. *Primary epithelioma of tonsil (living specimen).*

By Lennox Browne.

This patient is exhibited for two reasons, first, because of the intrinsic interest of the case, and, secondly, because it well illustrates the clinical differences between malignant disease of the tonsil and syphilis in the same region, a point which I am anxious to urge, since it was recently stated by a very high authority on the occasion of my showing other specimens of similar character, that these distinctions are frequently by no means well defined.

With reference to the first point, I find no case of this form of cancer in the tonsil recorded in the 'Transactions' of the Society, and although Erichsen and other surgical authorities state that any form of cancer may affect this region, it is the first case I have seen of primary epithelioma of this gland, nor am I aware of any other case in which it has been reported in detail. The patient came under my care on November 21st, the same day as the last volume of the Society's 'Transactions' had been delivered into my hands. In that volume (p. 247) I had made the suggestion, warranted, as I thought, by my own experience and by that of other cases exhibited to this Society, that in all probability primary malignant disease of the tonsil is most usually of the nature of a lympho-sarcoma. I am still of the same opinion, but this present case [and—September, 1879—one other I have since seen] certainly came to me as a warning not to be too ready to generalise even with a fair proportion of experience. The history of the case is as follows:

John M—, æt. 39, an engine-driver, of temperate habits, had enjoyed good health until twelve months ago, when he first felt some discomfort in swallowing, with an inclination to spit while taking food. Eight years previously he remembered to have had a pain in the left side of his throat extending to the corresponding ear, but it passed away, and had not recurred. On this occasion, however, his wife, on looking into his throat, told him that there was a large lump on the left side, and he at once sought advice. Having been treated at various places, chiefly, as it appeared, on the supposition that the disease was syphilitic, but without any relief of his symptoms, he applied at the Central Throat and Ear Hospital on November 21st. The following were the principal points in his condition:

He was pale, and evidently emaciated, weighing 7 stone 12¼ lbs. as against 9 stone six months previously. His general health and appetite were poor; his pulse 92. His voice and articulation were slightly nasal, his left nostril being obstructed, but there was no impediment in oral breathing, nor in the mobility of the tongue. His breath was very fetid. He stated that swallowing of solids had become impossible, and that he lived principally on bread and milk and soup. His sense of taste had become impaired. He complained of a shooting pain starting below the ear as soon as he got warm in bed, with considerable pain in taking food if he attempted to swallow it at all hot.

His family parental history was good; his father and mother both having died at advanced ages. He had been married twelve years, and although his wife had had several miscarriages she had not given birth to any living child. It had been necessary for her "to have a portion of her jaw removed on account of a tumour found at the root of a tooth which had been extracted." He denied having had syphilis.

On examining the mouth it was seen that the left half of the soft palate and corresponding tonsil and faucial pillar were occupied by an almost white, but in parts slightly pink, fungating growth, extending from the left side of the tongue, and for a considerable distance into the pharynx. It was closely connected with the lower jaw, and the tissue of the soft palate around it was red and swollen, but not indurated. Beneath the left angle of the lower jaw was felt a hard fixed lump (glandular) extending to the tip of the hyoid bone.

A portion of the growth was removed by means of the galvano-cautery loop and submitted to microscopic examination, which showed it to be composed of abundant proliferation of epithelial cells with but scanty small-celled stroma.

*Remarks.*—I desire now briefly to indicate the chief points of distinction in the clinical history of cancer and syphilis of the tonsil as illustrated by this and other cases reported by me in previous volumes of the 'Transactions.'

Though the patient's own account may not by any means exclude the possibility of a coexistent syphilitic dyscrasia, the method in which the two diseases affect the tonsil (as, indeed, any other part of the throat) is wholly distinct, and to more particularly emphasise these differences I have contrasted the chief features of the two diseases in opposing columns,

| SYPHILIS. | CANCER. |
| --- | --- |
| *Functional symptoms.*—Swallowing sometimes difficult, but never impossible, though occasionally leading to return of fluids through the nostrils; but the sensation is essentially one of discomfort rather than of pain, with entire absence of pain when the parts are at rest. | *Functional symptoms.*—Dysphagia as it is the first is also the prominent symptom, and increases in severity so as to lead to total inability to take solid food. Acute lancinating pain is a prominent and almost constant symptom. As in malignant disease in the larynx, it is generally felt radiating from the throat to the ear, corresponding to the side of the throat attacked. |
| *Physical signs.*—The tonsils are generally affected by syphilis in its earlier stages, by deposition on their surface of mucous patches, and rarely in the advanced stages; when, however, the disease attacks the gland in tertiary syphilis it is as a perforating ulcer. There is but slight secondary glandular enlargement, which is not painful, and subsides with the cause of irritation. | *Physical signs.*—Cancer, whatever the form is, always manifested in the tonsils as a new growth, which attains considerable size before the occurrence of ulceration. There is always considerable infiltration and induration of neighbouring glands, which become as painful as the primary seat of disease. |
| Hæmorrhages are rare. | Hæmorrhages are frequent and profuse, and are often the direct cause of death. |
| Emaciation, if existing, is only in proportion to diminished nutriment taken. | Rapid emaciation commences long before dysphagia is by any means extreme, and advances even with relief of symptoms. |
| *Therapeutic.*—Most amenable to appropriate treatment. | *Therapeutic.*—Advances in spite of every measure, medicinal or surgical. |

*September*, 1879.—I have only to add that in the nine months since this patient was exhibited, large pieces of the growth have been removed by the galvano-caustic loop or by ordinary wire écraseur almost each week, at the express desire of the patient, who

experiences thereby great relief in both his breathing and swallowing. Nevertheless, the disease has progressed, and now involves the base of the tongue, epiglottis, and the angle of the jaw. He has lost exactly fourteen pounds since he first came under observation.

*December 3rd*, 1878.

---

## 10. *Small round-celled sarcoma of the upper jaw.*

By W. J. Walsham.

J. B—, æt. 67, was admitted into the Metropolitan Free Hospital March 10th, 1879, complaining of a swelling in the left nostril. He stated that he first felt pain in the infra-orbital region about three months previously. The pain increased in severity up to the time of his admission, and caused him sleepless nights.

On examination, a soft, lobulated, bluish-grey growth was observed in the left nostril, readily bleeding when touched. There was a slight bulging of the anterior wall of the antrum, but no depression of the palate, nor protrusion of the eyeball. There was no glandular enlargement. On March 20th Mr. Walsham removed the left superior maxillary bone with the whole of the growth. The patient made a rapid and complete recovery.

The growth, which sprang from the anterior wall of the antrum and filled the whole of that cavity, and projected through its internal wall into the nose, was of a soft, semi-gelatinous consistency, and bluish-grey colour. Under the microscope it was found to consist of small, round, nucleated cells, with very little intercellular substance, which had no alveolar arrangement. *May 20th*, 1879.

---

## 11. *A specimen of melanotic sarcoma of the eyeball.*

By W. Spencer Watson.

J. W—, a leather-dresser by trade, of cachectic aspect, æt. 58, applied at the South London Ophthalmic Hospital (February 7th, 1879) on account of loss of sight of his right eye. He had

suffered from sudden severe pain in the eye and temple two months before, and he thinks his sight was lost either at the time or shortly afterwards. He knows of no instance of cancer or tumour in any member of his family, and never had any blow or injury on the eye.

On testing the sight, the loss of vision of the affected eye was found to be total; to the ophthalmoscope the pupil was absolutely dark, and oblique focal illumination gave an indistinct view of a dark brownish or blackish-grey body occupying the lower part of the vitreous space at its outer side. This body was evidently behind the lens. The pupil acted very little, if at all, either under the stimulus of light, or in concert with the sound eye; but before atropine was applied it had not been noticeably dilated.

The tension of the eye was slightly in excess, and the temperature, as tested by the ocular thermometer, half a degree lower than that of the sound eye. The cornea presented a somewhat roughened surface, and the aqueous humour a somewhat turbid appearance, such as is seen commonly in acute glaucoma. Enucleation was performed under the influence of the mixed anæsthetics. The patient made a good recovery and is now wearing an artificial eye with comfort, his general health and aspect having decidedly improved. The socket for some weeks had a somewhat hard prominence, but this swelling has now assumed a less threatening aspect, and is probably nothing more than ordinary cicatrix tissue.

A section of the globe was made from back to front vertically, disclosing to view a dense coal-black mass occupying two thirds of the vitreous space, the broad base of attachment being adherent to the sclerotic, but easily separable from it in the greater part of its extent. The free surface of this tumour is smooth and rounded, and the whole mass lies within the sclerotic, not penetrating it at any point. A separate nodule, however, of the size of a millet seed and of a brownish-black colour lay outside the sclerotic below and to the outer side of the optic nerve. Healthy sclerotic intervened between this nodule and the internal tumour. Another black pigmented spot was observed on the external surface of the sclerotic at the point of exit of one of the vasa vorticosa. Two suspicious-looking dark spots in the areolar tissue of the orbit were removed at the time of the enucleation, but microscopic examination shows that the black appearance in these pieces of areolar tissue is due to altered blood-clot. The retina was completely detached and lying as a crumpled

membrane on the surface of the tumour. The subretinal space being occupied by thin, orange-tawny fluid. The vitreous humour had shrunk to very small dimensions. The lens was dark tinted but translucent, and the iris natural in appearance to the naked eye.

A section was made from back to front through the tumour and the ocular tissues. The tumour was then seen to be composed of (1) a central or medullary portion, not uniformly pigmented, but having various shades of dark grey, and approaching in parts to deep brown black; and (2) of a cortical coal-black portion which was closely adapted to the central portion and apparently continuous with it, but abruptly marked off from it by its more intense pigmentation. This cortical portion varied in thickness from half a line in the thinnest parts to about 2'''' or 3'''' in its thickest portions. Two or three small excavated spaces were seen in the central part, these spaces being lined with a reddish, clot-like, ragged membrane.

*Microscopic* examination gave no evidence of any structural arrangement of the elements which seemed entirely cellular. The dense pigmentation of the cells in the cortical portion of the tumour obscured even the *form* of the cells in the thinnest sections, and it was only when they were broken up into shreds and fragments, that the characteristic melanotic sarcoma cells were seen; some oval or rounded and filled with pigment, some less completely filled with pigment, so that the oval nucleus was visible; others having only a few scattered granules of pigment in their cavity and allowing the nucleus to stand out distinctly. The structure of the lighter portions of the tumour was that of highly pigmented sarcoma. The interstitial tissue could not be traced in the black portions, but in the lighter and less-pigmented portions the numerous spindle-shaped cells, with anastomosing fibrils springing from them, may be presumed to have formed the interstitial and supporting tissue in the meshes of which the rounded cells lay. Some of the cells in these parts of the tumour were multipolar with two or three fibrillæ, and resembled ganglion cells of nerve tissue. *April 1st*, 1879.

*P.S. October 17th*, 1879.—As bearing upon the liability to a recurrence of the disease, it is noteworthy that in the case of a woman with melanotic sarcoma of the eyeball (reported by the author in 'Path. Trans.,' vol. xxviii, p. 210) there has been no recurrence of the tumour, nor any evidence of any similar disease in any other part of the body, though three and three quarter years have elapsed since the enucleation of the eye.

## 12. *Case of unilateral cancer.*

By P. M. Braidwood, M.D.

(Introduced by the President.)

The patient, an unmarried lady, æt. 63, consulted me in December, 1877, on account of a cough which was very troublesome, and was unaccompanied by expectoration. Obtaining no relief from medicine she became gradually weaker and lost all appetite for food. She next tried change of air and was somewhat benefited. She had always enjoyed good health, and had led an active industrious life. Her only serious illness during many years had been a severe attack of rheumatism about five years previously; but for some years she had complained of a "weak back," and had felt her knees failing her. An aunt died of cancer, but there was no other family history of the disease. She came again under my care during February, 1878, when I found her in bed complaining of "sciatica," very severe on the left side and less so on the right. At times she complained of pain in the right knee. On ocular examination of the buttocks I observed a bluish, bruised appearance of the *left* buttock, and suspected an injury of the part. At my next visit she stated that about the end of July, 1877, when descending from a railway carriage on to the station-platform, she slipped and fell back on the carriage step on her left buttock; she felt shaken, was stiff for a few days, and had a sharp twinge in the left sacro-iliac joint when she moved in certain ways. These symptoms gradually passed off with rest, but three months later she complained of lumbago, and a month later she felt, in the left iliac region posteriorly, as if she was being stretched upwards and downwards when she walked.

*Symptoms.*—When I commenced attending her in February, 1878, besides "sciatica," she complained of feeling as if a red-hot poker was being thrust up her spine; also of a "burning" sensation at a spot on the outer side of the middle of her left thigh; occasionally of a very gnawing pain in her left knee, and later, of a painful "twittering" sensation up the spine. She also drew my attention to a small, firm swelling behind her left ear. She perspired on the trunk and upper limbs, but *not* on the lower limbs, while below the

knees she felt always cold, but between the trunk and knees she felt tolerably warm. Rubbing gently and firmly with the hand relieved the pain which at first was referred (on pressure) to the whole left gluteal region, but became gradually localised in the left sacro-iliac joint. During the following month (March, 1878) she became much troubled with neuralgia in the left side of the face. A firm swelling, resembling a node, appeared at the vertex of the left occipital bone. Another similar swelling (as large as a walnut), painful on pressure, was observed on the outer aspect of the middle of the left femur, and a smaller one on the temporal portion of the left temporal bone. Now a very troublesome cough set in, which hurt the patient much across the sacrum, requiring her to keep her right hand constantly firmly pressed against the bottom of the spine. Her pulse ranged from 90 to 100, the temperature was normal, the bowels obstinately constipated but without pain when they were moved, and the stomach refused to retain medicine. She gradually lost power over the left lower limb, and the pain diminished.

*Autopsy* on May 11th, 1878 (twenty-nine hours after death).—Body greatly emaciated. Heart pale and thin-walled. Right lung healthy; left compressed upwards and empty of air, with two or three pints of straw-coloured serum in the thoracic cavity. Liver cut firm from commencing scirrhosis. Spleen, intestines, and kidneys were healthy, excepting some bronze-coloured spots on the splenic surface. Uterus showed small fibroids embedded in its walls, and each ovary showed a cyst of the size of a small apple. The lower lumbar vertebra projected forwards and to the right side. The last lumbar vertebra was softened and could be readily cut with a knife, while the last intervertebral cartilage was atrophied. The left ilium was found swollen, softened, readily incised, revealing in its centre a cavity filled with dark-coloured, bloody fluid, like cancerous juice. This juice, examined microscopically in its fresh state, exhibited the well-known appearance ("mutter-zellen," or "plaques globules") of medullary cancerous fluid. The left sacro-iliac joint was disorganised and dislocated, the ilium projecting forwards. On the inner surface of one of the ribs forming the left thorax was found an oval swelling, like a node, which was readily incised. The other similar swellings on the left temporal bone, left femur, &c., were also readily cut with the knife, and appeared to be of like degenerative nature to the left ilium. The gall-bladder was dis-

tended by calculi. Some of the mesenteric glands in the left half of the abdomen were observed to be enlarged. The left psoas, iliacus, and adjacent muscles were atrophied.

*Microscopical observations.*—(*a.*) Ilium (×30) showed healthy bone tinged pale pink, while the diseased part had a brownish-red, granular appearance. Haversian channels greatly dilated.

(*b.*) Ilium (×30) more deeply stained by carmine. Haversian channels enlarged, their walls thickened, and their lining epithelium greatly increased in amount. They contained granular matter, and between them were to be seen masses of proliferating cells. In some parts the whole tissue seemed broken down into a fibro-granular mass.

(*c.*) Ilium (×350). The epithelial supergrowth in the greatly-distended Haversian canals was well seen in those cut transversely, whilst those cut lengthways exhibited a transparent, slightly-tinged exudation interspersed with large granular cells. Between the Haversian channels, and in the interior of some of them, were seen crowds of proliferating cells of various sizes and forms, some being the well-known "mutter-zellen."

(*d.*) Costal tumour or nodes (×30). It was very difficult to obtain a section of this for microscopical examination owing to its not hardening in alcohol but breaking up into fragments when cut. Periosteum greatly thickened. The Haversian canals, where recognisable, were much dilated; but the osseous tissue was, for the most part, degenerated into a granular mass. The same magnified (×350) showed Haversian channels filled with exudation and with granular proliferating cells such as crowd the intermediate tissue.

(*e.*) Section of a mesenteric gland (×350) presented the ordinary appearance of such tissue infiltrated with cancerous juice. Here, too, the epithelial elements were those primarily affected.

(*f.*) The liver exhibited great thickening of the coats of its blood-vessels and overgrowth of the connective tissue in its vascular channels.

No signs of cancer were detectable in any of the viscera.

*Remarks.*—This is a good example of cancer attacking the epithelial elements of one tissue, and, for the most part, confining itself to that tissue-bone. Whatever the exciting cause, the predisposition to this special degenerative process was evidently inborn in our patient, and became kindled by the application of the excitant

though its spread was confined to one tissue by some pathological law as yet unknown. The dilated state of the Haversian channels, the thickened condition of their epithelial lining, the distension of their cavities by exudation containing granular proliferating cells, and the infiltration of the surrounding tissue by a similar exudative cellulo-granular mass, indicate that the process has been initiated in the vascular channels and thence has passed outwards. The limitation of the disease to the left half of the body is of special interest. In referring to the literature at our command, we have been unable to find a case recorded similar to this one, either as regards the tissue (bone) affected, or as regards the unilateral character of the invasion. This case further verifies Sir James Paget's remark, in the debate held on cancer before this Society, that "cancer is a disease of degeneracy, a disease of which the frequency increases as years increase; so that unless a man have lived to the full age of life, he may have died of some disease and never manifested the cancer which he yet conveys in predisposition to his offspring." We have, further, in this instance, a striking confirmation of Vajda's views that "the walls of blood-vessels are the starting-point of epithelial cancer" ('Ueber Entstehung des Epithelialkrebses und Regeneration des Epithels, im Allgem. Centralblatt,' 1873, p. 385, noticed in the New Syd. Soc. 'Biennial Retrospect,' 1873–74, p. 200). *November 19th*, 1878.

---

## 13. *Colloid cancer of the breast.*

By Rickman John Godlee.

The specimen exhibited was removed by Mr. Lister from a lady aged about forty-five. The tumour was of rapid growth; it was, roughly speaking, hemispherical, nodular on the surface, hard, and elastic, occupying the greater part of the breast, not causing marked retraction of the nipple, and undistinguishable, before the operation, from an ordinary case of scirrhus. On section it was made up of alveolar spaces, easily detected with the naked eye, con-

## DESCRIPTION OF PLATE XXV.

The figures in this plate illustrate Mr. Godlee's specimen of Colloid Cancer of the Breast. (Page 416.) From drawings by himself.

FIG. 1 shows an alveolar space and several masses of shrivelled cells surrounded by colloid material. × 200 diameters.

FIG. 2 shows general arrangement of growth under a low magnifying power.

Fig. 1.

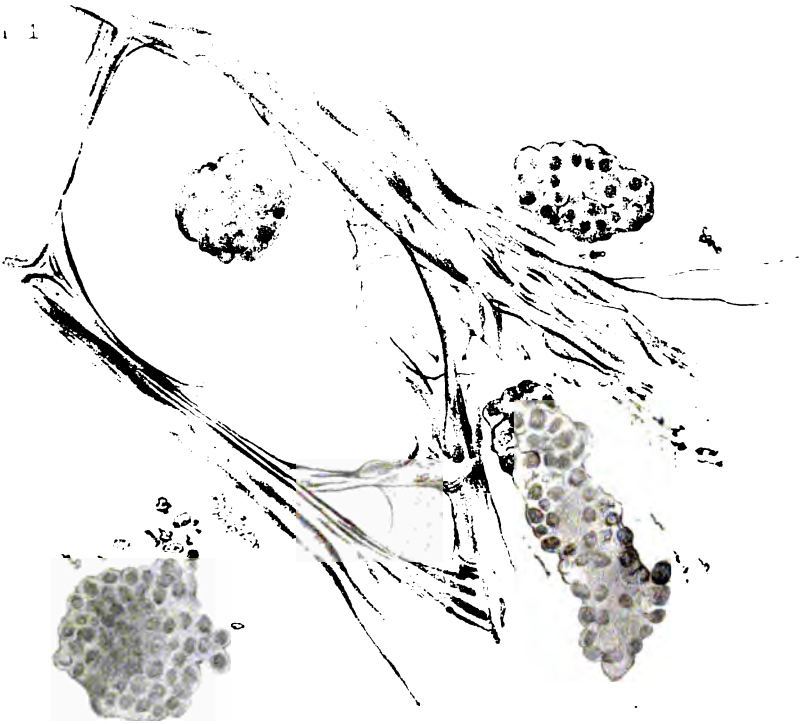

Fig. 2.

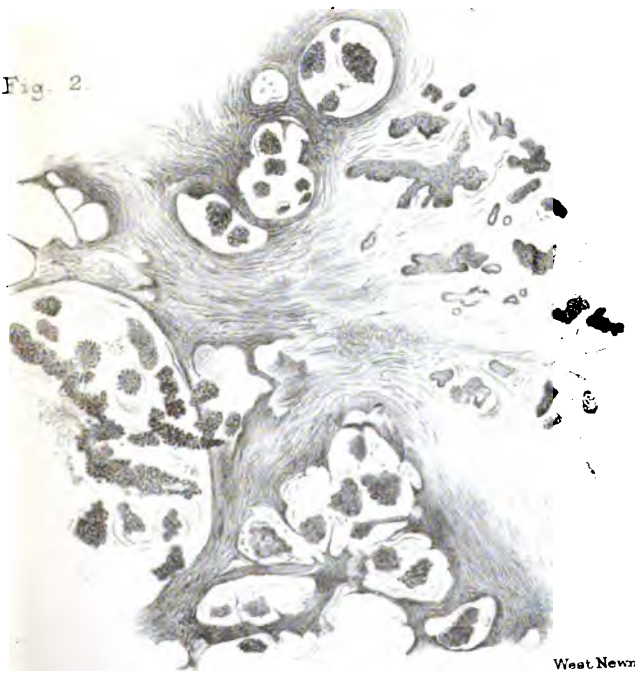

West Newman & Co. imp.

taining the well-known colloid material, transparent and gelatinous, and of a yellowish-pink colour. It was not adherent to the pectoralis major. Several glands were found in the axilla, much enlarged, and containing a growth identical in naked-eye and microscopic appearances to that which had occurred in the breast These glands were loosely embedded in the fat of the axilla, and shelled out with the greatest possible readiness.

I have nothing to add as regards the minute anatomy of the growth. The appearances shown in Pl. XXV, figs. 1 and 2, indicate that the structure is very similar to that of such cases as have been before described. The occurrence of colloid cancer in the breast, while not uncommon, has, I think, sufficient rarity to make it advisable to place another illustration of the appearance of the growth in this situation upon record in the 'Transactions.'

*November 5th*, 1878.

---

## 14. *Lymphadenomatous tumours of scalp and neck.*

By W. Morrant Baker.

The patient shown to the Society is a man (J. R—), thirty years old, who, for nearly a year, has had tumours of a somewhat peculiar character in the scalp and neck. There are two tumours in the scalp, symmetrically situate, one on and behind each mastoid process; two, also symmetrical, in the neck, one in each anterior triangle, and a fifth at the back of the neck, in the median line.

When the patient was first seen, about two months ago, the tumours over the mastoid processes were of about the size of a small Tangerine orange; those in the anterior triangle, less defined at their margins, occupied the upper two thirds of this space; and the post-cervical tumour, of a circular outline, and less prominent than either of the others, had a diameter of about three inches.

All the tumours have the same general characters. They are soft, almost fluctuating, yet not tense, apparently seated in the subcutaneous tissue, yet not easily movable on subjacent parts. The skin over them, with which they seem continuous, is not altered in

colour or texture; and they are not in the least degree tender. Their consistence seems to lie somewhere between that of a soft, fatty tumour, and a subcutaneous nævus; the tumours cannot, however, be obliterated so completely by pressure as the latter, nor are they lobulated like the former. Their texture feels most like that of the soft, semi-fluctuating, fatty lumps in the lower part of the neck which accompany the condition known as sporadic cretinism.

There is no tumour or other abnormal condition in any other part of the body.

The patient first noticed the tumours in the summer of 1878, and they gradually increased in size up to the time at which he came under my care at the end of January in the present year (1879).

When first seen the patient had a bloated or congestive complexion, as if he suffered from some impediment to the venous current, and his voice was somewhat thick and husky. He complained also of weakness, but nothing in his general health seemed worthy of special note.

Dr. Duckworth kindly examined him and reported that there was nothing abnormal in the heart or lungs; and an examination with the laryngoscope by Dr. Brunton revealed nothing beyond congestion in the upper part of the larynx and its neighbourhood.

The patient is now (April, 1879) much better than when first seen two months ago. He has, however, been troubled by slight morning cough and sickness for some time, and about a month ago his expectoration was streaked with blood.

The tumours have considerably diminished. They are only one half or one third as large as they were. The general health has also improved much, although the complexion is still a little congestive, and the voice not clear.

Besides saline aperients, the treatment has consisted of the administration of Arsenic and Syrup. Ferr. Phosph. co.

P.S. May 24th, 1879.—Since the patient's exhibition to the Society in April, the tumours have undergone suddenly a great alteration. Within a few days they all became larger and more tense—returning almost to the size which they presented in January. The post-mastoid tumours now feel almost as tense as if they were distended by fluid, and the post-cervical median tumour, from a state in which it was scarcely distinguishable from the surrounding subcutaneous tissue is now, in all respects, indistinguishable from an ordinary well-defined, firm and lobulated, fatty

tumour. Were it the only tumour present, and the history unknown, no surgeon could hesitate for a moment in diagnosing it as an ordinary fatty tumour.

The change in the local condition has not been preceded or attended by any remarkable alteration in the general health.

*April 1st*, 1879.

---

## 15. *Primary sarcoma of the suprarenal capsule, with secondary growth in the lung.*

By Samuel West, M.B.

Frederick G—, æt. 57, was admitted as a patient of the City of London Hospital for Diseases of the Chest on October 8th with this history. Beyond a winter cough for the last five or six years, and an attack of yellow fever many years ago, he had been in good health until six months before admission. The cough, which he had had during the winter, persisted and became much worse. He began to lose flesh, and to suffer from dyspnœa and palpitation on exertion. Shortly after, the expectoration became very viscid and streaked with blood. The amount of blood increased gradually, and on one or two occasions he brought up pure blood. During the month before admission his appetite failed and he had several fainting fits. He was recommended for admission on account of his hæmoptysis.

On admission he complained of considerable dyspnœa and severe pain in the right axilla. He had evidently lost much flesh, and was remarkably feeble, so that he could hardly sit up in bed. He brought up, with considerable difficulty, a large quantity of thick, viscid sputum streaked with blood. His temperature was 102°, and he suffered much from sleep sweats.

On examination it was clear that there was consolidation of the right base, which was, it was thought, chiefly pneumonic, though from the constitutional condition, and the history of the case, the possibility of a new growth was not overlooked.

The further history of the case gives but little additional information. The consolidation of the lung increased, the temperature

continued about 102°, the general condition of the patient grew steadily worse, and death took place on October 27th, about three weeks after admission.

*Post-mortem examination.*—On opening the abdomen the liver lay exposed for about six inches in the middle line below the ribs.

Left lung not adherent, emphysematous, with slight hypostatic congestion at the base. The bronchial mucous membrane was thinned, and the walls canvas-like.

Right lung completely solid throughout. The upper lobe solid, with œdema, and contained no air, but there was no pneumonic infiltration. The lower lobe solid, with recent pneumonia; in its centre was a cavity three inches in diameter, filled with cream-coloured, viscid substance, streaked with blood, strongly suggesting a soft sarcoma. This substance washed away under a gentle stream of water, in which arborescent shreds floated out, evidently the remains of the bronchi and blood-vessels. The walls were irregularly eroded, formed of altered lung-tissue, deeply pigmented.

The substance filled all the bronchi of the lower lobe, and had extended into the larger bronchi formed by the junction of those from the upper lobe, and had completely occluded these, leading, no doubt, to the condition of the upper lobe already described.

Microscopically, this substance consisted entirely of large polymorphic cells, with large nuclei, several free nuclei, much granular detritus, and some fat globules.

The bronchial glands at the root of the right lung were all much enlarged, and one measured $3 \times 1\frac{1}{2} \times 1\frac{1}{2}$ inches. On section this presented a beautiful mottled appearance of cream-white and red streaks, with pigment patches, in places broken by patches of free hæmorrhage. This was evidently sarcomatous.

*Heart.*—Right side dilated, filled with clot, partly decolorised, and *ante mortem*. Walls very thin and flabby, slightly fatty. The valves and walls of blood-vessels, especially of the pulmonary, were remarkably thin, and almost transparent.

The liver weighed $4\frac{1}{2}$ lbs., was firm on section, and slightly nutmeg. The gall-bladder was much contracted, and contained nine or ten large cholesterin calculi, and a little clear mucus.

Spleen slightly enlarged and firm.

Kidneys and intestines natural.

There were a few large varicose veins under the vesical peritoneum.

On raising the liver, a large tumour was found in immediate relation with its under and posterior surface, but not adherent to it, lying behind the peritoneum, which was not thickened or inflamed over it. It was roughly oval in shape, indistinctly lobulated, very soft, and almost fluctuating, deep red in colour, looking almost like a blood cyst. It measured about $5 \times 4\frac{1}{2} \times 3$ inches. It was situated above, almost upon, the upper part of the right kidney, to which it was attached by loose fascia. The kidney itself was perfectly distinct and separate from the tumour. Over the inner and anterior surface and slightly stretched, ran the vena cava inferior, while just under the lower surface, also slightly stretched, ran the right renal vein. The tumour received its blood-supply partly from the aorta and partly from the renal artery, while its veins opened into the vena cava.

The kidney was healthy, though somewhat large and pale. It had two ureters, one of which left the hilus at the upper, the other at the lower margin of the middle third of the kidney. They remained separate to a point an inch and a half from the bladder, where they united into a tube. There was no supra-renal capsule on this side, while that on the left side was perfectly normal.

There was no bronzing of the skin or abnormal pigmentation to be found.

Close to the right crus of the diaphragm was found one large lymphatic gland, giving on section the same appearance as that described in the bronchial gland.

Microscopical examination proved the tumours to be sarcomata, the seat of the primary growth being, it is clear, in the supra-renal capsule. *December 3rd*, 1878.

---

## 16. *On the changes in the sweat-glands in cancer and leprosy as illustrating the extremes of atrophic and hypertrophic pathology.*

By George Hoggan, M.B.

It will be within the recollection of some now present that, last session, when I brought before the Society the investigations I

had made into the condition of the lymphatics in cancer, and the manner in which secondary tumours develop from cancerous lymphatics,[1] I promised that, as the discussion then going on forced me to confine myself to the effect of the disease on the lymphatics, I would, if permitted, take a future opportunity of bringing before you the effect of cancer on other elements or organs.

To-night I propose, with your permission, to consider the manner in which cancer affects the sweat-glands, and especially the epithelial cells lining the tubes, they being, of all the *fixed* cells, the ones I have found most liable to take upon themselves the cancerous condition.

In my former communication, the only two kinds of cells I treated of as becoming cancerous were, first, the wandering cells, which having become cancerous, formed a plug occluding the lymphatics, and also by far the greater part of the secondary tumours developing from cancerous lymphatics; these cells, from their embryonic character being, as might have been expected, by far the readiest of all cells to assume the cancerous condition. The other cells I spoke of were the endothelial cells, which alone form the walls of the lymphatics and the greater part of the so-called stroma of the lymphatic glands. These fixed cells, as I then showed in several preparations, resisted for a considerable time the cancerous action, and only became cancerous after having been exposed for a certain time to direct contact with the cancer cells which formed the tenacious plug occluding the lymphatics; and, indeed, in some specimens, where they were in direct contact with the cancerous plug, both the nucleus and cell-substance of the endothelial wall of the lymphatic still remained intact, as if these, by a special design of nature, were intended to hinder as much as possible the spread of the disease.

With the epithelial cells lining the sweat-glands the case is different, and the above recapitulation has been rendered necessary in order to show, by comparison, the difference between the different kinds of cells in their relation to cancer. In the sweat-glands the epithelial cells are seen to become cancerous, not by direct contact with other cancer cells, but apparently merely as a consequence of the development of cancerous tumours in their vicinity, as if only a certain amount of specific influence, and not necessarily contagion, was sufficient to throw them into the cancerous condition. Indeed, it is in consequence of that susceptibility

[1] 'Pathological Transactions' for 1878, p. 384.

to take on morbid growth when exposed to excessive stimulation, that I am led to consider the epithelium of the sweat-gland as the element (in this case) in which cancer first developed through the tying of the nævoid wart on the chest. When we make sections of the skin, across the margin or line of infection which separates the healthy from the cancerous tissue, we find numerous instances in which portions of the sweat-glands can be observed, forming part of the lower border of large (microscopically speaking) cancer tumours, as if the tumours were being developed from the upper portions of the glomeruli. In these partially destroyed glands, every step can be traced in the course of infection of their individual cells, and in these it will be clearly seen that there is no continuity of diseased cells in the earlier stages, a solitary cell being seen here and there becoming cancerous, while lying amongst other cells apparently healthy; and it is this absence of continuity or contiguity which has led me to suppose, as already mentioned, that only a pervading influence, and not a direct contagion, was sufficient to throw those epithelial cells into the cancerous condition.

In one preparation under the microscope (Woodcut 9), we have a

WOODCUT 9.

Section through the lower portion of the glomerulus of a sweat-gland, showing different stages of cancerous infection of the lining epithelium. *a*, tubule whose lining cells are still comparatively healthy; *b* and *c*, tubules, in each of which only one cell has become cancerous; *e*, tubule in which all the cells have become cancerous; at *d* they have become disorganised and incorporated in the cancer tumour. $\frac{1}{110}$.

view of such a section through a sweat-gland becoming cancerous, in which one tube cut transversely contains cells, all of which appear as yet to be healthy (comparatively?). Next to it are two trans-

verse sections of gland tubes, in each of which only one cell appears to have taken on the cancerous condition, and is now twice as large as the contiguous cells among which it lies, some of which it has begun to elbow out of their position, so to speak, in order to give itself room to grow, thus leading to disorganisation of the epithelial lining of the gland. It will also be observed that the solitary cancer cell in each appears singularly transparent, as if both nucleus and cell-substance had become swollen. In a fourth portion of the tube, cut transversely, all the cells have become cancerous and disorganised, so that, but for intervening forms, it is difficult to recognise its glandular character or structure.

These changes can be seen even more clearly in a neighbouring glomerulus in the same field of the microscope (Woodcut 10), where,

WOODCUT 10.

Shows under a high power a section across the tubule of a sweat-gland, in which all the lining cells have become cancerous, increasing in intensity from *d* towards *c*; the basement at *c* having ruptured, allows the cells to swell *in situ*. *a*, triangular end of basement-membrane cell. $\frac{1}{250}$.

although the whole of the epithelial cells lining the tube have become clearly cancerous, yet, owing to bursting of the basement membrane or tube, the cancerous epithelium has been allowed to develope *in situ*, and thus the appearance of the gland structure has been preserved. In that gland tube the growth of the cells in the cancerous condition seems to have proceeded gradually from one side of the gland towards the opposite point in its circumference, as shown by the regular gradation in the size of the cells passing from right to left (or from below upwards in the figure).

In one respect, this gland tube affords an interesting comparison with the two tubes in Woodcut 9, for while in each of the latter, only one cell had become distinctly cancerous, in this one, only one cell may be said to remain comparatively unchanged.

The mechanical effect of the more advanced cancer cells in bursting, by their swelling, the basement membrane at that point is well shown. This is, however, a rare occurrence, the general rule being that the cells themselves get thrown into an irregular mass.

Even where the regular position of the epithelium does not exist to enable us to recognise a sweat-gland tube in a cancer tumour, we have a valuable index in the cells of the basement membrane to show what was a gland tube, even after its epithelium has become cancerous and disorganised. Normally, those cells of the basement membrane appear as endothelial cells of the shape of an elongated rectangle, lying longitudinally along the gland tube, and joined at their edges. On transverse section, as will be recognised in the preparation and drawings, they, with their nuclei, appear triangular in shape (probably owing to contraction), and deeply stained black by the pyrogallate, so that the epithelial lining appears encircled by a very distinct serrated girdle. The peculiar shape and staining of these cells are easily recognised in cancerous and disorganised gland tubes, where, indeed, they form the only certain index of its true character.

As far as I have been able to make out, these endothelial cells of the basement membrane only become cancerous some time after the epithelial cells which they enclose have become cancerous, showing, in this apparent resistance to the cancerous influence, a certain analogy with the endothelial cells forming the lymphatic wall. The cancerous change in the individual epithelial cells can easily be traced throughout its course.

In the first place, both nucleus and cell substance appear to become swollen, and the latter especially grows more transparent, and, if originally polygonal in shape, it becomes globular, as in Woodcut 9. By-and-bye, growth of the cell-substance ceases, although the nucleus continues to grow larger, and finally separates, or rather differentiates into several portions of more or less globular form, as shown in Wooodcut 10. I may mention, by the way, that this appearance, which I endeavoured to describe, without pretending to understand it, in my former communication, and which was also drawn in Woodcut 10 under like circumstances, has now been clearly explained by Pouchet's investigations into cell nuclei, published in the 'Journal de l'Anatomie' for January of this year, as being merely an exaggerated condition of the differentiation which

normally exists in the healthy nucleus, although it is only recognised with difficulty in the healthy condition.

There is no propagation of other cells from the cell which has become cancerous, and it appears to undergo no other change than what I have described, but goes, as one of the few fixed cells become cancerous, to assist in forming cancer tumours, of which, however, by far the greater part is formed by wandering cells becoming cancerous, which may be seen streaming towards the tumour from the nearest blood-vessels. Finally, as the tumours increase in size, there is no corresponding increase of blood-vessels within them, so that the cells thus deprived of nutrition gradually degenerate into amorphous, clay-like masses, in which no structure can be traced, and amongst which the originally existing blood-vessels, having become cancerous and destroyed, pour out blood into the dead tissue, thus acquiring for such cases the characteristic name of "fungus hæmatodes."

With regard to the gland epithelium seen in Woodcut 9, which I have spoken of as comparatively healthy, I ought to mention that this only appears so when examined by itself. In another preparation which I have placed under the microscope, and which represents a very common condition, it may be seen, by comparing one half of a gland with the other half, or with another gland in the same field, that the slightly swollen and transparent condition of these apparently healthy cells shows that they have indeed entered upon the morbid condition, a condition, however, which appears to be only passive or intermediate compared with the active cancerous condition into which one cell in each tube has entered.

After the earlier stages of the disease in the glands, when the basement membrane bursts and sets free the cells within it, or the cells themselves get disorganised, it becomes impossible to trace the exact amount they contribute to the whole tumour amongst the shapeless masses of cells which form it; and it is for this reason that I offer Woodcut 10 as an example of hypertrophic pathology for comparison with Woodcut 12, an example of atrophic pathology in the same glands in leprosy, under the same magnifying power. Not that that tubule has reached its maximum hypertrophy by any means, but it is difficult to trace it as a sweat-gland beyond that condition, a point which is equally true of Woodcut 12. As a rule, the cancer tumour or cancerous change in a sweat-gland seems to begin at the summit or upper part of the glomerulus, and in some hundreds of specimens I have

never noticed the cancer developing from, or at the lower border of, the glomerulus. This, however, may be due to the position of the cancer-filled lymphatics, which, as I have shown elsewhere,[1] are abundant, and almost always found in close relation to the upper portion of the glomerulus in the more superficial glands, and seldom, if ever, in contact with the lower border. I ought also to mention here, what indeed will be gathered from my previous communication, that the tumours growing near or from the sweat-glands are few, in comparison with the secondary tumours developing from the cancerous lymphatics immediately underneath the epidermis.

To prevent misconception, I ought also to state that the cancer of the skin, in this case, has no relation whatever to epithelioma. In epithelioma the malignant influence begins in, and extends down from, the cells of the epidermis, whereas in this case I have never found an epidermic cell affected by the cancer, owing, apparently, to the fact that the cancer tumour developing beneath the epidermis generally cuts the supply of nutrition off from the latter, and the moist, sodden condition of the underlying diseased tissues allowed or caused the superjacent epidermis to perish by a process of moist gangrene, so that it fell away, or was rubbed off, before it had time to become cancerous—a fate which, I may add, was shared by the hair, hair-follicles, and sebaceous glands, although the hair-muscles became incorporated and cancerous, as shown in Plate XXVI, fig. 7.

In my former communication I mentioned that the cancer tumours developing at the glands were of the medullary type, due, of course, to the fact that they were wholly composed of cellular elements. As, however, growth proceeds, the wandering cells, which seem to be attracted by their influence, and are seen flocking to them from every direction, become cancerous while they lie close to them between the bundles of gelatine, or, as it is generally called, white fibrous tissue of the dermis.

These communicate, in turn, the cancerous influence to the wandering cells beyond them, and thus we have layers of cancer cells lying between gelatinous bundles, whose nature also is so changed by the influence as to form a hard, tough material, and in this way what is known as scirrhous cancer is formed, a character given to the whole of the skin in the locality by the union of the various tumours, by

[1] 'Journal de l'Anatomie,' January, 1879.

the means I have just described, and the incorporation of the altered gelatinous tissue within the one mass.

Sometimes a secondary tumour, developing from one of the superficial lymphatics, compresses the tube of a sweat-gland near its orifice, and thus causes some part of the gland in the glomerulus to become cystic; this cystic condition is, however, a healthy one, the cells being healthy, and placed regularly in one layer, and is quite different from the unhealthy, dilated, or cystic condition of the sweat-glands in leprosy, as shown in Plate XXVI, fig. 6.

The changes which take place during degeneration of the sweat-glands in leprosy, leading to atrophy and complete disappearance of these glands, are much more difficult to trace, and require a longer description than in the case of cancer. Degeneration may be described as consisting of two phases, the first characterised by actual hypertrophy throughout, but leading to destruction of the cellular elements lining the tubes, after which come the atrophic changes of the second stage, which lead to complete disappearance of the gland.

Attention has already been directed to the disappearance of these glands in leprosy, but, as far as I can find out, not one of the various phenomena which characterise their disappearance has ever been described. The contrary has, indeed, been the case, and appearances due to them alone have been described as specific tissue or elements, as, for example, when Neumann . . a perfectly accurate drawing of a section of the skin in this disease, in which is seen the duct of a sweat-gland and several transverse sections of the glomerulus portion of the tube.

Following the vicious habit of giving specific names to elements or structures whose true nature the observer fails to understand, Neumann[1] calls the latter "colloid globules," and the former he calls "sinuous connective-tissue strand, formerly hair-follicle." I may also mention here that the destruction of sweat-glands is by no means general in this disease; and although, in the case I have been studying, the patient died in an advanced stage of the disease, it is only at certain parts, such as the hands and feet, that the sweat-glands were found in the last stages of atrophy, while in other parts of the skin of the bod , the sweat-glands were either unaffected or only in the first stage of degenera-

[1] I quote the English translation of his work.

## DESCRIPTION OF PLATE XXVI.

**Figs. 1—4 illustrate Dr. Hoggan's paper on the condition of the Lymphatics in Eastern Leprosy. (Page 504.) From camera-lucida drawings of preparations by himself.**

FIG. 1 shows, under a low power, the changes in the lymphatics (*a*, *a*) of the skin of the neck, and their relation to the hairs (*b*, *b*), sweat-glands (*c*, *c*), and main blood-vessels (*d*, *d*). Owing to thinning of the skin by absorption of its gelatinous tissue, the whole of the lymphatics lie in one plane, so that the plexus appears to be abnormally dense, and the lymphatics themselves dilated. Silver and gold preparation. $\frac{1}{50}$.

FIG. 2 shows a small portion of fig. 1 under a high power. The dilated lymphatic represented has its wall formed of healthy endothelium. The leprous cells (*a*, *a*), which lie everywhere near the blood-vessels (*c*, *c*), are absent from the lymphatic wall at *b*, where no blood-vessel exists. $\frac{1}{150}$.

FIG. 3 shows the early stage of deposit of leprous cells (*a*, *a*) around a vein (*b*). Epidermis (*c*); gelatinous tissue (*d*). Carmine and indigo preparation. $\frac{1}{150}$.

FIG. 4 shows a section through cutaneous lymphatic (*a*), the nuclei of whose wall are perfectly healthy. No leprous cells lie close to the lymphatic wall, although they are becoming deposited at a vein to the left. Gelatinous tissue (*c*); epidermis (*d*). Osmic acid and carmine preparation. $\frac{1}{150}$.

**Figs. 5—7 illustrate Dr. Hoggan's paper on the changes in the Sweat-glands in Cancer and Leprosy. (Page 418.) From camera-lucida drawings of preparations by himself.**

FIG. 5 shows two sweat-glands imbedded amongst leprous cells in the skin of the nose. The gland to the right is but little affected, but the glomerulus to the left is becoming distorted and elongated by pressure upon it. Its lining cells are vacuolating, causing obstruction of the duct and consequent dilatation of the glomerulus portion of the tubule. These changes are better seen under a high power in fig. 6. Epidermis (*a*); leprous cells (*b*, *b*); gelatinous tissue (*c*, *c*); muscular fibres (*d*). $\frac{1}{50}$.

FIG. 6 shows a portion of glomerulus similar to that in fig. 5. The cells in upper portions of tubule are undergoing the first stages of vacuolation. In the left lower portion the process is further advanced, and the lining cells are greatly distended. In the right lower portion is seen the last stage of vacuolation; the cells are bursting, and falling with their contents as *débris*, filling up the tubule, and thus ending the first or hypertrophic stage of degeneration. Preparations stained with carmine and pyrogallate of iron. $\frac{1}{150}$.

FIG. 7. Two smooth muscle cells from erector pili become cancerous.

Fig. 1.




Fig 4

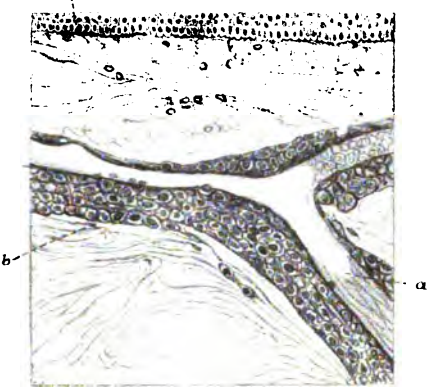


Fig. 2.

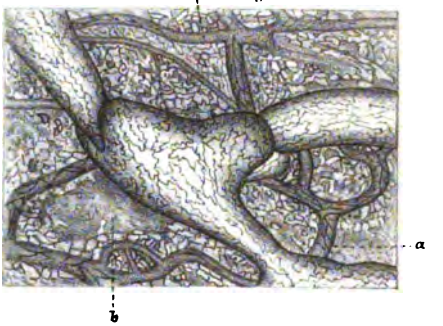


Fig. 3.

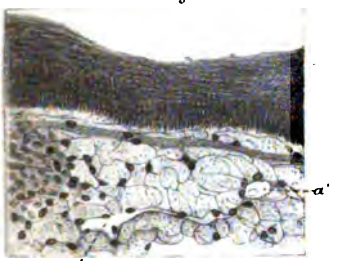


Fig. 7.



Fig. 8.

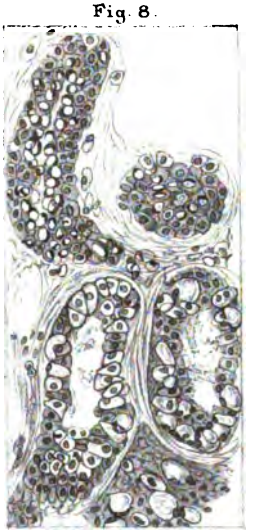

Fig. 6.

West Newman & Co lith.

tion, and function was still performed. Indeed, during the last hours of his life, the intense perspiration to which he was subject was a constant cause of complaint with this patient. It has also been stated that the gland first becomes destroyed at its orifice, an error which is the more serious because it is the very opposite of its actual condition, and may lead others, as it led me, into a long search in an entirely wrong direction. As a matter of fact, degeneration begins, and goes on fastest, at the lower portion of the glomerulus, and subsequently passes up towards the duct and its termination.

To facilitate description, I have prepared a drawing (Pl. XXVI, fig. 5), under a low power, of a section of skin which is placed under one of the microscopes, and which resembles very much the woodcut given by Neumann. The left gland of the two I have figured is much further advanced in degeneration than the right one, and is fairly typical of the first changes. That gland to the left also appears as if its duct had become occluded before reaching the epidermis, but it only requires a little careful examination to recognise that at that spot the duct has merely made a spiral turn, and the spiral been cut across in making the section; we have thus an appearance as if the gland had actually terminated. This can be best recognised by using the binocular microscope, which shows that, in the present case, the spiral turn passes downwards (towards the glass slide); and, indeed, without going further into the question, I may state that in no case whatever have I found that the gland-duct disappeared at its peripheral end in the early part of the degeneration.

The first point of interest we have to observe in the gland just referred to is the peculiar distortion that it has begun to undergo, and which is evidently due principally to the great deposition of leprous cells around it. There is nothing specially unusual in the fact that a gland duct may become spiral near its termination, even before it enters the epidermis, where, of course, the spiral is the rule for very obvious causes. In the present case, the spiral is probably increased by the manner in which the deposit of leprous cells take place. In a former paper, I showed that this deposit takes place specially in the plane or zone of the vascular plexus, thus leaving a certain amount of gelatinous or white fibrous tissue between that zone and the lower surface of the epidermis. This layer of gelatine finally disappears, or is absorbed, and, consequently, that portion of the sweat-duct which formerly stretched across it, is forced to accommodate itself, in

its absence, by assuming the spiral form, upon the same principle that it assumes the spiral in the epidermis.

The preceding change is, however, unimportant compared with what takes place at the glomerulus. There it will be observed that the globular form of this, the secreting portion, of the gland, is being gradually destroyed; partly, apparently, by lateral pressure from the neighbouring tissues upon it, but principally and primarily through pressure from above downwards, owing to which the glomerulus is becoming elongated, and its tubular coil is becoming unwound or unravelled. This, I think, is evidently due to the deposition of the thick layer of leprous cells above the glomerulus, which, reacting upon the gelatinous tissue surrounding the glomerulus, pushes it downwards, forcing it to uncoil at the same time, a change which is very manifest when compared with the globular form of the glomerulus of the gland to the right, which is as yet but little affected. This elongating or uncoiling of the glomerulus is, I may state, the general rule throughout the degenerating glands.

Contemporaneously with the distortion of the glomerulus, but whether caused by it or not I cannot say, we have much more important changes going on in the structure of, and in the cells lining, the gland tubules. Even by the low power at which that gland is represented, it is easy to observe that the lumen of the glomerulus portion of the tubule is becoming much more dilated than that of the excretory duct. We may also observe that the lower portion of the dilated tubule is filled up with *débris*, which does not exist in the upper portion of the dilated tubule, and, further, that where the first coil of the glomerulus joins at right angles the lower end of the gland-duct, there is not only no dilatation, but rather contraction or occlusion of the lumen of the tubule, in consequence of the inner layer of cells becoming vacuolated, and by this swelling occluding the tube. The whole of these changes, however, are better represented in another preparation and drawing of a gland (Pl. XXVI, fig. 6), almost identical with the one we have been studying, and drawn under a high magnifying power, in order to show all the stages which characterise the hypertrophic part of the degeneration, passing from above downwards.

The first thing we observe is that, instead of only having a single layer of cells, as in the normal gland, we have several layers of cells lying within the tubule; but, while the size of the lumen is not materially encroached upon, accommodation has had to be found by

distending the tube or basement membrane, and thus we have hypertrophy of the gland by numerical increase of the solid cellular elements.

It will also be observed that the whole of the inner or central lining cells have become vacuolated, and that vacuolation is likewise taking place to a considerable extent among the more external cells, or, in other words, the cells nearest the nutritive centres or regions; and where this vacuolation is taking place, the swelling of the cells next to the lumen leads to a more or less complete, even if temporary, occlusion of that lumen, and dilatation of the lower portions naturally ensues to a small extent. Unlike, however, the cystic condition caused in a healthy gland by pressure upon its excretory duct, as we saw in the case of cancer, we have not here a single layer of healthy cells, but several layers of cells undergoing further changes of vacuolation, as seen in the lower left hand tube.

Before proceeding further, let us now inquire into the character of this condition of vacuolation. In this case, there appears to be nothing specific about it, but it is only the ordinary form of vacuolation that has often been observed even in physiological degeneration of glands, as for example, by Creighton, in degeneration of the mammary gland after the period of lactation is over, although he only describes this one phase as seen in the upper tubule, and gives no clear interpretation of its cause or course.

In the upper tubule every stage of this vacuolation may be observed, from its first appearance as a minute globule of fluid lying between the nucleus and the cell-substance, up to the formation of a vacuole the size of the original cell, which in most cases compresses the nucleus against or within the protoplasmic wall which surrounds the vacuole. When such a nucleus is observed edgeways, it appears like the signet of a signet ring, being itself somewhat crescent shaped from the distortion it has undergone. When, however, it is viewed from the front, the nucleus possesses its normal shape and appearance, except, perhaps, that it is a little thinner. From this point of view it is more difficult to detect the vacuolation, as the nucleus lies in the centre of the circular vacuole so as to obscure to a certain extent its existence. A commonly accepted view of the cause of vacuolation is that it is caused by the swelling of the nucleolus within the nucleus, but to me that view is altogether untenable, from the very fact that in many cases the nucleus is seen floating free within the fluid of the vacuole, like a blood disc seen

edgeways, and sometimes bent in addition. That the nucleus could float within the cavity of something within itself is simply impossible, and I therefore entirely reject the nucleolar theory of origin.

To me vacuolation is merely a process by which the connection of a cell nucleus with its protoplasma is severed, leading to the destruction of the individual cell, a condition which is much more common than is generally suspected. In this vacuolation I do not include such forms of vacuolation as are seen in developing blood-vessels, in the development of bone from embryonic cartilage, &c. I merely refer to the vacuolation which leads to death of the cell.

Lately I have found stated in a German article that this vacuolation was simply the formation of fat within a fixed cell. To this I demur, and I have placed under the microscope a sweat-gland whose cells are undergoing vacuolation, and which have been treated with an excess even of osmic acid, and there it will be observed that, although the neighbouring fat-cells are rendered intensely black by the osmic acid, the liquid within the vacuole is entirely unaffected and colourless, showing that it is not fatty, but probably albuminous in character.

Let us, however, trace the process of vacuolation further, as it is seen in the lower tubule on the left hand, in which the vacuolating cells have increased greatly in size, and have become distorted by the pressure of the one upon the other. They are still, however, attached to the wall, for the cavity or lumen of the tubule is still clear; but in the tubule to the right we see that they are not only falling away from the wall into the lumen, but they appear also to have burst there, freeing the nucleus as well as their contained fluid, and forming an amorphous granular *débris*, that soon fills up the cavity of the tubule. This falling away of the vacuolated lining cells from off the basement membrane of the tubule constitutes the end of the first or hypertrophic stage of degeneration.

From this point the downward or atrophic changes succeed each other rapidly. The *débris* within the tubules becomes absorbed or excreted, and the formerly distended basement membrane contracts laterally through contraction of its cells, which also become vacuolated, and the whole tubule may be now described as attenuating, a layer or deposit of gelatine taking the place externally of the contracting tubule. I present a drawing (Woodcut 11) under a low power, of a section of the skin of the finger, which is also placed

under the microscope, and in it will be observed the various changes of attenuation which are being undergone by several glands which, from the distortion they have experienced, appear to have their

WOODCUT 11.

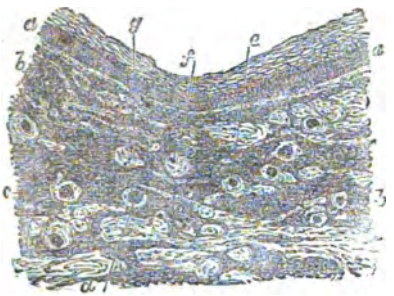

From an oblique section of the skin of the finger, shows the different stages of attenuation and absorption of the sweat-glands in the atrophic stage of degeneration. *a*, epidermis; *bb*, leprous cells; *c*, sweat-ducts only slightly attenuated; *e* and *f*, further advanced stages; *g*, spot from which the gland has entirely disappeared, its place being now occupied by gelatinous tissue or tendon. $\frac{1}{80}$.

tubules cut transversely or obliquely across, the gland looking like a dark circlet or dot within a transparent circle formed of gelatine; such a circle of gelatine can also be observed from which the attenuated gland has entirely disappeared, thus reaching the lowest possible point of atrophy. I have also drawn and placed under the microscope, under a high power, four stages of degeneration in these glands (or colloid globules of Neumann), which explain themselves.[1] The last of these (Woodcut 12) represents the attenuated gland about to disappear, and as it is drawn under the same power as the hypertrophied gland (Woodcut 10) in cancer, the comparison shows well why they have been chosen as extreme types of hypertrophic and atrophic pathology of sweat glands. Of course it will be understood that neither of the two represents the actual extreme reached in either disease, for, as we have seen in leprosy, the gland disappears altogether from its gelatinous matrix; and in the cancers the gland tubules soon become unrecognisable within

[1] In a subsequent case of leprosy, I noticed that the attenuating sweat-ducts, when seen longitudinally, presented a moniliform appearance, through irregular contractions and dilatations of their lumen.

the general tumour. I have ventured to describe the whole of the changes in the sweat-glands in leprosy at so great length because, while I am unaware that a careful investigation has ever been made by any one into the changes which take place in an atrophying gland,

WOODCUT 12.

Shows a gland-duct about to disappear, similar to *f* in Woodcut 11. *a*, attenuated gland; *c*, tendon-like gelatinous tissue; *b*, leprous cells surrounding the whole. $\frac{1}{420}$.

I also believe that what is true of the glands in leprosy is likewise true of all other glands undergoing chronic atrophy.

It, however, remains still to be shown how the *débris* of the cells becomes absorbed from the cavity of the tubule, or how the cells forming its disappearing basement membrane are absorbed. I have every reason to believe that the solid particles move off by their own power, as the particles of an absorbing fat-cell may be seen to move off from the neighbourhood of the cell-nucleus within the clear membrane of the mesentery, a question, however, which can be better studied in a joint article which has been published in the 'Journal of the Royal Microscopical Society' for June, 1879, where it is entered into at greater length than I could possibly do in this paper. *April 1st*, 1879.

## 16. *Blood cyst removed from the neck.*

By JOHN GAY.

THE patient, Mr. H—, æt. 27, a delicate man, had, for about five years, a cyst on the left side of his neck, which did not trouble him until its bulk interfered with movement, and, as he thought, during the last six months, with his health also.

It was punctured twelve months ago by one of our most distinguished surgeons, when a considerable quantity of blood flowed from it and it collapsed. It, however, rapidly regained its former size; when he showed it to Dr. Gutteridge, of Brook Street, who, taking it to be a blood cyst, sought my advice in November last year as to its treatment.

The cyst was then, as far as could be judged, the size of an ordinary orange, and ovoid in shape, with its long axis in the direction of the sterno-mastoid muscle, in front of which (in relation to the median line of the neck) it lay, overlapped at the lower part by some of its fibres. Although bound down and flattened somewhat by the fascia, it had some freedom of movement amongst surrounding textures; and its outline, as far as it could be traced, was well defined. The carotid artery could no where be felt, nor any pulsation or bruit be detected in connection with the swelling. I tapped it, and let out about an ounce and a half of pure blood, some dark and some bright. With the collapse of the cyst the bleeding ceased, and some solid matter like old clot could be felt within. It refilled in the course of a few hours without showing any disposition to exceed its former dimensions. The question of treatment then presented itself; and, with the prospect of having to encounter considerable hæmorrhage by any plan that could be adopted, it was assumed that this could be better controlled outside of the cysts than from the mouths of bleeding vessels in the interior, the surface of which was probably more or less covered with tough and ragged clot. Extirpation was therefore determined upon.

In November, 1878, with the assistance of Mr. Harrison Cripps, I again tapped the cyst, and obtained from it again nearly two ounces of pure blood. An incision was then made along its whole length, a little in front and parallel with the edge of the mastoid muscle when, on clearing its surface, a large but empty vessel was met with,

running over it from below upwards, and rather obliquely backwards, which turned out to be the common carotid, and also a nerve, a branch of the fourth cervical, which crossed it horizontally, Keeping clear of the former and dividing the latter, as some of its ramifications became lost on the cyst walls, the cyst was cautiously separated from its bed until the apex was reached, where it was found to be continuous by a firm and thickish pedicle at the base of the skull.

In the course of this proceeding, however, this cyst, or capsule as it really was, was torn through, and exposed another, the *real* cyst, lying somewhat loosely within, for on enlarging the opening it "shelled out" with very little help. Slight bleeding followed, but it soon ceased, and the capsule was removed by a very cautious division of its pedicle. On removal the capsule was found to have been in contiguity with the bodies and transverse processes of two or three cervical vertebræ, the hypo-glossal nerve, and the jugular vein below, and above with the carotid artery, the sheath of which it had appropriated, fascia, and an expansion of some of the front fibres of the mastoid muscle. One small vessel alone required a ligature, and the wound was dressed. The carotid was left beating beneath the skin, and, for the space of an inch or more, wholly nude. During the operation the cyst again filled with blood which, with some fawn-coloured, old and tough, and a little fresh clot, made up its contents.

The man made a good recovery, and a suspicious cough with expectoration, from which he had suffered for weeks before the operation, gradually subsided.

The cyst and capsule were carefully examined. The former had all the characteristics of an ordinary serous cyst with an extremely vascular endothelium. There were no vessels connecting it with the capsule that required a ligature. The latter consisted of ordinary fibrous and fibro-areolar stroma. There were no morbid elements in either.

*Remarks.*—The several forms of *blood cyst* or *tumour*, usually associated under the one or the other of these generic terms, will not, I think, be found on separate examination to have such common bonds of affinity as to justify such a classification. The mere fact that blood, exclusively of the envelope, forms wholly, or in part only, the constituent of such a tumour is futile as a base of classification, although it seems to have been adopted for that purpose. And in

the case of cysts, such as I have presented for your notice this evening, as I hope to show, there is hardly a point in which they agree with the several other varieties of blood tumours with which they have been thus allied.

In the first place, in all other varieties of so-called blood tumour, in which the blood is encysted or encapsuled, blood is not the earliest product, nor does it constitute the sole contents of the envelope. Neither, with the exception of cysts in which the blood, mixed with their natural contents, is traumatically drawn from the cyst-walls, is the blood derived from that source. In some of these the blood is in some respect an agent in the formation of its cyst or sac, but in none is it, as in the one before us, the passive consequence of its special organisation. This variety of cyst is specifically hæmorrhagic, and should be classed with the sebaceous, mucous, serous, and seminal cysts, with a right of a common ground of nomenclature in respect of its especial eliminating properties, such as "*hæmorrhagic*" or "*sanguineous*."

The blood tumours from which this form is to be distinguished are:

1st. Those of idiopathic or traumatic origin in which extravasated blood or clot forms to itself a cyst from surrounding areolar tissue, such as, for instance, those which are found within the brain or in connection with its membranes; in other organs, as in the ovary, kidneys, within muscles, or amongst other textures; hæmatomata, and some kinds of diffuse aneurysm. An interesting case of the latter form of blood tumour is related by Mr. Moore in the 29th vol. of 'Medico-Chir. Trans.' in which the tumour formed in the centre of the popliteal nerve through the rupture of a small artery and vein from a blow; 2nd. Blood-sacs of aneurysmal origin, in which the tumours become entirely or partially discontinuous with the parent vessel; 3rd. Blood-cysts (so called) in which blood is occasionally mingled with their natural contents, usually as the result of local injury, as in the case of the hæmatocele. These serous sacs or cysts are often converted into so-called "blood-cysts" but without any claim to that designation.

Mr. Birkett and Mr. Morrant Baker have severally treated of this class of cysts. In a case related by Mr. Birkett the cyst contained serum in childhood; and, after repeated tapping, the same fluid mixed with blood. As Mr. Baker showed, the nature of such a cyst is known by the sp. gr. of its contents.

The cysts in idiots' ears, that have been relegated to the class of blood-cysts, appear to me to be of the class now referred to. A blow or a pinch will readily make the contents of an ordinary serous cyst in the ear-lobe or elsewhere bloody.

4th. The so-called blood-tumours that appear to be strictly of vascular origin—the "spurious spleens" of Andral, the teleangiectasis of Rokitansky, and the "nævoid" growths of Paget, which seem to form a class by themselves, and differ widely from the real sanguineous cyst. They are trabecular or lobulated structures, sometimes having valves, or remains of valves on their inner surface, and are smooth and polished, resembling an auricle, unless the blood coagulates and roughens it. The question of an extraneous envelope or cyst is wholly unimportant in connection with this class of tumours.

5th. Certain intra-cystic growths such as the recurrent, fibroid or cancerous, with an admixture of blood, of which specimens have been exhibited, and in which the blood appears to be either the result of local injury or of a hæmorrhagic tendency inherent in the growth.

The distinctive peculiarities of the "sanguineous" cyst may thus be summed up:—

1. It contains blood or blood constituents without other admixture.

2. The blood is supplied by a specially organised cyst wall.

3. The cyst itself has no abnormal histological elements in its constitution.

4. Its vascular connections are not necessarily exaggerated.

5. Its hæmorrhagic properties reside in an extremely vascular endothelium, the hæmorrhage being, as far as could be inferred, in the case before the society, strictly parenchymatous.

6. When punctured, these cysts part with their fluid blood but refill. Their growth is slow.

7. They may become encapsuled, and will easily "shell" out on the capsule being opened. This is not, however, peculiar to this form of cyst.

8. They usually lie deep, and near to, though without any important connection with, large vessels; for the most part in the neck, axilla, pelvis, brain, so far as observations have gone.

9. They are innocent; allied generically to the serous, seminal, and such like cysts; and may be treated by excision, incision, or by injection with tincture of iodine or sesquichloride of iron, or their solutions.

*February* 18*th*, 1879.

# VIII. DISEASES OF THE SKIN.

## 1. *Specimen of the affection of the hair which has been described as Piedra, and as Trichoclasia or Trichorrhexis nodosa.*

By P. H. Pye-Smith, M.D.

The first description in English of this curious condition was given by Dr. Wilks in 1859. He writes ('Path. Anat.,' p. 186): "There is another affection of the hair which I do not think is described in books, but about which you will sometimes be consulted, and that is a breaking of the hair. Owing to the fracture a white spot is produced, and if a number of these are present, as, for example, in the whisker, they have been mistaken for the ova of pediculi, and alarmed the patient. If you examine one of these hairs, you may find it broken in one or two places, and thus presenting a nodulated appearance, and if then examined by the microscope the fibrous structure of the hair will be found broken up into a brush. I have seen interspersed a few dark granules, but I never could make out distinctly any sporules of fungi." The same affection had, however, been previously described by Dr. Beigel, a former member of this Society, in the 'Sitzungsb. d. k. k. Akad. d. Wissensch.' for 1855 (quoted by Kaposi), and a full account is given by Kaposi (Moritz Kohn) himself in the last edition of Hebra's 'Hautkrankheiten' (Bd. ii, S. 176). It is there that he proposes the somewhat grandiloquent name *Trichorrhexis nodosa.*[1] In a recent correspondence in medical journals the same affection has been described under the name Piedra. This term is, it seems, applied in Spanish America to a parasitic disease of the hair, which forms knots in it "as hard as a stone" (Piedra), so that it will scratch glass (?).[2] Whether this is the same affection as that now

[1] Not, as the learned dermatologist writes it, Trichorexis, which would mean "an appetite for hair" (ὄρεξις), instead of "breaking of the hair" (ῥῆξις).

[2] I have not seen the original paper by M. Desenne. If, as is most likely, it really applies to Beigel's disease (Trichoptylose of Devergie), it is an inaccurate account of a previously known disease.

exhibited it is difficult to say, but the present specimen agrees precisely with the accounts given by Beigel, Wilks, and Kaposi, and also by Dr. Tilbury Fox (under "Tinea sycosis"), Dr. Neumann ('Hautkrankheiten,' S. 298), and Dr. Liveing, who uses a term invented by Mr. Erasmus Wilson, Trichoclasis ('Handbook on the Diagnosis of Skin Diseases, p. 173).

The present case came to me as one of "Piedra." The patient, a young man, found that the hairs of one whisker showed white spots at intervals and broke short at these places. His health is perfect, and there is no affection of the skin, nor of the hair on the scalp, or even on the other cheek. With a low power the affected hairs are seen in the first stage to be swollen into a fusiform nodule at intervals of a few lines (Plate XXVIII, fig. 5 A). In others (B) the cortical layer has begun to split up and separate transversely. In those more advanced a fine granular material oozes out from the medullary portion (D). Lastly, the hair breaks across, leaving the brush-like, broken end formed by the frayed-out cortical fibres (C). Under a high power the exuded material shows no trace of its original structure, but appears as a uniform, finely granular substance. This has some resemblance to fish-roe, and might be mistaken for sporules. But a careful examination of several specimens, with the aid of reagents and staining, has convinced me that there is no vegetable structure present. There is no probability in favour of Beigel's suggestion that a development of gas causes the hair to split, but I am unable to offer any other. The cortex becomes apparently more dry, and its constituent fibre-cells less coherent, the medullary cells break up into this granular material and swell, until the rupture of the cortex is complete, and nothing remains to hold the hair together. There is no fatty degeneration. The most important characters of this curious affection are, its rare occurrence elsewhere than in the beard, its liability to be confused with the ova of pediculi on a superficial view, and with the spores of fungi on a microscopical examination, and its ready removal for a time by shaving the parts affected. *December 3rd*, 1878.

*Postscript.*—Since exhibiting this specimen I have seen one of the cases described as Piedra, and recognise in it precisely the features above detailed, and the absence of any vegetable parasite. I have also read an article on the subject by Dr. T. C. Fox in the 'Lancet' for December 7th, 1878. Reference is there made to Mr.

## DESCRIPTION OF PLATE XXVIII.

The figures in this plate are drawn from the specimens of Dr. Pye-Smith and Mr. Malcolm Morris, of Piedra.

Figs. 1—4 illustrate Mr. Malcolm Morris's specimens. (Page 441.) From drawings by Dr. A. Sangster.

FIG. 1A. Node seen *in situ*, mounted in glycerine and focussed to show the hair.

FIG. 1A. Same node focussed for the surface.

FIG. 2 illustrates the growth of the mass in all directions, the surface-cells becoming altered in shape to form a pseudo epidermis.

FIG. 3. Transverse section of the node, the hair itself having fallen out from the centre (*a*). The radial arrangement of space-like bodies are seen and rounded cavities (*b*) which do not communicate with the surface.

FIG. 4. Node substance broken up. Tuft-like groups of elongated cells (*s*), which have apparently escaped from the cavities above referred to.

Fig. 5 illustrates Dr. Pye-Smith's specimens. (Page 439.) From drawings by himself.

A. An affected hair with its bulb, showing the nodules under a low power.

B. Another specimen, under a $\frac{1}{8}$th objective, showing the appearance just before breaking and the persistence of the medullary part when the cortex has broken off.

C. The frayed end of a broken hair.

D. A hair in an early stage of the affection, showing the infiltration with minute granules and the rupture of the cortex.

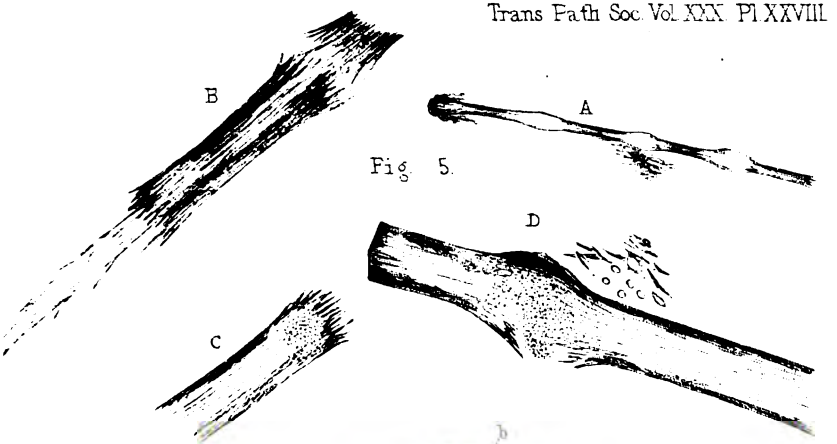

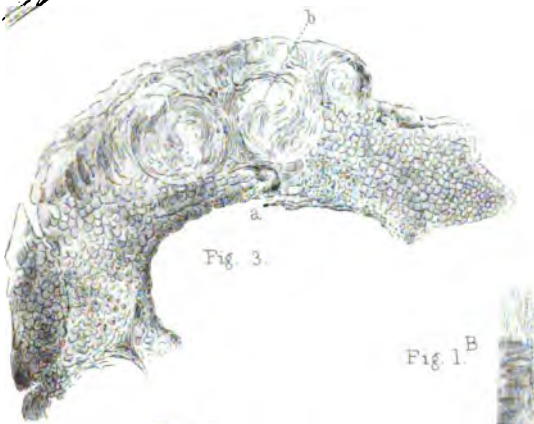


Fig. 3.

Fig. 1 B

Fig 2.




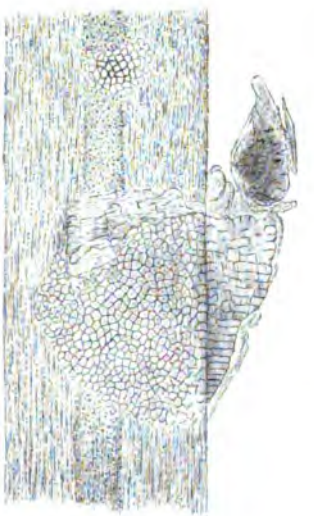

Mintern Lith.

Mintern Bros imp

Erasmus Wilson's description of a condition he calls "Fragilitas crinium;" but Mr. Wilson distinctly denied a preceding nodular swelling; and mere brittleness of hair, seen under many varying conditions, does not constitute the curious affection under notice. In the Catalogue of the Dermatological Collection of the College of Surgeons (1870) Mr. Wilson names an engraving of true Trichorrhexis, after Beigel, "Trichoclasia," to which he subsequently added the alternative title "Clastothrix." If, as Dr. Fox believes, a case described by Mr. Wilson in 1867 as Tricho-syphilis, was really an example of the affection recorded by Beigel and Wilks, the supposition that it depended upon syphilis is certainly mistaken. The condition found in the hair of a woman's head by Devergie in 1871, and named by him "Trichoptylose," is undoubtedly the same affection as Beigel's. It is briefly but accurately described in the last edition of Littré and Robin's 'Dictionnaire de Médecine.' It is remarkable that this is the only instance of the disease occurring on the scalp. Dr. Liveing and others have, however, recorded its presence in the axilla. All trustworthy observations agree in the absence of a fungus. Dr. Tilbury Fox, who placed the affection among the tineæ in his book, has since altered his opinion. With respect to nomenclature, it is a pity that so small a thing should be burdened with three names. "Trichoptylosis" has, strictly, the priority of date, but is the most awkward and the least descriptive of the three. Mr. Wilson's "Trichoclasia" is better, but the wide diffusion and just authority of Hebra's great work make it likely that the title there given will outlive the others, and that the affection will be generally known as *Trichorrhexis nodosa*.

*December 15th*, 1878.

---

## 2. *Piedra—a new disease of the hair.*

By Malcolm Morris.

The specimens that I show to-night are those of Piedra. The word piedra is the Spanish for "stone," and is used to designate a certain disease of the hair that occurs in the form of minute

nodes that rattle like stones when the hair is combed. The disease has only been found in one state of Columbia—that of Cauca. It was originally described in 1874, in a paper by Dr. Nicholas Osorio, of the University of Bogota, from which I quote the following:

"In 1874, Dr. Evaristo Garcia gave me a specimen of hair which had been sent to him from Cauca, and asked me to study in it the disease known in that state by the name of piedra.

"Dr. Guttierrez was kind enough to let me have a few more specimens some time afterwards.

"On examining one of these hairs by the naked eye, you will see several very small tubercles of a round shape, having the size of the head of a pin, of a black colour, and possessing a horny consistency. They are situated almost at equal distances. The microscopical examination with a low power shows no organisation at all. Magnified 350 times and treated with glycerine, scales similar to those of the hair-epithelium are brought into view. On teasing these tubercles with a needle, we see that they are hard and horn-like, and the small particles that are thus separated show the characters of the hair-epithelium. When this little tubercle has been taken off the hair remains almost natural, showing only a kind of circular depression around the spot which the tubercle had been filling up.

"These tubercles show none of the characters of the epiphytes described until now. They do not resemble the puccinia or the mucor, or the aspergillus, or the oidium, or the achor, or the microsporon, or the trichophyton.

"Considering the characters of the hair-epithelium and their resemblance to these offered by the elements in which the tubercle is separated by teazing, I believe that the disease is produced by the agglomeration of the epithelium in certain points of the hair." He adds "that it is found by experience that the disease is not contagious, and that the true cause which produces it is still unknown."

I have quoted from this report at length for two reasons. First, because my conclusions as to the nature of the disease differ materially from the opinion offered by Dr. Osorio, and, secondly, to prove the fact that the hairs I am about to describe are from the same district, viz. Cauca, and are affected in a similar manner; in other words, that they are genuine examples of piedra.

They were given to me a short time ago in Paris, by Dr. Guttierrez, the same gentleman who gave the specimens to Dr. Osorio. He told me that he had often seen the disease and that he

had removed these hairs. In answer to several questions, I gathered the following facts relating to the clinical history. It never occurs on any hair but that of the head, very rarely, if at all, in men. Never affects the roots of the hair, usually begins half an inch from root, thence spreads downwards, or rather is pushed on by the use of the comb. The number of nodes varies from one to ten on each hair. Two nodes are never found together but at irregular distances. There is a peculiar acid smell. It is not contagious. It never occurs in cold parts, but in the warm valleys. It is supposed to be caused by the use of a mucilaginous fluid, like linseed oil, which the women wash their hair with to keep it smooth and shiny. Another theory is, that washing in certain stagnant rivers produces it. These rivers contain a mucilage. The use of these fluids will not produce the disease in a cold climate; this has been proved by experiment. Heat is, therefore, essential as a part of the causation.

*General characters.*—The hairs are dark in colour, weak and flaccid. The small nodes or piedra masses occur at irregular intervals. They are intensely hard, producing a distinct noise when beaten against glass. In attempting to cut one with an ordinary knife great difficulty is experienced, the knife slipping off on either side. When considerable force is used the node breaks.

Under the microscope No. 1 (Plate XXVIII, figs. 1 A and 1 B) the node is seen *in situ* simply mounted in glycerine. In this drawing A is focussed to show the hair, B to show the surface of the node.

The appearance here seen is that of a honeycomb mass, consisting of spore-like bodies, deeply pigmented on the surface. There is a uniformity about the arrangement of these bodies, which is more clearly shown under the next microscope, and in drawing No. 2; in this drawing is shown the earliest stage of development, in which it may be seen that the mass appears to originate from one cell that grows by budding, not only laterally, as it will be observed at this point, but in every direction, forming radiating columns of spore-like bodies. As soon as the mass has grown to a certain size, the surface-cells seem altered in shape, becoming darker in colour, forming a pseudo-epidermis. Under the next microscope is a transverse section of the node, the hair itself having fallen from the centre. This drawing (fig. 3) shows it admirably. The radial arrangement of the spore-like bodies or hyphæ are now seen. Here and there are rounded spaces of considerable size, marked *b* in the drawing. These spaces do not apparently com-

municate with the surface, but are enclosed on all sides by the hyphæ.

Figure 4 represents some of the node substance broken up; at *a* is seen elongated cells arranged in tuft-like groups, and looking from their shape and size as if they had escaped from the before-mentioned cavities.

From the appearances which are here seen, I think it can be stated with confidence that the disease is fungoid in character, and that the fungus has attained a higher state of development than has been before described in connection with any of the dermatophytæ, with which we are familiar.

In trying to ascertain the real nature of this fungus, I must state my obligation to Mr. Charles Stewart for the hint that it probably belongs to the genus *ascomycetes*. He has kindly lent me a specimen which is under the microscope for comparison.

The drawings have been generously done by Dr. Alfred Sangster.

*March* 18*th*, 1879.

---

## 3. *The growth of the fungi in ringworm and favus comparatively studied.*

By George Hoggan, M.B.

Contributions to the history of the fungus of ringworm have of late been so numerous, and apparently so exhaustive, that I almost feel called upon to apologise for bringing this before you; and I can only justify the step by submitting that our knowledge of the course and progress of ringworm and its allied diseases is still incomplete, and having noticed some points which, I think, are not generally known, and which may prove interesting to many here, I have taken the liberty of bringing them before you.

I have chosen the fungi of ringworm and favus, because to me they present extreme types of two different conditions or directions of growth, between or under both of which most of the diseases of the skin due to vegetable parasites may be classed, and I have arranged specimens under the microscope which I think will be found fully to bear out the views I am about to lay before you.

Let me, however, begin by stating that I am not about to argue whether ringworm be due to an oïdium, an ustilago, a penicillium, or an aspergillus, or that favus may be due to any of these classes, or whether the two fungi be clinically the same, or different, or no fungi at all, each of these views being supported at the present day by some authors. What I am about to point out is that each one of the two fungi in its seat and direction of growth, in the appearance of its individual spores and in its clusters, in the element it destroys and its mode of destroying it, is entirely different from the other. I shall ask leave to direct your attention to the condition of the ringworm fungus upon the hair, rather than to its condition upon the surface of the skin, because in the hair we have a definite structure and arrangement of elements which we have not in the skin, and because its limitation to one general mode of disintegration renders the hair specially suitable for my purpose.

It may appear strange that, after the thousands of examinations that have been made of hairs affected by ringworm by eminent dermatologists, any point in its life history should remain unnoticed; but I believe the reason of this to be very simple. In examining for ringworm fungi, only the hairs which appear to the naked eye to be affected are chosen for examination, and the more they are affected the more readily are they chosen; and thus hairs in the initial stages, come to be overlooked, and the key to the whole thing unnoticed.

Now, in searching for the key, I pursue a different course. Having procured a clear case of ringworm, I search among what appear to be the healthy hairs at its margin for one in which only the first stage of invasion has been reached, and if among a hundred healthy hairs examined under the microscope I find one slightly affected, the find is well worth the trouble taken, and such an one is now under the microscope.

To understand the pathological effect of the fungus upon the hair, allow me to draw attention to the three or four points in its normal structure which make the point intelligible.

In the first place, we have the cuticle of the hair formed of the well-known imbricated cells, lying in one layer like slates upon a roof, and it is because the cells form only one layer that the hair is more suitable for our investigation.

As long as that one layer of cells remains intact, the hair, as a rule, remains also intact, but that layer once broken the hair perishes.

It protects the soft, moist, and probably living cells lying underneath it, not only from external influences, but also from becoming hard and dry from evaporation, as they are seen to do at the so-called point of the hair, which becomes tapered and hard through evaporation from the unprotected extremity. We shall afterwards see that the first step taken by the ringworm fungus is to get underneath this cuticle, and to throw it off like the bark of a tree, and this much effected, complete destruction ensues.

Upon the surface of the skin the cuticular layers of cells are too numerous, irregular, and constantly being rubbed off, to allow of its being a suitable tissue in which to fix and study the exact seat of the ringworm fungus. As a matter of fact, the fungus is seen growing several cells deep in the skin, leaving the question vague, but we have only to keep in mind that the many-layered cuticle of the skin becomes continuous with the one-layered cuticle of the hair to understand how in the first instance the fungus gets underneath the latter. So much for the cuticle. Now for the shaft of the hair, which consists of a comparatively solid tube, formed of elongated cells, and surrounding a more or less patent cavity containing the loose cells of the pith. The way in which the shaft is formed is easily explained by the manner in which a score of cells growing from the side of the hair papilla are forced, during growth, to compress themselves into the same length of the hair which accommodates the one layer of cells growing from the apex; but it is not necessary for this inquiry to go further into the point at present than to note that, owing to the locality where that shaft is formed, the ringworm fungus is not likely to penetrate into the shaft from below, as we shall afterwards see to be the case with the fungus of favus. Let us now follow the action of the fungus, as seen in the drawing and specimens under the microscope. That action may be divided into three stages, passing from the point of the hair towards its root.

In the first place, the fungus propagates itself as a thin layer, only one spore deep, immediately under the cuticle. The spores grow only laterally, as if from buds, the growth, however, being greater, or budding more numerous, in the direction of the length of the hair than round its periphery. For some time after it shows itself, the spores seem too small to work mischief, lying in regular rows under an undisturbed cuticle, but they represent the thin end of the wedge, which has been firmly inserted, and soon brings about the second

stage, when the spores growing larger in their bed, make room for themselves by bursting the cuticle of the shaft, as the bark is stripped from a tree, and throwing it off altogether.

The position is now entirely won by the fungus, which, from inability to attack the compact, elongated cells of the shaft, or the necessity of having convenient access to oxygen, had hitherto confined itself to the lower surface of the hair cuticle; but that cuticle removed, the fungus attacks the now defenceless cells of the shaft underneath, grows between them in rows or sheets, and separates them laterally like the bristles in a brush. The hair is now destroyed and breaks off. These three stages appear much plainer in the specimens than any description I can give of them, and they teach a lesson that would never have been learned upon the shapeless and structureless trunks found in an advanced stage of the disease. I may add that the specimen has not been treated by any caustic alkali, a process which makes more fungi than it shows, both in my hands and the hands of others, judging from one half of the woodcuts that are published.

In the fungus of favus, on the other hand, we have an element whose special seat is immediately underneath the epidermis, and between it and the dermis, its special action being to separate and raise the whole layer of epidermis up bodily from the dermis, and thus to form the circular cups on the surface of the skin, which are characteristic of the disease.

That this point of primary interest should not have been noticed before, is not so surprising as in the case of ringworm, for in favus t can only be clearly seen in such perpendicular sections of the scalp as I have placed under the microscope; and as patients do not die of favus, and the risks of cutting a piece of skin from the scalp are too great, it is not surprising that the point should have remained so long unnoticed.

But just as the ringworm fungus, which had its special seat immediately underneath the cuticular layer of the hair, ends by bursting it off and then appearing everywhere upon and within the hair, so does the favus fungus, after raising off the epidermis, end by piercing and destroying the dermis underneath and the epidermis above, and appearing in the shaft of hairs affected in the disease.

Its action in raising the epidermis as a sheet will be clearly seen in the specimens, the hair follicles and ducts of the sweat-glands remaining attached to the epidermis while it is being raised, and

being drawn out of their pits in the corium, like fingers from a glove. This operation has been facilitated by the growth of the fungi downwards between the cellular and gelatinous (white fibrous tissue it is called) sheaths, separating these in the first place, so that elevation of the dermis draws them also out.

The plants and spores of the fungi may still be seen attached to the outer surface of the sweat ducts in the preparations. In these preparations, and also in the drawing, may be observed the first stages of growth of the plant (if I may use the term) where three or four cells or spores appear growing from what is now the free surface of the dermis, the globular spores diminishing in size and tapering towards the point, until the plant appears like one of the little turned wooden pinnacles that one sees taking the place of a chimney on the ends of schools and meeting houses. We have no longer here, as in the cases of ringworm, fungus growth going on in lines or sheets, but the large favus fungi form plants like oak trees when seen separately, and looking like cactus hedges when seen in the mass cut perpendicularly, that is to say, in the direction of their growth. This, however, is a description which in no way corresponds to existing ideas, which conceive and represent favus plants as long lines of spores. Those conceptions are formed through examining the *débris* of the plants, which has become mixed up with the yellow inspissated serum or albumen exuding from the unprotected dermis, and forming the favus crust generally examined under the microscope. It would be quite as reasonable to expect that one could form a correct conception of an oak tree from an examination of the *débris* and shed leaves lying below it, as to describe a favus plant from the *débris* it sheds. It is quite true that favus fungi have been described and figured in the shaft of a hair as long lines of spores or mycelia; such appearances are, I have no doubt, quite correct, although I have not met with any in my specimens.

It is quite reasonable to expect that, as the favus fungus grows underneath the epidermis, any spores or plants growing within or from the papilla of the hair, would be carried along in the direction and process of growth of that structure, and would take the elongated appearance it there represents, just as the prickle cells of the epidermis assume the elongated form of cells in the hair shaft (or fibres as they are sometimes called), but in neither of the two elements thus modified would the true and general type be recognised. Here and there in the section, but especially in the

angle formed, at the periphery of the favus cup by the dermis and epidermis, a layer of coagulated albumen has been cut through in which may be seen imbedded hundreds of the spores and pieces of the favus plants of all sizes and shapes, and looking as natural and well preserved as flies in amber.

The manner in which the fungus propagates by budding can be very satisfactorily observed on some of the large spores forming, so to speak, the trunk of the trees. They all appear, however, to fall off when they have reached a certain size, and do not attempt to grow *in situ*, which would destroy the tree-like appearance of the plants; they probably go to form the great mass of the *débris* composing the crusts, and also to form the nuclei of new plants.

It will be observed how beautifully the fungus cell or spore changes its shape when, from forming part of a small shoot or branch, it is called upon to act as the trunk of the tree. The round spore first becomes oblong in shape, but as greater strength and power of adhesion to contiguous cells is required, it becomes constricted somewhat in the middle, like the bones of the fingers, while its end surfaces flatten, so as to form a large surface attachment for the next trunk spore on its distal and proximal ends.

Had this communication been made, as intended, at the last meeting, I should have only referred shortly to the question of the dynamic effect of the fungi in trichorexis nodosa in forming a third type of parasitic growth and mode of destruction, as I had already given my opinion upon it in the 'Lancet.' The discussion, however, which arose on Dr. Pye-Smith's communication, and in which I took part, may make it advisable that I should put on record here the opinion I expressed, and which I justified the same evening by exhibiting specimens showing clearly the masses of spores which were the special character of the disease. At the same time, I ventured to remark that, if the drawing and specimens of Dr. Wilks and Dr. Pye-Smith were typical of the disease they referred to, it seemed probable to me that two different diseases were being confounded, as they were in no way characteristic of the disease to which I referred, and of which I again show specimens.

There was no brittleness of the hairs in my case; on the contrary, when the exploding force of the growing granular masses within the hair tube had burst the tube at what is called the node, it only split the tube open at one side, forming a boat-shaped cavity, which seemed filled with spores, and from which masses of the spores were shed

all around. Of course the injury thus done exposed the cells of the shaft to subsequent destruction, but to the last they showed a non-brittle condition, and even when the hair was broken, it showed rather the longitudinal shiver of hard wood than the transverse, cane-like brush of the specimens shown by Dr. Pye-Smith.

I then insisted strongly on the point that the nodular swellings, and subsequent bursting and breaking, were due solely to the growth of the roe-like masses occupying the tube of the hair. I, however, admitted the possibility of those roe-like masses being a granular degeneration of the cells of the pith, but whether fungi or granular degeneration the dynamic effect was the same in bursting the hair tube. Histologically speaking, they might be either, but their exceedingly minute size makes it difficult to decide. Chemically, all the evidence was in favour of their being parasitic. In the first place, the disease began at the tips of the hair and passed down the hair tube, as if infection had been from without, while a granular condition of the cells would almost certainly have passed from the nutritive cells to the periphery.

Secondly, in similar cases, cutting off the diseased tips of the hair had cured the disease, showing again that the disease was due to external influence, for had it been due to internal influences, cutting off the diseased tips could scarcely have interfered with further development. In the present case, the beard and moustache were quite white, and the disease made its appearance in definite spots of a bright red colour, causing considerable disfigurement and consequent annoyance to the patient.

For the above reasons, then, coupled with the very distinct microscopic appearances, I incline to the opinion that the roe-like masses were parasitic and not granular, and, at all events, choice was limited to the two causes.

As I am not aware that any drawings exist showing the relation of the spawn-like masses to the injured spots, I have prepared drawings of two stages of dynamic action, namely, a newly exploded node and an exploded node being followed by disintegration of the cells of the hair shaft. They have all been drawn from a hair which had undergone no change from reagents, being preserved in glycerine as it was taken from the beard. I submitted other specimens to various reagents, but the appearances still remained, although the mechanical action of the washing and boiling had been to get rid of most of the free spores. As a rule, I condemn the use

made of most of the reagents recommended for the examination of hairs. It is difficult to say whether they do most harm by destroying natural appearances or by introducing artificial ones.

After what I have said of the comparative seats and results of growth of the fungi of ringworm and favus, it will readily be understood why the one should be less amenable to treatment and less easily eradicated than the other, and it is because I can nowhere find that the reason has been shown pathologically, that I have ventured to lay before you those views upon what I fear you may be tempted to consider a very paltry subject.

*December 17th*, 1878.

---

## 4. *Disseminated clavus of the hands and feet.*

By N. Davies-Colley, M.A., M.C.

I am indebted to the late Dr. Gayer, of the Medical College, Calcutta, for the specimen exhibited. It is the hand of a Hindoo Brahmin, æt. 45, who died in the College Hospital after amputation of the thigh for a severe compound fracture. Nothing is known about the previous history, except that the man was idiotic and epileptic. The soles of both feet and the other hand were affected with a similar eruption.

Dr. Gayer believed that "the hand was sound in all respects except the skin," and that "there was no anæsthesia present." He also stated that the nerves of the arm were not hypertrophied.

The hand is well formed. Upon the ball of the thumb, especially towards the radial border, there are irregularly-shaped patches of a white colour, occupying altogether about one third of the area of this region. There are also two small patches, in which the pigment is absent, at the root of the index and ring fingers. Scattered over the palm are numerous hard elevations of a hemispherical or bluntly conical shape, which make the skin feel like a nutmeg-grater or the material called shagreen. They are elevated about $\frac{1}{30}$th of an inch above the surrounding skin, and their height is

from $\frac{1}{8}$ to $\frac{1}{4}$ of the breadth of the base. Some are slightly cupped at the summits as if the spiny tops had been broken off. Here and there the whole tubercle appears to have dropped out, and a small pit in the skin shows where it has been. They are most numerous in the lower third of the palm above the roots of the fingers, and here I calculate that they number about sixty to the square inch. None are to be seen on the ball of the thumb, except near its junction with the rest of the palm. The hypothenar eminence is also free. Up the centre of the palm they form a band, which is $1\frac{1}{4}$ inches broad near the heads of the metacarpal bones, and gradually decreases to $\frac{3}{4}$ of an inch at the crease which separates the hand

WOODCUT 13.

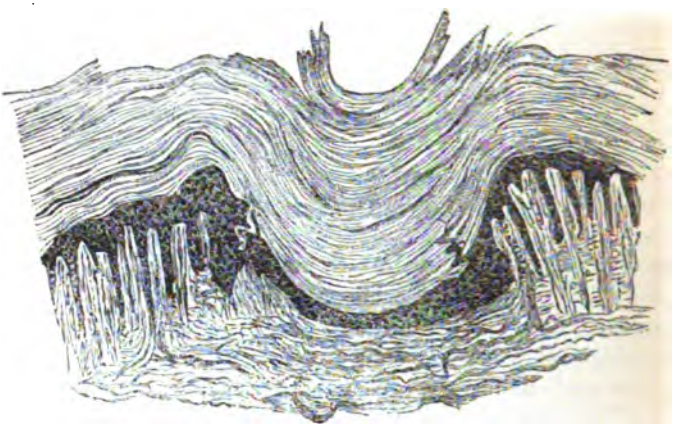

(×32)

from the forearm. On the palmar aspect of the fingers and thumb they form small groups, which are almost confined to the flexures of the joints, especially those of the metacarpo-phalangeal and first phalangeal joints.

The nails, the skin of the back of the hand and that of the forearm are quite normal. There appears to be no connection between the leucodermic patches and the tubercles, for hardly any of the latter can be seen where the pigment is absent.

Upon examination of a section of one of them under the microscope, the projection is seen to be due to a great thickening of the horny layer of the epithelium (see Woodcut 13), which is two or

three times as thick as that in the neighbourhood. The Malpighian layer, on the other hand, appears to be very little altered. Here and there it is, perhaps, a little thicker than normal. The papillary structure of the corium has quite disappeared under the greater part of the tubercle, and a slightly sinuous line alone indicates the separation between the epidermis and corium.

The sweat-ducts are normal. In the papilla around, and also in the deeper fibrous tissues of the corium, clusters of irregular granular masses of a reddish-brown colour are seen, which I take to indicate the sites of old effusions of blood.

It would seem, therefore, that these elevations are very small corns, and that the eruption is really a profuse development of minute and very prominent clavi. They are too small and numerous, and spread over too large an area, to be the result of ordinary pressure. Moreover, their absence from the ball of the thumb and the hypothenar eminence is hardly compatible with this cause.

As no history could be obtained, we can only guess at the origin of this condition.

It has occurred to me as possible that it was produced by frequent contact of the palms and soles with hot dust and sand. The remains of extravasated blood under the healthy portions of the skin seem to imply the existence of some irritation from friction or other causes. It is to be noticed that these hæmorrhages could not have been set up by pressure of the clavi, for they are around and not beneath them. The affection would seem to be a rare one, even in India, for Dr. Gayer, although he had had a long experience of Indian diseases, had never seen a similar case.

*March 3rd*, 1879.

*Report.*—We have examined Mr. Davies-Colley's specimen of horny epithelial growths on the palmar surface of the hand, and agree in the description given above.

H. G. Howse,
C. Hilton Fagge.

*April*, 1879.

5. *Eczema squamosum (vr. hystrix) of leg, associated with elephantiasis, from long continued congestion due to backward dislocation of the knee-joint.*

By H. G. Howse, M.S.

Annie M—, æt. 19, single, was admitted into Guy's Hospital under my care on January 14th, 1879.

*Family history.*—Father alive and healthy. Mother died in childbirth, but had suffered for some years from morbus coxæ with discharging sinuses.

*Personal history.*—When eight years old she was struck by a stone just in front of and below the knee; the skin was cut, but healed up in a few days, and she went to school as usual. Shortly afterwards a swelling appeared about the knee; it soon burst, and continued open and discharging. She then took to her bed and remained there for four or five years, the discharge continuing during the whole of that period. The knee was commonly dressed with wet rags and poultices. It was lanced two or three times when any fresh suppuration showed itself by pointing, and occasionally it was dressed with ointment, but no splint was ever applied to it, nor was she ever kept entirely at rest for any lengthened period, being allowed to get up at intervals.

The swelling about the knee afterwards seemed to extend slowly down the leg, the whole of which finally became affected. The skin became hardened, scaly, and discoloured. This discoloration commenced a little below and in front of the knee, and extended principally downwards, but also slightly upwards. The discharge from the sinuses continued during this period, varying in amount, but greater in cold weather.

On admission, the right knee was flexed to a right angle and dislocated backwards; there was a small amount of movement in it, which caused pain. The limb from the knee downwards was wasted; the skin was covered with dark-coloured thick scales like those of an armadillo, forming a kind of mosaic over the surface of the leg. There were large cicatrices about the knee, at the sites of former suppurations. These had caused the tissues immediately above the joint to waste so that there was a considerable contraction

in the size of the thigh at this spot. Above this point the thigh expanded, and the tissues were normal; although not equal in size to its fellow, yet the nutrition of this part of the limb was very good. The patient could not bear any weight upon the limb, and had walked for years with crutches. She was nervous and hysterical, and evidently suffering both mentally and physically from the condition of the limb.

The state of the integuments below the affected joint, the extreme backward dislocation of the tibia, as well as the mental and physical condition of the patient seemed to preclude any attempts at conservative surgery in the way of excision. She was therefore advised to submit to amputation, to which she consented. On February 4th, 1879, this was done immediately above the knee, by lateral flaps; this mode of amputation being adopted on account of the distribution of the affected skin, so as to save as much of the limb as possible. The femur was of small size for a person of her age and build. The popliteal artery and vein were both very small; the former was about the size of an ordinary adult radial. This was torsed, and a few small vessels tied with ordinary catgut; but there was very little hæmorrhage, showing that the blood supply to the affected limb had been very small. The flaps were drawn together with wire sutures, a drainage-tube introduced, and carbolised gauze dressings applied over the stump, the whole of the operation having been conducted with antiseptic precautions.

The patient did uninterruptedly well, though somewhat slowly, as might indeed be considered likely from the small size of the principal blood-vessel of the limb, and consequent deficient nutrition of the flaps. The average temperature was 98·8°; the highest temperature (once) 101°. The drainage-tube was removed on February 19th, and the last wire sutures on March 5th. She left the hospital on March 28th, the stump being then entirely healed except one small sinus, in which, however, no dead bone could be detected.

On May 31st, she was re-admitted to have a small, painful, compound sebaceous cyst removed from behind the ear. This was done on June 10th, and the wound healed primarily. A sinus in the stump still existed, but no bone could be found in connection with it, so its aperture was slightly enlarged with the knife and nitrate of silver applied. It then slowly healed and she was finally discharged from the Hospital on June 30th. Since the amputation she has immensely improved in health mentally and physically.

*Examination of the affected limb.*—The mosaic scale condition of the epidermis goes completely round the integuments of the leg, affecting the calf equally with the anterior surface. A patch of skin immediately below the knee on its anterior surface is fairly free from the thickened cuticle. The dorsum of the foot and of the toes is thickly covered down to the roots of the nails. The heel is nearly free, more especially posteriorly and on its inner side, and the whole of the plantar surface of the foot is comparatively free. Even on the parts least affected there is, however, thickening of the epidermis, and on the sole this is more marked towards the anterior part than posteriorly. The size of the mosaic scales is greatest over the middle of the leg; they here commonly measure from a quarter to half an inch across or even more. They are not at all regular in pattern, though the whole together has the appearance above described. Towards the dorsum of the foot and upwards towards the knee the scales become much smaller in size, assuming a conical appearance, and bearing a much closer resemblance to hedgehog or porcupine spines than to scales. When these scales are detached from the underlying epidermis (which may be done quite readily), they are found to have an average thickness of $\frac{1}{8}$th to $\frac{1}{3}$th inch or even more. Those at the upper part of the leg, when detached, leave a fairly smooth surface of epidermis underneath them, but those in the middle of the leg present on their under surfaces a series of large, coarse, conical processes, about $\frac{1}{16}$th inch long, which fit into corresponding depressions in the epidermis. These processes are much lighter in colour than the external surface of the scale.

When a section is made into the skin vertically, the corium is seen with the naked eye to be much thickened, and processes from it descend into the underlying fat tissues. The superficial fascia is not by any means atrophied, but is rather abundantly developed. Bands of fibrous tissue are found everywhere passing amongst the fat lobules, giving this stratum a much more uniform and denser consistence than it usually possesses. The same thickening of the fibrous element is found amongst the muscular tissue of the limb. The fascia propria of each muscle is correspondingly thickened, and into the substance of the muscle itself fibrous bands dip, dividing it into loculi which contain the muscular fibres. These fibrous septa are but thickenings of the thin septa ordinarily found in healthy muscle, but their hypertrophy in the present case gives a greater

consistence to the muscle, and a sense of greater resistance when cutting it with the knife.

Examined microscopically the thickened epidermis is not found to present features different from those presented by ordinary epidermal tissue. The *papillary* layer of the corium presents for the most part papillæ of the ordinary size. There are, however, here and there tufts of elongated processes, in which the papillæ attain a length of $\frac{1}{20}$th inch. These were principally examined from the affected skin near the knee, where the epidermal scales presented the more conical form. Below the papillary layer, the corium and superficial fascia present a densely matted mass of fibrous tissue, intermingled with very numerous minute nuclear elements, something like those which I have observed in a case of scleroderma. The thickness of these layers is much increased. In the deeper parts, fat vesicles and lobules more or less altered and atrophied by pressure, are interspersed amongst the fasciculi of connective tissue. Numerous spaces are seen amongst the fasciculi, but whether these are related to the lymphatic spaces of elephantiasis I have not had sufficient opportunities of examining the latter disease to be able to express an opinion.

The fasciculated arrangement of the connective tissue extends even amongst the muscular fibres, where the interfibrous connective tissue is much increased in amount, giving the section of the muscle to the naked eye, the appearance of being cut up by septa and trabeculæ.

*Remarks.*—The interest in this case lies in the origin of the condition from a state of chronic congestion of the capillaries of the part, due to knee-joint disease. There is first the history of injury to the knee, then a very slowly progressing disorganisation, finally abscesses and backward dislocation from softening of the ligamentous tissue. The popliteal vein became thus pressed upon first, probably to a greater extent than the artery, on account of the greater rigidity of the walls of the latter. Hence, we have the "œdema extending down the leg from the knee," spoken about in the report. This may account also for another element contained in the report, viz. the small size of the arteries at the amputation; the difficulty in the circulation from venous pressure increasing, the supplying vessels, viz. the arteries, either atrophied, or, at any rate, did not increase *pari passu* with the other tissues. From this condition arises a state of solid œdema of the leg, in which the papillæ and rete mucosum

slowly hypertrophy. From this in process of time arises the mosaic thickening of the epidermal tissue which formed so remarkable a feature in this case.

It is curious that the only other well-marked living case of this kind which I have seen is on the leg of a girl, now a nurse at the Evelina Hospital, in whom I excised the knee-joint for severe pulpy disease of the parts. The limb is entirely ankylosed, and the cicatrix dense and firmly adherent to the bone. Just below this adherent cicatrix, just where the capillary circulation *must* be much impeded by the firmness of the adhesion, occurs a patch as above described. And in two cases presenting a similar condition in the Guy's Hospital Museum, chronic congestion is spoken of as the exciting cause.

That the pathology of this case is thus explicable is tolerably self-evident. Whether the term used at the heading of this paper is the best that can be applied is another question. In default of a better we may still continue to use it. Ichthyosis is inapplicable, because this was not a congenital affection, and it seems to me that elephantiasis proper is also nearly as inapplicable, the latter being frequently a disease of hypertrophy, attended with large size of the supplying arteries of the limb, whereas here the vessels were all atrophied. Upon this point, however, I speak with some hesitation, on account of the very great variety which obtains in the cases classed under this head. Indeed, it seems to me that the word "elephantiasis" as at present used includes cases of more than one disease.

*February 4th*, 1879.

---

## 6. *Molluscum fibrosum.*

By John Wood, communicated by Royes Bell.

George L—, æt. 43, single, a stoker, living at Sunderland, admitted into King's College Hospital under Professor Wood's care. His family history is very good; his parents were not blood relations. His mother died when 36 years of age in childbed, her twin brother is alive and well. His father died at the age of 87.

No members of his family have suffered from skin complaints. At his birth nothing remarkable was noticed in his appearance, but when three weeks old the left upper eyelid began to thicken, and increased to such an extent that it quite covered the eyeball and prevented him from seeing out of the left eye. Two unsuccessful attempts have been made to improve matters, the first when he was 4 years old, the second when he was 14 years of age; the scars of these operations may be seen on the eyelid. The sight of the eye is quite good when the obstructing mass is lifted from before it. The outer part of both upper and lower lid of the eye has become elongated to the extent of 2½ inches by the overgrowth of the connective tissue and vessels, and hanging forwards, inwards, and downwards, covers the eyeball to such an extent as to prevent useful vision. The growth feels quite soft like nævoid tissue, and twitches frequently, The eye lashes are scanty, at times there is lachrymation and a discharge of mucus from under the lid.

The left side of the face and of the upper lip is also thickened. There is no abnormal growth of hair on this side of the face.

The left thigh and leg present a peculiar appearance, as the whole of their posterior aspect is occupied by large hypertrophied masses, which hang down in festoons extending from the fold of the buttock to the heel. These cause him great inconvenience as they increase in size after standing and induce fatigue from their weight. The growth began in the thigh when he was three years old, and has gradually crept down the leg to the heel. Both in this region and in the face the growth has been continuous but without pain.

The tumours are soft, and freely movable, and feel like thickened areolar tissue and blood-vessels, and can be handled without giving him pain.

The skin covering the swellings is coarse-looking; the orifices of the sweat ducts are very distinct, these are far apart and do not seem to be increased in number; he has to be very particular as to cleanliness as the secretions of the part are apt to become very offensive. Sensation diminishes from the circumference to the most prominent point of the tumour.

Scattered over his trunk, especially his back, are a number of small tumours from the size of a pea to that of a cherry; these are soft to the touch. A tumour removed from the back of the head in September 1878 has not returned.

Mr. Wood has determined to remove the superfluous growth from

the eyelid and also the tumour from the lower extremity, either in part or wholly.

Mr. George Pollock has narrated an interesting case in the 'Med.-Chir. Trans.,' vol. lvi, 1873, and the success attending his operation encourages surgeons to interfere. At the present time, with the aid of Esmarch's elastic bandage, which can be efficiently applied to the limb, and the antiseptic treatment carried out as it is at King's College Hospital, after the method of Professor Lister, we are justified in looking forward with confidence to a speedy and safe issue to the case. *February* 18*th*, 1879.

P.S.—Microscopical examination by Mr. Barrow of portion removed by operation from the face by Mr. Wood showed:—*Hypertrophy* of all structures except the papillæ, which were atrophied, and small cyst cavities in the subcutaneous tissue.

---

## 7. *The histology of molluscum contagiosum* (*Bateman*).

By Tilbury Fox, M.D., and T. Colcott Fox, M.B.

The view which has long been held, and with almost universal acceptance in England, concerning the nature of molluscum contagiosum (Bateman), viz. that each little tumour originates in, and is, an hyperplasic growth of a sebaceous gland, has been seriously assailed of late years, chiefly by continental observers, and especially by Bizzozero and Manfredi in Italy,[1] by Retzius[2] of Stockholm, C. Boeck[3] of Christiana, Lukomsky[4] of Kief, Otto Simon[5] of Berlin, and lastly, by Piffard[6] of New York, as the result of their micro-

[1] 'Revista Clinica di Bologna,' 1871 (with plates); see also the 'Centralblatt f. d. Med. Wissensch.,' Feb. 12th, 1876. (These observers formerly thought the tumours of sebaceous origin.)

[2] 'Deutsche Klinik,' 1872.

[3] 'Vierteljahreschrift für Dermatologie und Syphilis,' Jahrgang ii, 1875.

[4] 'Virchow's Archiv,' vol. lxv, 1875. (He was apparently unaware of the observations of the Italian professors.)

[5] 'Vierteljahr. für Derm. und Syph.,' iii Jahrgang, 3 Heft, 1876.

[6] 'Diseases of the Skin,' 1876, p. 345.

scopical researches. These observers are of opinion that the disease is in no way connected with the sebaceous glands, but that the little tumours are caused by a peculiar overgrowth and degeneration of the rete Malpighii. It is important, however, to add that what may be regarded as the old or original view, has recently been reaffirmed by Vidal[1] and André in France, and Kaposi[2] in Vienna, as the result of their independent microscopical observations. The belief in the sebaceous origin of the tumours was grounded, firstly, on clinical observation, secondly, on the experience common to many British observers, from Henderson[3] and Paterson[3] to Mr. Jonathan Hutchinson,[4] that when a "tumour" was enucleated and dissected out, its lobulated character, closely resembling a compound racemose gland,[5] could be easily displayed; and thirdly, on the microscopical observations of Henderson, Paterson (loc. cit.), Dr. Duckworth,[6] and Dr. Hilton Fagge,[7] which seemed conclusive.

As it appeared that the new views were meeting with considerable acceptance, we have recently carefully reinvestigated the histology of a disease presenting ample material, and now offer a brief report to the Society. We believe that we shall produce conclusive microscopical evidence to show that the older view is the correct one, and that the arguments which are thought to be antagonistic to it are misrenderings of actual facts. On comparing the descriptions and plates given by those, both British and Continental, who have written on the subject, we notice that they are all agreed as to the actual appearance of the tumours as observed under the microscope. These tumours certainly, whatever opinion may be held as to their origin, bear a very striking resemblance to the structure of a compound racemose gland both in the appearance of lobules connected by branch ducts leading to a central one and finally opening on the surface, and also in the details of the acini. Observers are also agreed that the contents of the tumours consist of epithelial cells, and the very peculiar bodies known as "mollusc

[1] "Le Progrès Médic.,' June 9th and 23rd, 1877, reported from the 'Trans. of the Société de Biologie.'

[2] 'Vierteljahr. für Dermat. und Syph.,' iv Jahrgang, 3 Heft, 1877.

[3] 'Edin. Med. Journal,' vol. lvi,' 1841, pp. 213, 280.

[4] 'Lectures on Clinical Surgery,' 1878, p. 11.

[5] Piffard (loc. cit.) says, "The whole presents a rough appearance to a racemose sebaceous gland, for which it was taken by the earlier observers."

[6] 'St. Bartholomew's Hospital Reports,' vol. iv, 1868.

[7] 'Guy's Hospital Reports,' 1870.

bodies" or "molluscous cells." It is only right to say, however, that although the latest observers have added nothing new to our knowledge of the microscopical appearances of this disease, they have recorded them with increased exactness and detail. The real points at issue then are these:—*Firstly*, the origin of the gland-like looking tumours, and *secondly*, the source and nature of the so-called *mollusc bodies*. Lukomsky, whose views we may take as recent and as agreeing in the main with those of Bizzozero and Manfredi, obtained his specimens from Professor Recklinghausen, who handed him some twelve little tumours *from the penis* of a man who had died in hospital. Although tumours from this site are open to the objection that they are likely to be condylomatous, still, *from Lukomsky's description*, he seems to have dealt with specimens of true molluscum sebaceum.

In his examination of the expressed contents he describes irregular, faintly granular, cuticular-looking cells, and the mollusc bodies, some of which are lying free and in some appearing as if thrust into the epithelial cells (there may be two or three in a cell), and then perhaps surrounded by a vacuole, and, lastly, epithelial cells showing moulds from which the mollusc bodies have evidently dropped out. He thinks that these appearances are greatly in favour of the fact that the mollusc bodies are produced in cells of the Malpighian layer,[1] and as the latter reach the surface and take on the cuticular changes, the mollusc bodies drop out. He also figures a vertical section through a very early tumour which, as delineated by him, certainly looks like a marked localised overgrowth of the Malpighian layer. He then connects this condition or stage with that of the fully developed tumour by other intermediate stages of development, which he asserts proves the growth downwards of the interpapillary portion of the rete by cone-like processes into the corium. In this process of overgrowth, in which wandering cells take a prominent part, the papillæ are gradually almost obliterated and form what in the fully-developed tumour look like fibrous septa between the acini and the lobules. As the overgrowth of the rete continues degenerative changes occur in the cells, and the tumour is hollowed out into the gland-like looking structure and becomes filled with degenerated cells, which discharge themselves externally. Lastly, he discusses the nature of these degenerative

[1] He differs from the Italian professors, however, in thinking the wandering cells play a very prominent part in their production.

## DESCRIPTION OF PLATE XXIX.

Plate XXIX illustrates Drs. Tilbury and T. C. Fox's paper on the Histology of Molluscum Contagiosum. (Page 460.)

FIG. 1.—Section from the neighbourhood of a large tumour, to show the earliest stages of the process (tumour removed from the arm of a child). × 120

FIG. 2.—Vertical section through the centre of a tumour to show the enormously dilated duct (from the arm of a man suffering from a general form). × 75 (Pillischer).

FIG. 3.—Portion of an acinus, × 400 (Verick), to show—

*a.* The completely formed "mollusc bodies" being forced to the mouth of the acinus.

*b.* The fibrous wall of the acinus.

*c.* A "mollusc body" forming by vacuolation and the formation of sebum.

Fig 1.

Fig 2.

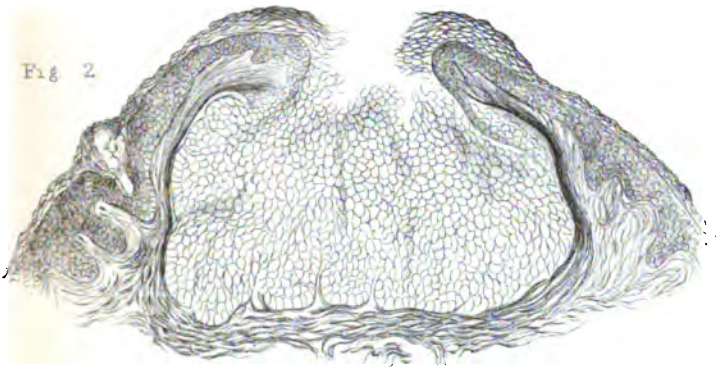

Fig 3.




F. Mintern lith

Mintern Bros imp

changes, and details the actions of reagents, but he comes on this head to no definite conclusion.

Boeck (loc. cit.) is in reality in accord with Lukomsky in all essential points, and their illustrations tally. He finds the same acinus-like growth made up of enlarged and altered epithelial cells, which he regards as formed by the downward growth of the Malpighian layer and quite unconnected with the sebaceous glands.

We now proceed to give our own observations. The tumours[1] we have examined varied in size from that of an ordinary pin's head only, and not only this, but we have carefully examined the accompanying adjoining portions of apparently healthy skin, so that we might observe the very earliest changes in the formation of the tumours if possible. Firstly, we can confirm what other observers, including Boeck and Lukomsky, have found as regards the general appearances seen under the microscope. But we are sure that the view taken by these latter observers, as to the origin of the tumours, cannot be held by any one who has traced out the earliest changes that occur in their formation.

In one of our sections through a small tumour—fortunately for our purpose in an adjoining portion of skin—we noticed that a sebaceous gland was in a state of commencing hypertrophy (Pl. XXIX, fig. 1); the lobules and acini were larger than usual and unusually distended, with increased contents, but no actual budding out of new acini was observed. Woodcut 14 gives the appearance of an ordinary molluscum tumour as usually met with in a vertical section which just misses the central aperture, and is, we think, really only an exaggeration of the early condition pourtrayed in Pl. XXIX, fig. 1. In Pl. XXIX, fig. 2, is seen a similar tumour from another case in vertical section through the central aperture or duct. It is well known that this central aperture is to be found almost invariably, and it will be noticed that it never presents an appearance consistent with the *bursting* through the cuticle of the contents of the tumour, but has all the aspect of the dilated duct. This dilatation (accompanied by shortening of the duct) sometimes takes place to an extraordinary extent where much pressure is exercised, as was most markedly shown in

[1] We have examined many of these little tumours, so well known in England, taken from the faces and bodies of children both in the apparently contagious and non-contagious form, also from the scalp of a man of 45 (a rare site), and from a case of general distribution in a man aged 60; and from a mother who was nursing a child affected with these tumours.

the section of a tumour removed from the confined situation on the scalp. Woodcut 14 certainly does not show any implication of the rete in the growth of the tumour beyond its thinning and stretching, and the consequent obliteration of the papillæ, from the pressure exercised by the enlarging growth. It cannot be denied that some of

WOODCUT 14.

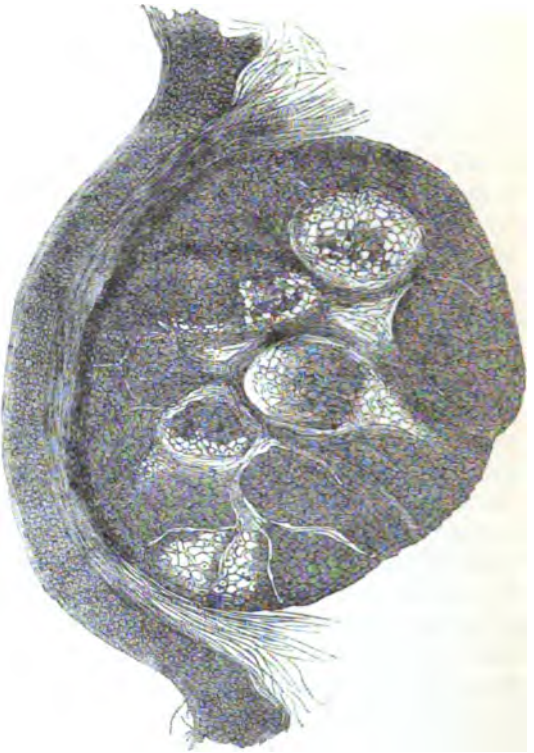

the sections made through the central dilated duct simulate an appearance consistent with the fact of the tumour being due to a down growth and subsequent degeneration of the rete. Pl. XXIX, fig. 2, is a very fair illustration of this point. Beyond this we have not met with any evidence of such implication of the rete.

We have traced the gradually increasing hypertrophy of the gland

structure, with concurrent increase of contents, and consequent dilatation of the ducts into a large cavity in a variety of specimens. As each tumour enlarges it condenses the connective tissues around and so forms a thick capsule. Numerous blood-vessels are seen cut across in the capsule, and the leucocytes seem also increased in the latter.

We now proceed to speak in detail of the *changes that occur in the cell contents of the tumours*, and to point out the true character of

WOODCUT 15.

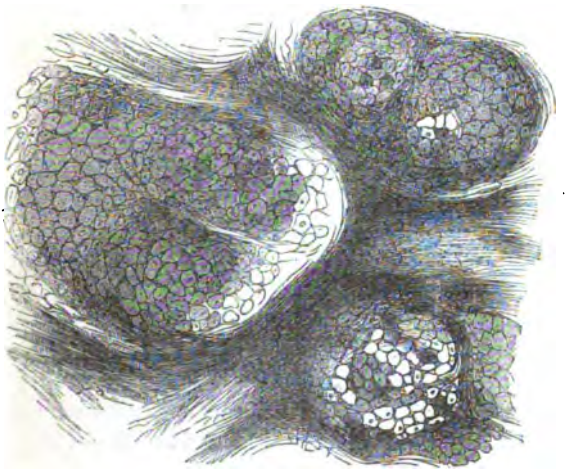

This woodcut is taken from the central portion of Woodcut 14, highly magnified.

the peculiar bodies met with. In order to understand properly what happens, it is necessary not only to examine the acini and their contents in a section, as well as the expressed contents, but to appreciate the mode in which the sebaceous secretion is formed in a normal gland. We find that the peculiar mollusc bodies are simply produced by a process of extreme vacuolation of the ordinary lining cells of the acini, which process goes on more or less constantly in health.

When an acinus is examined in section (Pl. XXIX, fig. 3) the cell contents, at the most external part nearest the investing capsule or septa dividing the acini, consist of one or generally more limiting layers of the more or less columnar cells usually met with in sebaceous glands. Succeeding these (*i. e.* more internally away from the septa

towards the centre of the acinus) several layers of smaller "Schleim" cells are met with crowded together in abnormally increased numbers, and in which the nuclei are seen to be very active. These cells are again succeeded towards the centre of the acinus by progressively enlarging cells in all stages of vacuolation, and, with increase of size and completeness of vacuolation, gradually assuming a peculiar aspect, and the vacuoles becoming filled and distended with a thick gummy-looking substance, which makes them appear as if they had undergone a complete colloid or other degeneration. In these cells the nuclei, around which the vacuolation usually commences, get pushed to the side of the cell and eventually disappear or are obscured. There are thus two sets of conditions to be noted, (*a*) changes connected with the increased formation of cells in the "Schleim" cell layer as seen by the activity of the nuclei, the increasing number of cells, and their small size, and (*b*) changes noticed in the succeeding layers connected with the formation of altered sebum, which begins by a vacuolation of the protoplasm and the deposition of oil in the vacuoles. These changes are clearly traced in fig. 4. None of these cells are denticulated. Capillaries are met with in the fibrous septa and engorged vessels in the condensed capsule, but the latter not to a very considerable extent.

In the "Schleim" cells in the middle layer the multiplication of cells is very active, the nuclei become large, sometimes they are single, at other times two or three are found in cells, as at *a* and *b*, each apparently becoming surrounded by separate and distinct cell walls of their own, and without doubt the result is the true endogenous formation of young cells. In some cells, and particularly, as before stated, in the part farther away from the capsule or septa, the nuclei of the cells are observed to be situated towards the outer wall of the cell, pushed aside as it were by the contents. In many cells a vacuole is seen to be beginning around the nucleus, or at the side opposite the nucleus, or even the centre of the cell. In the cells nearest the centre of the acinus the vacuolation is seen to be complete, and it takes place in almost all, if not all, the cells; the nuclei disappear, the vacuole become filled with altered sebum—the supposed colloid substance—and the concreted mass which fills the centre and mouth of the acinus is then mainly constituted by these cells, which are the peculiar looking large bodies known as *mollusc bodies*. The various stages of this process of vacuolation can readily be traced and are represented in Pl. XXIX, fig. 3.

These vacuolated cells are identical with the molluscum bodies as figured by Lukomsky and Boeck, but these observers have not appreciated the nature of the changes which have occurred to produce them. We think that the phenomena of molluscum may be regarded as exaggerations of normal phenomena, and that it is not a little important to recognise the nature and distinction of objects in reference to the activity of the nuclei on the one hand, and vacuolation on the other; the former leading to greatly increased endogenous growth of cells, the latter being connected with a

WOODCUT 16.

This woodcut is also taken from the central portion of Woodcut 14, highly magnified.

secretory or excretory act. Both are normal occurrences, but in molluscum they are unduly exhibited. Naturally the whole gland becomes hypertrophied by actual increase of the secreting area of each acinus and enormous distension by increase of contents. There is probably not any actual budding out of new acini.

It is of consequence to remember that these changes in nuclei and protoplasm are by no means peculiar to molluscum contagiosum. They have been observed by Kaposi and Simon, and others in condylomata. We have seen them in one form of lymphangiomata, in psoriasis, too, in slight degree, and elsewhere; and they occur generally in physiological gland activity, and in morbid changes in certain glands connected with undue excitement or more decidedly diseased

changes. The recent researches of Dr. Creighton[1] upon vacuolation of the mammary glands are very apposite in connection with these changes in molluscum contagiosum. He says, speaking of the secretion of milk:

"The type of the secretion is, however, the same as in the sebaceous glands, and that of the latter may be compared to the desquamation of the neighbouring epidermis. Now, in the case of the skin, the numerous layers of cells enable the process to be clearly seen. In the lowest layers there is a multiplication of cells by the ordinary hyperplastic process of division; a layer of cells that have begun their career in this manner as formative or plastic cells come in their turn to the surface, and undergo the horny transformation, after which they are cast off. There is here no special class of cells which are set apart for formative activity; the same cells are at one time in a formative stage and at another time in their functional stage, and the many layers of the cells enable us to see the two incidents of their life apart." These stages we hold are well marked in molluscum contagiosum, and it seems that the excessive formation of the cell contents here is simply an exaggeration of the normal processes. The retention of the contents is due no doubt in great measure to the increased secretory surface owing to the hyperplasia of the gland, whilst the ducts are unequal to the increased demand on them. But at the same time, *owing apparently to an alteration in the condition in the sebum*, the cells do not rupture and deliquesce as usual to form the fluid secretion, but form a concreted mass as in comedones, which gradually distends the gland cavities.

What the exact nature of the change is that occurs in the sebum we are not prepared to say. As the result of numerous experiments with reagents[2] on the expressed contents, we cannot obtain any

[1] 'On the Physiology and Pathology of the Breast,' 1878.

[2] *Glycerine* clears and defines the cuticular cells especially and their refractile contents, and shows up the extreme irregularity of their outline.

*Potash* defines the cells and, as Ferrier pointed out ('Brit. Med. Journ.,' 1872), clears them by saponifying the fat, so that much of the characteristic appearance of the *mollusc bodies* disappears, and they are only distinguished then from the *cuticular cells* by their shape.

*Iodine* simply stains slightly.

*Ether* dissolves more or less of the oil and refractile particles according to the time the cells are subjected to it, but does not get rid of all, which is similarly

evidence that it is of a *colloid* or other similar and well-ascertained nature. Indeed, we believe that contents of the mollusc bodies are still of an oily nature, but that there is some element or quality lacking, which ordinarily leads to the rupture of the cells and escape of the oil, as, indeed, may be effected by reagents.

There are still one or two important points connected with the appearance seen in the *expressed contents* of the tumours which should be mentioned. In these contents we observe mingled with the *mollusc bodies*, whose origin we have accounted for, a number of clear cellular bodies, uniform in size, and containing highly refractile granules, at once reminding us of cast-off *cuticular cells*. These cells are not noticed in section of the tumours, except in the main duct. They have an extremely irregular outline, and do not convey the idea that they are distended with thick substance like the mollusc bodies. Whilst many of them lie free, others, in considerable numbers, contain mollusc bodies, either completely or partially imbedded in them, and many of those lying free afford evidence, by showing cup-shaped moulds, that one *or more* mollusc bodies have been imbedded. This point is well illustrated in Lukomsky's figures, and, believing he found some vacuolated, he considered them cells undergoing the colloid degeneration, and that the mollusc bodies are really formed in them and finally drop out. It should be remembered, in relation to this point, that, in forcibly expressing the contents of a tumour, vacuolated cells in process of formation into mollusc bodies, as already described, may be met with, but they are smaller than the cells now specially under discussion. We believe that these cuticular-looking cells have no such intimate relations with the mollusc bodies, but that they are really of the nature of those of the stratum corneum (see exactly similar ones in the expressed contents of *comedo*), and that mollusc bodies become more or less completely imbedded in them by reason of the great mutual pressure of the collected masses. Moreover, it is rare to find a mollusc body anything like completely imbedded, and we have persuaded ourselves that this appearance, where met with, is generally due to the aspect under which the cell comes into view.

We have purposely limited our remarks in this paper to the

the case, however, when fatty particles in other affections are subjected to this reagent.

*Carmine and logwood* (especially the latter) stain the mollusc bodies intensely, and so differentiate markedly the *mollusc bodies* from the *cuticular cells*.

histology of molluscum contagiosum (Bateman), and avoided any discussion of the causation or contagiousness. But we may take the opportunity to add that in all investigations we have never detected any fungous elements in a fresh specimen. Fat granules and tiny oil globules occasionally offer considerable resemblances to fungi, as those experienced in the examination of hairs are aware, and we have seen the irregular edges of the cuticular cells in the expressed contents present an appearance which might easily be taken for mycelial threads. If specimens be left exposed for some hours, vibriones and torulæ in surprising numbers make their appearance, but, of course, bear no relation to the causation of the disease. To our minds, this affection is wholly unlike a parasitic disease, if only for one fact, that there are no signs of the peculiar irritation and destruction to which fungi invariably give rise.

We come to the conclusion, therefore, that molluscum contagiosum (Bateman) is undoubtedly a disease of the sebaceous glands, consisting in hyperplasia and hyperactivity of the whole gland-structure, which is exhibited not only by the increase in size of the individual acini and the formation of a little "tumour," but in the increased endogenous formation of gland-cells, their subsequent vacuolation, and, finally, the formation of the peculiar *mollusc bodies* by the alteration of the sebum, which forms and collects in these vacuoles and distends the enlarged cell.

---

## 8. *On a case of lymphangiectodes, with an account of the histology of the growth.*

By Tilbury Fox, M.D., and T. Colcott Fox, M.B.

Thomas W—, æt. 21, clerk, was admitted into University College Hospital, under the care of Dr. Tilbury Fox, on June 29th, 1878.

*Family history.*—His father was in the army, and died of Bright's disease at the age of thirty-five, having been invalided home from

the Mauritius on account of that disease. The mother, now aged thirty-seven, is naturally a delicate woman. She has had two sons, one of whom died when he was eight years of age from cholera, but he was unaffected by any cutaneous trouble. The mother has had also five miscarriages.

*Previous history.*—The patient was born in the Mauritius of English parents, and left that island at the age of six years for England. The young man had not suffered from any severe illnesses other than those incidental to childhood, apart from the affection about to be described.

He was born with two large unraised nævi, like port-wine stains (mothers' marks), on the left thigh, which are not of evident neurotic distribution, and which have persisted to the present time unchanged. At the age of six months the veins of the left calf began to be enlarged and become prominent. It was not, however, until he was two years old that the special condition to which we wish to call attention showed itself. This condition is also limited to the back of the left lower extremity and the anal region, all other parts of the body surface being healthy.

The mother says that when her son was two years old a number of little "warty" growths made their appearance on the skin of the left buttock, the back of the left knee, and about the left half of the peri-anal region, on quite distinct areas to those occupied by the nævi, and he was laid up with a kind of low fever, which left him much prostrated, and from which he did not fully recover for six months. The "warty" places felt tender for some time. She also states, and the patient corroborates her, that at the age of 7, 11, 15, and 19 respectively, he suffered from similar attacks, which, on each occasion, greatly debilitated him, and kept him unwell for three to six months. It would appear that on each of these occasions the skin trouble became worse, the "warty" prominences enlarging and becoming more and more vesicular in appearance. On two occasions, viz. when seven and eleven years old, an abscess formed in the middle line between the buttocks. The patient states that at the time of these attacks the left thigh looked as if it were burnt in places, and little bladders formed, which became pustular and gave exit to a discharge for a time. He does not seem to have been troubled with any inflammation or tenderness of the groin glands, nor has he noticed any red lines running up the thigh. From time to time tiny "warts" and nævoid spots have continued to appear

about the back of the limb, and the latter are at first vivid in colour, but gradually fade to a duller hue. These fresh appearances are not noticed by him to occur in connection with any marked febrile attacks.

*Present state.*—The patient is of slight build, of the middle height, and dark complexioned, with black hair and eyes. He has an excessively neurotic temperament, is very nervous, stutters markedly, and has a pallid aspect. He is very intelligent and well educated.

On the outer side of the left buttock, extending from a little above the trochanter to slightly below the lower fold of the nates, is a "port wine mark" about six inches long by one wide. Below this, and rather external to the middle line of the limb, is a second similar nævus, about the size of the patient's hand, reaching from the middle of the thigh to the back of the knee-joint; it varies in width from three inches to one inch. The three outer toes of this limb are also marked similarly, and there are enlarged port-wine coloured veins on the lower part of the scrotum. These conditions are congenital, and have not undergone any degenerative changes. There are further some enlarged veins at the back of the thigh, and more markedly at the back of the calf, whilst on the outer side of the latter is a very soft, reducible, bluish-looking round swelling, about an inch in its greatest diameter, which is clearly a venous cavern, and which fills again with blood after being emptied. When arose not clear, some time after birth. These venous conditions have no apparent connection with the "warty" growths.

Scattered over the back of the limb, viz. on the inner aspect of the middle third of the thigh, just above the popliteal space, especially over the head of the tibia, and below the back of the knee, are collections of little raised points, evidently of a blood vascular nature, the size of small pin's heads, looking like subcutaneous hæmorrhages. The patient says they are at first bright red, then purplish, and finally many grow pale, and even disappear. They do not become vesicular. This latter condition is, in parts, intimately mixed up with the vesicular growth to be now mentioned. But in addition, and, for the most part entirely distinct from these nævus conditions, are certain warty-looking growths. These are situated between the buttocks, extending from the base of the coccyx to the front of the anus; also, more externally, over the left gluteus maximus and about the lower fold of the left nates; and again, over the popliteal space. These growths are not continuous from one region to

another, but isolated into several irregular raised patches, and look at a distance like warty growths, but when more closely examined *like frog spawn* heaped together into masses. The earliest diseased areas are made up of a multitude of distinct, flattish, papulæ-like growths, aggregated into patches, and each item of the mass looks like a tiny, sessile, pale-pink wart (not bigger than a very small pin's head) with a vesicular centre. The older and larger patches are raised into irregular masses as much as half an inch above the surface. In some places these latter are semi-nævoid, or rather, mixed with tiny dilated venules. About the anus the growths are most irregular and elevated, and might, at first sight, be likened to moderately exuberant condylomata. In the popliteal space the warty-looking growths resemble those about the anus, but are smaller. They are in size about that of mulberries, some larger, some smaller. At the lower fold of the nates the prominent patch is the size of the palm of the hand, and elevated half an inch in the centre. When carefully examined these irregular masses appear to be formed by the gradual out-growth of the smaller points (this is confirmed by the patient's account), and apparently consist of minute cysts imbedded in a more or less fibrous matrix. The cysts may reach the size of a small pea, but a certain amount of inflammation then appears to attack the growths and rupture the cysts. *The growth is not affected by pressure as is the case with ordinary lymphatic varices.* If the vesicles either in the larger or in the minute isolated growths are punctured a clear watery fluid exudes. It is albuminous, and contains a few lymph corpuscles and some epithelial cells in a state of vacuolation with fatty contents, but there are no inflammatory products, and no blood elements. No enlarged glands can be detected about the limb, and the skin around the nævi and vesicular growths is quite healthy. It is very important to add that the left limb is hardly appreciably larger than the right, the slight increase that is noticeable in girth here and there being mostly due to the projecting veins and vesicles.

Lastly, it is worthy of notice that the lad has had two mild attacks of lymphatic inflammation of the foot in addition to the febrile attacks before mentioned. One attack was about a year ago and the second during his residence in the hospital. The left foot suddenly became diffusely swollen and red and painful over the instep, as if an abscess was threatening, but after the application of warm fomentations it as suddenly subsided.

[The patient was exhibited to the Society and also water-colour drawings of the diseased parts.]

*Minute anatomy.*—With the patient's consent, two portions of the diseased surface were removed for microscopical examination, the one where the vesicular and some slight nævoid appearances were intermingled in a moderately early stage, and the other from a locality where the warty and vesicular aspects were specially and apparently alone present *and in a very early stage.* The following were the results obtained by careful and detailed investigation of a large number of sections.

The disease may be said to consist, in the parts examined, in a slight hyperplasia of the skin textures generally, doubtless due to the marked over-supply of veins present and the specially great development of the lymphatic structures. The arteries are large and notably the veins, the latter dilating and branching very freely and forming a very loose plexiform nævoid structure in the more superficial layers of the corium, but they are always in the distinctly tubular-walled form. The juice or lymphatic tracts are well marked and increased, and lymphatic vessels, easily distinguished in places from the veins, can be traced dilating into varicosities and large spaces, and enlarging in the uppermost layers of the corium into cysts, which project on the surface of the skin as the vesicles. The glands and hairs are very slightly hypertrophied in places, but have undergone no important changes. The accompanying figure 1 gives a very good general idea of these changes.

To go more into detail the changes are these:

*The epidermis.* The *horny layer* is increased in amount, but unequally so. The cells are heaped together loosely, are congregated about the follicular orifices, and have not completely undergone the horny transformation and flattening out.

The *rete Malpighii* is increased in the total amount of its cell elements, but the interpapillary portions are very irregular and stretch down between and beside vesicles, in some instances, a long way. The lowest layer of rete cells is more or less pigmented and takes staining very deeply. Where the vesicles exist the surface is rendered very irregular, and their progressive enlargement and multiplication stretches out and distorts the rete layer and thins it excessively, in some parts to a single layer of cells.

*The corium. The papillæ* are, as a rule, enlarged, often enormously, owing to the development in them of the vesicles and the prolonga-

tion downwards of the interpapillary portions of the rete. Their blood supply is very abundant, and tortuous vessels can be seen resembling those in psoriasis. Capillaries can frequently be traced between the vesicle and the rete. The "juice tracks" are well marked unless obliterated by the pressure of the enlarging vesicle, and we believe we can trace lymphatic vessels coursing into the papillæ.

*The upper or sub-papillary layer* is the seat of a multitude of spaces of varying size and endless shape. Though mostly rounded or oval in outline there exist also cracks, and slits, and tubes of irregular calibre. They often contain disintegrated granular matter and some cells, like white blood-corpuscles; and have very delicate walls lined by endothelium. Indeed they often seem like simple cleavings in the tissue.

The changes in the lymphatics are clearly primary, and it is evident that these appearances are due to a system of branching varicose and dilated tubes, and that indeed they are lymphatics mixed up with nævoid capillaries and vessels. The cysts or vesicles in the papillæ are part of the same system and are lined by similar endothelium and have similar contents. The juice tracts in the superficial corium layers, which are extensively developed, are in intimate relation with these lymphatic vessels and ampullæ, and the latter seem often to open out of them. The finer lymphatic vessels are so extremely delicate that they are very difficult to trace and distinguish from the capillaries. The veins are greatly increased in number and calibre and ramify in every direction, but mostly course through the juice tracts. They have no direct connection with the system of tubes before described. Many are dilated and varicose, but no caverns are found, and their well-marked coats and contents clearly mark them as a rule from the lymphatics. The fibrous tissue is generally increased, but not otherwise altered. In the *deeper layers of the corium* the changes are similar, but very much less marked. The lymphatic vessels are with difficulty traced and the dilatations much less developed. The juice tracts are extensive, and coursing in them are large arteries and very large veins. The *fat* is not materially increased in amount.

*The hairs and sebaceous and sweat glands* are large, but the actual gland and hair structures do not seem to be materially concerned in

the disease. The peri-acinous juice tracts, however, are largely developed and communicate with those in the sub-papillary layer.

To sum up the minute anatomy the microscope discloses that the disease consists mainly in an overgrowth of the venous and lymphatic tissues. In some regions the former is most marked and shows on the surface as large "mothers' marks," or large varicose veins, and in other regions the latter predominates and undergoes excessive dilatation, forming on the free surface large vesicles as in "lymph scrotum," whilst in other parts still the two conditions are more or less intermingled.

*Comments.*—The case we now record must be allowed to possess considerable interest both from a clinical and pathological point of view. Though many cases (congenital and acquired) are on record in which lymphatic vesicles have developed in conjunction with venous nævi and with hypertrophy of the affected parts, there is no case we can find which tallies very nearly with this now described. In our case the condition of the veins was in a measure congenital, but the appearance of the lymphatic vesicles, whatever might have been the congenital condition of the lymph vessels, was an occurrence subsequent to birth. So slight an hypertrophy of the limb also is very unusual. It would occupy far too much time of the Society to enter into a comparison of the many cases on record, so we will conclude by simply drawing attention to an elaborate collation and discussion of all recorded (in any way similar) cases of lymphatic disease recently published by Dr. Busey ('Occlusion and Dilatation of Lymph Channels,' New York, 1878).

*October 15th*, 1878.

---

## 9. *Microscopical examination of some pustules removed from the back of the hand in a case of iodide of potassium eruption.*

By Dyce Duckworth, M.D., and Vincent Harris, M.D.

Two portions of skin, including pustules, were removed after death from the back of the hand of a patient who was shown to the Clinical Society by Dr. Duckworth in November, 1878,

('Clinical Society's Transactions,' 1878-79), suffering from iodide of potassium rash.

They were hardened in 2 per cent. solution of bichromate of potassium, and sections made from them in various directions were stained in logwood in the usual manner.

The pustules examined were about one line across.

It was found that they principally implicated the superficial layer of the cutis vera. The papillary layer at the affected part was flattened out, stretched, and even excavated, and contained a large number of small cells, and a quantity of newly formed fibrous tissue (fibro-nuclear layer).

Blood-vessels were seen to be very numerous in all the specimens, both in the neighbourhood of the sweat-glands and also in the part of the cutis vera; immediately beneath the pustule they were dilated, but empty of blood. The vessels passing into the depth of the corium in the centre of the pustule, and also those of the periphery, were seen to be ensheathed in streaks of exudation-corpuscles. No evidence of the rupture of any blood-vessel was to be obtained.

The sweat-glands seemed entirely unaffected, even in close proximity to the pustules, although in several places the blood-vessels were found affected, as before mentioned.

In one or two sections the ducts were seen opening upon the surface of the skin, close to the affected part.

No evidence was afforded of the implication of any hair-follicle.

In both pustules examined, there was distinct separation of the inflamed tissue from the subjacent healthy structures.

The epithelium bounding the pustules was found to be in a perfectly healthy condition.

From the above, it is inferred that the pustules are not of the nature of acne, but are due to a superficial localised dermatitis, resulting in cicatricial tissue. In the present case, however, no evident cause of such localisation (as, for example, rupture of blood-vessels) could be demonstrated. *May 20th*, 1879.

# IX. DISEASES, ETC., OF THE DUCTLESS GLANDS AND LYMPHATIC SYSTEM.

## 1. *Addison's disease with peculiar pigmentation.*

By D. J. Leech, M.D.

R. W—, æt. 43, unmarried, and until recently a resident in the County of Durham, was admitted into the Manchester Infirmary on the 10th of December, 1878.

In the early part of his life he worked in lead and coal mines, but for the last fifteen years as a stonemason. Many years ago he suffered from an attack of inflammation of the lungs, but with this exception had enjoyed uniformly good health until the present illness commenced. No history of syphilis could be obtained, nor had he met with any accident. He had been exposed to much hardship, and at one time drank beer to excess.

Two years ago he noticed brownish oval spots on the back of the middle and ring fingers of both hands. At this time he felt perfectly well. The spots coalesced and formed large brown patches; then new spots appeared near the margin of these patches, and soon increasing in size united with them. In this way the areas of discoloured surface gradually grew larger, the backs of the hands and the forearms and arms being successively affected. Next discoloration was observed on the abdomen, subsequently on the legs, and, lastly, on the face. The method of extension was similar in all these localities except the face.

Two months after the first appearance of brown spots on the hands the man's health began to fail, and in a very short time he became too weak to follow his employment. For some months before he entered the hospital he had not altered much in colour; he had noticed, however, that the brownness had become rather less marked on the body, legs, and hands, but his face had grown darker in tint.

In the first two years he had lost forty pounds in weight. During

the earlier part of his illness he had suffered much from pain in his back; six months prior to admission it had entirely disappeared, but it returned a few days before he came into hospital.

On admission the man weighed 139½ pounds, and looked worn and thin; he complained of pain across the loins, lassitude, and incapacity for exertion. He said he could walk half a mile, though with difficulty, but the slightest muscular effort tired him. The conjunctivæ were not of a pearly white colour, but rather wanting in clearness; the hair was of a dark brown colour.

The skin was dry and for the most part of a bronze-brown hue, varying in intensity, and here and there mottled with freckles or dark spots, but some parts of the body were perfectly free from coloration. In some places the transition from bronzed to untinted skin was gradual, but in many a distinct line of demarcation existed between the pigmented and non-pigmented parts. On the bronzed surfaces were seen islands of white skin, varying in size, with well defined outlines; and dark brown patches, with irregular but sharply cut edges, were scattered in many places on surfaces otherwise colour free. Most of the unbronzed skin appeared perfectly natural in colour, but in some parts, and especially on the hands, it seemed abnormally white. Some approach to symmetry was evident in the position of the pigmented and non-pigmented surfaces on the two sides of the body.

The face and neck were very deeply tinted, the temples being particularly dark. A line of still deeper colour extended across the forehead a little in front of the hair, and behind this the coloration rapidly faded away, extending only a short distance over the scalp.

The anterior part of each of the upper eyelids for about a quarter of an inch was deeply pigmented, but behind this that portion of the lids, which under ordinary conditions was not exposed to view owing to the eyes being deeply set, was natural in colour, though here and there small specks of pigment could be seen on the white ground. The line of demarcation between the portion of the lid coloured and that free from colour was sharply defined.

The bronzing of the neck became distinctly less marked about the line of the collar, shading off rapidly into a dirty brown tinge over the back, and into a light bronze tint over the chest, on which freckles were very distinct.

The nipple areolæ on both sides were intensely pigmented. A

little below the level of the nipples the colour began to increase again, and becoming deeper on the abdomen terminated on both sides over the ilium and outer part of the groin in a well-defined arched border, whilst over the pubes and inner part of the groin it passed on to the penis and scrotum, increasing still further in depth.

The upper and inner two thirds of the thighs were devoid of any trace of pigmentation. These colour-free portions were not quite symmetrically placed on each side of the body, though almost so; and that on the right was divided into two parts by a sharply-defined bridge of bronzed skin, which was absent on the left. The larger portions of the thighs were deeply bronzed; in front a well-defined and curved outline marked the boundary of coloration, but towards the back of the thigh and towards the loins the bronzing commenced imperceptibly.

The penis and scrotum were intensely black; round the prepuce the coloration ceased abruptly at the line where the skin became inverted.

The gluteal region was not very deeply pigmented, but round the anus the coloration was very dark. On each side of the anus was a well-defined patch, two inches long and one broad, absolutely devoid of pigmentation, and on the scrotum and buttock were seen several similar patches, varying in size from a split pea to a sixpence. There were, too, on the lightly tinted gluteal region several small roundish spots of deep bronze colour.

The deep bronzing of the thighs almost ceased at the level of the patella, abruptly on the inner side, gradually on the outer. The legs were only slightly tinted, what pigment there was being distributed unevenly.

The ankles and feet were curiously marked; much of the skin was free from pigment, some of it slightly pigmented, but here and there were dark broad strips of deeply bronzed skin. On the left side, for instance, one of these bands, about an inch broad, extended three inches from the heel over the tendo Achilles, and a second from the outer side of the foot to the external malleolus. The tips of the phalangeal joints were quite free from colour, but part of the dorsal surfaces were bronzed.

On the soles of the feet but little discoloration was seen, but near the heel and at the anterior part of the foot there were indications of slight pigmentary deposit in the rete.

The axillæ and shoulders were not much bronzed, but the anterior

axillary folds on both sides were much coloured. The arms were evenly bronzed, but here and there were patches of various size, free from colour. The tip of one olecranon was bronzed, the other was devoid of colour.

The forearms and hands were almost symmetrically marked; the dorsal surface of the forearms and the greater part of the back of the hands being deeply bronzed, whilst the ulnar and front part of the forearms and ulnar margin of hands were free from pigment, save that here and there, on parts of the hand and forearm, otherwise colour-free, were splashes of colour, looking almost as if they had been flirted from a brush.

The posterior surfaces of the metacarpo-phalangeal and phalangeal joints were free from colour. The dorsal surfaces of the anterior part of the hands and of the fingers were also for the most part free from colour, and even abnormally white, but with here and there a few small, oval, or irregular brown spots, varying in size. The palms of the hands were dark and horny, but not distinctly bronzed.

WOODCUT 17.

The woodcut shows the distribution of pigment on the left arm. The demarcation between the bronzed surface and the colour-free patches was quite as distinct in other parts of the body.

Neither the buccal mucous membranes nor the tongue presented

the slightest trace of pigmentation, nor were they very anæmic. The man suffered slightly from indigestion, but the appetite was moderately good. He did not vomit, nor had vomiting ever been a prominent symptom.

The pulse, under seventy, was small and very compressible. The heart sounds were weak, but otherwise natural. The blood was several times examined microscopically, but nothing abnormal was discovered. The red corpuscles were only counted on one occasion, and then found above the average in number. The relation of white to red corpuscles was not altered.

No physical indications of lung disease could be detected, nor did the man complain of dyspnœa. He looked as if he were mentally depressed, and his memory was rather defective, but complained of nothing save lassitude and pain in the lower part of the back. The fundus occuli was normal on both sides. No albumen or sugar could be found in the urine, of which the specific gravity averaged 1023.

For a week or two after coming into the infirmary, on the 10th of December, the man improved somewhat in strength; then a cough began to trouble him, and he lost his sleep and his appetite; the pain in the back remained severe.

On the 16th of January he weighed nearly five pounds less than at the date of his admission, and was weaker. After this he improved somewhat, the pain in the back left him, and he gained weight, though his cough continued, and the existence of slight dulness under the clavicles was noticed.

On the 3rd of February he was improving apparently, and weighed 140 pounds, but the next day he was seized with shivering and feverishness, and soon afterwards with diarrhœa and vomiting.

The febrile condition, vomiting, and purging continued for three or four days; then he began to breathe with difficulty, and his cough became more troublesome.

On the 9th his breathing was irregular; the vomiting had ceased, but the diarrhœa continued, and he had occasional pain in the bowels. He became slightly delirious at times.

The diarrhœa and pain in the bowels continued at intervals during the next five days, no treatment affording more than temporary relief. The tongue became dry; he wandered at intervals, then lapsed into a semiconscious state, and died on the 15th of February, 1879.

At the *post-mortem* examination forty-two hours after death the body presented a wasted appearance; the colour of the skin was somewhat lighter than during life; there was a fair amount of fatty covering over the abdominal muscles. On opening the abdomen the viscera were remarkably dark in colour, and this was not due to post-mortem change, for the weather being intensely cold decomposition had not commenced. After removing the intestines the left supra-renal capsule could be distinctly felt, but the right could not be found. The kidneys and all the tissues around them were most carefully removed. In taking out the aorta, solar plexus, and semilunar ganglia it was noticed that both the right great splanchnic nerve and the right semilunar ganglion were larger and darker coloured than usual. The solar plexus presented no unusual appearance, but it was not carefully dissected out. The mesenteric glands were not enlarged. The spleen was hard and large, weighing 11 oz.; the liver natural both in size and appearance. The stomach when opened seemed perfectly normal; the mucous membrane of the small intestine was somewhat congested, especially near its termination. For some distance above the cæcum the solitary glands were distinctly enlarged, the agminate glands less markedly so. Some of the larger solitary glands seemed softened at the apex. The walls of the heart were rather soft, but this organ was otherwise normal. The lungs were darker and firmer than usual at the apices, and puckered in places. On section, nodules of consolidation, evidently of old date, were found in them. The vertebræ were free from disease.

Dr. Morrison Watson kindly dissected out for me the kidneys and capsules from the tissues, with which they had been removed. The left capsule was found hard, nodulated, enlarged, and oval in shape, closely adherent to the kidney, and lower in position than usual, for it was placed internal to the upper part of this organ rather than above it. The right capsule was completely atrophied, a firm fibrous cord imbedded in adipose tissue representing what remained of it. On section, the left capsule presented an elongated oval surface, two inches long by three quarters of an inch wide. All characteristics of healthy structure were gone. The fibrous covering of the capsule seemed in some places thickened, in some places infiltrated with fat. The upper part of the capsule was soft, and resembled fatty tissue. The central part was firmer, and seemed made up of reddish material, radiating into the surrounding

tissue, and yellowish soft masses surrounded by fibrous tissue. The lowest part consists of a caseous-looking material in yellowish or brownish-white patches bounded by fibrous tissue.

My colleague, Dr. Dreschfeld, examined for me microscopically the capsule, ganglion, skin, and lung, and thus reports:

"The upper portion of the capsule consists almost entirely of fat cells with a little areolar tissue. The central part contains some glandular tissue, but this is found only in small, isolated, circular patches. Fully-formed fibrous tissue encircles masses of glandular structure, and sending inwards finer fibres separates them into several lobules, which are found to be further or less advanced in fatty degeneration. In the central part, too, is found a sparing quantity of fat cells, blood-vessels, and embryonic tissue, consisting chiefly of lymphoid and large cells, but in some parts undergoing caseation.

"The lowest part of the capsule, caseous looking to the naked eye, shows microscopically the structures observed in chronic caseous changes, such as are seen in the lung, viz. fatty detritus, lymphoid cells, adenoid tissue, and giant cells with many nuclei. The giant cells are usually found in the midst of an accumulation of smaller cells or in the midst of a small caseous centre. Blood-vessels are only sparingly found in this part of the capsule. Some degenerated gland structure is also met with.

"The right semilunar ganglion and the nerves passing into it and out of it are larger than ordinary. The consistence is very firm on section; the nerve-fibres are found intact for the most part; in a few places the structure is broken up.

"The several bundles of nerve-fibres are separated by areolar and adipose tissue to a greater extent than in health. The chief changes are found in the ganglion cells, by far the larger portion of these being slightly shrunk, their nuclei being very indistinct, sometimes quite absent, and their contents consisting of masses of irregular highly-pigmented granules (Pl. XXVII, fig. 4 *b*). Round many of the ganglion cells fibroid tissue is seen.

"The *skin* presents the usual appearance seen when it is bronzed, cells containing pigment granules occupying the lowest layer of the rete mucosum. The pigment cells are like ordinary epithelial cells; their nuclei can be no longer distinguished; their contents consist of fine pigment granules. Pigment cannot be found in any part of the epidermis or subcutaneous tissue, and it was entirely absent in

## DESCRIPTION OF PLATE XXVII.

Figs. 1 and 2 illustrate Dr. Goodhart's case of the Supra-renal Capsule affected with early Addison's Disease. (Page 486.) From drawings by Dr. Goodhart.

Fig 1.—Section of the supra-renal capsule, life size. The transverse line limits the diseased part.

*a.* Capsule thickened.
*b.* Cortex mostly healthy.
*c.* Caseous change.

Fig. 2.—Section of the diseased part of supra-renal.

*a, a.* Cells of the gland columns, most of them healthy. In some places small and too numerous, as if they were proliferating and taking part in the disease.
*b.* Early caseous change between the cell columns.
*c, c.* Large vein full of blood-corpuscles.
*d.* Small cell growth separating the cell column.

Figs. 3 and 4 illustrate Dr. D. J. Leech's paper on Addison's Disease with peculiar pigmentation. (Page 478.) From drawings by Dr. Young.

FIG. 3. Section of skin taken from the arm at the junction of bronzed and colour-free skin, showing abrupt disappearance of pigment in cells of rete.

FIG. 4. Section of right semilunar ganglion.

*a.* Splanchnic nerve.
*b.* Pigmented ganglion cells.
*c.* Fibroid tissue.

Fig. 2.




Fig. 1.

Fig. 3.



Fig. 4.

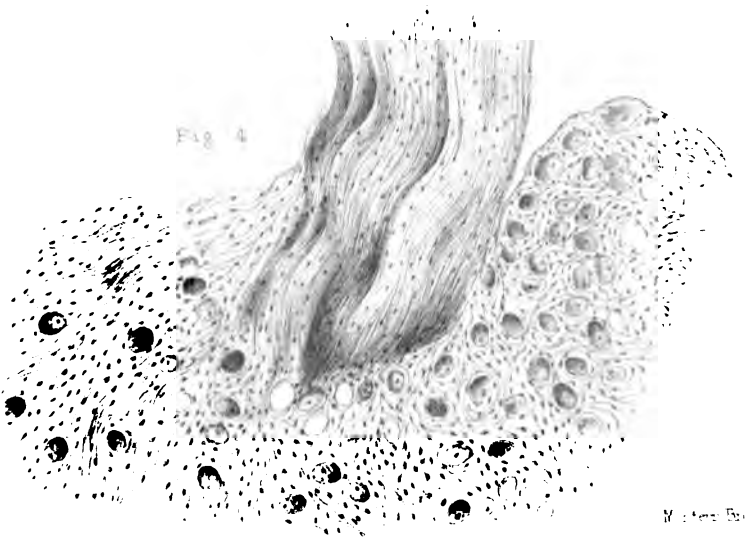

Mintern lith.

Mintern Bros. imp.

sections of the colourless patches. The pigmentation of the rete ceases absolutely at the well-defined edge where the bronzing ceases.[1]

"In the lungs the hard nodules in both apices, some parts of which are firm and highly pigmented and others soft and friable, show the lesions characteristic of chronic tuberculosis, viz. fatty detritus surrounded by embryonic fibrous tissue in which lymphoid elements and giant cells are found, with marked peribronchial, periarterial, and perialveolar thickening. The alveoli outside the nodules were found filled with pneumonic material.

"In the *intestines* nothing abnormal except intertubular thickening and atrophy of some gland cells is found. There is no pigmentation."

The form of pigmentation in this case is extremely rare. In Addison's disease gradual transition from pigmented to non-pigmented surfaces has been almost universally found, but here not only was the transition abrupt but in many places the bronzing was darkest just round the colourless patches, making the resemblance to leucoderma very complete. A case somewhat similar to my own has recently been recorded by Dr. M'Call Anderson.

The mode in which the colour of the skin became altered is involved in some obscurity. The patient himself asserted that, though the bronzed portions of the skin spread at the expense of the natural skin, yet in certain parts, such as the hands, the bronzed colour had been replaced by white skin. This may have occurred in a few places, but I could find no evidence leading me to believe that the whole of the patches observed scattered around the pigmented portions of the skin had appeared subsequent to a general discoloration. *April 15th*, 1879.

[1] Pl. XXVII, fig. 3, was drawn from a section of the skin of the arm taken from one of the oval patches seen in the woodcut at the junction of the bronzed with the uncoloured skin.

## 2. *Two cases of early disease of the supra-renal capsules (Addison's disease).*

By James F. Goodhart, M.D.

Case 1.—*Early Addison's disease, with disease of the sacrum and lumbo-sacral joint. Double psoas abscess and amyloid viscera.*—A man, æt. 36, was admitted into Guy's Hospital under the care of Mr. Durham. Five months before admission he had felt stiffness down the inner side of the left thigh, and a month after noticed a swelling in the left groin. He was admitted with a discharging sinus in the groins and thigh, and dead bone was found about the sacrum. He died, gradually exhausted, without any special symptoms.

On *post-mortem* examination I found a dark man, with dark hair and beard, but no trace of any abnormal pigmentation of the skin, gums, or tongue. He was much emaciated, and there was extensive disease of the sacrum and lumbo-sacral articulation, and a psoas abscess extended upwards to the diaphragm upon each side.

The left supra-renal capsule was as follows:—The greater part of it was healthy, but at one end it was hard and cartilaginous, and upon section the cortical and medullary parts were replaced by a grey, translucent, and, in parts, vascular material, which was undergoing minute caseous changes. There was no suppuration in the immediate neighbourhood, and the nerves all looked normal. The other capsule was healthy; both were a little too adherent to the surrounding textures.

The kidneys weighed 15 oz.; they were lardaceous, and affected by tubal and interstitial changes. The liver and spleen were lardaceous.

The histological features are best seen by reference to the figures (Pl. XXVII, figs. 1 and 2) and the corresponding references; but it may be briefly stated that the point of the case lies in this, that the microscopical examination rather suggests that the cells of the "cell columns" are themselves taking part in the formation of the cell growth characteristic of the disease. The normal gland columns are easily distinguishable, and amongst them is a fibro-cellular growth of new formation.

CASE 2.—*Tubercle of left supra-renal capsule, cerebellum, and pons varolii.*—A boy, æt. 5, was admitted under the care of Dr. Moxon, and subsequently came under Dr. Frederick Taylor. There were no symptoms of Addison's disease. The capsules are described by Dr. Hilton Fagge, by whom the inspection was made, as follows: The right was bulky; its cortex of a bright yellow colour. The left still had its cocked-hat form, and was firm. Parts of its cortex showed the yellow colour on the surfaces, but other parts were of a greyish-white colour and somewhat granular. This was found on section to be caused by a hard material, greyer than the usual medulla of the organ. This in some places infiltrated the whole thickness of the supra-renal capsule, while in others it formed rounded nodules in the medulla, over which a thin layer of cortical substance was spread. It appeared to be of quite recent formation, and not as yet to have commenced to caseate.

The microscopical appearances are very similar to those described in Case 1. . A small cell growth infiltrates the cell columns and runs between them, leading to their atrophy and entire replacement by the new growth.

The two cases illustrate two groups of cases with which Addison's disease is associated, but which are, *perhaps*, essentially different in origin, viz. spinal caries and tubercle. Addison's disease has not infrequently been coexistent with spinal disease, and one obvious suggestion from such an occurrence is that a local inflammation in the neighbourhood has led to a local inflammation of the capsules, quite unconnected with any constitutional state, such as tuberculosis is held to be an evidence of. But it is noteworthy that in this particular case, although such a thing is possible, there is no distinct evidence of the spread of the disease from the outside; on the contrary, it appears to have commenced within the capsule.

The cases, if they be, and one of them certainly was, tubercular, have a histological interest in relation to the origin of tubercle, which has been said to start in adenoid tissue, in connective tissue, in the endothelial lining of vessels, &c. It appears to me probable that it is by no means so exclusive in its seat of election as has been supposed. I believe tubercle starts in many tissues—in one of these cases by an overgrowth of the cells of the supra-renal body—and I beg to express my dissent from its one and only origin in adenoid tissue, a view which appears to me in many cases to necessitate the active use of imagination. *November 5th*, 1878.

### 3. *Elephantiasis arabum.*

By Sir J. Fayrer, M.D., F.R.S., and D'Arcy Power, B.A.

I am indebted to my friend and former colleague, Mr. S. Bowen Partridge, Professor of Surgery in the Medical College of Calcutta, for the two specimens of this disease that I have the honour of submitting to the Society this evening. He describes them as follows:

"One, the smaller one, is a very typical specimen of the lymph scrotum. I removed it on 19th June, 1878, from a Hindoo beggar, æt. 25, named Gunga Vishnu. He was born in Hyderabad, but had resided in Calcutta for the last ten years. The tumour was of three years' growth, during which time he had irregular attacks of fever once or twice a month. During each febrile attack there was copious discharge of sometimes milky, sometimes sero-sanguinolent fluid, and he had got into the habit of giving himself relief by a rough sort of tapping, namely, pinching off a bit of distended integument with his nail and encouraging the fluid by pressure. The tumour after removal weighed 11 ounces. I operated *bloodlessly*, and he is making a good recovery, in fact, is nearly well."

"The other was an ordinary case (of elephantiasis), which I removed from a Brahmin, æt. 30, resident of Calcutta, a broker. It was of two years' growth, and weighed after removal 3 pounds 4 ounces. I operated *bloodlessly*, and he also is doing well.

"I examined the fluid in the lymphoid case on one occasion, not very thoroughly, however, and did not find any filariæ."

These, therefore, are examples of the two forms of elephantiasis that are so frequently seen in some parts of India,[1] notably in Bengal and on the sea coast where the sea air and the malaria unite.

I think they may be interesting to the Pathological Society if only as a supplement to the late communications on lymphoid disease, and I am enabled through the aid of Mr. D'Arcy Power to

[1] I find, for example, that in twelve years, from 1859 to 1871, I operated on 193 cases, of which 158 recovered and 35, or 18·2 per cent., were fatal. The tumours varied in weight from a few ounces to upwards of 100 lbs.

illustrate the following remarks by an excellent series of microscopical preparations of sections of the structure of these abnormal growths.

The recent investigations of Lewis in Calcutta, Manson in China, and Bancroft in Australia, throw a new light on the etiology of elephantiasis, and seem to show that it is frequently associated with, if not caused by, hæmatozoa—Filaria sanguinis hominis.

Dr. Bancroft has detected the parent worm of this embryo, which was originally discovered by Wucherer in Bahia in 1866, by Lewis in Calcutta in 1869, in chylous urine, and most important of all by Lewis in 1872 in the blood of persons suffering from chyluria, elephantiasis, and other diseases; whilst Manson in China made the remarkable discovery that the mosquito acts as intermediary host, and therefore probably as a propagator of the parasite, depositing it in water after undergoing developmental changes in the insect tissues. It is then transferred to man, where becoming sexually mature, it sheds its embryo in swarms into the blood to become the source, it is said, of elephantiasis, and possibly several other morbid conditions.

Elephantiasis is a non-contagious disease, endemic in certain localities, generally intertropical, and near the sea coast, characterised by recurrence of febrile paroxysms attended by great suffering, inflammation, and progressive hypertrophy of the integument and areolar tissue, chiefly of the extremities and genital organs, and occasionally by swelling of the lymphatic glands, enlargement and dilatation of the lymphatics, in some cases by the coexistence of chyluria and the presence in the blood of certain hæmatozoa; the hypertrophy of the integument resulting in enormous enlargements of the extremities, scrotum or labia, accompanied by an albuminous deposit in the cells of the areolar tissue, and by degeneration of the muscular and osseous tissues.

*Natural history.*—It is endemic in India, the Malayan peninsula, China, Egypt, Arabia, the West Indies, parts of America, chiefly within the influence of the sea air—and probably, sporadically, all over the globe, perhaps excepting in extreme northern and southern regions. It has been observed that removal from the endemic area checks, whilst return there reproduces the disease.

It is totally distinct from elephantiasis græcorum (true leprosy), with which, the same generic term being applied to both, it is still sometimes confounded: as shown by V. Richards they are occa-

sionally coexistent. Of 636 cases recorded by him in Orissa forty individuals, or 6·29 per cent., were thus affected.

The ordinary form in which the disease presents itself is hypertrophy of the integument and areolar tissue of some part of the trunk or limbs, and notably of the legs and genital organs. The skin becomes enormously thickened by hypertrophy of all the fibrous elements of its structure, attended by the deposit of a quantity of albuminous fluid in the cells of the areolar tissue. The papillæ are prominent and much increased in size. The integument is formed into hard masses or folds, with a rugose condition of the surface, not unlike the appearance of an elephant's leg. The feet and toes are sometimes almost hidden, and the scrotum or labia form enormous outgrowths, often attaining great weight in the male, accompanied by large hydroceles. From the male they have been removed weighing upwards of 100 lbs.

The appearance of such a tumour, where the disease has its chief seat in the integuments of the penis, is well shown in fig. 1, or of the scrotum, in fig. 2. In some cases these are the seat of a dilated and turgid condition of the lymphatic vessels, which during the periods of vascular excitement, when the febrile attacks occur, give way and discharge a chyle-like fluid; in others the surface assumes a temporarily herpetic condition which weeps an acrid and offensive serous exudation.

These outgrowths are not to be regarded merely from their local point of interest. They are the result of certain climatic influences whose exact nature is not at present determined; though, considering the geographical range of the area where the disease is endemic, it seems probable that, whatever other cause may be at work, the so-called malarious influences play an important part in its production.

Lewis's discovery of hæmatozoa in the blood of those affected with chyluria, coupled with the fact that such subjects are also frequently, if not always, affected by elephantiasis with its febrile paroxysms, hypertrophied integument, and lymphatic disturbance, is not only very suggestive of a community of origin of these morbid conditions, hitherto regarded as different, but also tend to suggest an explanation of other imperfectly understood forms of tropical disease and cachexiæ.

It may be well, whilst recognising that hypertrophy of the integument may occur in other conditions, to limit the term

elephantiasis as now used, to the constitutional form of the disease that occurs within certain endemic areas, and which is manifested by paroxysmal febrile attacks, accompanied by a disturbed condition of the lymphatic system, chyluria, hæmatozoa, and progressive inflammatory hypertrophy of some portion of the tegumentary system.

Cases occasionally present themselves in which hypertrophy of the integument alone, or in combination with a greatly disturbed and dilated state of the lymphatics and glands, with or without a certain amount of constitutional disturbance, occurs; but although it may be so far correct to call such cases elephantiasis, it should be borne in mind that they are more local in character than the disease in malarious intertropical countries.

Elephantiasis affects both sexes, and all ages and conditions of life. No race is exempt, but it is much more frequent, relatively, in the dark than in the fair races, and it appears that men suffer in a much larger proportion than women.

Waring says that of 945 cases observed in Travancore, 716 were males, or 75·76 per cent.; whilst 229 were females, or 24·34 per cent., or about 3½ males to one female. It must be remembered that prejudices against submitting females to treatment or examination exists strongly in the East, and may in some measure account for the disproportion.

It is most common in adult and middle life; and comparatively rarely begins in a very young child or an aged person; the period of life between twenty and forty being that most liable to suffer.

Some authorities deny that it is hereditary. Richards says he is persuaded that hereditary predisposition is frequently a leading cause of its manifestation. Of 236 persons 193, or 73 per cent., had one or both parents affected.

It not unfrequently occurs without much obvious injury to, or disturbance of, the general health during the intervals between the febrile attacks, which in some cases are few and slight. The appetite, spirits, and strength are good, the functions are all normally performed, and the only inconvenience is that due to the size and weight of the outgrowth. On the other hand, it is frequently quite the reverse; the rapidly recurring febrile attacks, the pain, exhaustion, suffering, and visceral complications, induce a state of cachexia and debility sometimes so serious as to render even surgical interference impracticable. Withal, it should be

stated that hepatic and splenic enlargements do not as a rule result from the persistence of the elephantoid fever alone, though not unfrequently, as a more direct result of malarious poisoning, they seriously complicate the evils of the sufferer's condition. It should be noted that albuminuria, as well as chyluria, is occasionally present.

In some cases, after the outgrowth has attained a certain bulk, it ceases to grow altogether, or increases slowly and insidiously without febrile disturbance, and in such cases the general health remains good, but there is generally a tendency to recurrence of the fever once or twice a month; when the parts affected become tense, hot, painful, and swollen, and often discharges a serous or lymph-like fluid, which may be acrid and offensive. Some tumours, on the other hand, are very slightly, if at all, so affected, and remain perfectly dry.

In all cases, however, some growth goes on, and even when, as occasionally happens, fever has ceased to recur, there may be a gradual, but slow and painless increase of the hypertrophy. The greatest variety and uncertainty characterise the duration and progress of the growth; sometimes it is very rapid, at others it is slow, with intermissions of activity and indolence of development.

According to Richards, the average duration of the disease, as deduced from the observation of 636 cases, was 11½ years; he notes that the earliest age was nine years, whilst the latest at which he observed it was eighty years.

It appears from this that the disease has little influence in shortening the duration of life. Richards further remarks that the period at which it first appears is by no means limited, though it principally attacks persons between the ages of fifteen and forty years, and that he had never known an infant to be attacked: experience, however, proves that young infants are not exempt, though, in them, it is rare.

In certain cases there is some reason to believe that it interferes with the procreative powers, not only mechanically, but by the cachexia and debility induced. Men, however, who have long been incapacitated, have become fathers after removal of the tumour, and there seems no ground for concluding that the presence of the disease elsewhere than in the genitals, unless it be accompanied by exhaustion and debility, causes failure of the generative powers in

either sex; though it would seem that some women have a tendency to miscarry when suffering from elephantiasis.

Various causes are assigned for the disease in the regions where it prevails. Air, water, food, and, as it is frequent near the sea-coast, eating fish, have been credited with it. The proximity of certain forms of vegetation, the geological formation of the soil, have each or all been regarded as predisposing and determining causes. Climate and locality, combined with poor living, are doubtless predisposing causes; and it is probable that (as Lewis has suggested), like other disturbances of the lymphatic system, it may be found to be intimately associated with the existence of hæmatozoa.

Lewis describes the *Filaria sanguinis hominis* as a minute embryo, often exceedingly difficult to detect, but sometimes found in great numbers in the blood of persons suffering from chyluria and elephantiasis. It is enclosed in a tubular sheath, within which it elongates or shortens itself; the average diameter is about that of a blood-corpuscle, and its average length about forty-six times that of its greatest width, *i.e.* its diameter is about $\frac{1}{3500}$, and its length $\frac{1}{75}$ of an inch. It varies, however, slightly in size. It approximates more closely to *Filaria medinensis* embryo than to that of *Trichina spiralis*, though much smaller than either, especially in breadth.

It is impossible not to recognise the important bearing that these researches may have on the causation and pathology of elephantiasis, chyluria, and disordered conditions of the lymphatic system.

Further investigation may probably not only confirm this view of their origin, but throw fresh light on the subject, and perhaps show that the disease is endemic in certain districts where this particular filaria is indigenous and the mosquito most abounds, because the blood of the indigenous residents is fitted to be its habitat.

Dr. A. Webb believed that in some cases the disease had a syphilitic origin. This view, however, has not met with much support, nor is it founded on any very convincing evidence. As to its malarious origin it may be said that it is not always most prevalent where paludal fevers are most severe, and that though frequently complicated by elephantoid fever is not identical with malarious fever. It seems probable that, as in the case of dysentery, goitre, and other forms of disease, its occurrence may be in some way determined by the causes that give rise to intermittent fever,

such as we are wont, failing a more precise definition, to call malarious.[1]

The subjects of this elephantoid fever, at least in India, are very strongly impressed with the belief that it is due to lunar influences and have the firmest belief that the paroxysms are synchronous with and dependent on the changes of the moon; as it undoubtedly does frequently happen that the febrile accessions and excitement of the local disease take place coincidently with lunar changes, it is not strange that a notion which is of such universal acceptance among certain classes, as the influence of the moon on vital action, whether in disease or health, should find favour where there is such apparent ground for believing in it. Such is the case, however, and one might as well try to persuade the sufferer that he had no fever at all, as that it was not so caused.

No race is exempt from the disease, but, whatever may be the explanation, the white suffer less than the dark races. It does occur occasionally, though very rarely, in the pure European in India, more frequently in those of mixed descent; most frequently in the native, and possibly by the operations of culex acting as an intermediary host in the genetic cycle of the filaria. It will generally be found that where it occurs in persons of apparently European parentage, there is a mixture, however slight, of dark blood. Waring says that the lower animals are not exempt; and even birds have been known to suffer from a swelling of one or both legs, which, though unaccompanied by fever, was in all respects similar to the hypertrophy of elephantiasis.

The disease occurs in different forms and in various degrees of severity. In some the attacks of fever are of repeated recurrence, from intervals of a fortnight to that of months; the increase of

[1] Dr. Bancroft, in Australia, suggested, and Dr. Manson, in China, discovered, that the mosquito is the intermediary host in which the embryo filaria undergoes development, and is by it transferred to the water, whence it finds its way into the body of man. This being the case, it is probable that the mosquito may play an all-important part in the dissemination of the disease; and such, Dr. Manson believes, is the case. Indeed, he appears to think that the geographical distribution of the disease is coincident with that of culex.

Whilst attaching the greatest importance to Manson's views, which receive support, both in fact and analogy, I am not yet prepared to admit that elephantiasis is so closely dependent on this insect. Further observation may suggest some modification of these views—may prove that the disease is not altogether dependent for its spread on this insect.

hypertrophy in the limbs or genital organs being rapid. In others the febrile paroxysms are irregular, of slight intensity, and the growth of the hypertrophy slow and less pronounced.

Long intervals of quiescence, varied by occasional increase of swelling, with very little manifestation of a febrile tendency, occasionally occur; in certain cases there is continuous increase, but unattended by any obvious disturbance of the general health.

The hypertrophy in most cases appears to be simply an increase in the natural elements of the part, the blood-vessels and lymphatics sharing in the growth. In some the lymphatics and lymph spaces are most concerned, giving rise to a condition described as "lymph varix" by V. Carter, and by me as nævoid elephantiasis. It has also been well described since by Manson, Macleod, and others, when it is frequently associated with chyluria, in which the appearance of a soft and fluctuating swelling, which when punctured gives issue to a white or pinkish fluid, very closely resembling chyle, is presented. The lymphatic glands also share in the enlargement. In other respects the progress of this is like that of the ordinary form of the disease. In the majority of cases of scrotal elephantiasis, one of the earliest symptoms is the formation of hydrocele.

In certain cases (chiefly occurring in Europe) the increase in size of the lymphatics occurs without more marked disturbance than occasional fits of excitement in the part, accompanied by increase of temperature and discharge of chyle-like fluid from the distended vessels; the loss of which, when profuse, causes considerable exhaustion. These cases, though perhaps not identical with, are very closely allied to, true elephantiasis.

The relation of filaria to this and other diseases requires further investigation, and it seems probable that we may obtain important results in regard to its etiology.

But little impression has as yet been made by constitutional treatment. Remedies, though useful during the febrile paroxysms, in moderating their severity and the excess of local action, have little power in preventing recurrence or in checking the onward progress of the disease.

A due combination of local and constitutional remedies, with rest, improved diet, and improved hygienic conditions, may, and no doubt do, materially control the progress of the disease and relieve suffering. No remedy, however, is so potent as change of climate. This, if effected in the earliest stages, may completely

arrest the disease, and perhaps, but this is doubtful, even disperse any incipient structural change that may have occurred.

This has occasionally been observed in rare cases in Europeans, that returning to Europe, they have, after a time, lost the disease, and almost, if not entirely, any hypertrophic changes that may have occurred. Natives of India improve, and the disease often ceases to progress, if they leave the endemic area during the early stages and reside in other and drier localities. Such a change, for example, as from Calcutta to Delhi, in the case of a native of Bengal, is often effective in arresting, if not in curing, the disease. It is constantly observed, however, that after the hypertrophic condition had become advanced, the paroxysms of fever are still liable to recur, even when the climate is changed, though they do so with less violence, showing that the tumour itself acts in some way as the source of a dyscrasia that perpetuates the recurrence of the febrile state, which does not cease altogether until after it has been removed. This, where the disease affects the genital organs, is possible. When the limbs are the seat of the disease, it is not so.

The onset of elephantiasis is frequently violent and attended with great suffering. There is high fever, intense pain in the lumbar region, the groin, the spermatic cords and testes, which become much congested and swollen, whilst acute hydroceles form. This is often attended with sympathetic vomiting, nausea, rapid and erythematous swelling of the external parts; and if the extremities be attacked, the swelling is often very tense and painful, accompanied by much effusion into the areolar tissue. The surface of the integument in much inflamed, and sometimes discharges a serous ichor or chyle-like fluid, according to the extent to which the lymphatics are involved in the particular case. There is much constitutional disturbance, increase of temperature, and often depressing nausea and vomiting when the cords are implicated, when the great tension and swelling of the cords is apt to dilate the abdominal rings so widely, that when it subsides after recovery, the patient is liable to suffer from hernia through the widened inguinal passages.

During the fever and excitement, salines and aperients, with local soothing applications, fomentations, and often opiates, are necessary to relieve pain and give rest. When this stage has passed, quinine is useful, and if anæmia exist it should be combined with iron, which may be all the more necessary if other indications of malarial cachexia be present. Many remedies have been recommended,

but there is no reason to believe that beyond their general action as tonics, antipyretics or febrifuges, they have any special effect on the disease. Richards thinks that he has seen benefit result from confining certain natives of Orissa to a milk diet; but it is to be feared that even this simple form of treament will not always succeed.

It is impossible to over-estimate the importance and value of change of climate; in the case of Europeans it should be to Europe; in that of natives of the country to a district where the disease does not prevail—away from damp and malaria as much as possible; further, all measures should be resorted to that can tend to improve the general health and the condition of impoverished blood which no doubt exists.

Surgical treatment, where the hypertrophy is advanced, is often most successful in relieving the sufferer not only of the tumour, but also of the fever, which ceases when the outgrowth is removed; it would seem that the outgrowth acts as a source of dyscrasia, keeping up the recurrence of fever as long as it remains.

Tumours of the genital organs, sometimes of enormous size, are now removed with complete success, and, considering the formidable character of the operation and the magnitude of the mass—which has occasionally exceedeed 100 pounds in the male—with comparatively small mortality.

The removal of a scrotal tumour is effected by incisions along the course of the cords and the dorsum penis. The cord, testicles, and penis are turned out by a few touches of the knife, and then reflected and held up on the abdomen, while the mass of the tumour is rapidly swept away by a few bold incisions in the perinæum. The removal should not occupy more than two and a half to three and a half minutes, unless any complication arise from adhesion of the testes to cicatrices, such as are often caused by the application of the moxa, a favourite native method of treating the disease in the early stages.

The numerous venous and arterial bleeding points should then be arrested by ligature or torsion, and the surface of the wound dressed with simple oiled lint and antiseptic dressing.

No attempt should be made to preserve flaps of integument either for the penis or testes. It is unnecessary, and almost certain to be followed by recurrence of the disease. The process of cicatrisation goes on rapidly, and in from two to four months all is closed in by

cicatrix tissue, which gradually perfects itself, and has no liability to become the seat of a recurrence of the disease.

Before commencing the operation, especially in the case of a large scrotal tumour, it is well to drain it of blood by placing the patient on his back, elevating the tumour on the abdomen for an hour or so before the operation, during which time pressure by a bandage (a modification of Esmarch's) may be used, and cold (ice) applied. During the operation the application of a whip-cord ligature drawn tightly round the neck of the tumour prevents loss of blood, and it is very important that not more blood than can possibly be helped should be lost from the numerous bleeding points which are seldom controlled by fewer than twenty to thirty ligatures, often more. The shock of the removal of so large a mass is often severe. The patient should in such cases be left on the table until reaction has thoroughly set in, and care taken that at or soon after this period, no hæmorrhage should occur from small vessels which during the operation may have escaped notice.

In thin persons the abdominal tourniquet may be applied.

The process of healing occupies from two to four months, but when complete is very satisfactory. The genital organs are covered and protected, and the relief to the sufferer, who had for years been encumbered with a tumour of perhaps thirty to sixty pounds weight, may be imagined! The procreative powers are also frequently restored. Of 193 cases of scrotal elephantiasis operated on in the Medical College Hospital in Calcutta between 1859 and 1871, 158 recovered, thirty-five, or 18·2 per cent., proved fatal, the causes of death being pyæmia, embolism (cardiac and pulmonary plugging), diarrhœa, tetanus, shock.

The tumours removed varied in weight from a few ounces or two or three pounds to 110 lbs. The ages of the patients ranged from 20 to 50 years.

It has been suggested that elephantiasis of the limbs may be treated by ligature of the main artery. It is difficult to understand on what physiological principle this mere temporary starvation of the limb should have any efficacy in permanently removing the local expression of a constitutional disease. That it might temporarily ameliorate it, there is no reason to doubt, but the same effect could be produced by pressure on the limb or its artery, or by continuance in the recumbent posture; and such, indeed, has been the result of experience in certain cases in India. Ligature of the femoral

artery, which was necessarily accompanied by protracted rest in bed, the application of bandages, and the general diminution in size that would follow such an ordeal, were followed by a considerable reduction in the size of the leg. The improvement, however, was temporary, and the disease returned to its original dimensions on the patient's resuming the usual mode of life.

*Report upon two specimens of scrotal tumour.*—The specimens immediately after removal had been placed in a tin canister containing strong alcohol. The tin was hermetically sealed, and was forwarded to Europe. The tumours were transferred directly after the tin had been opened into strong alcohol. A small portion of each, situated at the upper part of the scrotum 1·25 inches behind the raphæ, immediately below the projection of skin which had been reflected from the urethra, was then cut off and placed in absolute alcohol for twenty-four hours. A portion of the tissue which had been thus hardened was then embedded in a mixture of paraffin and oil, and was cut in the usual way with a razor wetted with spirit. The sections were afterwards stained in picro-carmine, when the muscles and epithelial structures were stained yellow by the picric acid, whilst the nuclei became carmine coloured, as well as in hæmatoxylin—anilin blue or anilin violet. The specimens were then put through the ordinary dehydrating and clarifying processes, and were finally mounted in Canada balsam. The sections were made in transverse and longitudinal directions.

After preparation by the method described the sections were examined microscopically with one of Hartnack's microscopes, the combinations used being the ocular No. 4 and the objectives 4 and 7. In the microscopical examination the points to which the attention was most carefully directed were the epidermis, the rete Malpighii, the distribution of pigment, the subcutaneous tissue, the hair-follicles, the glands, the blood-vessels, the lymphatics, and various foreign bodies. The nerves were not seen to any great extent, owing in part, no doubt, to the method by which the tissue was preserved.

Taking the points to be noticed *seriatim*, we find that—

The epidermis is not modified, at least noticeably; it is not materially thickened, yet it is thicker than in the case of the second tumour. The cells are less flattened, and their nuclei are somewhat more perceptible, whilst the line of demarcation between the

epidermis and the rete Malpighii is sometimes less well defined than in the smaller tumour, the epidermis thus appearing to run more gradually into the rete.

The rete Malpighii is of considerable thickness, whilst its constituent cells are distinct and well-marked, the nuclei being seen with the greatest clearness, otherwise it does not appear to have undergone material change.

The pigment is evenly diffused throughout the vertical row of cells which constitute the lowest layer of the rete, extending slightly into the upper part of the subcutaneous tissue.

The subcutaneous tissue is very greatly thickened; it contains a very large amount of unstriped muscular tissue, arranged in narrow bands vertically as well as transversely. The subcutaneous tissue is chiefly composed of areolar tissue intermixed with elastic fibres; numerous free nuclei appear to be present in the neighbourhood of the muscular bundles and in the upper layers. The subcutaneous tissue is very compact, and appears to be entirely devoid of fat.

The hair-follicles and hairs appear to be quite normal.

The glands are the sebaceous and sudoriparous.

The sebaceous glands are small, but are otherwise normal.

The sweat glands are large and somewhat complex; they appear to be situated at different heights in the tissue, some being nearer whilst others are further from the surface. The sweat ducts are therefore of varying lengths, but are of small diameter.

The blood-vessels are very numerous, and are of large size.

The lymphatic channels are fairly numerous, some of them being of considerable diameter.

In the smaller of the two tumours the lymphoid form.

The epidermis is not modified, at least to any great extent; it forms only a thin layer, consisting of stratified cells, whose boundaries cannot be distinguished.

The rete Malpighii is of very considerable thickness, but whether this is due to hypertrophy or is the normal condition of the part in the skin of an Indian it is impossible to state without examination of the unaffected skin from the same part in a healthy subject, and this we regret that we have been unable to obtain.

The pigment does not appear to be either increased or lessened. It appears to be deposited in some parts between the epidermis and the rete Malpighii, as well as in the deeper layers of the latter.

The subcutaneous tissue is throughout very greatly hyper-

trophied. It is chiefly composed of areolar or ordinary white fibrous tissue intermixed with a little elastic tissue. Unstriped muscular tissue appears to be developed in some parts to a very much larger extent than in others; as a rule, however, it is only sparingly present. In many of the sections there is an exceedingly large development of lymphoid tissue. Fat is also present in considerable quantity.

The hair-follicles are considerably enlarged and thickened, the enlargement being chiefly due to hypertrophy of the root sheath.

The sebaceous glands are greatly hypertrophied, and are filled with a lymphoid tissue.

The sudoriparous are likewise largely developed, not only in regard to the diameter of the tube, but also to the complexity of its coils. That this deviation from the ordinary type is not normal may be seen by comparing it with the condition of the glands in the larger tumour.

The blood-vessels are large, and may in many cases be seen to be filled with corpuscles.

The lymph channels are large.

Small, highly refracting, angular bodies, which stain deeply, are seen in several of the sections; they are situated in the subcutaneous tissue. The importance and relations of these bodies we are at a loss to comprehend. The sections have been most carefully and systematically examined for *Filaria sanguinis hominis*, of which, however, we were at first unable to find any trace either in the adult or larval form. In this task, one of no small labour, we must acknowledge the great courtesy and kindness of Dr. Cobbold, who assisted us in the most liberal and painstaking manner, and from whose observations we have derived the greatest benefit. Upon a more careful examination of the tissues we have come to the conclusion that certain nuclear-looking bodies may possibly represent sections of the filariæ. These nuclei, which have been already mentioned, were at first supposed to belong either to lymph corpuscles, to the large flat cells present in subcutaneous tissue, or to unstriped muscle. On further investigation, however, they are found to be small semicircular bodies, not unlike portions of a red blood-corpuscle, and of about the same diameter; they stain deeply, and are enclosed in a sheath, which is apparently structureless in transverse section. They are present in enormous numbers, and are found chiefly in the larger tumour. They appear also to be

present in the smaller tumour. In one of the blood-vessels they are also present, though they are not seen there with great distinctness.

The tissue of the scrotum is somewhat difficult to examine, first, on account of its having been preserved wholly and for somewhat too long a period in strong spirit; and, secondly, because there are, at least, five structures which might be taken to resemble a filaria in transverse section. Thus, the small hair-follicles when the section of the hair has dropped out; the ducts of the sebaceous glands, more particularly when they are filled with secretion; the ducts of some of the sweat glands; sections of the contracted blood-vessels; and, lastly, sections of the lymphatics, might all be readily mistaken for such a structure.

HENRY POWER,
D'ARCY POWER.

*February 8th*, 1879.

*Postscript to Sir Joseph Fayrer's and Mr. D'Arcy Power's paper on elephantiasis.*

*Comparison of the normal with the pathological appearances.*—Since the above paper was written Sir Joseph Fayrer has succeeded in obtaining the scrota from two Indians unaffected with elephantiasis. These specimens were preserved and treated in exactly the same manner as those previously described.

Microscopical examination showed that, in the case of one scrotum, a large quantity of fat was present in the deeper part of the corium and subcutaneous tissue. To such an extent was this developed that the fat occupied 0·247 millimètre when the entire thickness of the skin was 0·38 millimètre. As is well known this appearance is exceedingly unusual, inasmuch as the skin of the scrotum and penis in common with that covering certain other parts of the body is generally stated to be wholly destitute of fat. The occurrence of fat has already been noticed in the case of the ordinary form of elephantiasis. It must, however, in all probability be regarded as normal, and indicating a diseased but still common condition, since two subjects out of four exhibited this change, whilst in the other two specimens no trace of fat cells could be detected.

The epidermis in the diseased scrota does not appear to have undergone any alteration, for in both the normal and pathological conditions it is represented by a thin layer of stratified cells.

The rete Malpighii seems to be less developed, the individual cells being less distinct and less numerous in the healthy tissue. In elephantiasis, therefore, this portion of the integument becomes slightly hypertrophied.

The pigment layer in the two diseased specimens is lighter in colour than in the normal forms, but this change may be due to an individual peculiarity.

The corium in the healthy tissue is composed superficially of a close network of connective tissue in the ordinary way, with accompanying muscle-fibres and elastic tissue. It contains the hair-follicles and sweat glands. The deeper portion is much less dense, and contains a large proportion of involuntary muscle-fibre. The papillæ of the corium are of large size, and are frequently compound.

The hair-follicles are not unusually large in the normal scrotum, and they are situated between the superficial and deep layers of the corium, or in the fat when this is present. In the unhealthy tissue, however, the hair-follicles have undergone a marked increase in size, due chiefly to an increased development of the outer root sheath.

The sebaceous glands are neither prominent nor well marked in the healthy skin, and it is in this point that the greatest difference appears between the sections of the healthy tissue and those made from the one affected with the ordinary form of elephantiasis. In the latter case not only are the glands themselves of enormous size, but the component cells are very large and distinctly defined.

The sweat glands in every section are large and very complex.

The blood-vessels in the healthy tissue are fairly numerous, but they are developed to a very much larger extent in the diseased specimens. The same remark will apply to the lymphatics.

The bundles of involuntary muscular fibres are present in considerable quantity, though not in such numbers as in the cases of elephantiasis.

Nuclei are also present in large numbers, especially in the tissue immediately below the rete Malpighii, but they are generally elongated or angular, and appear to belong to the connective tissue and muscle. In no case so far as has been observed do they present the peculiar semicircular appearance which was noticed in some of those belonging to the diseased tissue.

## 4. *On the condition of the lymphatics in Eastern leprosy.*

By George Hoggan, M.B.

In the twenty-seventh volume of the 'Pathological Transactions' Dr. Vandyke Carter contributes a paper intended to show that the lymphatics of the skin are specially involved in elephantiasis græcorum, and he emphasizes this opinion in the twenty-eighth volume to the extent of attributing similar importance to the lymphatic sheaths of the nerves. If I understand him rightly, his general contention is that leprosy is zymotic in its nature, and that masses of micrococci or zooglœa are specially to be found in the neighbourhood of the lymphatic vessels and lymphatic sheaths of the nerves, appearing there as clusters of pigmented granules, varying from light brown to black in colour.

In this communication I am in a manner forced to refer specially to those observations of Dr. Carter from the fact (as stated by himself) that they are noteworthy by their "standing alone;" and if I subsequently differ from him in all essential particulars, we differ only in our interpretation of facts admirably pourtrayed by Dr. Carter, but which improved modes of preparation enable me to read and understand in a sense opposed to that arrived at by him.

On last Good Friday a leper died, whose case is probably familiar to most of the skin specialists in the United Kingdom, to all of whom he had applied for relief at some period or other of his long illness of fifteen years, his case having been published at different times by different observers; and I present a photograph of him as he appeared ten years ago, when he entered St. John's Hospital under my colleague, Mr. Milton.

T. S. C— was born in India; his parents were Irish, and his mother suckled him herself. He had been vaccinated in India, but was unable to trace from whom the lymph had been derived, and at the age of ten years he had been sent to be educated in this country.

Four years later he had an eruption which was treated as scarlatina, and six months afterwards he began to experience tingling sensation in the tips of the ring and middle fingers of the

right hand, which soon ceased, but left the skin of those parts anæsthetic. It will be unnecessary for me to go further into his case than merely to state that for fifteen years the disease made steady progress, and when he died sight and smell had entirely gone, voice and cutaneous sensibility had almost completely disappeared, while taste and hearing were already much affected. His nose had entirely disappeared, sight had failed through opacity of the cornea, not apparently from retinal derangement, and his countenance presented the horrible disfigurements characteristic of the last stages of the disease.

For several months before his death he had been under my continual personal supervision, and before he died he gave orders that I should be called at once and his body placed at my disposal, so that I might have an opportunity of applying the silver, gold and osmic-acid methods of preparation upon the still living tissues.

Thanks to his kindness and forethought, I am now able to bring before you some of the results I have obtained, as far as they concern the lymphatic system in general and Dr. Carter's conclusions in particular.

Under the microscope I have arranged specimens, and alongside of them drawings of the appearances they present illustrating the conclusions I have arrived at. In the silver and gold preparations of the plexus of lymphatic vessels as seen from the outer surface of the skin, it will be noticed that the silver lines marking the boundaries of the crenated endothelium, which alone forms the wall of the lymphatic vessels in the skin (fig. 2, pl. xxvi), are everywhere well defined, showing that, as far as the component cells are concerned, the lymphatic walls are absolutely healthy.

Under a low power, embracing a large portion of the plexus of lymphatics in one field (fig. 1), certain notable deviations from the normal conditions in the general appearance and arrangement of the lymphatic vessels are to be detected. In the first place the lymphatics are considerably more dilated than usual, especially at the valvular pouches (fig. 2), some of which appear enormously distended as they lie immediately under the epidermis, the cause of which I shall subsequently endeavour to explain. This appearance will be clearly recognised in one specimen under the microscope, where a slice was made horizontally from the surface of the skin, that was intended to pass immediately below the plane of the lower cells of the epidermis. At one point, however, owing to a slight

depression of the surface, the knife has left a thin layer of epidermic cells still attached to the dermis; these cells have sufficed to protect the underlying dermic tissue, as well as the red colour of the injection filling the blood-vessels, from the action of the silver and gold solutions.

At the very edge of that patch of epidermic cells some largely dilated lymphatics are to be seen, looking like great bags or reservoirs on the course of the lymphatic vessels which pass horizontally from them, and seem to be of the ordinary calibre where they join the dilated portion.

As the crenated endothelium characteristic of the lymphatics is very well marked, no one, I think, can doubt that these are lymphatics, and that this is a condition in which they are seldom seen. Another preparation by a different method, where the tissues were first fixed by osmic acid and then stained by picrocarmine (fig. 4), shows one of those sinuses collapsed; the nuclei of the endothelium lining it appear to be absolutely healthy. It will also be noticed that the lymphatic plexus is much denser than normal, the vessels being closer together (fig. 1), so as to form smaller meshes.

This is probably due to the fact that the skin has become extremely thin, and consequently the lymphatics which run horizontally through the whole thickness of the skin have become, so to speak, compressed into one plane, presenting the appearance of a greater number of lymphatic vessels than usual to a given extent of surface, while in reality the number of vessels is normal, but appearing in a thinner stratum.

This is just what we should expect from their manner of development, for I have shown elsewhere[1] that in the fœtus the lymphatics are all developed on one plane on the hypodermic surface of the skin, but afterwards become separated into different planes in the whole thickness of the skin by the interposition of gelatine, or, as it is called, white fibrous tissue. It is, therefore, only reasonable to suppose that when, as in leprosy, the gelatinous tissue becomes absorbed, the lymphatics will naturally return nearly into the one plane.

It is probably this same thinning of the skin which causes the great dilatation of the lymphatics at the valvular pouches. If we can suppose a lymphatic vessel passing obliquely through a certain thickness of skin, we may reasonably hold that if

[1] 'Journal de l'Anatomie,' 1879, page 1.

that thickness becomes diminished to one half its extent by absorption of the skin, the lymphatic vessel occupying that thickness would also require to accommodate itself to the diminished extent, and this would naturally take place by the walls of the lymphatic settling down, so to speak, to the level of the valvular attachments, where the vessel is strongest and most rigid, and the regurgitating pressure of the lymph also greatest.

Such a movement would give an appearance exactly coinciding with the appearance seen under the microscope.

Owing to the destruction of the individual nerve-fibres in some parts in leprosy, the blood-vessels become greatly dilated. The same cause may also lead to general dilatation of the lymphatics, although such special cases as I have noticed are evidently due to the cause I have assigned to them. I may further mention here that, while that skin was only of half the usual thickness, it was highly elastic, and when cut horizontally with a sharp knife it gave a sensation like that of slicing cheese, being in this entirely different from the tough, and generally with difficulty sliced normal skin.

While I believe that this is the first time that the lymphatics of the skin have been shown in Eastern leprosy, I must also give my opinion that what Dr. Carter has described as lymphatics are only veins, for the lymphatics of the skin have no such course as that assigned to them by Dr. Carter in his drawing, which, on the other hand, corresponds with the course of the cutaneous veins. In fact, I believe that it is impossible with the process he used to show the course of the lymphatics.

Again, in one of the silver preparations and drawings I exhibit, it will be observed (fig. 2) that, while the irregular blotches which mark the spaces containing the cells pathognomonic of leprosy, generally cover the whole surface, at certain points close to the walls of the lymphatics they are entirely absent (fig. 2, *b*).

This is a point of special interest as opposed to Dr. Carter's conclusions, for it will be shown afterwards that these cells are identical with the leprous elements—the micrococci or zooglœa which he describes. If we examine carefully we shall find that these cells are generally found close to the walls of the blood-vessels, or, properly speaking, the veins, and when they appear to surround the lymphatics, it will be found that this is due to the presence of the blood-vessels in the same locality. But to

see this clearly we must have recourse to other methods of preparation. If we make a section through a lately invaded portion of the skin, either in the early or last stages of leprosy, we find that immediately external to the veins (fig. 3), but only there, a great number of cells become deposited in the position usually occupied by the wandering cells.

I submit a preparation and drawing under a high power of such a deposit of cells around a vein (fig. 3), and this, I believe, is the true interpretation of the cells shown in Dr. Carter's drawing. It must, however, be clearly understood that it is only in an early stage of invasion that this can be well seen; for afterwards the various layers join together by absorption of the intervening gelatinous tissue, forming the great masses of leprous tissue shown by Neumann and others in their drawings of skin affected in leprosy. These cells seem to be first deposited in thin laminæ concentric with the vessel, so that if the razor cuts parallel on either side of the vessel, the laminæ become easily disassociated, and it is from such a lamina that the cells seen in the preparation are shown under a high power. In an early stage these cells have a yellowish tint in the white races, but probably they would be darker in the dark races. Osmic acid does not blacken them readily as it blackens fat-cells, as you may have remarked under the microscope. In one preparation, where they are shown in the mass, and which has been stained by indigo (fig. 3), it will be seen that, while the gelatinous tissue of the skin is but slightly tinted of a light lavender colour, the leprous cells lying around the vein appear of a dark green colour, caused by the combination of their own yellow tint with the blue colour of the indigo-staining fluid. This peculiarity cannot be seen if the section has been stained by picro-carmine, as you may satisfy yourselves in the preparation under the microscope.

But what are those cells which become deposited outside the veins? I have little hesitation in pronouncing them to be altered wandering cells, resembling those which, when about to develop into fat cells, first grow a larger amount of protoplasma round their nuclei than they possess in the active wandering condition. It is in this protoplasm that the first globules of oil make their appearance; and, indeed, this is exactly the condition of several of the cells in the group I have drawn. Some of these cells show oil globules developing within them, and a large globule in one of them has been blackened by the osmic acid injected to fix the tissues.

Now why do these wandering cells congregate and remain outside the walls of the veins? Have they passed out of these vessels, and are they unable to proceed further, or have they returned to them, but are unable to pierce the wall, and thus remain outside and close to the nutrition supply? These are questions I am unable to answer, but I am strongly of opinion that these cells are destitute of the ordinary amount of vitality which enables them to move about, and that this want of vitality is increased by the destruction of the nerves of the part.

It is known that section of the sciatic nerve, in studying nerve degeneration in the living animal, results always in ulceration of the limb and generally death of the animal; and although I have never examined such a limb microscopically, I venture to predict that, when examined, it will be found that a local traumatic leprosy has been unwittingly produced, the ulceration in which is due to the same cause.[1] As those cells continue to accumulate in the immediate neighbourhood of the blood-vessels, they finally extend as dense masses up to the lower surface of the epidermis, from which they appear to cut off the supply of nutrition, causing the epidermis at such spots to break down as if by a localised gangrene, and thus it is that the ulcers characteristic of leprosy appear to be produced.

As regards Dr. Carter's supposition that the lymphatic sheaths of the nerves are similarly affected to his supposed lymphatics, I can only state that I have given long and minute study to this question of lymphatic sheaths of nerves where the results appeared to me to be satisfactory, and I have come to the conclusion that such lymphatic sheaths of the nerves are purely hypothetical, and have no existence in fact, and that, therefore, it is unnecessary for

[1] In the 'Archives de Physiologie' for 1875 Jean Tarchanoff publishes an account of certain experiments on frogs which are very appropriate to this question. He found that when frogs were curarised (p. 44) "there was a well-pronounced emigration of white cells through the walls of the veins and capillaries into the tissues." He further proved that this was due to paralysis of the vaso-motor system by curare, by means of the following experiment:—"If we destroy (he says, p. 45) the cerebro-spinal axis of a frog we find identically the same picture under the microscope in the mesentery, tongue," &c. Hence it appears that both after experimental destruction of the nerve-centres and during the temporary paralysis produced by curare a condition is brought about similar to what I have shown in leprosy.

me to enter further into the question of their importance in eastern leprosy.

Finally, as the result of my investigations into the lymphatics and other systems in leprosy, I feel bound to state that, although leprosy causes changes in the appearance of the lymphatics, such as I have described, these changes are merely secondary, and the lymphatics themselves have no share in the causation of the disease, which must be sought for in other tissues.

*November 5th*, 1878.

*Report of the Committee on Morbid Growths on Dr. Hoggan's microscopical specimens of the skin in leprosy.*—We have carefully examined Dr. Hoggan's specimens of leprous skin, which exhibit well most of the changes described by him. The lymphatics appear to be abundant and to be of larger calibre than normal, especially at the valvular pouches. They do not contain masses of micrococci, nor do we see any canals plugged with micrococcus masses. The chief feature in the disease appears to consist in abundance of cell elements in the cutis and in the subcutaneous tissue. These cells lie not only around the veins but in the interstices of the fibrous tissue around the sweat glands in the vicinity of veins and occasionally of small arteries.

JAMES F. GOODHART,
HENRY T. BUTLIN.

*December 16th*, 1878.

# X. SPECIAL COMMUNICATIONS.

## 1. *Address on lardaceous disease in reference to its anatomical seats and pathological relations.*

By W. Howship Dickinson, M.D.

Mr. President and Gentlemen,—In responding to the request with which I have been honoured, I will be mindful, as in duty bound, of the injunction with which our late excellent President accompanied it—that I should be brief; and that I may be so I will keep as closely as may be to the text which has been chosen for me—

*Lardaceous disease in reference to its anatomical distribution and pathological relations.*

I shall not occupy the time of the Society by historical retrospect, but will proceed at once to the topic upon which I have to invite discussion. Lardaceous disease—to use the term which the Pathological Society has authorised—appears to have remained, until within the memory of many who must be here to-night—I will not say idle, for it is difficult to suppose that it was not always active in connection with the diseases which produce it now, it is difficult to suppose that it was not always the contemporary of destructive lung disease, of empyema, of discharging lesions of bone, and of syphilis—but at least undetected. It accomplished its morbid purpose in secresy, until, during the last half century, its deeds have been gradually brought to light.

The disorder consists in a widely pervading tissue change, which is shared by the blood-vessels, and the distribution of which, external to the vessels, is regulated by their course, as if they were the channels as well as the subjects of the morbid influence. I need not hesitate to assert—what probably few will question—that

the special change is of the nature of an addition; an infiltration or penetration of the tissues by a material, foreign to their healthy nature, which the blood-vessels bring to them. That the blood-vessels bring it is an assumption—lardaceous matter has not as yet been found in the blood—but it is an assumption which is warranted by all the circumstances of the disease. We became acquainted with the infiltrating material first in the tissues: in this situation it has been the subject of many conjectures. Rokitansky, among the first by whom it was recognised as an infiltration common to many organs, regarded it as albuminous. Meckel looked upon it as allied to cholesterine; and his views found a later and an able supporter within these walls in the person of Dr. Montgomery. Virchow considered it to be akin to starch or cellulose, as if the human body in its deterioration approached the functions of a vegetable, and by the authority of his great name imposed upon it the designation of "amyloid." But succeeding observers, among whom an honorable place must be assigned to our own countrymen, Pavy and Odling, subjected the affected organs to ultimate analysis, showed that their proportion of nitrogen was that which belongs to the protein bodies, and that whatever amyloid characters the morbid substance might have, it had not the amyloid composition. Upon these observations, abundantly confirmed as they were by other chemists, both the amyloid and cholesterine views fell into desuetude as provisional rather than permanent.

The nitrogenous nature of the deposit being established I will pass to distinctions which have been more recently claimed as dividing it from other nitrogenous substances. The marked dead-house character of the formation, the outward and visible sign by which it is known after death, is its reaction with iodine. It absorbs this eagerly, and may be made to assume almost the full tint of the reagent. Whether by a judicious adaptation of sulphuric acid with iodine a blue can be obtained is a point of little importance now that the amyloid theory is extinct. I have seen black but not blue. Some observers, to judge by their pictures, have found a blue which is nothing else than heavenly. If any such tint is ever produced it is probably due to plates of cholesterine, which, together with the fatty products, are often found in connection—though not necessary connection—with the special change.

The ready and delicate test which iodine affords for the new material has supplied a stepping-stone to another point, namely,

the action of the alkalies upon it. However marked the iodine reaction, it for ever vanishes upon the exposure of the tissue to even a very dilute solution of potash or soda, and this before there has resulted any material injury even to the microscopic structure of the organ. That which gives the reaction has been dissolved out or modified, and its place knows it no more. But it can be, as Dr. Marcet showed, recovered from the solution by the action of an acid, again to display its characteristic reaction and present itself, if I may use the expression, as a disease disembodied. There is a point about the iodine reaction which is full of practical suggestion. The property of displaying the "amyloid" reaction, or, in other words, of combining with iodine, is associated with the condition of acidity. Fibrine can be made to display it by solution in hydrochloric acid, and to lose it again by being allowed to absorb potash. With these indications the question at once presents itself: Is this material, which is so specially soluble in alkali, which behaves with iodine, and I may add, with other reagents too, so much as if it had been modified by an acid,—is this material in any definite manner wanting in alkali so as at once to account for its separation in a solid state, and distinguish it from the normal constituents of the blood, which in organic composition it so nearly resembles? The answer is that the new material as compared with healthy tissue is wanting in potash, and that to a significant extent. I need not quote details, which have been already made public; the deficiency has been ascertained with regard to both liver and spleen: in the liver, from a healthy average of 0·209 to 0·169 in 100 parts, or, according to Dr. Dupré, from one of 0·283 to one of 0·151 (a diminution, according to Dr. Dupré, of nearly one half); in the spleen, from a healthy average of 0·311 to one under disease of 0·196. Together with this alteration are others, less striking, in the mineral constituents of the new material; the phosphoric acid is diminished, but not proportionately to the potash; the chloride of sodium variably increased, the earthy matters rather remarkably so. This last fact furnishes an important distinction between two conditions, which have some points of resemblance, and were for some time held to be identical—lardaceous enlargement and rickety enlargement. Under rickets the lime salts are diminished in the viscera as in the bones. In the lardaceous condition they are increased.

Points of resemblance exist, as I have said, between the larda-

ceous deposit and fibrine which has been artificially deprived of its alkali. These relate not only to its iodine reaction, but to the insolubility of its iodine compound in water, its solubility in alkali, and ultimate composition. Dr. Marcet made this resemblance, to which attention had been drawn, part of the subject of an investigation which he undertook at the request of this Society. An acid solution of fibrine is precipitated by iodine; an acid solution of albumen—making use in this instance of acetic acid—is similarly precipitated, whereas ordinary albumen is not. These are significant facts in relation to the possible origin of the morbid deposit and its characteristic reaction.

To put the chemical part of the question in a form suited for discussion, I would say that lardaceous disease consists in a general deposition of the fibrine or albumen of the blood modified by loss of alkali or gain of acid.

The part of the subject which presents itself in juxtaposition with the nature of the disease is its mode of production. It has been vaguely attributed to *cachexia*, including in this condition tubercle, cancer, bone disease, syphilis, rheumatism, and drunkenness. The unsatisfying nature of this view, however, suggested a further sifting of the states to which it had been traced. Two fundamental conditions remain as the general, if not the invariable, causes of the disease—the one is suppuration, the other is syphilis. Suppuration is the intermediary by which tubercle, cancer, caries, dysentery, empyema, pyelitis, and bed sores act in producing the disease. That the blood should be the worse for the loss of corpuscles, and with them of potash, which pus involves, and that tangible results should follow from the impairment, may well be supposed.

I will not trouble the Society with details which have already been made public, but I may briefly state that of eighty-three cases of lardaceous disease collected from the St. George's *post-mortem* books seventy-three were in connection either with protracted suppuration or syphilis, leaving but ten not ostensibly accounted for by one of these agencies. Suppuration occurred in sixty-two cases; syphilis was recognised in eighteen.

I am glad here to mention the name of an honoured, though no longer an active, member of our Society, Dr. George Budd, who, so long ago as 1857—though I have only recently happened to have come across his observations—gave a prominent place to continued

suppuration among various causes to which he ascribed the "scrofulous liver," the name under which he described the state which we now know as lardaceous.

As to the other definite cause of the disease (syphilis), we cannot as yet even guess at its mode of operation, excepting very generally as involving injury to nutrition in a variety of ways.

Passing from the general characters and causes of the change, to its distribution in the body, I come to a part of the subject the knowledge of which will, I have no doubt, be permanently added to by the members of this Society. It is not necessary that I should do more than briefly indicate its ordinary anatomy. The iodine reaction which is characteristic of the change is found earliest and oftenest in minute vessels, which in most instances are arterial, though perhaps the Malpighian capillary of the kidney is more early and more often affected than any other vascular structure. The straight arterioles of the cones usually participate soon after or even simultaneously. While upon the subject of the kidney I may refer to a fact which is strongly declared in its pathology: the lardaceous condition is often succeeded by fibrosis, as if the special infiltration acted as an irritant to the interstitial tissue.

Though it often happens that the change is to be found in the kidney, and not elsewhere, yet there would appear to be considerable variety in the place of its beginning. It early affects the liver, involving the terminal branches of the hepatic artery, and infiltrating the cells of the middle zone of the lobule. The spleen shares in the change, its Malpighian bodies assuming under the change, as is well known, the appearance of boiled grains of sago. The mucous membrane of the small bowel frequently displays the reaction upon the blood-vessels of the villi; it is found less often in the stomach, and less often still in the large bowel. The change is frequent in the lymphatic glands, which occasionally present recognisable, though not great, enlargement. And it has been found in the vessels of the skin and of the pancreas; and Dr. Grainger Stewart tells us that he has recognised it in the muscular fibres of the uterus. No doubt this list might be indefinitely extended, since there are, perhaps, few parts of the body which are free from the possibility of being attacked. The reaction sometimes occurs, and that most intensely, in the substance of intracranial tumours—probably of syphilitic origin—as upon formations of the same kind elsewhere. Not only is the alteration found as stated in the smaller arteries,

but I have known it to be strongly declared upon the lining of the aorta, upon fibrinous vegetations in connection with diseased valves, and upon a fibrinous block in the spleen found in the same subject. I have referred to the occasional infiltration of epithelial cells. I have still to mention that the reaction is sometimes, though rarely, graphically displayed in the substance of fibrinous casts in cases of lardaceous disease of the kidney. For many particulars which are wanted in this necessarily brief outline, I must appeal to the wide experience of the Society.

But I have said enough to show that the lardaceous reaction, and I may go so far as to say the lardaceous material, is to be found not only in many organs, but in many tissues and morbid products—not actually in the blood, but in fibrine which has been separated from it during life in the shape of vegetations and casts; in vascular structures of all kinds, arterial, capillary, and venous, all necessarily in immediate contact with the blood; and in epithelial cells, which are but one step removed from it. Thus the blood would appear to be the origin, if not the seat, of the change; and its nature to be a permeation by something which the blood supplies. In short, the change is an infiltration—not a degeneration, as it has by some been regarded. It is not so much a change of existing tissues as an addition to them. This is a point which, among many others, awaits the verdict of the Society. Other points on which the opinion of the Society is needed will suggest themselves. I would ask, supposing the existence of a new material to have been established, whether it is wholly new, and in all respects different from the normal constituents of the body, or whether it is, as I have ventured to infer, but a modification of something—either the albumen or the fibrine. I am inclined to believe it is of the latter—normally existing in the blood. What is the significance of the deficiency of potash in the new material? Has this any relation to its solidity and separation? Is the loss of potash in pus the process which links together, as cause and effect, the discharge and the deposit; or is the result produced by mere de-alkalisation; or are both these necessary results of suppuration insignificant or of minor importance?

Then what are the causes of the disease? Suppuration and syphilis are beyond question: they may act together or separately; but does the disease ever ensue from tubercle or bone disease in the absence both of suppuration and syphilis? I have not been able to

satisfy myself that it does so; but the Society is wiser not only far than myself, but than any individual member of it. Are any causes of the disorder to be identified beyond suppuration and syphilis? Shall we still talk of its origin in cachexia, or limit its causes more definitely? It comes on readily within the tropics: is this for any further reason than that suppuration is here profuse, and soldiers and sailors prone to contract specific disease? Of the cases of which the cause is not ascertained, are any spontaneous, or is lardaceous disease but the attendant and follower of other morbid states?

I hope I have not kept the Society too long. I am well aware that whatever interest may belong to this discussion—and I anticipate that it will result in additions to our knowledge and adjustments of our mode of thought which shall be of more than temporary value—the interest will belong to the communications which have yet to be made, and in no respect to my stale reiteration of a twice-told tale.

Dr. F. Charlewood Turner.—In the *post-mortem* records of the London Hospital, from the commencement of the year 1875 up to the present time, fifty-eight cases, in which lardaceous degeneration of one or more of the organs was observed, have been recorded amongst about 2100 inspections.

The records of these cases have been examined—(1) In regard to the anatomical distribution of the disease in the different viscera found affected; and (2) in regard to the pathological condition, in association with which this degeneration has been here found to occur.

1. As regards the former point, a simple enumeration of the organs found affected in the several cases shows that in the fifty-eight cases the spleen was affected forty-eight times, the liver thirty times, the kidney fifteen times, and the intestines ten times. The spleen alone was found affected in no fewer than twenty-three cases.

In the ten cases in which the spleen was not found affected the liver was found affected in every instance except one. In that case one kidney alone was found lardaceous (the other having been destroyed by scrofulous disease). In five of the cases the liver alone was found lardaceous.

These facts indicate that of these three organs the spleen is the most liable by far to be found affected with lardaceous degeneration,

and that after the spleen the liver is most likely to be found so affected.

Proceeding further to consider what the facts of these cases indicate, as to the pathological conditions with which the lardaceous degeneration of the liver and kidney more especially is found associated, it is remarkable that of the ten cases in which these glandular organs were alone affected, four were cases in which the lardaceous degeneration was found in association with syphilis (out of a total of eight cases in which this association occurred); and three others were cases in which malignant disease was present (out of a total of six); the three remaining cases being one of caries of the vertebræ, out of a total of thirteen cases of bone disease included in the series, and two out of twenty cases of phthisis pulmonalis.

These facts seem to indicate that syphilitic and malignant disease, which have an especial tendency to affect these glandular organs, and more especially the liver, tend to increase the liability of these organs to become the seat of the lardaceous degeneration.

The records show, in fact, that in eight cases of lardaceous degeneration associated with syphilis, the liver was found lardaceous four times and the kidney five times, and that in six cases of lardaceous disease associated with malignant disease the liver was found lardaceous four times. In these fourteen cases the liver was found lardaceous eight times, not lardaceous six times, the proportion being in the ratio of four to three; the kidney was found lardaceous five times, not lardaceous nine times. In the remaining forty-four cases of the series the liver was found lardaceous twenty-two times, and not lardaceous an equal number of times; the kidney was found lardaceous ten times, not lardaceous thirty-four times, or in the proportion of five to seventeen—ratios contrasting strongly with the previous ones.

On the other hand, while in the fourteen syphilitic and malignant cases the spleen was found lardaceous seven times only, in the forty-four other cases it was found lardaceous no less than forty-one times.

It is remarkable that it further appears from the facts of these fourteen cases, as far as they go, that where such an association is found, the liability of the liver, at least, to undergo lardaceous degeneration is greater in those cases in which the organ does not itself present any evidence of having been affected by syphilitic or malignant disease.

Thus, out of the eight cases of syphilitic disease, in six the liver was found to have undergone changes characteristic of that disease. In only two instances was this organ also lardaceous. Out of the six cases of malignant disease the liver was invaded by the growth four times, in two of which instances it was also lardaceous. That is to say, out of ten of these fourteen cases, in which the liver was found affected with syphilitic or malignant disease, in four cases only was the organ also lardaceous. In the other four cases, in which the liver appeared to have escaped implication, it was found to be lardaceous in every instance.

In the case of the kidney, recognisable syphilitic changes in the organ occurred only once, and in only one case also was this organ found invaded by malignant disease, in which case one kidney was destroyed by the growth. No inference can therefore be drawn from the facts regarding this organ on the point in question. The facts in relation to the liver, though so few, seemed sufficiently remarkable to be worthy of mention.

A comparison of the frequency with which, in the other forty-four cases of the series, the lardaceous degeneration was found to have occurred in these organs, when affected with other pathological changes, and when apparently otherwise normal, or nearly so, shows results not less remarkable than the above.

Amongst these cases the liver was found to have undergone such pathological changes of a definite kind five times, only once being found at the same time lardaceous. The kidney had undergone such changes thirteen times, in two instances only being also lardaceous. Out of eighteen organs only three were lardaceous, or 16·6 per cent.

The frequency with which the lardaceous degeneration was found in organs otherwise normal, or nearly so, being twenty-one out of thirty-nine, and eight out of thirty-one respectively; or of seventy organs twenty-nine were lardaceous, that is, 41·4 per cent.

The inference from which facts would seem to be that in these cases also, the existence of pathological changes in the liver and kidney renders these organs less liable to be affected with lardaceous degeneration.

As a parallel fact it may be mentioned that in seven cases more or less extensive ulceration of the bowel was found, but in only one of these cases is the mucous membrane noted as having been lardaceous.

2. As regards the pathological associations of the lardaceous degeneration in these cases, it appears that in forty-two out of the fifty-eight cases this degeneration occurred in association with prolonged suppuration. These included twenty cases of phthisis, one being implicated with empyema; thirteen cases of bone disease, six being cases of vertebral caries, four of necrosis, three of disease of joints; four cases of empyema, and four of abscess. In eight cases, as already mentioned, it was found in association with syphilis, and in six cases with malignant disease. In two instances it was found in patients who had died with cardiac disease, one case being probably syphilitic. In the remaining case it was found in a patient, a subject of the hæmorrhagic diathesis, who had died from recurrent hæmorrhage from an old retro-uterine hæmatocele.

In three cases there was a history of ague, in all long antecedent (26, 28, and 32 years). In one case there was syphilitic disease, in the other two cases malignant disease was present. In the former case only was the spleen found lardaceous.

There are no cases of dysentery, nor any of tuberculosis, excepting in cases of phthisis, included in the series.

In four instances the liver was found cirrhosed, in only one of these cases was it also lardaceous. Granular kidneys were found in six cases, the organs being at the same time lardaceous in three instances—two of which were cases of syphilis.

Large white or mottled kidneys occurred ten times; in one case only, a case of syphilis, were they also lardaceous.

The question of the relation of lardaceous degeneration to malignant disease being of some interest, it appeared desirable to give some account of the six cases in which these diseases were found associated.

The following is a very brief abstract of the facts ascertained about them:

Case 1 is that of Wm. R—, æt. 48. This patient was admitted into the London Hospital with œdema of the lower extremities and ascites, dating six months back, and slight albuminuria. There was a history of free drinking, frequent vomiting, and passage of some blood from the bowels. The patient died ten days after admission with symptoms of acute peritonitis.

At the autopsy the liver was found to contain several nodules of malignant growth. The spleen presented the typical sago appear-

ance and reaction. The kidneys looked as if albuminoid, but gave no reaction. There was a large scar on inside of right thigh.

No history of syphilis or of necrosis or chronic suppurative disease is recorded in this case; but the existence of a large superficial scar on the inner side of right thigh, "as big as a *cheese plate*," is suggestive of venereal, possibly syphilitic (phagedænic) disease.

Case 2.—Dennis S—, æt. 47. A temperate man. Admitted on account of a malignant mass with ulcerating surface in left side. Chest symptoms developed, and subsequently slight jaundice and œdema of legs. The liver was then found enlarged, and albumen in the urine. The patient died two and a half months after admission.

The *autopsy* showed a mass of growth growing inward from chest-wall, and nodules in lungs and liver. The liver and spleen were markedly lardaceous.

The history of this case was that the tumour had existed six years. It had been removed twelve months before his admission, on account of its size. There was an open ulcerating surface for six months before death. He admitted having suffered from gonorrhœa, but denied syphilitic infection.

Case 3.—Richard H. T.—, æt. 44, was admitted into the London Hospital on account of an epithelioma of the tongue. The tongue was removed. An attack of erysipelas followed, from which the patient died ten days after admission.

At the post-mortem great enlargement of the liver was found, due to lardaceous change. No other organs were found to be similarly affected. The liver weighed 5½ lbs.

I have been unable to obtain notes of the previous history of this case. No indication of the existence of evidence of syphilis or of old chronic suppuration appears in the records.

Case 4.—Hoolalee A—, æt. 49, was admitted with œdema of the legs, and much albumen in the urine, and complaining of lumbar pain, and great weakness. The case was regarded as one of acute nephritis. The albumen increased, the patient became more feeble, and died four weeks after admission.

The autopsy showed malignant disease of the abdominal glands and mesentery invading the liver. The spleen was lardaceous. The kidneys were large and white.

No history of the previous health of this patient could be obtained. His symptoms dated from four weeks previous to his admission.

CASE 5.—George A—, a sailmaker, æt. 50, was admitted on account of a large tumour in the left lumbar region, which was regarded as probably splenic enlargement, although no notch could be felt in it, as there was a history of severe ague twenty-six years before, and many years residence in a tropical climate.

The tumour, however, increased rapidly in size, and the patient died two months after admission. The hepatic dulness was observed to become enlarged after the patient's admission, concurrently with the increasing tumour.

The autopsy showed a large mass of malignant growth filling up the left side of the abdomen, which had invaded and destroyed the left kidney. The liver was greatly enlarged, weighing 8¼ lbs.; it was lardaceous, and contained a few masses of growth. The growth was very vascular and caseous. There was a history of gonorrhœa, but not of syphilis.

CASE 6.—Thos. McC—, æt. 48. The patient was admitted on account of pain commencing in the right lumbar region, and darting across the epigastrium. There was a history of chronic obstruction of the bowels, and a hard tumour was felt in the right lumbar region.

Malignant disease of the colon was diagnosed from these facts, together with the markedly cachectic aspect of the man. This diagnosis was confirmed after the patient's death, which occurred just eighteen months from the time when his health began to fail.

The autopsy showed that there was cancerous ulceration of the ascending colon, and that the liver had undergone the lardaceous change in a slight degree.

In this case there is a history of gonorrhœa and syphilis twenty-six years before admission, and of epileptiform fits nine years afterwards, for which he was admitted into the hospital, and from which he recovered in three months. There is also a history of ague at the age of sixteen.

The evidence afforded by Cases 2, 3, 4 and 5, as to malignant disease being an efficient determining cause, direct or indirect, of lardaceous degeneration of the viscera, seems sufficiently conclusive.

In Cases 2 and 5 there is a history of gonorrhœa, though not of syphilis; while in Case 3 we have no information on this point. It might thus be said that the possibility of a previous syphilitic infection cannot be entirely excluded in any of these cases, and the possibility remains that in all these cases later conditions may have

operated indirectly in bringing into activity some latent residuum, dependent upon a former syphilitic infection.

In Case 4, a distinct history of syphilitic infection, and more especially the occurrence, several years later, of symptoms indicative of a serious constitutional change resulting from it, make such a view appear more probable.

It is perhaps not impossible, on the other hand, that the slight degree of lardaceous degeneration found in the liver in this case may have been of old date, and unconnected with the malignant disease subsequently developed.

If, as would appear from clinical observation, this organ when affected with the lardaceous degeneration may, under favorable circumstances, be restored to its normal condition and functional activity, it does not appear improbable that this chronic change should, under less favorable conditions, remain stationary and altogether latent; supposing the extent of the disease is not so great as to materially affect the general health, and more especially where, as in the cases in which the spleen alone is found to have undergone the change, the disease appears to be limited to an organ whose functional integrity is not of essential importance to the system.

The possibility of lardaceous degeneration of the spleen remaining latent for very long periods is suggested by the occurrence of cases in which, after suppuration continued over many years, death has occurred in a manner accidentally within quite a short period of an operation, revealing lardaceous degeneration limited to this organ.

Among the cases included in the series is a very remarkable instance of such a course of events.

A healthy man, æt. 71, had had a discharging sinus in the neighbourhood of his knee for over forty years, from which pieces of bone had escaped from time to time. This seemed to have given him little inconvenience, as he had had no medical advice about it until he came to the hospital. Amputation was performed, but the man unfortunately died with pyæmia within a month of his admission.

In this case lardaceous disease of the spleen was found at the autopsy. It seems scarcely possible to say at what period this splenic degeneration occurred, or how long it might have continued to remain latent, had the patient's life not been thus as it were accidentally cut short.

No certain inference can thus be drawn as to the existence of any connection between the lardaceous degeneration of the spleen and malignant disease in Cases 1 and 4. In Case 1, the lardaceous disease may perhaps be referred with greater probability to prolonged suppuration indicated by the very extensive scar on the thigh. In Case 4, the previous history is wanting.

In one of the cases in which the lardaceous degeneration was found associated with cardiac and renal disease, a similar doubt may be felt as to the possible inference of any connection between the two pathological conditions.

Case 7.—Wm. R. B—, æt. 27, a well-nourished, healthy-looking man, stated that three years before being admitted to the London Hospital he had suffered from a severe attack of acute rheumatism with many relapses, and complicated by an attack of acute nephritis. He had suffered from cardiac symptoms dating from this attack, but had been pretty well until taking cold a month before coming to the hospital. He had albuminuria in the anasarca, and sign of cardiac disease. He died about ten weeks afterwards, with pleuritic effusion and acute peritonitis.

At the autopsy incompetence of the mitral and stenosis of the aortic valves was found, and large white kidneys. The spleen alone was lardaceous.

In this case there was no history of continued suppuration, nor of syphilitic infection.

In the second case there was the same form of cardiac lesion, and the kidneys were cirrhosed. These organs and the spleen were lardaceous.

Case 8.—Chas. R—, æt. 48, had suffered twenty-seven years previously with a white swelling of the knee for which amputation was performed.

He was admitted with symptoms of cardiac disease, which dated from an attack of acute rheumatism twelve months before. He had anasarca, ascites, and much albumen in the urine. The heart was enlarged, and there was the physical sign of mitral regurgitation and aortic stenosis. The patient died seven months after his admission.

The autopsy showed, in addition to the valvular disease indicated by the clinical symptoms, large lardaceous kidneys, with puckered surface and some contraction of the cortex, and a lardaceous spleen.

The lardaceous degeneration in this case may possibly have dated from the old disease of the knee.

One other case deserves mention in relation to the pathological connections of lardaceous degeneration.

CASE 9.—Harriet J—, æt. 24, married. A subject of the hæmorrhagic diathesis. She was admitted on account of shortness of breath, dating from an attack of rheumatic fever twelve months before, and for hæmoptysis of six weeks' duration, the loss having been considerable. She had had a miscarriage two months before admission, and had been losing flesh. For three days there had been cramping pains down the outside of the right thigh and leg, with lameness of the limb. The right buttock appeared more prominent than the left. She attributed this to a fall down stairs three years previously. There was considerable pyrexia with morning remission, and night sweating. She complained of pains all over her. There was no swelling of the joints. She suffered also from incontinence of urine. Ten days after her admission considerable hæmorrhage occurred from the vagina. A hard mass was at that time felt projecting from the right wall of the pelvis. No fluctuation could be distinguished in it. The hæmorrhage recurred again and again, until the patient sank from loss of blood four weeks after the date of her admission.

At the autopsy an old hæmatocele with a firm fibrous wall ¼ inch thick was found in the broad ligament on the right side. It was adherent to the bladder, and had extended downwards and backwards, into the sacro-sciatic notch; it had there ploughed up the obturator internus muscle, and had passed out of the pelvis along its border. Its cavity was lined with a distinct pigmented membrane, and was filled with soft chocolate-coloured substance, evidently altered blood clot. The uterus was healthy, and the peritoneum intact. The liver was much enlarged and lardaceous, the kidneys were pale and mottled, and lardaceous. The spleen also was markedly lardaceous.

There was in this case no history or direct evidence of the existence of any of the generally recognised efficient causes of the lardaceous degeneration, to account for its occurrence.

Dr. GREENFIELD exhibited microscopic specimens of lardaceous liver, spleen, and kidney stained with methylaniline violet. He also showed a drawing made at least sixty years ago, which well represented a piece of liver in advanced lardaceous degeneration, but was

labelled "lipoma of the liver." This he thought of some interest in relation to Dr. Gairdner's statement that lardaceous disease was formerly confounded with fatty degeneration.

Although he had listened with great interest to Dr. Dickinson's masterly exposition of lardaceous disease he felt that there were many difficulties in the way of accepting the view that lardaceous disease was an infiltration rather than a degeneration, and that the evidence upon which Dr. Dickinson relied was to some degree incomplete. But though he felt bound to raise these objections, he would not pretend to be able to settle the questions raised.

The iodine reaction, on which Dr. Dickinson seemed to rely as a sufficient and unfailing test for lardaceous degeneration, always appeared to him a very rough and uncertain one. For although it does stain lardaceous parts well in many cases, it sometimes fails, especially in certain organs. Moreover, it does not lend itself well to microscopic examination, nor is it permanent. And, what is of still more importance, it stains other degenerated or altered albuminoid bodies in a way which is indistinguishable from lardaceous material. Whatever its value the reaction would not, therefore, be regarded as pathognomonic. He had used with success a method of staining with methylaniline violet, which he believed was first introduced by Cornil.[1] The sections were first stained deeply with the colouring agent, then the sections mounted in glycerine acidulated with acetic acid. The parts which have undergone lardaceous change stain very deeply, but the addition of acetic acid causes them to turn of a bluish violet colour, the nuclei of cells, &c., staining violet red. This reaction, whilst very distinctive, is much more suited for microscopical examination than that with iodine. It was also possible, as in some of the sections shown, to mount sections thus stained in the ordinary way in dammar or balsam, although the difference in colour did not persist. Individual muscle-cells, &c., which were thus degenerated, were well picked out from the healthy muscle.

Now, in the examination of the kidney by this method it was found that the casts which stain brown with iodine do not give this characteristic reaction with methylaniline violet, and hence cannot be regarded as lardaceous. In the rare instances when they do give the reaction, they are not the so-called "waxy" casts which

[1] "Note sur la Dégénérescence Amyloide," 'Archives de Physiologie,' 1875, p. 671.

are found in every form of renal disease, but casts formed of epithelium which has undergone the lardaceous degeneration. It might be that albuminoid casts in the convoluted tubules, owing to their long contact with acid urine, become chemically altered, so as to resemble lardacin in their character and reactions.

Another point to which he would refer was the question whether lardaceous disease was an infiltration or a degeneration. No doubt the theory of infiltration, first suggested by Rindfleisch and adopted by Dr. Dickinson, was a plausible one and had many points in its favour, but the difficulties in the way of accepting that view appeared to him to be great, and he preferred to adhere to the older view that it is a degeneration. The basis of the infiltration theory was that the parts first affected were those nearest to ultimate arterioles, for example, the afferent arterioles and glomeruli in the kidney, the malpighian bodies of the spleen. Again, some had supposed that the so-called waxy casts in the kidney were formed by an actual excretion of lardaceous material into the tubules, and had used this as a strong argument in favour of this theory. The latter argument was, as he had shown, fallacious. Nor could the evidence on the other hand, be considered conclusive. For the change in these parts would equally well be accounted for by the circulation of some material which caused a degeneration, or the mere malnutrition of vitally active and usually highly nourished parts of the organism. If it be an infiltration, why did one see sometimes only a few muscle-cells in an artery undergoing the change, the inner coat and all the other cells remaining intact, as in the specimen shown? And why was not the material generally distributed throughout the body, but limited to certain functionally active organs such as the spleen, kidney, and liver? Where was this material formed, in the blood or at the seat of suppuration?

And, again, if the loss of potash is, as Dr. Dickinson supposes, the main agent in determining the change, would not this be in favour of the view that either a less alkaline condition or an impoverished state of the blood led to a degeneration of the parts supplied. Moreover, he was inclined to believe that the loss of white corpuscles was quite as constant and important as the loss of potash, and neither could account for lardaceous degeneration in syphilis without suppuration. He ventured to suggest these difficulties in the hope of a fuller explanation of the theory of *infiltration*, as opposed to

*degeneration*, and must for the present hold to the latter view, as more consonant with known facts.

Lastly, he had certainly seen lardaceous degeneration in a number of cases of syphilis, both congenital and acquired, in which there had been no suppuration, some had bone disease, others none. As to the retrograde changes which occurred in lardaceous material, though its durability was great, it often underwent fatty degeneration, molecular disintegration, and even calcification.

The PRESIDENT said that whether the outcome of the discussion might in respect to novelty be much or little, he thought that no one would doubt that the Council had done wisely in deciding to bring the subject of lardaceous disease before the Society. Ten years ago, at the suggestion of Dr. Dickinson, a committee was appointed to examine into the nature of this disease, and to advise as to the name by which in future it should be known. Dr. Marcet took a chief share in the chemical investigation, and it was conclusively determined that the substance is albuminoid. Since then but little original work in this subject had been done by the members of the Society, and it was, therefore, appropriate that we should now ask whether any new knowledge has been obtained, and, if so, what it is. He believed that the object of the Council in inviting a debate on this topic was, first and principally, to obtain statements of new facts, illustrated by preparations or drawings; secondly, to obtain numerical statements of *post mortem* room experience; and, lastly, to draw forth brief expressions of opinion from those who had no new facts to furnish. At the last meeting, although in the discussion which followed Dr. Dickinson's opening paper no new facts had been elicited, yet Dr. Turner had given an excellent summary of the dead-house experience of the London Hospital, and they had heard brief statements of present creed from two of the ablest pathologists in Europe (Dr. Wilks and Dr. Gairdner), both of whom had worked as pioneers in this special subject. He hoped that this evening might be successful in obtaining new facts, or, at any rate, in eliciting from other hospitals general statements of experience. But even if little more should result, the Council would not be disappointed, as it would have been finally shown that pathologists are almost unanimous as to the chief facts. He would state very briefly some of the questions which had occurred to him as requiring investigation. Dr. Dickinson said that lardaceous

deposit was an infiltration from the blood, not a degeneration of tissue, and that it escaped alongside the arterioles of certain known viscera and regions. Could anything be said against this view, or might it be considered as accepted? Dr. Dickinson had also advocated the view that a deficiency in alkali is the main feature in which lardaceous infiltration differs from the more ordinary forms of albuminoid deposits. He further in a general way cut down the list of supposed causes, and asserted that suppuration and syphilis far exceeded all others in importance. Dr. Dickinson had not stated whether syphilis, when not attended by suppuration, can cause it, or can, at any rate, cause it in a severe form. Dr. Turner's report was also silent on this point. If syphilis alone be a cause, he would inquire how does it act? It seemed improbable that the mere existence of a syphilitic taint could produce it, for, were this so, lardaceous disease would be far more common than it is. He thought there were two modes of explaining the facts; one, that the long-continued suppuration which attends a certain number of severe forms of syphilitic ulceration of skin and bone produces general lardaceous tendencies, as in any other prolonged suppuration; the other, that syphilitic formations are themselves liable to lardaceous change independently of general predisposition. He would ask whether these two hypotheses embraced all the facts, and also whether there really were cases of severe and general lardaceous disease in the subjects of syphilis, in whom no suppuration had ever been present? This last question was most important, and he regretted that he had no facts to offer for its solution. He was familiar with the hopeless cachexia sometimes met with in syphilitic patients, and which seemed to be associated with lardaceous disease, but he could not recall a single case of this kind in which severe suppuration had not preceded the cachexia. Dr. Dickinson had brought into prominence the tendency of new formations to become the seat of lardaceous changes. Dr. Turner had confirmed the statements as regarded the influence of cancer as a cause. In reference to this class of influences, and also to lymphadenoma as an occasional cause, he hoped for further information during the discussion. As regarded numerical statements, he would suggest that it would be better to place severe cases of general tendency to lardaceous deposit in a list apart from those in which the disorder was proved to exist only on a small scale, as, for instance, in a single viscus, or in a new growth. Might it not be possible that there were

local predispositions as well as general ones, and that the two differed most widely in importance? It was of importance that the discussion should not pass outside the domain of strict pathology; but, without risk of going beyond bounds, he thought he might ask histologists what evidence is forthcoming as to the retrograde or curative changes which are possible in lardaceous disease? Do its deposits ever disappear, and is it possible for an organ once affected to be restored to soundness? If not curable, is it always aggressive, and at what average rates? What are the conditions by which it is most certainly identified during life, and how long may be the interval between the supposed cause and the development of the disease? In Dr. Turner's summary several cases had been placed in the suppuration class, in which the only proof was the existence of a scar, which had been for some time sound. Is there any reason to suppose that the drugs given for the cure of syphilis take any share in predisposing to these changes? It is said that the disease is very common in hot climates; he thought it would be very useful if members would speak also as to the curative effects of climate, and especially of sea air. The only criticism he would venture to offer on Dr. Dickinson's paper was that it was briefer than he could have wished. He hoped that in his reply Dr. Dickinson would amplify some of his remarks.

Dr. Pye-Smith.—We are practically discussing the theory of lardaceous disease, which was brought forward by Dr. Dickinson in a remarkable paper twelve years ago, and I wish to submit to the Society certain difficulties which prevent the acceptance of that theory.

First, the process described for making the lardaceous material artificially can, it appears to me, have no other result than the production of the well-known body syntonin. But syntonin is certainly not identical with the morbid product we are discussing. For syntonin is exceedingly soluble in acids and in alkalies, lardacein is very insoluble; syntonin is readily digested, while the lardaceous substance resists digestion. I have tried specimens of syntonin prepared with acid of various strengths, from various proteids, and at various temperatures. The products thus obtained differ in the depth of colour produced by iodine; but generally this is more decided than in the case of albumin, less so than in that of lardaceous substances or some specimens of vitellin.

Secondly, the effect of potash is not, I submit, upon the "dealkalized fibrin" but on the iodine. It is the same effect which potash or soda produces on the brown stain of iodine applied to coagulated albumen, to ordinary fibrin, and to dextrin, and in like manner the colour can be restored by neutralization with acid. It is in fact only what we see when we use liquor potassæ to efface stains of iodine on the fingers; the unstable coloured compound of iodine with keratin or lardaceous material, or glycogen, or dextrin, or starch is decomposed, and the colourless potassium iodide thus formed may be again decomposed and the colour restored, by addition of an acid.

Again, although the cases published by Dr. Dickinson (loc. cit.), Dr. Wilks ('Guy's Hospital Reports,' 1856, p. 103, and for 1865, p. 45), Dr. Fagge ('Path. Trans.' for 1876, p. 334), and many others, prove that the more frequent antecedent of lardaceous disease is prolonged suppuration, yet there is no doubt that syphilis without suppuration can produce this lardaceous change; and there are other things lost besides potash in a flow of pus. There is oily material and globulin and nuclein, beside albumin, and, of the saline constituents of the body, phosphates are discharged in large quantity as well as potash salts. Indeed, the analyses by Dr. Dupré of lardaceous viscera, quoted by Dr. Dickinson, show (as we should expect) a deficiency of phosphates as well as of potash.

As to the chemical composition of lardacein, we need not go back to the long-disproved hypotheses of Virchow or of Meckel. Even Kekulé's analysis twenty years ago established the presence of nitrogen; and the ingenious method by which Kühne took advantage of the characteristic insolubility of lardaceous matter to separate other constituents of the affected viscera from it, instead of it from them, has finally settled the position of this material among the allies of albumin. But I am not aware of any reason for regarding it as more closely related to fibrin than to other allied products, as elastin, or keratin, or chitin.

No one, of course, would now speak of fibrin being exuded from the blood in inflammation; but the proposition, if I may translate it into modern language, that lardaceous material in the tissues has its nearest analogue in the fibrinous adhesions of ordinary inflammation has not, I think, any sure ground to rest on. We now know that inflammation is accompanied by the exit of colourless corpuscles, that these products of inflammation show tendency either to fatty

or calcareous degeneration (forming pus or caseous material), or to formation of connective tissue (in organisable lymph and cicatrices), and that the exudation of plasma and formation of fibrin in the tissues is always accompanied by the local and general signs of irritation. In lardaceous disease, on the other hand, there is no appearance of leucocytes either by emigration from the blood-vessels, or by proliferation of tissue-cells, degenerative changes are only very rarely observed,[1] and organisation into connective tissue never; while all the appearances, both local and constitutional, are those of a passive and retrograde rather than an active process.

Lastly, we do not find the lardaceous material exuded or infiltrated between the elements of the affected tissues, but making its first appearance in their very midst, displacing the protoplasm of a secreting epithelial cell in the liver or of a contractile muscle-cell in the middle coat of an artery. The processes more nearly allied in their clinical aspects to lardaceous disease are those of fatty and calcareous degeneration with which Virchow associated it.

For these reasons we should, I think, maintain the original view of Rokitansky (as we have adopted the name given by the Vienna school, *speckig*, *i.e.* lardaceous) that lardaceous disease is a degeneration, a chemical and structural change in living tissues, and not as Rindfleisch and Dr. Dickinson regard it, an infiltration among the tissues of a morbid material derived from the blood.

It appears to me that "dealkalized fibrin" is syntonin and not artificial lardacein, that the lardaceous change is not of necessity connected with the loss of potash, and that neither chemically nor functionally does it resemble fibrin more than other albuminous compounds.

Dr. Goodhart.—I must apologise for speaking quite unpremeditatedly, but you, sir, upon various points, have asked for information, which is, I think, already before the Society in one of the volumes of its 'Transactions' (vol. xxvii, 1876, p. 324, *et seq.*), though the communication which affords it has not as yet been alluded to in this discussion. It seems, indeed, to have been quite forgotten that, so far as statistics can show anything, the statistics of lardaceous disease have been already given to us in a most valuable paper by Dr. Hilton Fagge, in connection with his remarks

[1] In the remarkable instances brought before the Society by Dr. Fagge in the twenty-seventh volume of our 'Transactions.'

during the debate on syphilis. They were compiled from the *post-mortem* records of Guy's Hospital, during a period of twenty years, by Mr. Lancaster. It will, I think, render this debate more complete if I attempt to answer some of your questions from the figures given in that paper. Because, as now, so hereafter, there is a risk of the facts being overlooked by reason of their being, perhaps, a little out of place.

That they comprise the whole experience of Guy's Hospital upon lardaceous disease for so long a period is a warrant for insisting on their value and the necessity for their reintroduction. Till now the knowledge of the fact that they had been already published rendered it unnecessary, so we thought to give them again to the Society, and obviated any prolongation of the debate on my part.

You invite attention to several points, and first I notice this: Is syphilis, apart from suppuration, competent to produce the lardaceous change? Now, during these twenty years, 244 cases have been recorded in which lardaceous changes were present in the viscera; and of these, 154 were associated with chronic suppuration, and 76 with syphilis. In 34 of these 76 cases there was evidence of former or present bone disease or suppuration, leaving about 42 in which the affection seemed attributable to syphilis, *per se*. Dr. Fagge also adds that during the same period the total number of inspections of syphilitic cases amounted to 177, making the proportion of cases of syphilis in which lardaceous disease existed nearly 43½ per cent. So that there can no longer be any doubt that cases of severe general lardaceous disease occur in the subjects of syphilis in whom no suppuration has ever been present. The report does not state anything concerning the distribution of the change, but I have myself, for other purposes, taken 150 consecutive cases from our records, and found, what general impressions already left no room to doubt, that in many of the cases the lardaceous change is general. Thus, the liver was affected in 73 cases, the spleen in 99, the kidney in 110, the intestine in 63. These figures embrace both classes of cases, syphilitic as well as suppurative, and there is, I think, but little distinction between the two, as regards the distribution of the morbid product. If any exist, I should say that, on the whole, the disease is more widely distributed in syphilis than in cases of suppuration. How the change is brought about under these circumstances is not known, but it seems not improbable that a chemical change, such as this in all probability

is, may be favoured by the local pyrexia, which must almost of necessity be present in connection with the long-standing cell activity which obtains in syphilis. It certainly is not the fact, however, that syphilitic new formations, limiting that term to well-marked gummata, are more prone or so prone to undergo the lardaceous change as the less altered parts of the solid viscera. In connection with this part of the subject, it must also be remembered that in all statistics of lardaceous disease cases are to be found in which, although there has been suppuration, it cannot be supposed to have been of sufficient extent or duration to explain the change satisfactorily. Dr. Fagge gives five such cases, and I have myself seen a case of spinal disease, with caseous pus, in front of the spine, in which there was no evidence that the abscess had ever opened, therefore the patient had been subjected to no discharge, though she may have had suppurative fever.

With regard to its *cure* histology has nothing to say with reference to lardaceous disease, but certain retrograde changes are known to occur in the direction of conversion into fat which have been duly noted by Dr. Fagge in the report from which I am quoting.

I come next to the length of time that must elapse between the commencement of suppuration and the production of the disease, and here it must be evident I think that this will vary according to the individuality of the patient. The resistance to the change by some or their amount of recuperative power, under what to others would be exhaustive, suppuration seems to be so great that for long no material amount of lardaceous disease takes place. This, and the fact that the change occurs in syphilis when we have not the least idea as to its time of onset, prevent the formation of any very reliable conclusion. Still here are the facts. "There were about six of these cases in which the origin of the suppuration was some local disease, having a definite starting point so as to allow of one forming an opinion as to length of time required for the development of the lardaceous change in the viscera. One patient had had a carbuncle eight months; another had suffered from pelvic cellulitis for the same period; a third had had a bedsore seven months, the result of a fracture of the spine received a fortnight previously. In a fourth case there was an ulcerating sarcoma of the abdominal wall which had been discharging for four months only. In a fifth there had been fracture of the spine three months before, bedsore for two and a half months, and a double empyema, but this patient

had fibroid testes and a scar in the groin. Lastly, a sixth case was one in which amputation of the leg had been performed three and a half months before death, on account of a compound fracture, with abscess; in that instance the patient died of diphtheria, and it is particularly noted that the lardaceous change was just commencing in both the liver and the spleen." So that it would appear that three months is the shortest period in which the disease, so far as Guy's is concerned, is known to have occurred. But I have this suggestion to offer on this head that the duration of the suppuration necessary to produce lardaceous disease depends in great measure upon the duration and intensity of the fever. If either in suppuration or syphilis the pyrexia be great or perhaps if it be prolonged without much intensity, other things being not adverse, the lardaceous change will be produced rapidly. I think I have observed that this is the case, and this view has some important bearings. In the first place, it may throw some light upon the fact, now confirmed by very many, that this is a disease very rife in hot climates; and secondly, it would serve to associate the lardaceous change with those other histologically not very different morbid changes which have been noted by various observers, I mean those hyaline changes in the vessels which have been described as occurring in various febrile conditions. I would only add that I agree with Dr. Greenfield and others that the iodine test is entrusted with too great responsibility in making it the sine quâ non. It is the best test that we have, may be, but it not so very infrequently fails in very early and very late cases. In the former the reaction is liable to be confused with normal colorations, particularly upon mucous surfaces, and very late changes also sometimes fail to give any reaction at all, particularly in the spleen.

Dr. Stephen Mackenzie said that, with reference to the remarks which had fallen from Dr. Goodhart, as to the influence of fever in producing lardaceous disease, he would like to call attention to a change in the blood-vessels that occurred in certain diseases with blood alterations. He had found it in the arteries of the spleen in nearly all the cases of pyæmia he had examined; in some cases of diabetes, in a case of angina Ludovici, and in some other diseases. Dr. Klein had first described the change in typhoid and scarlet fevers. In many cases the change in question was confined to the intima, but in some cases it involved the muscularis. It consisted in

a hyaline transformation, which did not give a characteristic reaction with iodine, but stained slightly with methylaniline violet. He did not regard it as lardaceous, but it occurred in diseases attended by alterations in the blood, most of them febrile in character, and he thought an examination into the nature of this change in the vessels might throw some light upon lardaceous disease.

Dr. RALFE.—I wish to draw the attention of the Society to the fact that iodine not only gives with fibrin treated with dilute hydrochloric acid the deep brown-red stain which is held to be the characteristic reaction of lardacein, but also with ordinary fibrin, and with alkali albumen or casein. On porcelain dishes I have placed specimens of (*a*) ordinary coagulated egg albumen; (*b*) acid albumin or syntonin; (*c*) alkali, albumen, or casein; (*d*) pure blood fibrin; all treated with iodine and all showing, with the exception of the ordinary albumen, in an equal degree the staining with iodine. This fact is of considerable importance, as it shows that no special reliance is to placed on the iodine reaction as indicating the presence of lardacein, and that the development of the reaction merely denotes the presence of an albumen other than ordinary albumen; whilst the fact of the red colour being developed equally with *alkali* as well as with *acid* albumen, shows that the reaction is not caused by the removal of alkali. In watching the progress of the debate I have been surprised at the little prominence given to the nature of the fatty changes occurring in the organs in this disease. Are these fatty changes in themselves a part of the disease, or a result of impaired circulation consequent on the condition of the vessel? I do not myself believe the fatty changes are due to the latter condition, because the character of the fatty matter appears both physically and chemically distinct from that produced by retardation or impairment of blood supply in other pathological states. Dr. Stephen Mackenzie, in the course of the debate, drew attention to the hyaline degeneration of the interior of small arteries in certain acute febrile diseases, and intimated that though the material gave no definite reaction with iodine, still the further study of this condition might throw some light upon lardaceous degeneration as being associated with alterations in the blood. The suggestion is a particularly valuable one. It might be that the difference between the hyaline and waxy is only one of degree, the hyaline being the

first step in the degenerative process. The study of the degenerative changes in albuminous bodies has only recently attracted attention, and till our knowledge respecting these changes is more developed it is hardly safe to venture on wide generalisations with respect to the nature of the disease. On a point connected with the clinical aspect of the question I can confirm Sir Joseph Fayrer's statement of the occurrence of the disease apart from suppuration as an occasional result of tropical malarious disease. A notable instance being that of an old Greenwich pensioner, aged ninety, who died from simple old age, and who for years was known to have considerable enlargement of the liver and spleen, which a post-mortem examination proved to be caused by an infiltration of those organs with lardaceous matter. All his other organs were apparently sound; there was no evidence of old abscesses or other cause of suppuration, nor of any dysenteric attack, nor of syphilis, but he had been much exposed to malaria in the West Indies.

Dr. Dickinson.—I beg to return my cordial thanks to the Society for the consideration with which my views have been received, and to certain members individually for their support. My thanks are due to the President, if I may say in his absence what I should scarcely presume to say were he present, as to one who never approaches a subject, be it what it may, without adding to our knowledge of it. They are due to Dr. Gairdner as one of the earliest workers in the matter before us, one who together with other pioneers in pathology gathered together at Edinburgh about the year 1851, among whom must be mentioned the late Dr. Hughes Bennett and Dr. Sanders, came to conclusions more nearly like those of the present day, and I will venture to say more true, than some which at a later date issued from Germany. And I have also to thank Dr. Wilks, who contributed largely to our knowledge of this subject at a time when such knowledge was scanty. But I am speaking now of what is within the memory of the Society, and it is not my purpose to deal historically with the question of lardaceous disease. Such a design, indeed, is procluded by the limits of the time which is assigned to me.

I will first briefly notice some observations made in the course of the debate, and then add a word or two upon the question in general.

To put the last speaker first, as fresh in our minds, I may say that

I think there can be no doubt at all, I did not, indeed, know that any had been expressed, as to the fact that syphilis acts generally upon the system as a cause of lardaceous disease not locally with reference to the particular lesions. Distant organs and structures are affected just as much as those near to the specific localisation.

Next, with regard to my friend Dr. Greenfield, who spoke first, and in referring to what he said I shall necessarily include points which were touched upon also by other speakers, so that in some particulars one reply will do for several. With regard to casts and generally. The iodine reaction with casts is quite exceptional even when the kidneys show it strongly; but when it is met with it is so characteristic that there is no mistake about it. I have published an illustration which shows it with considerable accuracy.

Dr. Grainger Stewart, to whom we owe much with regard to the pathology of the disease and its clinical associations, tells us that he has not seen the reaction in this situation though something like it; but I cannot doubt that it sometimes, though rarely, occurs. No doubt casts and epithelial cells which have been soaked in acid urine, as Dr. Greenfield suggests, often tint rather deeply, as might be expected from the relation which clearly exists between acid and iodine; but their colour does not reach that of the proper lardaceous cast. With regard to the aniline violet I have had no experience with this colour, though I have experimented with other aniline colours, beside a large variety of different dyes and reagents. I have found no test which is comparable with iodine in its practical utility; the next best is indigo. The alkaline condition of the healthy tissues slowly destroys the blue colour of sulphate of indigo; in the lardaceous parts it is retained.

It must be borne in mind that the iodine test is one of degree, not of kind; it is only a question of more or less, not as if distinctly different colours were produced in health and disease, but only more or less of the same. The reaction is no more than a power of absorbing and holding iodine; substances not lardaceous vary more or less in this respect, so that the line between lardaceous and non-lardaceous is not always so sharp as one would wish. It has been shown that this affinity is closely associated with the condition of acidity; it may be developed in either fibrine or albumen by putting them in this condition; and possibly, as in the case of epithelial cells found in urine, there may be an approach to it under other

than lardaceous circumstances. Practically, however, the test is easy of application, and its results seldom doubtful. It cannot be said to be absolutely pathognomonic, or, at least, there are very early and very late conditions of lardaceous disease in which it is not to be detected. The unassisted but practised eye will sometimes appreciate the change in the liver before iodine does so. The acini swell and become waxy or pinkish in look, the whole organ increasing in size, but as yet iodine may show nothing, though we may be sure from the appearance of the organ and the circumstances of the case that it would do so were time given. Again, there are instances of retrogressive disease—I have seen it marked in the spleen—in which the iodine reaction had disappeared, though the organ has not yet lost its waxy look or shrunk to its healthy dimensions. It was rapidly doing so, but the special characters of the change were lost before the retrogression was in all respects complete. Thus, iodine is not an invariable test, but it is practically the best.

Dr. Greenfield objects to my calling the change an infiltration, not a degeneration ; I said it was an addition to the structures, not merely an alteration of them. That something has been added is evident from the enormous increase of bulk which some viscera—notably the liver and spleen—display under the disease. The liver will reach from the ribs to the groin, and fill nearly the whole of the abdominal cavity ; and if this evidence of addition be not enough we have the further fact that potash will dissolve out an enormous proportion of nitrogenous material from the lardaceous organ as compared with that of health. It will be remembered that Dr. Marcet obtained it in this way for analysis, and exhibited it before this Society. Then, again, the distribution of the morbid change is in favour of its being an addition which many tissues may receive. I need not repeat the evidence which the reaction gives of its presence not only in vascular structures, but in casts, epithelial cells, vegetations, and gummata. It is more likely that the same thing should be added to all of these than that these very different substances should all decay in the same peculiar and unusual shape. Dr. Greenfield asks why the change is not found in the skin and in the bones ; we may ask why is any morbid change found anywhere that is not found everywhere? Every disease has its own affinities, like every secretion. I do not contend that the material is poured out at large like a mere soakage into a dropsical limb, but

that it is something which is found in the blood and taken up by its appropriate tissues.

Dr. Greenfield revived a suggestion which I ventured to bring before the College of Physicians at the Croonian Lectures[1] which I had the honour of giving in 1876, and have since referred to, namely, that the loss of white corpuscles with suppuration might be importantly concerned in the development of the disease. The potash of the blood is chiefly contained in the corpuscles, the soda in the serum; thus a loss of corpuscles would entail a loss of potash and what remains behind as lardaceous deposit might represent the serum with its chloride of sodium. In order to test this view, I examined with the hæmatometer a number of cases of protracted suppuration and lardaceous disease. I need not dwell upon the results which have been published, but in brief they came to this: both under suppuration and with the lardaceous disease the white corpuscles were increased; I thought I should find them to be diminished, but it was not so. What loss there was, and that often considerable, was on the part of the red. These were few and ill coloured. Perhaps we hardly know enough with certainty as yet to argue from these observations; we must know more of the relations of white and red corpuscles; but it is highly probable that a loss or deficiency of corpuscles and with those of potash is a very important part of the pathological process.

Dr. Pye-Smith asks a question with regard to the action which caustic alkali has upon the lardaceous tissue in destroying its power of reacting with iodine. He suggests that this is due to nothing more than the very familiar fact that caustic potash destroys the colour of iodine by forming with it a colourless salt, namely, our very much esteemed agent iodide of potassium. I think Dr. Pye-Smith might have given me credit for avoiding this very obtrusive fallacy; or rather, I will say that I think he would never have asked the question if he had made the experiment, for I am sure that if he had done so he would have made it so carefully as to have satisfied himself on this point.

The fact is, that it is not any remnant of liquor potassæ in the tissue to which the effect is due, for this may be washed by all the water of Niagara, soaked for seven years in spirit, or neutralised by acid, and yet, when once the lardaceous matter has been acted

[1] 'British Medical Journal,' June, 1876, p. 683. 'Albuminuria,' 2nd edit., p. 246.

on by potash or soda its reaction is gone never to appear again. The material is soluble in alkali, more so than the healthy tissues, and the potash takes it out.

Then Dr. Pye-Smith refers to the action of artificial gastric juice upon lardaceous organs, and tells us that by its agency everything has been found out about it. The observations to which he refers have long been before the profession. They appear to me to be very far short of what we want. Lardaceous matter is supposed to be indigestible; a lardaceous organ is digested, and what is left is supposed to be lardaceous matter. This is analysed, and thus shown to be of nitrogenous composition, as we know also by more sure methods. This method teaches us nothing of the salts, to which some importance must be attached; they are all washed out or dissolved in the process.

I may say, with all respect to the distinguished chemist by whom the process was employed, that I do not think that it is one from which much more can be learned. But I must touch upon a statement which Dr. Pye-Smith has made in regard to it as not being consistent with my own observations. I pointed out certain points of analogy between fibrine dissolved in acid and the lardaceous material. I do not say they are identical, but similar. Dr. Pye-Smith says that the fibrine thus altered cannot be the same as lardaceous matter, for it is digestible, while lardaceous matter is not. So far as my observations go—on this point they are not very numerous, though apparently clear in result—fibrine thus altered becomes nearly indigestible, thus contrasting with normal fibrine, which dissolves easily, and approaching the character of the lardaceous deposit which does not.

Lastly, Dr. Pye-Smith argues that the material cannot be fibrinous, because the process bears no semblance to inflammation. This appears to me scarcely to meet the occasion. Fibrine comes out otherwise than as inflammatory exudations—in the effusion of dropsy, on the valves of the heart, the lining of the aorta, and elsewhere. Besides, I do not say the product is simply fibrinous, but something formed in the blood, which may be made out of fibrine. Whether the material is essentially fibrinous or essentially albuminous may admit of doubt, but it *may* be derived from fibrine, even though inflammation is not concerned.

Not to dwell longer upon individual remarks, I will touch upon the general result of the discussion. Nothing has been brought

forward to invalidate the view that the matter is derived from the blood, as one of its constituents in a slightly altered state; whether allied to fibrine or albumen may as yet be an open question; the ultimate composition may equally suit either. In its insolubility in water it is like fibrine. It is found in some situations proper to fibrine, in others, as in epithelial cells, more often belonging to albumen. If essentially albuminous it has come to resemble fibrine in its insolubility. It has its own peculiarities, of which want of potash appears to be one of the most important.

The causes of the disorder are, perhaps, of more practical importance. The discussion has brought none to light save suppuration and syphilis. Dr. Turner's cases are important in this respect. They are striking in suggestion of these causes, even where they were not definitely ascertained. A man, without definite history of suppuration or syphilis, had a scar upon his leg "as large as a cheese plate." Others, innocent of syphilis, admitted to gonorrhœa —a favourite compromise among the hospital classes.

No one has asserted that lardaceous disease is due to cancer or tubercle when these growths are unaccompanied by discharge, or to alcohol or chronic rheumatism, or to indefinite cachexia, or that it could arise spontaneously. I once thought it could be traced to protracted albuminuria, but I am now convinced that the albuminuria in such cases was of lardaceous origin. Thus, lardaceous disease is always secondary, and the only causes to which we can trace it are these two—suppuration and syphilis. I do not say there *are* no other causes; I think it inconceivable but that there must be others, but they must be operative so seldom, as compared with the two great causes which have been mentioned, that as yet they have eluded our search.

The action of suppuration appears pretty clear in the loss which it involves, and the consequent deposition of what remains behind in relative excess. How syphilis acts is more obscure. I think there can be no doubt that it does act, and that most efficiently, *per se*, independently, that is, of suppuration. We see lardaceous results from syphilis where suppuration has been practically absent, and in other cases where it has been trifling. The two causes often concur. Syphilis without suppuration appears to be a far less frequent cause of the disease than suppuration without syphilis.

What may be the *modus operandi* of syphilis is a question more easy to ask than to answer. But when we consider how profoundly

syphilis affects nutrition we may be prepared to attribute almost any wasting result to it. Syphilis may stop the introduction or development of that which pus takes away. A deficient income may produce the same result as an excessive expenditure—syphilis may represent one and suppuration the other. The blood-corpuscles in syphilis have been numbered and found wanting: whether the similarity of result between suppuration and syphilis is owing to these, in one case being taken out and in the other not put in, is a question which, for the reasons I have already stated, cannot yet receive a conclusive reply.

I think Dr. Goodhart's observations upon the effect of a febrile temperature are of interest; I may add a fact I have recently learned from Dr. Moxon. He tells me that under typhoid he has known lardaceous organs to recover themselves. Is the material burnt up—consumed by the fever—as are many of the healthy tissues?

I will say a word, in conclusion, about the retrogression or disappearance of the disease under other agencies, the more especially as the President directed attention to this part of the subject.

I will not depart from the pathological restriction which surrounds the discussions at this Society by enlarging upon therapeutical points, but it is not possible to omit some mention of them without giving an inaccurate view of the possibilities of recovery or cure which belong to lardaceous disease in different circumstances.

The fact which presents itself strikingly with increasing experience is, that this disorder, though often intractable, is by no means always so. When it comes on from syphilis recovery will sometimes occur under large doses of iodide of potassium under apparently hopeless circumstances. I have known a case in which the liver enlarged from this cause so as to reach the groin gathered itself up under iodide of potassium so as to project only two inches below the ribs. Ascites in connection with a similar organic change will sometimes diminish with remarkable rapidity under the same agency. And with regard to the kidney, though this organ when affected with lardaceous disease is much less amenable than the liver, yet it will occasionally yield to treatment in a way that a few years ago we should not have thought possible. I saw a remarkable instance of this in a case I saw three years ago with Mr. Cottle, of Savile Row. The patient, a young man, who was

suffering severely from constitutional syphilis, and had lost bone from this cause in more than one situation, was attacked with general dropsy, and his urine found to be albuminous to the extent of one half. The nature of the affection was clear, and he was treated at first with the iodide of potassium and mercury, and afterwards, as he did not bear the mercury well, with the iodides of potassium and iron. I did not expect that the kidney would right itself, but it gradually did so under long use of the remedies, and at last the patient got absolutely well. I heard from Mr. Cottle about him only a day or two ago. He is perfectly well in all respects; the urine is absolutely free from albumen, though it remained albuminous for two years.[1]

[1] The recent return of a patient from the South of France reminds me that his case may be presented as another illustration, and that a rather striking one, of recovery from albuminuria connected with lardaceous disease and that with syphilis.

A gentleman, now about forty-five years of age, had a chancre in 1861 and secondary symptoms in 1863. No further symptoms attracted notice until 1874, when he found himself suffering severely from periosteal pains, with nodes, especially on the clavicles. With these he got much emaciated and out of health, and at the end of the same year began to show decided indications of lardaceous disease; the urine became excessive, he had thirst and diarrhœa, and the legs became shapeless with œdema. The urine in the December of this year (1874) was found to be loaded with albumen, the coagulum varying from one quarter to one half.

This gentleman, who regulated his own remedies with much observation and judgment, was kept on anti-syphilitic treatment, which chiefly consisted of iodide of potassium, to nearly the limit of his capacity for it. Fifteen to twenty grains were commonly taken three times a day, together with which in the early part of his illness he took occasional short courses, or fragments of courses, of mercury, but not with much regularity, and in the later stages, iron—this with confidence and persistence. It is to be added as having contributed, perhaps importantly, to the result, that he was urged to winter in the south, and did so for four years, in the Riviera.

It was long before the renal disorder showed any signs of yielding, but after about nine months the albumen lessened to the habitual proportion of about one fifth, and slowly further diminished, until by June, 1878, it was estimated at only one fifteenth. The general symptoms were now greatly mitigated. The improvement continued through the following winter, and when the patient showed himself on his return from the Riviera, at the end of May, 1879, the secretion was so nearly natural that it was difficult to decide whether there was or was not a trace of albumen, so minute was it. There is now (June, 1879) no diarrhœa, thirst, or diuresis, nor any constitutional symptom of lardaceous or renal disease. There is no sign of cardiac hypertrophy or increased vascular tension, and the

When lardaceous disease comes on from suppuration it is more obstinate, but even in these circumstances it will frequently proceed to recovery. *Post-mortem* examination often shows us that suppuration from passing causes is sometimes associated with the smaller degrees of lardaceous change, such as could not have been discovered during life, and would probably never have made themselves apparent, had the patient lived and the suppuration not continued. But even the larger degrees of the lardaceous change may pass away, and organs swollen to the utmost resume their normal dimensions. The process, however, is slow as compared with the rapid improvement which the syphilitic cases sometimes undergo. A boy was, for many years, an habitué of the Hospital for Sick Children, under my colleague, Mr. Thomas Smith, and the subject of much judicious surgery. About nine years ago he began to discharge profusely from diseased bone belonging to the pelvis and hip-joint, and a year after began to display the visceral swelling of lardaceous disease. The liver reached half way to the umbilicus, the spleen to the crest of the ilium, the two together causing much prominence of the belly. The urine became slightly albuminous. A less hopeful prospect could scarcely have been presented than in the aspect of this boy, with his helpless prostration, his attenuated frame, and his solid abdominal swelling. But under liberal diet and general tonics he slowly mended. He then had the good fortune to become the charge of a benevolent lady and enjoyed for many years advantages, especially in frequent visits to the sea coast, which would not commonly have fallen to his lot. The result, though it took long to accomplish, may be briefly related; it amounted to his almost complete recovery. When seen two years ago he was in good apparent health. The albumen had disappeared. The spleen was still enlarged, but the liver did not transgress its normal limits. The boy was sent to school in apparently good health, and it was hoped that he would in time completely recover.[1] But I have lately learned that this hope was not to be gratified. At the end of the year 1877 he had an attack of hæmatemesis, together with a return of the dropsy; at the end of the following year he had a recurrence of the hæmorrhage, from which he never rallied.

subject of this report—he can no longer be called a patient—presents all the characteristics not only of unimpaired but redundant health (June, 1879).

[1] This case, as yet incomplete, is referred to in my book on 'Albuminuria,' 2nd edit., p. 290.

He died last December, at the age of fifteen, a year after the first vomiting of blood, eight years from the appearance of the visceral enlargements.

I could mention other instances of recovery from lardaceous disease. This event is more readily brought about when the disease is of syphilitic origin. As a rule the liver recovers faster than the spleen, the spleen faster than the kidney. In this organ the fibrosis which the lardaceous change sets up is apt to add an intractable complication.

The use of iodide of potassium where there is a specific source is of inestimable value, but so far as I have seen long persistence—for two years or more—may be needed to get its full value out of it. When suppuration without syphilis is in question this drug does not appear to be of any use. Good food and pure air, iron, cod-liver oil, and quinine are the agents of most service in such circumstances. The salts of potash alone are disappointing, though they are well borne, especially when suppuration is progressing. Liquor potassæ answers best. It may be advantageously given in combination with the cod-liver oil, or in a mixture, with tartarated iron.

It only remains for me to thank the members of the Society for the patience with which they have listened to these somewhat lengthy observations. *April 15th*, 1879.

---

## 2. *Thoughts on the nature of certain observed relations between diphtheria and milk.*

By W. H. Power, M.B.

(Communicated by George Buchanan, M.D.)

I have lately had occasion to investigate for the Local Government Board an epidemic of diphtheria affecting a large number of families in North London with the result of finding a connection between the distribution of the disease and the distribution of a particular milk. The connection was unmistakable, and far too wide and too exact to have been accidental. Defining the "cause"

of a disease as being that without which the disease would not have existed, the milk has been demonstrated, I venture to think satisfactorily, as having been the cause of the diphtheria. For the stages by which this conclusion has been reached I refer to my report on the outbreak.

In passing to consider the next question, How did the milk become capable of distributing the infection of diphtheria? I was helped by certain facts that came out as the inquiry proceeded. 1. That the "milk" referred to was the product of two businesses owned by the same person, and of two sets of cows, not of a single set; the one set being lodged at Muswell Hill, the other set at Kilburn. 2. That the potency of the "milk" to do harm had been at one time manifested by the Muswell Hill milk and not by the Kilburn milk, and at a later time had been manifested by the Kilburn milk almost to the exclusion of the Muswell Hill milk. 3. That, in short, there was good reason to believe in the transference of a morbific agency from Muswell Hill to Kilburn. These considerations led to examination in detail of the circumstances of the two businesses, with the result of showing that the surroundings of the cows at the one and the other place were remarkably distinct, but that there had been occasional transference (though the occasions were unrecorded) of the cows themselves from one place of business to the other. There arose, therefore, presumption that it was not by transference of any condition or thing external or incidental to the cow, but rather that it was by something personal (if I may so speak) to the cow or cows, that the observed transference of morbific power from Muswell Hill to Kilburn was brought about. For details under these various headings I must again refer to my report, which brings the facts respecting milk infection down to the point that some condition of the cow as cow and of her milk as milk has probably been that which has been concerned in the production of the diphtheria.

I would here make a short digression for the sake of summing up the position of our knowledge about milk epidemics generally. And first, as regards enteric fever. Of this fever, where milk is not in question, we know that it spreads habitually by means of infected water or infected air; and it is only reasonable, when milk does appear to come in question, to begin by examining whether some intervention of infected water or infected air has not been the way in which distribution by milk has been brought about. Looking critically

at the several examples of "milk-enteric" that are on record, some are found to indicate, beyond a doubt, this intervention of water or air; such are cases wherein, the more closely inquiry into details has been pressed, the more exactly have the resultant facts fitted a hypothesis of water-borne infection of milk. Other examples are found where such intervention of water or air has been obscure, but where we must admit that the phenomena of the outbreak would become readily intelligible on some hypothesis, itself likely enough, of water or air contamination. But there is a third class of cases, where the intervention of infected water or air, though it cannot be excluded, is seen to be distinctly unlikely, and where the further (beyond the point of association of the disease with the milk) exact and painstaking inquiry has been pushed, the greater has become the difficulty of explaining the infectivity of the milk by any known method of milk infection; so that those who examine such cases with most care are forced to ask themselves whether, if "milk" *per se* were able to produce enteric fever in the human subject, the observed facts would not tally better with a hypothesis of an infectiveness of milk *per se* than with the hypothesis of infection of the milk through the intervention of water or air.—Passing to scarlatina in its observed relations to milk, the first thing to be noted in the present connection is that in no instance has the intervention of infected water ever claimed to be considered; secondly, that air infection has not come in question, except as part of the question of direct human contamination of the milk; and thirdly, that, as matter of fact, the surroundings of the milk, after its secretion by the cow, have seldom sufficed to explain its infectiveness. Hence, in the recorded instances of milk-scarlatina, observers have generally had in view the possibility that cow as cow and milk as milk may really have been concerned in the production of the resulting disease in the human subject.—To go on to milk-diphtheria, we know as yet very little of its occurrence, and that little has been ascertained concomitantly, I believe, with my own investigations. Respecting it I have only to say that, so far as I know, the cases have lent no support to any hypothesis that antecedent human cases were wanted for the production of the infectious quality of the milk.

To revert to the North London diphtheria epidemic, where the phenomena of the outbreak would receive their readiest explanation, if we could believe in the existence of some condition proper to the cow herself, and capable of affecting her milk; I would observe,

first, that we already know of certain diseases in the cow capable of affecting the human subject with disease. Let us see what these are, and think, as we go along, of any parallelism these may show to each other or to the disease that we are now inquiring for. A. There is vaccinia, a disease of which we know that it is *ejusdem generis* with human smallpox; that it can be had in the cow by inoculation with smallpox matter; that it is a disease affecting but little the general health of the cow, therein differing vastly from smallpox in the human; that it has little or no tendency to spread through the air from cow to cow, here again differing altogether from its human analogue; that in its local manifestation in the cow it particularly affects the skin of the udder, but does not materially affect the quantity or quality of the milk secreted by the animal. B. There is "foot-and-mouth disease," of which we know that, in its various stages, it affects the milk secretion to a varying degree, and that it is transferable, though not readily, with the milk, under some conditions that are not well understood, to the human, giving rise to aphthous affections and disturbances of the stomach and bowels among consumers of the milk. C. Thirdly, there is miliary tubercle of the cow, of which we know that it can give tubercle to animals, perhaps including man (?), that consume milk of the affected cow. D. Again, there is an anthrax fever of oxen and cows, which has been convicted of causing malignant carbuncular disease among people who have eaten the flesh, and a throat disorder very like diphtheria among pigs that have been fed on it and on the milk. E. Once more, I would cite the case of a recognisably parasitic disease, not, indeed, that I know of, derived from the cow, yet important for our present purpose, as giving a glaring illustration of how a disease in the quadruped can be a mere ailment passing unobserved, whereas on its transference to man it produces the most serious results—trichiniasis.

I think it must be granted that, with this list of diseases before us, there would have been *primâ facie* reason for thinking whether diphtheria, affecting man as a consumer of cow's milk, might not possibly have been derived from the cow constitution itself. And the reason for thinking about it has become stronger when we note the very striking circumstantial probability, to which my recent inquiry has led me, that the North London diphtheria epidemic was concerned with some condition proper to the cow, and not with any external condition derived by the milk from the cow's surroundings,

What, let us ask, must be the properties of a disease in the cow that shall satisfy the conditions of the present problem? I pass over the question whether it is to be a "specific" disease or not, inasmuch as with our present knowledge we should have difficulty in defining specificity, and because we must admit that diphtheria being the human manifestation of the cow disease we are seeking there is the least of all occasion to dogmatise on the point.

Our cow disease must, firstly, be one that affects little the general health of the animal; and, secondly, it must be one that affects materially the quality of the milk. A moment's reference to the diseases above enumerated will show that there are cow diseases, even in the small group that are known to be communicable to man, having the one and the other of these properties separately, though there is not one that has both properties conjointly. It will be apparent that both together are most likely to be met with in some cow ailment that affects the milk apparatus itself, and I have met with one, hitherto not recognised as having any concern for milk consumers, which appears to me eminently worth observation by the student of etiological problems, and also of the careful investigation of the comparative pathologist.

"Garget" is the trivial name given by cowkeepers to disease that at times attacks milch cows, affecting the constitution of the animal but slightly, but her udder more seriously. I cannot affirm the unity of all the disease that goes by this name, but the garget described to me by various non-medical observers is characterised as follows:—Usually one or two (seldom, if ever, all four) quarters of the udder are invaded. One of the first symptoms is, it would seem, pinkness or blood-staining of milk drawn from a particular teat or teats, followed probably at next milking by a "sticky" or "mattery" admixture with the milk from these teats, and by hardness and swelling of the quarter or quarters of the udder affected. Soon the yield of milk from the affected quarters diminishes, or becomes in extreme cases altogether suppressed, though the quantity and quality of milk yielded by the sound quarters of the same udder are not materially altered. This affection of the udder lasts from one to several weeks, and does not necessarily affect to any obvious degree the health of the cow suffering from it. Another affection of the cow which appears to differ from the foregoing, but which has not yet, so far as I am aware, received a distinctive name—it would probably also be called "garget" by agriculturists—is characterised

by admixture of blood with the milk without other decided affection of the udder or of the cow. This condition, too, may, I am told, last many weeks; its cause seems to be altogether unknown.

It is perhaps necessary to add that the period of my inquiry at which I got together the above data was altogether too late for their application (except by inquiry of the owner of the businesses) to the outbreak under investigation. The owner knew garget, but was not aware of its occurrence among his cows during the period of the outbreak; none had, he said, been reported to him by the cowkeepers. In effect the impression left upon my mind, at the termination of my interview with him, was that the cows in question, or some of them, might have suffered repeatedly from any disease of the severity ascribed to "garget" without the fact of its occurrence among them necessarily coming to his knowledge.

In "garget," as here described, or in some other disease resembling it in those broad features of which a dairyman or farmer is likely to take cognisance, we seem to have a complaint in the cow that very exactly fulfils the requirements that I have defined; and one, moreover, that could have passed unobserved (unobserved, that is, by people about the cow), or have been regarded as (or even confounded with) some common-place and unimportant affection, in such a way as not to have been taken into account during dairy operations. Clearly garget is worth further study as to its possible relation to diphtheria in the consumer of cows' milk. I wish to put the matter on record with this Society, in the hope that members who have opportunity of investigating it further may be induced to do so.

*January 7th*, 1879.

---

## 3. *Garget.*

By A. H. Smee.

During the summer my friend Mr. Power, who was at the time investigating the cause of the epidemic of diphtheria at the north-west of London, told me that he had reason to believe that a particular milk supply was in some way connected with this

outbreak, but as far as he had then investigated he could not detect any cause for milk pollution after it left the cow, and that there appeared some *primâ facie* evidence of a milk pollution in the animal itself. The question, therefore, had arisen to him whether there existed any form of disease among cattle which, although capable of fouling milk, produced so little constitutional disturbance in the animal that the disease might escape the notice of dairymen. On inquiry I soon discovered that a condition of milk was known among dairy people as ropy or stringy milk, connected with a state of the udder, in some districts called garget, which did not usually seriously affect the general health of the animal in this condition. On inquiring more fully I found to my surprise that the disease had manifested itself among my own cows on more than one occasion. I afterwards discovered that at the very time I was engaged in making experiments for my book on milk some of my cows had suffered with the disease, and so little importance did my own bailiff attach to the complaint that he did not think it worth while to call my attention to the subject, or to bring me a sample of the milk, although he was collecting for me in the district the milk of diseased animals. I soon found that veterinary surgeons knew little of the subject, and that most agricultural works and works on veterinary medicine contained very little information upon the disease, as the cowmen treat the disease themselves, and frequently do not inform their own masters, because they have a belief that the disease comes on from their own ill-treatment or their carelessness in milking of the animals entrusted to their care. My own bailiff has told me that the first intimation that he has had that a cow was affected with garget was by finding upon the strainer sticky or slimy matter, which he had regarded as calling for an overhaul of the herd until he discovered the affected animal. The milk of one quarter was, he reported, sufficient to spoil the milk of four or five cows for "setting." But if the milk was used for immediate consumption he thought it was very possible that the dairyman might never discover the disease. It therefore became necessary, in investigating the cause of garget, to draw up a set of questions, which I forwarded to friends residing in different parts of England and Wales. The answers to these questions I have condensed in the following statement:

*Garget or ropy milk, or cold in udder.*

| | |
|---|---|
| 1. Cause of garget? | All observers agreed that cold and wet were predisposing causes; some added fever, over-drinking, a blow in full udder, rupture of a vein in stock-making for sale, bad milking, or other causes. |
| 2. Has particular food any tendency to produce the disease? | All but three answered in the negative; one gave change of feed —rye and tares; another grain or beans. |
| 3. Is there more than one kind of garget? | Half the observers answered only one form of true garget; the other half qualified the answer "No," unless cold, injury, and coloured milk be considered as a different form. |
| 4. Is it a frequent occurrence in cows? | Half answered uncommon; the others answered frequent; one stated it was equal to three per cent. per annum of the stock; a few farmers have never had the disease in many years' experience. |
| 5. Does it attack more than one cow in a herd? | All but two answered this question in the negative; two answered, "Very rarely." |
| 6. Can a cow have the disease more than once? | Answered for the most part in the affirmative; two or three stated that they always fattened the cows, and therefore could not say. |
| 7. Has the age of cow any influence on the liability of cow to attack? | "Young cows," by one observer; the rest negative. |
| 8. What time of year is it most common? | It appears that it is not affected by the time of year; most prevalent however, during cold, wet seasons, and when cows first turned out. |
| 9. Is garget contagious? | All answered that it is not contagious. |
| 10. What are the symptoms of garget? | Tenderness in udder, suppression in quantity of milk, inflammation |

of udder, milk thick and discoloured; one added, loss of appetite; another, glands in jaw and neck affected, coat harsh and staring.

11. Does it affect the general health of cow?

Some answered "Yes," others "No." One stated it was followed by loss of power on affected side, another, if neglected, gave rise to cancer.

12. How many days does the disease last?

This question was answered variously, from two to six days to two to twelve weeks.

13. Number of quarters, and which commonly affected?

Generally one, sometimes two, rarely all four; hind quarters most prone to the disease.

14. How does it affect the milk during its various stages?

First, thick, discoloured, then bloody, afterwards stringy, becomes ropy, then watery.

15. How soon does it affect the milk?

This question was answered, "At once," except by one observer, who states two or three days, but an unprofessional man would not recognise the disease until shown by the milk.

16. Do the affected quarters dry off?

All agree if disease lasts affected quarter dries off if taken care of; some state milk returns again.

17. Do the affected quarters again yield milk when the cow recovers?

Rarely; usually dry off to next calving; sometimes quarter permanently lost.

18. Is milk from unaffected quarters altered?

One answered "Yes," the rest "No."

If milk from affected quarter is added to other milk:—

19. Does it affect its keeping?

Yes, it is no good; ought to be thrown away; cannot say milk is thrown away.

20. Does it affect the health

Four answered in the affirmative,

| | |
|---|---|
| of calves if fed upon it? | four in the negative; those who answered in the affirmative stated that calves became poor and thin, and scoured them. |
| 21. Does it affect its capacity for butter-making? | All agreed it could not be used for butter-making. |
| 22. Does it affect its capacity for cheese-making? | All agreed it could not be used for cheese-making; one stated it separates and goes to the bottom of the vessel; in setting the curd it will not mix. |
| 23. Are the cows kept for rearing calves, butter- or cheese-making, or for a milk business? | Observers kept the cows for butter- and cheese-making, milk business, and rearing of calves. |
| 24. Are the cows kept on high-land or low-land pastures, or are they stall fed? | Neither high nor low pastures nor stall feed appeared to have any influence on the disease. |
| 25. What breed of cows in the herd? | Various breeds. |
| 26. Is it ever fatal? | Sometimes it appears to be fatal, if neglected, by rupture of the udder, or by neglecting to empty the affected quarter during the progress of the disease. |

It is obvious, from the above statement, that under the generic name of garget there exists certainly more than one disease.

*First.* A garget is referred to traumatic origin arising from injury to udder, from blows, poke with horn, lying upon it, rupture of a vein in stock-making (that is, leaving milk in the udder for twenty-four to forty-eight hours, for the purpose of enhancing the value of a cow for sale). I think the largest number of ropy milks arise from this cause. I have reason to think that it is from this cause alone that garget was produced in my own cows, as the complaint only appeared during the time I had a particular cowman in my service and has not again appeared since he left. Calves fed upon the milk of this kind of garget do not appear to be affected in general health. My bailiff has always put the calf to suck the diseased quarter without an ill-effect to the animal.

*Secondly.* A form of garget produced by cold, which runs an acute course. It does not appear to affect the general health of the animal or the health of pigs or calves which may be fed with the milk.

*Thirdly.* A form which occurs less frequently, and is possibly of a specific nature. This form not only appears to affect the general health of the animal, as in the case of the cow which had loss of power on side of affected quarter, and the cow which had staring coat, loss of appetite, and glands of jaw and neck affected, but it also seems to affect the milk in such a way that it may injure the health of calves, scouring them and causing them to waste away.

The following is the analysis of milk of a cow stated to have ruptured a vein in stock-making. The sample was taken from a cow that had suffered from bloody milk for six weeks.

Milk from affected quarter gives the following:

| | |
|---|---|
| Total solids | 11·97 |
| Fat | 2·95 |
| Non-fatty solids | 9·02 |
| Ash | 0·62 |

It will be seen that although the milk was distinctly coloured it differed little from normal milk; no blood-cells could be recognised by examination with the microscope. The light brown or reddish tint of the whey was due to an indefinite particle of brown matter, the nature of which was not made out.

By the kindness of Dr. Jacob I had an opportunity of examining a specimen of milk from a cow that had been attacked by some form or other of garget, which yielded on analysis:

| | |
|---|---|
| Total solids | 11·7 per cent. |
| Fat | 2·5 „ |
| Non-fatty solids | 9·2 „ |
| Ash | 0·76 „ |

A very thorough search with the microscope did not reveal anything abnormal, and from the above composition it is evident that this milk would have been passed as good milk by a public analyst. It is important, however, to note that the cow from which the specimen was taken was recovering from the attack, and that an acute stage, in which the milk really had been altered, may have been

passed through, before the time that this particular sample was taken from the cow. It is a coincidence of great apparent importance, upon which I leave Dr. Jacob to write, but at the time diphtheria broke out in the Princess Mary Homes at Woking this garget existed in the farm which supplied the Home with milk.

It is hardly necessary for me to point out that the chain of evidence connecting garget with diphtheria is at present altogether incomplete, yet I venture to think that the provable use of diseased milk is a point worthy of considerable attention in the investigation of future outbreaks of diphtheria.

Considering the universal employment of milk as an article of food by all classes of society I have thought it desirable at once to bring under the notice of this Society my researches on garget, because a thorough investigation of milk in disease would, I venture to believe, reveal many facts of importance to the health of the human subject.

It is, however, an investigation that would be surrounded with great difficulties. It would require many observations to be made in different localities under varied circumstances, besides requiring the expenditure of much time, scientific skill, and money.

A thorough investigation would be far beyond the means of any private individual, perhaps beyond the resources even of our scientific societies, and the subject promises, I think, to be one of sufficient importance to deserve inquiry by Government.

*January 7th*, 1879.

---

## 4. *On the relation of organisms to antiseptic dressings.*

By W. Watson Cheyne, M.B.

The antiseptic treatment of wounds, as introduced by Mr. Lister fifteen years ago, was based on three distinct hypotheses, which may be shortly stated as follows:

1. The local inflammatory processes and the general febrile disturbances which follow wounds are, in the main, due to alteration in, to putrefaction of, the discharges of these wounds.

2. This putrefaction of the discharge is brought about by the growth of organisms (schizomycetes) in it.

3. These organisms do not develope spontaneously, and they must therefore gain access to the wound from the outer world.

With regard to the first and last of these theories a great mass of evidence has been accumulated, and they are now very generally accepted. The view, however, according to which the lower organisms are looked upon as the causes of putrefaction in fluids is still much disputed, many observers regarding the bacteria constantly present as simply accidental accompaniments of the chemical changes. Nevertheless, several facts have of late years been brought forward which render the former supposition probable. Thus, Pasteur has demonstrated that the fermentation of saccharine solutions is due to the growth in them of the yeast plant, and the same observer has shown that the butyric fermentation[1] is dependent on the development of bacteria. Cohn has further drawn attention to the relation between certain forms of schizomycetes and the development of special pigments.[2] And one of the most absolute pieces of evidence on this subject was brought before this Society last year by Mr. Lister,[3] who showed that the lactic fermentation of milk was caused by the development in it of bacteria of a distinct and recognisable form.

Among the facts in favour of this view might further be included the results of the antiseptic experiment itself. In this the chief attention of the surgeon is concentrated on taking all conceivable precautions to prevent the entrance of organisms to wounds from without, and, as the result of experience, it is found that where the precautions theoretically required are rigorously carried out decomposition of the discharges of a wound is avoided, while where the precautions taken are less stringent putrefaction occurs. A piece of evidence necessary in order to render this experiment of value for either view is, however, as yet wanting, viz. an investigation as to whether organisms[4] are present or absent in the discharges from wounds so treated.

The first communication on this subject was made five years ago by

[1] 'Comptes Rendus,' Tome 52, and Études sur la Bière.

[2] 'Beiträge zur Biologie der Pflanzen,' Bd. i, 1875.

[3] 'Transactions of the Pathological Society,' 1878.

[4] I mean by the term "organisms" the group of bodies termed by Nægeli "schizomycetes," by Cohn "schizophytes," by Sanderson "microzymes."

Dr. Ranke, of Halle.[1] He published a note of some 300 examinations of the discharge from fifteen wounds treated antiseptically and following an aseptic course, in which he states that on only one occasion did he fail to find organisms. The organisms present were for the most part micrococci in pairs, also streptococcos, rarely small or middle-sized bacteria. He therefore believes that the growth of coccobacteria septica does not sufficiently explain the etiology of septic diseases.

While by some these observations have been received as accurate and as confirming their previously formed views, by many they have been looked upon as erroneous, either from having been made on cases in which the antiseptic treatment had been imperfectly carried out, or in themselves faulty. In answer to objections of the former nature, urged by Professor Klebs of Prague,[2] Dr. Ranke published another paper in July, 1876,[3] quoting cases to show that the treatment had been in reality properly conducted. He instances especially cases of hydrocele, treated by making a small incision into the sac, stitching it to the skin, and treating antiseptically, where cure followed without any inflammation or constitutional disturbance, but where, nevertheless, organisms were present in the discharges. From those cases, as well as from the various published reports of the results of Professor Volkmann's practice, there seems no reason for doubting that the observations were made on wounds treated with all due precautions, and following a course similar to that which Mr. Lister himself would expect.

About the same time Demarquay published the results of eight cases treated "antiseptically," in all of which organisms were found.[4] The general course of the wounds so treated, as described by the author, and the fact that one of the eight cases died of pyæmia, show that the antiseptic treatment had not been carried out with sufficient care.

Two years later there appeared in the 'Deutsche Zeitschrift für Chirurgie' a paper by Dr. Fischer,[5] giving the result of investigations carried on in Professor Lücke's wards in Strasburg. He employed chemical tests, as recommended by Von Recklinghausen,

[1] 'Chirurgische Centralblatt,' No. 13, 1874.

[2] 'Archiv für Experimentelle Pathologie,' Bd. iii, p. 315.

[3] 'Deutsche Zeitschrift für Chirurgie,' Bd. vii, p. 63.

[4] 'Comptes Rendus,' 1874.

[5] 'Deutsche Zeitschrift,' Bd. vi, p. 320.

and found organisms in all his cases. He, however, states that bacteria were not unfrequently present, his results in this respect differing from those of Dr. Ranke. Now, it so happens, that I spent the summer of 1876 in Strasburg, and thus had frequent opportunities of seeing the "antiseptic" practice in that hospital, and I can only say that I was not surprised to hear that bacteria were present in the wounds there treated.

The last paper on this subject was published by Dr. Schüller in the spring of 1877.[1] In his investigations cultivation experiments were employed. He found that in many cases organisms are absent both from the discharge and from the cultivating fluid, whilst in others their presence was shown by the increasing turbidity of that liquid.

His results, although much more definite than those previously published, are nevertheless somewhat contradictory, and are open to several objections.

Thus, in the first place the cultivating fluid used was what is known as Bergmann's fluid, a liquid by no means the most favorable for the development of organisms. Indeed, many forms refuse to grow in it at all.

Further, the antiseptic employed in the treatment of his cases was salicylic acid, which has not been found to yield such good results as carbolic acid.

Lastly, the method of inoculation employed was faulty. In order to make the inoculation the edge of the dressing was lifted so as to expose the drainage tube, no spray being used. Now, as the result of this, in an hospital atmosphere, error might arise in two ways: either organisms might gain access to the wound, develope there, and be obtained at the next inoculation; or dust might fall into the flask during the momentary exposure.

When I became Mr. Lister's house-surgeon in 1876 I resolved to take advantage of my opportunities to investigate this matter carefully. My wish was heartily seconded by Mr. Lister, and since that time he has placed all his cases unreservedly at my disposal for examination.

I began by making microscopical examinations of the discharge from wounds, using at the same time reagents, more especially acetic acid and glycerine, as recommended by Professor Von Recklinghausen. From such observations, continued daily for several

[1] 'Deutsche Zeitschrift,' Bd. vii.

months, I arrived at the conclusion that *bacteria* are not present in the discharge from wounds treated antiseptically. To determine the presence or absence of *micrococci* was, however, much more difficult. The discharge from a case treated antiseptically differs very markedly from that obtained where other treatment has been adopted. Leucocytes are generally absent, or, if present, are very granular, apparently undergoing degeneration. There is also a very large quantity of granular matter, probably derived from degenerated pus-cells, or portions of fibrine rubbed off from the surface of organising blood-clots. To affirm or deny the presence of micrococci in such a fluid is a matter of extreme difficulty, and, even now, I would not be bold enough, without having employed other methods of investigation, to express an opinion in many cases (see fig. 6).

Accordingly, in January, 1877, I commenced a series of inoculation experiments, transferring the discharge from wounds into flasks containing fluid highly nutritive to the various forms of organisms. The fluid which I first employed, and which I still use at times, was milk. This, however, from its tendency to froth when boiled, is troublesome to prepare pure, and as it does not possess many of the advantages of clear fluids, I looked about for some equally good transparent cultivating liquid. I tried Pasteur's and Cohn's fluids, and, after reading Schüller's paper, Bergmann's, but I found them too insensitive to be of any value for my purpose. I then used vegetable infusions, more especially turnip, which I found to answer very well; but I ultimately adopted infusion of cucumber, which seems to be as sensitive as milk, and in which I have never yet found any organism refuse to grow. I also, in many cases, employ as additional test solutions milk and infusion of meat.

To prepare the infusion a cucumber is sliced, placed in water, and infused for about four hours, till a specific gravity of about 1003 is attained. This fluid is then filtered, introduced by siphon into flasks previously purified by Mr. Lister's method,[1] boiled for twenty minutes, kept for some days (at least two) in an incubator, and then decanted under a spray of carbolic acid into smaller purified flasks, which are likewise placed in an incubator for several days before being used.

For the purpose of inoculation small capillary tubes, such as those used for vaccination, are employed. These possess the ad-

[1] Loc. cit.

vantage over needles in that, while they take up a larger quantity of the discharge, they protect it from the carbolic acid of the spray during the transit from the wound to the flask. The tubes are dropped into the flask containing the cucumber, and this is then placed in an incubator kept at the temperature of the human body.

The procedure may be shortly described as follows :—The outer portion of the dressing having been removed under the carbolic spray, a tube, which has been previously purified in carbolic lotion, is heated in the flame of a spirit lamp in the spray, so as to drive off all the carbolic lotion and to render it dry. This tube is now rapidly introduced into the drainage tube, and from thence immediately into the flask, which is opened in the spray close to the wound. The flask is then placed in an incubator kept constantly at a temperature of 98° F. Where flasks with cotton caps are used it is well to wet the margin of the cap with carbolic lotion before lifting it, so as to prevent any dust from falling from the cap into the fluid.

Before proceeding to the experiments I tested this method, and found it perfectly trustworthy. Thus, whenever I inoculated flasks in this manner from a fluid containing bacteria, I got bacteria ; when, on the other hand, I inoculated from a pure fluid, the fluid in the flask remained pure, this fluid at a later period rapidly becoming the seat of development of organisms when these were introduced into it.

In performing these experiments I always inoculated two flasks, and often another was taken and the whole process gone through in the same place, with this difference, that the tube in the latter case, when heated, was put directly into the flask without touching the wound. These latter flasks remained, without exception, clear.

When development occurs in the flasks inoculated they generally become muddy in thirty to fifty hours, but, where the fluids remained clear, I have kept them in the incubator for weeks, and then tested them by the addition of fluid containing bacteria.

As a result, I find that in cases treated antiseptically, where, of course, there was an unbroken skin to start with, one of two things may happen—either the fluid remains perfectly clear, without the development of organisms showing that none were present in the wound, or the fluid becomes turbid from the presence in it of organisms of the form shown in fig. 2. In both cases the wound follows an aseptic course, *i. e.* no local or constitutional dis-

turbance results from the operation, and, from the appearance of the wound, one could not tell in many cases whether these organisms were present or absent.[1] These organisms are minute spherical

WOODCUT 18.




Fig. 1 is copied from Mr. Lister's paper on "The Germ Theory of Putrefaction and other Fermentative Changes," in the 'Transactions of the Royal Society of Edinburgh,' vol. xxvii, 1875, and represents the growth of micrococci as seen under the microscope.

Fig. 2. Micrococci from a wound treated antiseptically, growing in cucumber infusion.

Fig. 3. Micrococci growing in cucumber infusion containing carbolic acid.

Figs. 4 and 5. Forms of bacteria injected into animals, causing death.

Fig. 6. Drawing of the discharge from a wound treated antiseptically.

Fig. 7. Ordinary forms of organisms which may grow in cucumber infusion inoculated from wounds not treated antiseptically.

(Figs. 2—7 are represented as seen with Hartnack's powers magnifying 920 times linear.)

---

[1] Those who have worked long at antiseptic surgery will have met with cases where, when a dressing is left on for six or seven days, or when a deep dressing is left on for some weeks, the discharge has a sour odour and the skin around is somewhat excoriated. As the wound in other respects follows an aseptic course, Mr. Lister concluded that this was probably a chemical change taking place between the discharge and the gauze dressing. Knowing the peculiar property possessed by salicylic acid of preventing chemical fermentations, Mr. Lister uses it in such cases with the effect of diminishing or preventing this change.

bodies, arranged in pairs, short chains, or groups of smaller or larger size; in fact, they belong to the division of schizomycetes termed *micrococci*.

If now we contrast these results with those obtained in wounds not treated strictly antiseptically we find this marked difference—that in none of the latter were organisms absent, while in almost all *bacteria* as well as micrococci were present. Fig. 3 represents some of the most common forms of organisms found. It is to be observed that in many of these cases antiseptics were employed, both externally and injected into the wound, but no precautions were taken, either to penetrate all the recesses of the wound with the antiseptic so injected, or to prevent the access of organisms during or after the dressings.

I may mention that in four cases which were originally treated antiseptically *bacteria* were found, but in all their presence was indicated by disagreeable smell or by symptoms of local or constitutional disturbance. One of these patients was a man with psoas abscess, who was in a very weak state on admission. He suffered so much from absorption of carbolic acid that the dressings were made smaller than usual, and were left on much longer than would have otherwise been the case, on some occasions even for thirty-six hours after the discharge had appeared at the edge. Thus, it is not surprising that putrefaction should have occurred. Here the admission of bacteria was followed by foul smell of the discharge, profuse suppuration, hectic fever, and death. It is thus evident that bacteria as well as micrococci can flourish under an antiseptic dressing. The explanation of their absence must therefore be that the circumstances which permit of the entrance of micrococci are not such as to allow the advent of bacteria.

But, it may be said, there is no specific difference between micrococci and bacteria; the micrococci found in aseptic cases are

In these instances I have always found micrococci.

If micrococci be grown in about three drachms of cucumber fluid, after three days they seem to die; at any rate, they will not grow in any liquid. But yet if the fluid be kept for some weeks it will gradually become red, till it ultimately is of a dark vermilion tint. Thus chemical changes continue after the activity of the organism has ceased. May not something of the kind occur in these cases? Chemical changes are primarily set agoing by these organisms, but continue of themselves, and thus salicylic acid acts by preventing these changes, as Mr. Lister supposed, though, according to this view, the organisms are necessary for their commencement,

simply bacteria altered in form by the new conditions in which they are placed. Professor Billroth, indeed, has gone so far as to assert that there is only one species of organism—coccos—in the group of schizomycetes that this may under varying circumstances assume the form of bacterium or coccos, these two being transmutable into each other.[1] That micrococcos is an organism distinct from bacterium is also denied by Hallier[2] and doubted by Klebs,[3] while it is strongly affirmed by Cohn,[4] Rindfleisch,[5] and others.

During the long time that I have observed these organisms I have never met with any instance in which a micrococcos has become a bacterium, or *vice versâ;* indeed, my work has furnished me with decided evidence to the contrary. It will be more convenient, however, if the summing up of this evidence be left till the end of the paper. In the mean time, in order that it may be clearly understood what I mean by micrococci, I will describe them, following, for the most part, Cohn's definition, as follows:—Colourless or coloured round cells, very small, generally under one mikrometer in size, with or without movement, growing from pairs into short chains or groups of smaller or larger size, not derived from bacteria, nor developing into them. Other living spherical bodies may be found in cultivating fluids, such as spores of fungi, or, indeed, of some forms of bacteria as pointed out by Koch[6] and Ewart;[7] these, however, when fresh nutriment is added, develop again into fungi, on the one hand, and bacteria on the other. The life-history of micrococcos seems only to consist in development from pairs to short chains or groups of larger or smaller size, this cycle being repeated on the addition of fresh pabulum.

The characteristic method of grouping is shown in fig. 2, and better in fig. 3. The irregularity of the chains and the rapid formation of groups is attributed by Cohn[8] to softness of the intercellular substance allowing the individual bodies to be displaced, their division, according to him, taking place only in one direction

[1] Coccobacteria septica.
[2] 'Parasitologische Untersuchungen,' 1878, p. 67.
[3] 'Archiv für Experim. Pathol. u. Pharm.,' Bd. i, 1873.
[4] Loc. cit.
[5] 'Virchow's Archiv,' Bd. liv.
[6] 'Beiträge zur Biologie der Pflanzen,' Bd. ii, 1876.
[7] 'Microscopical Journal,' vol. xviii.
[8] Loc. cit.

(transversely to the long axis of a chain). Another and more probable view has been put forward by Mr. Lister.[1] In performing some experiments on the germ theory of putrefaction his room became infested with a minute organism which he termed granuligera, which in reality belongs to the group "micrococcos" as above defined. He studied the development of these organisms, and a copy of his drawings is here shown (fig. 1). According to his observations, the irregularity of the chains and the formation of groups is due to the fact that the cells divide not only transversely, but longitudinally; indeed, in one instance he observed both modes of division going on in the same cell. I have made several attempts to observe the growth of these bodies on the hot stage, but their dancing motion is so great that I have found it impossible to do so. By examining them, however, at various periods of growth, their method of grouping seems to me strongly confirmatory of Mr. Lister's view, and more especially is this apparent when they are grown in fluid containing carbolic acid.

Micrococci grows luxuriantly in cucumber and turnip infusions. In meat infusion they attain a larger size than in other fluids. In milk they produce but little change as regards smell and taste; the milk, however, separates into two parts, an upper clear fluid, and a lower white granular deposit.

Micrococci which have grown at a high temperature will not develope when inoculated into a flask kept at a much lower temperature. Thus, micrococci from a wound, the temperature of which is 98° F., will not grow if placed in an incubator kept below 80° F.

Tiegel has pointed out that if a fluid containing organisms be made strongly alkaline with carbonate of soda *bacteria* quickly disappear, only a few micrococci remaining, which also ultimately vanish.[2]

Koch finds by the use of his new method of investigation that, while micrococci stain with hæmatoxylin, bacteria do not.[3]

Micrococci when acted on by a strongly peptic solution at the temperature of the human body remain unaffected, in contrast to ordinary albuminous granular matter which soon disappears. Many

[1] 'Transactions of the Royal Society of Edinburgh,' vol. xxvii, 1875.

[2] 'Virchow's Archiv,' Bd. lx.

[3] 'Untersuchungen über die Ætiologie der Wundinfectionskrankheiten,' Leipzig, 1878.

forms of *bacteria* similarly treated become aggregated into clumps, or may, for the most part, disappear, only a few irregular rods and granules remaining.

We must now approach the consideration of the questions which necessarily arise in connection with the presence of these organisms under antiseptic dressings, and the first which presents itself is—How is it, if organisms are the causes of many of the evils consequent on wounds, that the cases in which these micrococci are present do not apparently differ from those from which all organisms are absent?

In answer to this question it is to be observed that we have here to deal with a well-marked and distinct group of organisms. When grown in cultivating liquids, be it milk, meat, or cucumber, but little alteration is produced. There is slight increase of acidity, very faint, sour odour, but only slight alteration in taste. And so when they grow in wounds they produce no smell in the discharge nor symptoms of local irritation, showing that the products of their growth are not acrid, for it will be admitted that any chemical irritant present in a wound would give rise to more or less inflammatory symptoms. Nor are their products, absorbed into the circulation, poisonous. In these points they present a marked contrast to the ordinary forms of *bacteria*. These, when cultivated in a suitable fluid, produce more or less alteration in it; the fluid becomes acrid, disagreeable to the taste, and it may be foul smelling; and, thus, when they gain admission to a wound, their presence is announced by the development of disagreeable odour, or by symptoms of irritation about the wound, or of constitutional disturbance showing that chemical substances of a more or less acrid or poisonous nature are present in the discharges.

But, when we come to look into the literature on this subject, we find that by many micrococci are regarded as the causes of important, more especially septic, diseases. Thus Oertel, in his paper on diphtheria, designates as micrococci[1] the organisms to which he ascribes the production of this disease. He, however, adopts Hallier's views and accordingly, in the figures which he gives, well-marked bacteria of various forms are grouped together with micrococci proper under the one comprehensive term of micrococcos, and I can see nothing in his paper to lead one to suppose that the round bodies rather than the rods are the cause of the

[1] 'Deutsches Archiv für Klinische Medicin,' Bd. viii.

disease. In the diphtheria of wounds Hueter had previously discovered organisms in the tissues and in the blood, and he likewise calls them micrococci (monads).[1] Again, by Hueter,[2] Recklinghausen,[3] Lukomsky,[3] and others the margin of the erysipelatous blush is said to contain micrococci, which are regarded by them as the causes of the disease. Similar views are entertained by Recklinghausen,[4] Nassiloff,[4] Eberth,[5] &c., as to the so-called diphtheritic inflammation of the cornea, produced by the inoculation of putrid fluids on it. Orth[6] also has found micrococci in the peritoneal fluid in puerperal peritonitis, and, in connection with the subject of septic diseases, Birch Hirschfeld[7] thinks that, though bacteria may be important factors in these affections, yet the essential *rôle* is played by micrococci. Further, a form of endocarditis has been described by several observers as Heiberg,[8] Eberth,[9] &c., in which micrococci are said to be present in the ulcers on the valves, and this disease has, therefore, received the name of micrococcal endocarditis. And, lastly, may be mentioned the views of Birch Hirschfeld,[10] who finds, as the result of experience, that, where micrococci are present in wounds, these generally assume an unhealthy appearance. In none of these cases, however, is the evidence sufficient to show that *micrococci* rather than *bacteria* are the cause of the diseases, nor to show that the micrococci may not have been accidental, as indeed, as I shall presently point out, is not unlikely to have been the case.

Now, in order to test this matter with the micrococci at my disposal, Mr. Gerald Yeo has kindly performed some experiments for me. In the first experiment seven cubic centimètres of cucumber infusion, in which micrococci were present and calculated to be at least as numerous as two millions per minim, were injected into the jugular vein of a rabbit, while, at the same time, into another rabbit 6 c. c. of cucumber fluid containing bacteria of the form

[1] 'Medicinische Centralblatt,' No. 12, 1868.
[2] 'Allgemeine Chirurgie,' 1873.
[3] 'Virchow's Archiv,' Bd. lx, p. 418.
[4] Ibid., Bd. l.
[5] 'Zur Kenntniss der Bakterische Mycosen,' 1872.
[6] 'Virchow's Archiv,' Bd. lviii, p. 437.
[7] 'Archiv der Heilkunde,' xiv, 1873.
[8] 'Virchow's Archiv,' Bd. lvi, p. 407.
[9] Ibid., Bd. lvii, p. 228.
[10] 'Schmidt's Jahrbuch,' vol. clxvi, p. 190.

shown in fig. 4, were introduced. The first rabbit was quite unaffected by the injection, it took its food as usual, its temperature never varied, and it did not lose flesh. The second rabbit was very ill on the following day, it would not take its food, and its temperature was only 100°. (The temperature before the injection was 102°.) On the second day its temperature was 98°; it had diarrhœa, and was rapidly losing flesh. On the evening of the 4th day it died, its temperature during the forenoon having been 92°. Similar experiments have been performed six times with micrococci from aseptic wounds and, for comparison, with different forms of bacteria. In each case 2½ c. c. of cucumber infusion containing respectively micrococci and bacteria of the same age were used. In none of the animals into which *micrococci* were injected were any effects produced, while all of those which were treated with *bacteria* died.

But not only are micrococci obtained from aseptic wounds harmless, micrococci got from the air, from tap water, from unopened abscesses, indeed, from rabbits themselves by methods to be later explained, have proved in like manner innocuous. Nor do they, when inoculated on the cornea, or injected into the subcutaneous cellular tissue of a healthy animal, produce any of the inflammatory processes which so frequently follow the use of many forms of bacteria.

We must, therefore, conclude that the ordinary forms of micrococci are harmless, and that the reason why no symptoms are produced in the cases in which they occur is, that the products of their growth are not chemically irritating or poisonous. But I must guard against making too absolute a statement. There are no doubt many forms of micrococci. This is evident from the fact that some forms have the special property of producing pigment, and of these there are different kinds producing different pigments. Koch also has in his recent beautiful work brought forward strong evidence to show that pyæmia in the rabbit is due to the development of micrococci in the blood.[1] Certain it is that, if forms of micrococci are hurtful, these are rare in the surrounding world, and that the conditions which allow of the admission of the ordinary forms to wounds treated antiseptically are not such as permit the entrance of the hurtful kinds.

But why do *micrococci* and not *bacteria* gain access to wounds

[1] Loc. cit., p. 54.

treated antiseptically? How is it that organisms of any kind are found in the discharge from aseptic cases?

These two questions must be considered together, and in answer to the latter three possible hypotheses may be put forward, and must be individually dealt with.

1. The organisms gain access to the wound through the body, being carried to it in the circulating blood.

2. They enter the wound through some loophole in the antiseptic method, or through faulty application of it.

3. They arise in the wound by a process of spontaneous generation.

In considering the first view we are at once met by the question —Do organisms occur normally in the blood or tissues of the healthy living body?

Many of the members of this Society may remember that Dr. Burdon Sanderson, in his lectures at the University of London last year,[1] referred to experiments lately performed by Tiegel[2] and Billroth.[3] These observers found that, on rapidly removing portions of various organs from a newly killed animal, and dropping them into melted paraffin, bacteria developed in these organs in a few days. They therefore concluded that organisms capable of development are normally present in many of the tissues of healthy living beings. Dr. Sanderson further stated that he had repeated these experiments more carefully, and had obtained similar results.

In investigating this subject I have made use of a totally different method. A number of beakers are prepared, each containing a quantity of pure cucumber infusion. The hair of the abdomen of the animal, rabbit or cat, having been well soaked with 1-20 carbolic acid lotion, the creature is killed by a blow on the back of the neck, and its abdominal cavity quickly opened under a distant spray of carbolic acid. Portions of various organs—liver, spleen, kidney, pancreas, muscle, heart with its contained blood, are rapidly cut out with pure instruments, and transferred to the beakers containing the cucumber. The latter are then placed in an incubator.

The rationale of the method is as follows: The organs are removed without any possibility of external contamination. They are put into flasks carefully purified, as is further certified by the

[1] 'British Med. Journal,' Jan. 26th, 1878.

[2] 'Virchow's Archiv,' Bd. lxix.

[3] 'Coccobacteria septica.'

fact that the cucumber infusion which they contain has remained pure, although they have been kept for some time in an incubator. This cucumber fluid keeps the tissue moist and prevents the drying which would otherwise take place. Further, it is itself an extremely favorable medium for the growth of organisms, and therefore these, if present, would in all probability develope in it. This fluid, in which the organs lie, is not, however, merely pure cucumber infusion, it is also an infusion of meat, thus consisting of a combination in the highest degree putrescible. The extremely minute quantity of carbolic acid which gains access to the organs is not sufficient to have any effect in retarding development. This will be quite evident presently.

In order to test these beakers, and thus be absolutely certain as to the presence or absence of organisms, I inoculate from them at various periods flasks containing cucumber infusion. If organisms are present in the beakers they will develope in these flasks; if they are not, the fluid will remain unaltered.

As the result of this method of investigation, now carried out in many cases, I find that organisms do not occur in the blood or tissues of the healthy living body.

But, you say, the method may not be correct; organisms may be present and yet not be able to develop. The following facts, will, however, sufficiently answer this objection. If in removing the liver I wound the gall-bladder bacteria develope in the beakers. If the manipulations are imperfectly carried out organisms appear. Thus, in one of the first experiments, performed in December, 1877, I allowed one of the organs to touch the outside of the beaker. In this vessel bacteria developed. If micrococci in sufficient quantity be injected into a rabbit, and the animal killed, say in half an hour, or even in twenty-four hours, micrococci, and these alone, will develope in the beakers and in the flasks. In the same manner if bacteria in sufficient quantity be injected into the animal they will be obtained from the organs, and apparently of the same kind as those introduced. Here no micrococci are found. Thus where micrococci are introduced they are obtained; where bacteria are injected they in like manner develope; where the organs of an animal into which neither micrococci nor bacteria have been artificially introduced, and which is in a healthy condition, are tested in the manner described, no organisms are found. Therefore organisms are not present in the blood or tissues of the *healthy* living animal.

Further evidence in favour of the utility of this method will be immediately forthcoming.

This assertion does not rest on my own unsupported testimony. That the fluids of the body do not contain organisms has been shown by various observers. Their absence from the blood has been proved by the experiments of Professor Klebs,[1] of Mr. Lister,[2] and of Dr. Burdon Sanderson.[3] That the urine is sterile is evident from the researches of Mr. Lister[4] and M. Pasteur. The same thing has been demonstrated, as regards milk, by Mr. Lister.[5] The existence of organisms in the healthy animal is also denied by Koch[6] in his recent work; and, finally, by removing the organs of rabbits antiseptically, and wrapping them in gauze or placing them in calcined beakers, Chiene and Ewart have come to a similar conclusion.[7] And if we examine Dr. Tiegel's method more carefully we find many objections to it. The most important has already been answered by Tiegel. It is this; when the knife cuts soft tissues such as the liver, the vessels are emptied of their blood by its pressure, and, after it has passed through, they must become filled with air.[8] Tiegel acknowledges the force of this objection, and says that the cases to which it would not apply are the kidneys and salivary glands.[9] But it is just in these organs that he gets negative results: "was indessen durch ganz andere Umstände bedingt sein kann." What the other circumstances are he does not state. Indeed, the only case in which he found organisms in all the organs of the same animal was in a dog, where, twenty-four hours before death, the abdomen had been opened, and the intestine ligatured in two places. But surely Dr. Tiegel does not mean to say that this was a *healthy* animal? Here, indeed, I think it not improbable that the organisms thus found were present in the organs before death.

[1] Loc. cit.

[2] 'Quarterly Journal of Microscopical Science,' April, 1878.

[3] Ibid., vol. xi, 1878.

[4] 'Transactions of the Royal Society of Edinburgh,' 1875.

[5] 'Transactions of the Pathological Society,' 1878.

[6] Loc. cit.

[7] 'Journal of Anatomy and Physiology,' April, 1878.

[8] Klebs, loc. cit.

[9] In removing the kidney, for example, Dr. Tiegel places a ligature around the pedicle close to the hilus, and the vessels are then divided beyond this constriction. The substance of the organ is thus not cut into.

When, however, we come to examine animals *suffering from disease* we find that in certain cases organisms capable of development may be present in the blood and tissues. The determination of the conditions in which this occurs is a matter of the greatest importance, and therefore I do not intend to do more to-night than to mention one or two points which are necessary to complete this paper.

If an acute inflammatory process be induced in an animal, say by the subcutaneous injection of ammonia, as pointed out some years ago by Dr. Burdon Sanderson,[1] the organs examined by the method I have described may be found to contain organisms; I say "may," for organisms are not always present.

If, again, the nutrition of an animal be profoundly interfered with, as in slow poisoning by phosphorus, organisms will after some time be found in the blood and tissues. Here, it may be said, inflammation of the intestinal tract has been caused, and the epithelial barrier against the entrance of organisms has been removed. But the blood and tissues, when in a healthy state, have the power of themselves of destroying organisms when these are introduced into the body. Thus if into the veins of four medium-sized rabbits $\frac{1}{4}$, $\frac{1}{2}$, $\frac{3}{4}$, and 1 c. cm. respectively of ordinary bacterial fluid be introduced, and the animals be kept alive for twenty-four hours, and then killed and their organs preserved, in the first three no organisms will be found, while in the last they may or may not be present. Where larger quantities of the fluid have been introduced they will certainly be found. Thus, even though the organisms could gain access to the blood, yet, so long as the nutrition of the animal is fairly well carried out, they would be destroyed. The reason that they are found where large quantities of bacterial fluid are injected seems to be that along with the bacteria their products are introduced, that these act in the same way as phosphorus, as poisons, and that thus the resisting power of the animal is diminished. In like manner, if sepsin be so prepared and introduced as to avoid the introduction of organisms along with it, organisms will nevertheless be found in the internal organs.

In other words, in severe inflammatory processes, or in great interference with the nutrition of an animal, organisms may pass into the blood without losing their vitality. The organisms usually found are micrococci.

[1] 'Medico-Chirurgical Transactions,' 1873.

In investigating this point in man, I have confined myself to the examination of abscesses when opened. In chronic abscesses I have not as yet found any organisms, and in this my results agree with those obtained by Billroth,[1] by microscopical examination alone. Of acute abscesses I have inoculated from thirty-two cases. In twenty-five of these no organisms were present, while in seven micrococci were found. In none were bacteria present. I omit here one abscess in the ischio-rectal fossa, where I found both bacteria and micrococci, and one with fæcal odour in the lumbar region, from which I did not inoculate when opened, but in which undoubted bacteria were seen on microscopical examination. Billroth has paid special attention to this subject, and he finds micrococci in a larger proportion of acute abscesses than I have done. It must be mentioned, however, that the abscesses which I have examined were not as a rule very acute. Thus, some were buboes, and, indeed, of three of the cases where micrococci were found two were buboes after soft chancre, and one was a suppuration in the groin, following a sore on the foot. Professor Billroth's cases seem to have been more severe, and thus the difference in results may be explained. He likewise only mentions the occurrence of micrococci. In acute osteomyelitis, where a communication had not yet been established with the external air, organisms have been found in the medullary canal or in the pus surrounding the bones by Von Recklinghausen,[2] Klebs,[3] Eberth,[4] and Godlee.[5] These organisms were as a rule micrococci. Bacteria have but very rarely been present, and that only in the most severe cases. That these micrococci are simply accidental and not essential to the inflammatory process[6] is evident, because they do not occur in all cases, and because, when introduced into animals subcutaneously, or into the circulation, or inoculated on the cornea, they produce no effect. (Billroth inoculated the cornea of a rabbit, without effect, with the pus from a newly-opened acute abscess of the thigh containing micrococci, while the discharge from a healing wound not treated antiseptically produced

[1] Loc. cit.

[2] 'Deutsche Zeitschrift,' Bd. iv, ¶ 239.

[3] 'Ueber Schusswunden,' 1871.

[4] 'Virchow's Archiv,' Bd. lxv, ¶ 341.

[5] 'Lancet,' Nov. 21st, 1874.

[6] It is probable that the presence of micrococci in cases of ulcerating endocarditis, &c., may be similarly accounted for.

the so-called diphtheritic inflammation.) Further, I have injected into my own arm, on two occasions, one and five minims respectively of cucumber fluid containing micrococci at least as numerous as two millions in each minim, without the production of abscess.

If now we apply these facts to the subject under consideration I think it must be concluded that it is only rarely that the micrococci can have reached the wound through the body. To do so implies such an inflammatory disturbance or depression of the nutritive processes as is not usually present after operations conducted antiseptically. A patient on whom an operation has been performed antiseptically is, after the effects of the chloroform have passed off, provided there has been no great loss of blood, practically as well as before the operation. There is no inflammation and no febrile disturbance. The patient, as far as one can judge, ought to be as able to resist the entrance of organisms into his blood as before the operation.

If, however, these micrococci did enter the wound from within they would do so during the first few days after the operation; but, on looking at my notes, I find that for a week at least the wound has generally remained free from them. The following case is very illustrative:—A patient was admitted on March 8th, 1878, with seven chronic abscesses, one in the neighbourhood of each knee-joint, one close to the left elbow-joint, and four about the right wrist-joint. They were all opened on March 9th, and they followed an aseptic course. On March 11th inoculations were made from all without result. On March 22nd micrococci were found in the abscess in the left leg, but none had as yet been obtained from the others. On March 24th they were present in the elbow. On April 28th micrococci were found in the right leg, the wrist still remaining free. Here, if the organisms came from the blood, why did not all the wounds contain them at the same time? And why were none present in the abscesses on March 11th? Another case may be mentioned as bearing on this point. A boy was admitted in the beginning of April, 1878, with caries of the thumb. There was an open wound in which were bacteria. An abscess formed in the axilla of the same side, and was opened on April 11th. No organisms were present in the abscess when opened, but on April 13th micrococci were found. On April 29th a second acute abscess was opened in the upper arm, but contained no organisms. If the micrococci came from the blood, why were they not present in the second

abscess? If they passed along the lymphatic vessels from the wound to the axilla why were none found in the first abscess when opened? Other similar cases might be narrated.

Accordingly, with regard to the first suggestion, we must say that, while in some cases the micrococci may have entered the wound from the body, yet such does not seem to be the ordinary course of events.

In looking for a loophole in the antiseptic dressings, we may divide them into three parts—a lotion in which various objects are soaked before being brought into contact with the wound,—a spray to purify the surrounding atmosphere,—and a dressing so constituted as to give off carbolic acid to the discharge as it passes under it.

That the lotion is sufficiently potent to destroy any organisms which come in contact with it will be very evident to any one who chooses to examine the subject. If one places a preparation of actively moving bacteria under the microscope, and allows a little carbolic lotion, 1—20, to flow under the cover glass, the movements will be seen instantly to cease. This, in fact, is the method which I use when I wish to draw moving bacteria with the aid of the camera lucida. And, further, it is by soaking the cotton in carbolic lotion that I purify the cotton caps covering the flasks.

But if carbolic lotion can destroy organisms, so must the spray. For the spray is simply carbolic lotion, the particles of which are in a state of extremely minute division. Any speck of septic dust falling into the spray must come in contact with the carbolic lotion, and be instantly deprived of vitality.

Further, the performance of the experiments related in this paper would have been quite impossible without the aid of the spray. The room in which the flasks were prepared and many of the experiments performed is a very small one, and in it I keep pathological preparations and putrefying fluids and tissues of all kinds. The most momentary exposure of a flask without its cap in this atmosphere is certain to be followed by the development of bacteria, while any attempt at transferring organisms from one flask to another without the access of fresh forms of bacteria is quite impossible. But flasks may be exposed without their caps for any length of time in the spray without the subsequent development of organisms, though the latter will grow readily if added intentionally. And organisms may be transferred from one flask to another in the spray with the certainty that only the variety of organism thus intro-

duced will develop. Indeed, I believe that the aid of the spray is invaluable in such investigations, and that its use will clear up many of the contradictory results obtained by different observers. A very striking proof of the value of the spray, which occurred to me lately, may be mentioned. The flasks which I use are purified by heating them to a temperature of about 600° F. in a box like that described last year by Mr. Lister. The flasks are in the first instance heated without any covering, the cotton caps are then applied under the spray, and the flask with its cap reintroduced into the box, where it is thoroughly dried in order to drive off any carbolic acid which may be adhering to it. As the temperature to which the apparatus is, in the first instance, raised chars cotton wool, I have used asbestos to filter the air as it passes into the interior of the box during cooling. For a time this answered quite well, but lately portions of the asbestos have become detached, and thus holes have occurred through which air can enter without being filtered, and, as a result, on several occasions I have found that all the flasks so prepared were impure. This has been obviated simply by directing the spray against the door of the box as soon as the lamp which heats it is extinguished. The box is thus surrounded by spray; the air passing into it first passes through this spray, and, as a result, since I have done this I have not failed in any instance to obtain perfectly pure flasks.[1]

[1] An experiment which I performed some time ago may be mentioned. Two flasks containing pure milk were opened in my room and left open for ten minutes. (In both bacteria developed.) As soon as these flasks were removed two other flasks similarly charged were put in the same place in a fine cloud of carbolic acid spray. They were opened and left open for ten minutes. (Both of these remained pure, though when tested at a later period organisms rapidly developed in them.) When they were removed the spray was stopped, and two fresh flasks were placed in the same position, opened, and left open for ten minutes. One of the latter remained pure, in the other organisms developed.

Since the above was written I have performed the following experiment:—Four flasks provided with cotton caps were purified according to Mr. Lister's method. Into two of these pure cucumber infusion was introduced in the way described at the commencement of this paper. These two flasks were then placed in an incubator for four days. At the end of this time the fluid was still found to be clear in both. About half of the liquid in one of the flasks was then poured into one of the empty previously purified flasks in a cloud of carbolic acid spray. These were then placed in the incubator, and they remained permanently clear. The same process was gone through with the other flasks without the use of a spray. In both of these bacteria developed. Here, when the fluid was poured

Our suspicion, if a loophole do exist in the method, must, therefore, fall on the dressing, and an examination of the cases will confirm this. For, as I have said, it is at a late period in the treatment of a case that these organisms appear, generally where the dressings have been left on for several days, and where the discharge has reached the edge some hours before changing, or where the discharge has been considerable, even though the dressings have been changed more frequently. And thus I have been able in some cases to prevent the entrance of these organisms by changing the dressings daily, and, conversely, they are easily enough obtained in any given case simply by dressing it less frequently. To mention one instance. A psoas abscess was opened on January 16th, 1878. I determined to see if in this case these organisms could be excluded. The dressings were accordingly changed daily till February 16th. Fluids of different kinds inoculated during this period remained barren. During March it was dressed every three days, still no organisms. On April 24th, when it was dressed for the second time after an interval of four days, the discharge having on both occasions appeared at the edge of the dressing some hours before it was changed, micrococci developed in the fluid inoculated. There had been no alteration in the condition of the patient.

If such a fluid as milk be tested with the view of determining the amount of carbolic acid which must be added in order to prevent the development of organisms, it will be found that a large quantity is necessary. Thus they readily develope in a proportion of carbolic acid and milk 1—60, and I have grown them in as large a proportion as 1—54. On examining the milk while the carbolic acid is being added a granular precipitate will be seen to take place. In the same way, if carbolic acid is added to serum or white of egg a white precipitate occurs, and here likewise a large proportion of carbolic acid is necessary to prevent development. In artificial cultivating liquids, such as Pasteur's fluid, no precipitate takes place, and a much smaller quantity of carbolic acid is required to hinder the growth of organisms. In other words, where carbolic acid is added to an albuminous fluid a compound is formed, which is but little antiseptic. So in the case of the antiseptic

from one vessel to the other, it passed through the air, and air also entered into the first flask to take the place of the liquid. Where this air had not been acted on by carbolic acid organisms developed, but where it had previously passed through the spray it failed to cause development.

dressings; where there is profuse discharge, though the first which comes through may not be putrescible, yet very soon the carbolic acid is not present in sufficient quantity to prevent the development of organisms. And, as carbolic acid is very volatile, when a dressing is left on for several days a considerable amount of carbolic acid will have escaped by evaporation, and thus the meaning of the following rules of treatment derived from experience becomes apparent:—"The dressing must not be too small." "The dressing must not be left on longer than twenty-four hours after the discharge has appeared at the edge." "In no case is it safe to leave a dressing unchanged for more than eight days." Experience has shown that any marked disregard of these rules will in all probability be followed by putrefaction in the wound.

But this still leaves unexplained why it is that *micrococci* only are found in wounds treated antiseptically. At first the only hypothesis which I could think of was that micrococci can grow in fluids containing carbolic acid in larger quantity than those in which bacteria can develope. I have accordingly performed numerous and elaborate experiments to test this view, but I have been quite unable to find any such difference in the first instance. An observation which I made in these experiments seems, however, to furnish the clue to this mystery. I had previously observed that where one flask was inoculated with bacteria, and another with micrococci in like amount, that which contained the bacteria was, as a rule, muddy in from twelve to twenty hours (the quantity of fluid in each flask being ʒiij to ʒiv), while thirty to fifty hours elapsed before the fluid in the flask into which the micrococci had been introduced became opaque. But if to this fluid carbolic acid, say in the proportion of 1 to 500, be previously added the result is just the reverse; the flask containing the micrococci becomes opaque in twenty-four hours, while that containing the bacteria does not become muddy till a later period. Following out this line of investigation, I have found that if micrococci and bacteria be introduced together into a cultivating liquid containing carbolic acid, the micrococci will develope rapidly, often to the complete exclusion of the bacteria. Where no carbolic acid is present exactly the reverse is the case; most forms of bacteria grow quickly, the micrococci being apparently prevented from developing. But, it may be said, in the former case the bacteria became transformed into micrococci. But if the same bacteria be introduced into a flask containing no micrococci bacteria alone develope.

So in the room in which I work I have never been able, without the aid of the spray, to transfer *micrococci* from one flask to another. For in the latter flask *bacteria* almost invariably developed. But if carbolic acid be previously present in the fluid the operation may be done in the most leisurely manner with a certainty of obtaining micrococci alone in the second flask.[1]

If a drop of tap water be added to an infusion bacteria develope. To a flask of meat infusion containing carbolic acid I added a drop of tap water, and micrococci were the result.

It is thus apparent that though bacteria and micrococci can grow in fluids containing like amounts of carbolic acid, yet the micrococci find these liquids more suitable for their growth than do the bacteria; indeed, they may grow more rapidly in them than in fluids containing no carbolic acid at all. And therefore when bacteria and micrococci fall together into discharge containing carbolic acid the latter develope with much greater rapidity than the former, and may thus reach the wound long before them. If, however, sufficient time be allowed to elapse before the changing of the dressing bacteria also may enter the wound.

One other observation completes this subject. The largest proportion of carbolic acid in cucumber infusion in which organisms develope is from 1—450 to 1—500. In one of the last experiments performed with the view of seeing whether micrococci could grow in a larger proportion of carbolic acid than that sufficient to prevent the development of bacteria, I used micrococci which were growing in a fluid in which a small quantity of carbolic acid was already present. This was done on April 14th. On examining the flasks on April 15th, I found one containing carbolic acid in the proportion of 1—400 quite opaque from the development in it of micrococci, while those in which a larger proportion of carbolic acid was present remained clear. On the same day I inoculated from flask 1—400 a new series containing carbolic acid in the following proportions:—

[1] In performing such experiments one must remember that to mix bacterial and micrococcal fluid together will likely result in the death of the micrococci, and therefore the bacteria and the micrococci must be separately introduced into the cultivating fluid. It is best to use fluids in which micrococci and bacteria are growing together, and, further, they ought not to be more than twenty-four hours old, for micrococci become incapable of further development in two to three days, and as the bacteria develope their products may exercise a deleterious effect on the micrococci. The bacteria may be conveniently separated from their products by Hiller's method.

C. 1—400, C. 1—350, C. 1—300, C. 1—250. On April 16th, C. 1—350, and C. 1—400 were quite muddy from the presence of micrococci; while C. 1—300 and C. 1—250 were clear. That afternoon a fresh series, C′. 1—350, C′. 1—300, C′. 1—250, C′. 1—200 was inoculated from C. 1—350. On April 17th, C′. 1—300 and C′. 1—350 were muddy. Here the limit seems to have been reached. For though I have obtained slight development in carbolic acid and cucumber, 1—275 and 1—250, this is not vigorous. As the micrococci grow in larger proportions of carbolic acid they become much larger, and the grouping and mode of growth described by Mr. Lister is more evident (see fig. 3).

The facts, then, seem to be that the discharge when profuse or when it arrives at the edge of a dressing which has been left on for some days, does not contain sufficient carbolic acid to prevent the development of organisms in it; that micrococci, which are more abundant in the ward atmosphere than bacteria, find this a particularly favorable medium for growth; and that as they grow they increase in vigour, and become more able to live in fluids containing a larger proportion of carbolic acid, and thus, if time be given them, they will ultimately reach the wound.

The hypothesis of spontaneous generation, however convenient when no other explanation is forthcoming, has been so disproved of late that there does not seem to be any necessity for discussing it. I shall just allude to one or two points. Were spontaneous generation at all frequent, such a method of investigation as I have employed would be impossible, for in various conditions of the atmosphere, temperature, &c., organisms would spontaneously develope in the cultivating fluid; and yet I have kept the same flasks of cucumber or milk for months until they have dried up, without in any instance organisms developing unless they had previously been introduced from without. But if these micrococci arise spontaneously in a wound, why do not *bacteria* likewise appear? (The supporters of the spontaneous generation theory speak for the most part of the latter as originating in this manner.) And further, if their origin be due to physical conditions external to the patient, why do not these micrococci appear in all the wounds in the same ward at the same time? Or, if their advent be owing to some change in the nutritive or other conditions of the patient, why do they not arise in all the wounds in the same patient at the same time? (compare the case of the man with seven chronic abscesses).

To sum up we find: that where the antiseptic treatment is properly carried out, organisms are either completely absent from the wounds or, if present, they belong to the class of *micrococci*, while in wounds not treated antiseptically organisms are always present and generally consist of various forms of bacteria: that bacteria can live in wounds under antiseptic dressings when they gain admission: that while micrococci give but little indication of their presence, the entrance of bacteria is generally accompanied by the development of smell or by symptoms of local or constitutional disturbance: that micrococci form a group of organisms quite distinct from bacteria, as shown by their mode of growth, their relation to reagents and to carbolic acid, their effects on fluids and on the living body, and further by the fact that though they have been under careful observation for eighteen months under the most varied conditions and in different kinds of fluids, no instance has occurred of a transformation of the former into the latter, or *vice versâ*: that the ordinary forms of micrococci whencever derived are harmless, whether they be introduced into the veins, under the skin, or inoculated on the cornea, thus contrasting markedly with the ordinary forms of bacteria, which are more or less hurtful: that organisms do not occur in the blood or tissues of a healthy living animal, though they may be present in states of disease, as in acute inflammatory processes: that they are not essential for the inflammatory process, however much it may be complicated by their presence: that the explanation of their presence in wounds is that the discharge flowing from underneath an antiseptic dressing is not too strongly antiseptic to prevent the development of organisms in it: that the organisms which find it the most suitable pabulum are micrococci, and these as they continue to grow in it become stronger, and able to grow in fluids containing more carbolic acid: that this seems to be their ordinary mode of entrance, though they may possibly in some cases come from the blood: that the admission of bacteria into a wound is the result of carelessness, while their entrance from the body can only happen in the most grave disturbances of the vital functions, in such conditions that only operations of the utmost necessity will be performed.

Before concluding, I must express my obligations to Mr. Lister for much kind criticism and assistance, and to Mr. Gerald Yeo for performing for me some experiments which would otherwise have been left undone.

*May 6th*, 1879.

# XI. MISCELLANEOUS SPECIMENS.

## 1. *Foot with nine toes.*

By Francis Mason.

Mr. Francis Mason exhibited a leg he had removed for congenital deformity. The patient from whom the specimen was taken was a muscular lad, aged 14, who through life had enjoyed excellent health. His sole object in seeking admission into St. Thomas's Hospital was to undergo amputation of the limb, which was quite useless, and rendered him incapable of earning a livelihood. His father and mother were perfectly healthy, and no similar deformity could be traced in the family.

Mr. Mason showed photographs and a cast of the patient before the operation, and sketches of the part after removal.

In referring to the points of interest, Mr. Mason said that the thighs of each side corresponded in length, but the lower end of the femur of the deformed (or left) limb assumed a rounded prominence, and there was little or no inter-condyloid notch. There was no patella. The leg, which measured about half the length of the normal limb from the knee to the ankle, could not be extended beyond a right angle. Flexion, however, was fairly free, and there was some lateral movement. The tibia and fibula were both rickety. The upper part of the tibia articulated with the back portion of the rounded eminence already referred to as representing the condyle of the femur, and the head of the fibula, a large projecting part, articulated at its outer aspect. There was well marked equino-varus of the foot; but perhaps the most interesting point in the specimen was the presence of nine toes, eight of which were connected with separate metatarsal bones. The dissection of the foot showed on the dorsum that the tendon of the extensor proprius pollicis sent slips to the third, fourth, and fifth toes (counting them numeri-

cally from the inner side); that the extensor longus digitorum sent slips to the sixth, seventh, eighth, and ninth toes; and that there was a communicating slip of tendon between these two muscles. The extensor brevis digitorum provided tendons to the fifth, sixth, seventh, and eighth toes, which blended with the tendons of the long extensor. In addition there was a well marked slip, having an independent origin, which was inserted into the dorsal surface of the first phalanx of the second toe. There was no tendon to the innermost or first toe, either on the dorsal or plantar surface. This toe seemed to be a loose appendage. On the plantar aspect the tendons of both the short and long flexors went to the second, third, fifth, sixth, seventh, and eighth toes (taking them numerically from within outwards, as on the dorsal surface); but the long flexor alone went to the fourth and nine toes. As already stated, there was no tendon connected to the innermost toe, either on the plantar or dorsal surface.

The patient made a rapid and excellent recovery after amputation.

Mr. Mason believed that this deformity was very rare, and remarked that there was but one other instance recorded in the 'Transactions' of the Society (in vol. ix, p. 427). The case was under the care of the late Mr. Athol Johnson, who removed the four supernumerary toes only. *May 19th*, 1879.

---

## 2. *Rabies of the dog.*

By Edwards Crisp, M.D.

The dog (a fox terrier) from which the parts I exhibit, brain spinal cord, tongue, larynx, stomach, heart, and spleen, were taken I saw die of rabies on Wednesday, the 3rd October. It was secured by chain in a closed chamber, no medicine was given, and no violence used. It was bitten by a rabid dog three weeks before its death; he that day also bit ten or twelve other dogs in the neighbourhood, some of which have been since killed; one was

supposed to have gone mad, and was killed without doing any mischief.

The dog was carefully looked after by a very intelligent attendant, who supplied me with the following report:—Saturday afternoon (five days before death) the animal stared at its master, looked wild, and refused food and drink. On the next day he was still at large, became restless, sulky, took little notice of his attendant, and still refused to eat or drink; his flanks were hollow. On Monday, October 1st, he was chained up, and soon began to manifest signs of ill-temper, such as snapping at objects near to him. The voice became altered, approaching more to the character of a howl (probably the most characteristic symptom of rabies). Saliva flowed abundantly from the mouth so as to cover the neck and upper part of the chest with this secretion. When water and food were offered him he refused them, but no convulsive motions were produced from this cause. On the following day, Tuesday, the dog became furious, snapping at imaginary objects, and biting at everything near him, even the brick wall; tremors and *subsultus tendinum* were sometimes present. He became weak, and died on the afternoon of the next day, Wednesday. Nearly up to the time of death, when he was unable to stand, he continued at intervals feebly to close his jaws, as if in the act of snapping at something. His pulse was very quick, and the skin cold several hours before death, as witnessed by me. No food nor water was said to have been taken from the appearance of the first symptoms, no excrement was passed, but urine was freely voided several times during his confinement in the chamber.

I scarcely need say that the symptoms vary somewhat in the dog, some animals exhibiting less ferocity, Yowett and others supposing that this is influenced to some extent by the breed or the variety of the animal.

I had the dog carried to my stable, and made a careful examination ten hours after death. Externally there was a small cicatrix on the nose where the bite had been inflicted. On taking off the skin the flesh presented an unusually dark red appearance. The brain and spinal cord were immersed in spirits of wine, but I did not make a very careful examination of these parts as I wished to refer them to the Committee of Morbid Growths.[1] Externally, as

[1] The President did not think the brain and cord sufficiently fresh for microscopic examination.

will be seen, especially in the drawings, the brain and spinal cord presented a high degree of vascularity, the vessels being greatly distended. The nasal sinuses were also vascular, and covered with some thick mucus; the lining membrane of the larynx, trachea, and bronchi were also vascular, but less so than the parts before described. The tongue was not enlarged, and presented no abnormal appearance. There were no papillæ nor vesicles at the base, such as have been found in some cases of rabies. The salivary glands were not enlarged. The lungs were healthy, and free from emphysema. The heart (both sides) contained a large quantity of dark-coloured grumous blood. Externally the parietes were very vascular. The stomach was empty, and furnished no evidence of vascularity. The liver, spleen, kidneys, and intestines were also normal. The bladder contained a small quantity of urine. The blood under the microscope presented a natural appearance.

From the above description it will be seen that, exclusive of the great vascularity of the membranes of the brain and spinal cord, no lesion was met with of an abnormal character. I regret that the rapid decomposition of the body prevented my making a careful examination of the sympathetic and other ganglia. I may, I hope, be pardoned if I very briefly allude to a few points in connection with this disease in man, the dog, and other of the lower animals.

I may premise that I have seen three cases of hydrophobia in man (including one spurious), three of rabies in the dog, and one in a horse.

A curious mistake is made by the author of a recent book on surgery, much read by our students. "The fact," he says, "is that a dog usually bites at the legs, and thus, when he inflicts a wound, it is through clothing, by which his teeth are wiped, the saliva arrested, and thus the wound escapes inoculation." From a large number of cases I have tabulated, I find that a great many more persons are bitten in the face, body, and upper extremities than in the lower limbs; indeed, it is the nature of a dog to attack the upper part of the body.

The important differences between rabies in the dog and hydrophobia in man are:

1. In man the period of incubation, as far as we know, is generally longer.

2. Whilst man is affected with dysphagia, is seldom able to take water, and is often thrown into nervous paroxysms by the sound of

this fluid, as well as by impulsion of air on the skin, the dog is rarely, if ever, affected by these agents.

3. That, as regards the duration of the disease after the appearance of the symptoms, there is no important difference between man and the brute.

4. The convulsive movements witnessed in man are rarely, or ever, seen to the same extent in the dog.

5. The dog, and other of the inferior animals when suffering from rabies, become excited at the sight of another dog; but this animal produces no such effect on human beings.

6. In the dog the voice is materially affected; but in man no such change takes place, excepting the hoarseness that sometimes accompanies the last stage.

7. That in the dog the natural instincts are somewhat changed, there being generally a desire to eat his own excrement and other filth; in man no such disposition is shown.

8. Other symptoms, such as the protrusion of the tongue in the dog, the disposition to bite even at imaginary objects, may be noticed.

9. As regards the morbid appearances, there is, as far as we know, no essential difference, if we except, perhaps, the papillæ or vesicles that are sometimes seen under the tongue of the dog. It is more than probable that in the human subject some of the appearances have been partly due to the active treatment employed.

To show the great importance of this subject, and the great increase of this malady, I quote the returns of the Registrar-General of the number of deaths in England and Wales from hydrophobia, from 1838 (when the returns were first published) to 1876, the last published return:—24, 15, 12, 7, 15, 5, 7, 17, 18, 25, 15, 11, 16, 14, 5, 8, 2, 4, 8, 4, 1, 4, 1, 2, 19, 36, 10, 7, 18, 32, 56, 39, 28, 61, 47, 53. So that in these years there were 658 deaths from hydrophobia in England and Wales. In the first decennial period (1838—1847), 145 deaths; average 14·5 per year. In the second decennial period (1848—1857), 87 deaths; average 8·7 per year. In the third decennial period (1858—1867), 92 deaths; average 9·2 per year. And from 1868—1876 (8 years), 334 deaths; average 41·75 per year. Average of the total number of years, 17·31 per year.

This great increase of late becomes a matter of serious consideration, and I believe the fact that the police are unable to enter premises and destroy dogs that have been bitten in a great measure

accounts for the increased mortality. The importance of the subject is my excuse for introducing these figures to the notice of the Pathological Society. *October 21st*, 1879.

---

## 3. *Skin diseases in the horse.*

By George Thin, M.D.

### I. *Sebaceous tumours.*

Mr. G. Fleming, Veterinary Surgeon to the 2nd Life Guards, to whom I am indebted for being able to see the case, and for the specimen examined, has supplied me with the following history:

"Black mare, æt. 18 years; skin in a very healthy condition, and the mare herself had never shown any symptoms of cutaneous derangement. On various parts of the body were discrete well-defined nodules, varying in size from that of a pea to a small hazel-nut. There were no signs of inflammation or pain in or around these tumours, and the only objection to them was the unsightly appearance they gave the horse's skin."

Microscopical examination of the tumours showed them to be composed of epithelial cells. Some of the cells were flattened, and so arranged as to form capsules to subdivisions of the tumour. Within these subdivisions the cells contained slightly pigmented matter, by which they could be identified as being of a similar nature to the cells of the adjacent healthy glands.

The points to be noted in these tumours are the absence of irritation in the surrounding connective tissue, and the absence of breaking down in the compact cellular mass of which they are composed.

### II. *Erythema circumscriptum* (?).

The following case also occurred in Mr. Fleming's regiment, and

I am again indebted to him for the opportunity of seeing it and for the specimen. The following are Mr. Fleming's notes:—

"Black mare, 9 years old. First affected with acute inflammation of the submaxillary glands; great tumefaction and eventual suppuration of these glands. Secondary abscesses formed on the face, with erysipelatous inflammation of the skin of the head and serous subcutaneous infiltration of this region. Much coincident fever, the temperature rising as high as 105° (normal temperature 100° in horse) with traces of albumen in the urine. The animal exhibited symptoms of great prostration. During the existence of the most serious symptoms an eruption of raised circular patches appeared on the skin, over the entire surface of the body. These patches were rarely confluent, and varied in size from that of a sixpence to a florin. They were perfectly circular, more raised at the circumference than the centre, and the hair appeared to be darker on them than on the unaffected parts of the skin. This eruption gradually disappeared, and the horse recovered."

In this case the microscopical examination was chiefly remarkable for its negative results. Sections were carried from the swellings into the surrounding unaffected portions of the skin, but no marked line separated the one area from the other, as an examination of the patch before it was excised had led me to expect. The only change found was a very slight infiltration of colourless blood-cells between the bundles of connective tissue, and at some parts around the blood-vessels.

The exudation which had produced the patches had therefore consisted in great part of the unformed element of the blood, and it may be inferred that the blood-vessels had sustained at these parts some injury, or were subjected to some pressure which weakened their walls sufficiently to permit an escape of serous fluid, but not sufficiently to permit the escape of the formed elements.

The erysipelatous inflammation and secondary abscesses about the head suggest blood-poisoning as the immediate cause, the morbid matter attacking the blood-vessels at certain points. The name erythema circumscriptum has been suggested by Mr. Fleming, and, from the pathological stand-point, does not seem to me to be liable to any serious objection.

### III. *So-called eczema in the horse.*

A disease termed by veterinary surgeons "eczema" has been

lately prevalent amongst horses. Mr. Fleming gives me the following note on the subject:—

"It is a very common disease of the horse's skin, especially in summer, in hot climates, often accompanied by intense itching. There is always shedding of hair on the affected patches, with an exudation of pus and serum which forms crusts. Some horses are liable to the disease for years. Remedial agents have only a temporary effect. It sometimes leads to hypertrophy of the cutis, with corrugation where the panniculus carnosus muscle is thickest."

The specimen I examined was excised from a trooper in Dublin at the instance of Mr. Collins, the head of the Veterinary Department in H.M.'s Service. The following notes of the case have been kindly supplied by Mr. A. J. Owles, Inspecting Army Veterinary Surgeon.

"The animal from which the piece of skin was taken has been twice under treatment for 'eczema,' and it was during the second period that the morbid specimen was obtained, when the disease was in a somewhat chronic stage. The first admission was on 7th September, 1877, discharged 'cured,' as we thought, 22nd November, and readmitted 2nd January, 1878. The disease first appeared n the form of vesicles about the size of small peas on different parts of the body, attended with great itching. The vesicles burst and exuded a pale straw-coloured fluid, which dried and formed a crust on the surface. The hair was either rubbed off the affected parts, or it became detached without friction and fell off. When the hair was clipped over the affected parts, small bare spots were visible at the seat of former vesicles. In the chronic stage vesicles were not found in the portion of skin longest affected, but raw-looking spots, or spots covered by a thin brownish crust, had taken their place, producing an appearance somewhat similar to that of a chin which had been 'rasped' in shaving. The skin becomes harsh and thickened; in several cases it became almost corrugated. The portion sent was in the chronic thickened stage to some extent."

The appearances found on microscopical investigation were not those which are described as being characteristic of eczema in the human subject. These are stated to consist of serous infiltration of the cutis, swollen connective-tissue bundles in the corium, enlargement of the papillæ, cell-infiltration between the bundles, a swollen condition of the cells of the rete mucosum, and a cellular infiltra-

tion between these latter. In the skin from this horse I found the morbid appearances limited to the hair follicles, sebaceous glands, and the portions of the epidermis adjacent to the opening of the hair follicles. The hairs were absent from a large number of the follicles. In some follicles the hair was intact in the deeper part of the follicle, and tapered to a thin point before its exit from the cutis. In some sebaceous glands the secreting cells had become agglutinated into a honey-combed mass near the point where the sebum is discharged into the follicle, and in one specimen there was some breaking down and disintegration of the cells of the root-sheaths at this point. Near the hairs cavities, filled with cellular elements and débris, had formed between the rete mucosum and the horny layer. Their contents were definitely bounded by the epidermic cells and stained deeply by logwood. I had observed similar cavities in the epidermis and external root-sheaths in tinea tonsurans, and the condition is not confined to any special disease, but is found in different affections attended by irritation of the rete mucosum. They might be described as minute abscesses in the rete mucosum. The cells of the rete were not swollen, and there was no cellular infiltration of the epidermis, such as that described by Biesiadecki in eczema in man. Cell infiltration in the cutis (although to a very moderate extent) was observed in the papillary layer, and was more marked at some parts than at others. There were no appearances which could be interpreted as signifying that there had been swelling of the bundles of connective-tissue.

The affection must, I think, be considered as one of the epithelial elements of the hairs and sebaceous glands. The evidences of peri-follicular inflammation are not sufficient to warrant the supposition that the disease is identical in its nature with the acne of man.

The minute swellings in the epidermis are sufficient to account for the itching which is a prominent symptom of the disease, and which has, perhaps, more than anything else, led to its being considered eczematous. *May 20th*, 1879.

# INDEX.


ABSCESS of LIVER, cases of (N. Moore) . . . . 306
ADDISON'S DISEASE, two cases of (J. F. Goodhart) . . . 486
„ with disease of the sacrum and lumbo-sacral joint, double psoas abscess (J. F. Goodhart) . . . . . 486
„ with tubercle of left supra-renal capsule, cerebellum, and pons Varolii (J. F. Goodhart) . . . . . 487
„ with peculiar pigmentation (D. J. Leech) . . . . 478
„ — microscopical examination of capsule, ganglia, &c. (Dr. Dreschfeld) . 484
AMYLOID LIVER, STOMACH, and INTESTINES, in a case of tubercle of the lung (J. F. Goodhart) . . . . . 233
ANEURYSM of AORTA, and destructive changes in left lung from compression of its bronchus (J. P. Irvine) . . . . . 241
„ of the abdominal aorta, associated with disease of the aortic valves; death from uræmia (H. A. Lediard) . . . . . 288
„ of ascending aorta, compression of left bronchus by (J. P. Irvine) . 239
„ — unusually large, which burst externally (H. A. Lediard) . . 284
„ case of three, arising from the descending aorta (H. G. Orlebar) . 286
„ SUBCLAVIAN, cured (Sydney Jones) . . . . 292
ANTISEPTIC DRESSINGS, on the relation of organisms to (W. W. Cheyne) . 557
AORTA, rupture of within the pericardium (N. Moore) . . . 283
„ see *Aneurysm.*
AORTIC VALVES, disease of, originating in congenital defect (T. B. Peacock) 277
„ disease of, in a case of aneurysm of the abdominal aorta, death from uræmia (H. A. Lediard) . . . . . 288
ARTERY, PULMONARY, dilatation of, with stenosis of the pulmonary valve, &c. (D. W. Finlay) . . . . . 262
„ — dilation above stenosis of (T. Barlow) . . . . 272
„ — embolism of, succeeding thrombosis of the veins of one lower extremity (R. Lyell) . . . . . 294
„ — stenosis of, from disease of the valves, probably of congenital origin (T. B. Peacock) . . . . . 258
ATROPHY and HYPERTROPHY, changes in the sweat glands, as illustrating the pathology of (George Hoggan) . . . . . 421
„ gelatiniform, and chondro-calcareous, of bones, in hereditary syphilis (Jules Parrot) . . . . . 341
BACTERIA, comparison of their development with micrococci, &c. (W. W. Cheyne) 578-580
„ in the blood during life in cases of pyæmia . . 44, 149
*BAKER* (*W. Morrant*), case of rodent ulcer, reference to (G. Thin) . 374
„ lymphadematous tumours of scalp and neck . . 417

*BARKER* (*Arthur E.*), incipient synovitis in hip-joint . . . 353
*BARLOW* (*Thomas*), specimens of bronchial gland disease . . 254
„ congenital heart disease, pulmonary stenosis, with dilated pulmonary artery above the stenosis . . . . . 272
„ specimens of craniotabes . . . . . 332
„ specimens of disease of skull in congenital syphilis . . . 333
„ and *D. B. LEES*, on lesions of the cranial bones in congenital syphilis (three living cases) . . . . . 350
*BECK* (*Marcus*), *report* on C. Heath's case of removal of the scapula . 406
„ see *Pyæmia* (Report of Committee on).
*BELL* (*Royes*), see *Wood* (*J.*), molluscum fibrosum . . . 458
*BELLAMY* (*Edward*), and *ALFRED SANGSTER*, cancerous ulcer of the face, 371
„ *report* of the Committee on Morbid Growths on ditto (J. F. Goodhart and H. T. Butlin) . . . . . 373
BLADDER, spontaneous fracture of calculi within, exhibited by Mr. Croft, *report* on, by W. M. Ord . . . . . 318
„ &c., DISEASES of, see *Urinary organs.*
BLOOD, microscopical examination of, in cases of pyæmia . 39-49, 137-149
„ circulation of, in lungs, obstructed: extreme congestion of Brain due to (S. Coupland) . . . . . 189
BLOOD CYST removed from the neck (J. Gay) . . . 435
„ — summary of its distinctive peculiarities . . . . 438
*BOILEAU* (*J. P. H.*), penetrating wound of the heart, involving the transfixion of both ventricles, but not causing death for several minutes . . 278
BONES, DISEASES of . . . . . 332-359
„ lesions of, in hereditary syphilis (Jules Parrot) . . . 339
„ cranial, lesions in congenital syphilis, three living cases (H. Barlow and D. B. Lees) . . . . . 350
BONY TUMOURS of inferior maxilla (J. F. Goodhart for B. Edwards) . 358
BOWEL, see *Intestines.*
*BRAIDWOOD* (*P. M.*), case of unilateral cancer . . . 413
BRAIN, dermoid cyst of the (J. P. Irvine) . . . . 195
„ diffuse punctiform hæmorrhages in hemispheres of, in extreme congestion from obstructed pulmonary circulation (S. Coupland) . . . 189
„ rupture into the fourth ventricle of a hæmorrhage in the cerebellum (W. A. Sturge) . . . . . 194
BREAST, colloid cancer of (R. J. Godlee) . . . . 416
BRONCHI of right lung, occlusion of, by mediastinal tumour (R. D. Powell) 249
BRONCHIAL GLAND DISEASE, specimens of (T. Barlow) . . 254
BRONCHIAL TUBES, compression of large, lung changes caused by (J. P. Irvine) 239
*BROWNE* (*Lennox*) primary epithelioma of tonsil, (living specimen) . 407
*BUCHANAN* (*G.*), see *Power* on the relation between diphtheria and milk.
*BUTLIN* (*H. T.*), sequel of a case of multiple round-celled sarcoma in a boy (lympho-sarcoma) . . . . . 396
„ *report* on E Bellamy and A. Sangster's case of cancerous ulcer of the face 373
„ *report* on Jas. Gairdner's specimen of multiple tumours . . 394
„ *report* on Geo. Hoggan's microscopic specimens of the skin in leprosy . 510

CALCULI, VESICAL, cases of spontaneous disruption of (J. Kraus) . 314
„ specimen of spontaneous fracture of, within the bladder, exhibited by J. Croft, *report* on by W. M. Ord . . . . . 318

CANCER, UNILATERAL, case of (P. M. Braidwood) . . . 413
„ and LEPROSY, changes in the sweat-glands in, as illustrating the extremes of atrophic and hypertrophic pathology (Geo. Hoggan) . . 421
„ and SYPHILIS of the TONSIL, chief points of distinction in the clinical history of (L. Browne) . . . . . 409
„ COLLOID, of the breast (R. J. Godlee) . . . . 416
CANCEROUS ULCER of the face (E. Bellamy and A. Sangster) . . 371
„ of hepatic flexure of the colon, peritonitis, gumma in lung and in testes (J. F. Goodhart) . . . . . 234
*CARTER* (*Vandyke*), papers on the condition of the lymphatics in elephantiasis, reference to (G. Hoggan) . . . . . 504
CEREBELLUM, hæmorrhage into, rupturing into the fourth ventricle (W. A. Sturge) 194
CHARCOT and LUYS "on hypertrophic cirrhosis," referred to (R. Saundby) 301
*CHEYNE* (*W. Watson*), on the relation of organisms to antiseptic dressings 557
„ — references to papers on the subject, . . 558-559
CIRCULATION, ORGANS of, DISEASES &c., of . . 258-296
CIRRHOSIS, hypertrophic, of the liver, morbid anatomy of (R. Saundby) . 301
CLAVUS, disseminated, of the hands and feet (N. Davies-Colley) . . 451
*COATS* (*Joseph*), see *Gairdner* and Coats, Multiple tumours.
COLLOID, see *Cancer* (colloid).
COLON, cancerous ulcer of hepatic flexure, peritonitis, gumma in the lung, &c. (J. F. Goodhart) . . . . . 234
COMMITTEE ON MORBID GROWTHS, REPORTS:
„ on E. Bellamy and A. Sangster's specimen of cancerous ulcer of the face and nose (J. F. Goodhart and H. T. Butlin) . . . . 373
„ on James Gairdner's specimen of multiple tumours (J. F. Goodhart and H. T. Butlin) . . . . . 394
„ on Chr. Heath's case of removal of the scapula (M. Beck and R. J. Godlee) 406
„ on Geo. Hoggan's microscopic specimens of the skin in leprosy (J. F. Goodhart and H. T. Butlin) . . . . . 510
COMMITTEE on the nature and causes of PYÆMIA, septicæmia, and purulent infection, REPORT (see *Pyæmia*) . . . . . 1
COMMUNICATIONS (SPECIAL).
1. Discussion on lardaceous disease . . 511-546
2. On certain observed relations between diphtheria and milk (W. H. Power) . . . . . 546-551
3. On garget or ropy milk, or cold in udder (A. H. Smee) 551-557
4. On the relation of organisms to antiseptic dressings (W. W. Cheyne) 557-580
CONGESTION, long-continued, due to backward dislocation of the knee-joint, causing eczema squamosum of leg (H. G. Howse) . . . 454
„ of BRAIN, extreme, due to obstructed pulmonary circulation; diffuse punctiform hæmorrhages in substance of cerebral hemispheres (S. Coupland) . 189
CONVULSIONS, URÆMIC, in a case of syphilitic tubercle of the lung (J. F. Goodhart) . . . . . 233
CORPORA CAVERNOSA and SPONGIOSUM PENIS, gangrene of, from thrombosis of iliac vein (?) (J. Gay) . . . . . 323
*COUPLAND* (*Sidney*), diffuse punctiform hæmorrhages in substance of cerebral hemispheres in extreme congestion of brain, due to obstructed pulmonary circulation . . . . . 189
„ chronic lobar pneumonia; grey induration, gangrene, and secondary suppuration, in lower lobe of lung . . . . . 224

*COUPLAND* (*Sidney*), defect in the ventricular septum of the heart, probably congenital; unusual site of aperture . . . . . 266
CRANIAL BONES, lesion of, in congenital syphilis, three living cases (T. Barlow and D. B. Lees) . . . . . 350
CRANIOTABES, specimens of (T. Barlow) . . . . . 332
CRANIUM, specimens of disease of, in congenital syphilis (T. Barlow) . 333
*CRISP* (*Edwards*), rabies of the dog . . . . . 584
*CROCKER* (*H. R.*), case of congenital malformation of the heart . . 273
„ ditto . . . . . 275
„ ditto . . . . . 276
„ case of warty growth on tricuspid valves . . . . . 281
*CROFT* (*John*) specimens of spontaneous fracture of calculi within the bladder, *report* on, by W. M. Ord . . . . . 318
CYST, BLOOD, removed from the neck (J. Gay) . . . . 435
„ DERMOID, of the brain (J. P. Irvine) . . . . . 195
CYSTITIS, suppurative phlebitis of vesical, iliac, and femoral veins following (W. J. Walsham) . . . . . 321

*DAVIES-COLLEY* (*N.*) protrusion of orifice of ureter through meatus urinarius in a female child . . . . . 310
„ disseminated clavus of the hands and feet . . . . . 451
„ — *report* on ditto by H. G. Howse and C. H. Fagge . . . . 453
*DAVIS* (*James*), details of a case of penetrating wound of the heart . 278
DEFORMITY, CONGENITAL, of foot [nine toes] (F. Mason) . . 583
DEGENERATION of the LUNGS of uncertain nature (S. West) . . 220
DERMOID CYST of the brain (J. P. Irvine) . . . . . 195
*DICKINSON* (*W. Howship*), *address* on lardaceous disease in reference to its anatomical seats and pathological relations . . . . 511
„ *reply* in the DISCUSSION ON LARDACEOUS DISEASE . . . . 537
DIGESTION, ORGANS of, DISEASES, &c., of . . . . 297-309
DIPHTHERIA, on the nature of certain observed relations between, and milk (W. H. Power) . . . . . 546
DISCUSSION on LARDACEOUS DISEASE . . . . 511-546
DISEASES, &c., OF THE NERVOUS SYSTEM . . . . 189-219
„ of the ORGANS OF RESPIRATION . . . . 220-257
„ of the ORGANS OF CIRCULATION . . . . 258-296
„ of the ORGANS OF DIGESTION . . . . 297-309
„ of the GENITO-URINARY ORGANS . . . . 310-331
„ of the OSSEOUS SYSTEM . . . . 332-359
„ MORBID GROWTHS . . . . . 360-438
„ of the SKIN . . . . . 439-477
„ of the DUCTLESS GLANDS and LYMPHATIC SYSTEM . . 478-510
„ SPECIAL COMMUNICATIONS:
„ — 1. Discussion on lardaceous disease . . . . 511-546
„ — 2. On certain observed relations between diphtheria and milk, by W. H. Power . . . . . 546-552
„ — 3. On garget and ropy milk, or cold in udder, by A. H. Smee 551-557
„ — 4. On the relation of organisms to antiseptic dressings, by W. W. Cheyne 557-580
„ MISCELLANEOUS SPECIMENS . . . . . 581-589
DISLOCATION, backward, of knee-joint, with congestion causing eczema squamosum of leg (H. G. Howse) . . . . . 454
DISRUPTION, SPONTANEOUS, of vesical calculi (J. Kraus) . . 314

DOG, rabies of the (Edwards Crisp) . . . . . 584
*DORAN* (*Alban*), perforating ulcers of the ileum from obstruction after ovariotomy . . . . . 298
*DRESCHFELD* (—), microscopical examination of the capsule, ganglion, skin, and lung, in Leech's case of Addison's disease . . . 484
DRESSINGS, ANTISEPTIC, on the relations of organisms to (W. W. Cheyne) 557
*DUCKWORTH* (*Dyce*), and *Vincent HARRIS*, microscopical examination of some pustules removed from the back of the hand in a case of iodide of potassium eruption . . . . . 476
DUCTUS ARTERIOSUS, closed, with patency of foramen ovale, &c. (D. W. Finlay) 262

ECZEMA in the horse (G. Thin) . . . . . 589
ECZEMA SQUAMOSUM of leg, associated with elephantiasis from long-continued congestion, due to backward dislocation of the knee-joint (H. G. Howse) . 454
*EDWARDS* (*Branford*), see *Goodhart*, Tumours of maxilla.
ELEPHANTIASIS, with eczema squamosum of leg, from congestion, due to backward dislocation of the knee-joint (H. G. Howse) . . . 454
ELEPHANTIASIS ARABUM [two specimens of scrotal] (Sir J. Fayrer and D. Power) . . . . . 488
EMBOLISM of the pulmonary artery, succeeding thrombosis of the veins of one lower extremity (R. Lyell) . . . . . 294
EMPHYSEMA in a case of fibroid phthisis, syphilitic (J. F. Goodhart) . 232
„ and collapse in left lung, from compression of its branches by an aneurysm of the aorta (J. P. Irvine) . . . . . 244
ENDOCARDITIS, ULCERATIVE, *table* of . . . . 132
EPITHELIOMA, PRIMARY, of tonsil, living specimen (L. Browne) . 407
ERYSIPELAS, relationship of pyæmia and septicæmia to . . 6
ERYTHEMA CIRCUMSCRIPTUM in the horse (G. Thin) . . 588
EYE-BALL, melanotic sarcoma of (W. Spencer Watson) . . 410

FACE, cancerous ulcer of (E. Bellamy and A. Sangster) . . . 371
*FAGGE* (*C. Hilton*), *report* on Davies-Colley's specimen of disseminated clavus of the hands . . . . . 453
FAVUS, growth of the fungi in, compared with ringworm (G. Hoggan) . 444
*FAYRER* (*Sir J.*) (and *D'Arcy POWER*, elephantiasis arabum . . 488
„ — *report* upon ditto, by Henry Power and D'Arcy Power . . 499
„ — postscript to ditto; comparison of the normal with the pathologicnl appearances . . . . . 502
FEMUR, subperiosteal sarcoma of (John H. Morgan) . . . 403
FIBROID, see *Tumour* (fibroid).
FILARIA SANGUINIS HOMINIS, described by Lewis (Sir J. Fayrer and D. Power) . . . . . 493
*FINLAY* (*David W.*) malformation of the heart, stenosis of the pulmonary valve, with dilatation of the pulmonary artery and hypertrophy of the right ventricle; patency of foramen ovale, &c. . . . . 262
FISTULA, RECTO-VESICAL, septicæmia, terminating latally (A. Morison) . 326
FOOT, congenital deformity of [nine toes] (F. Mason) . . . 583
„ disseminated clavus of the hands and feet (N. Davies-Colley) . . 451
FORAMEN OVALE, patency of, with cribriform opening in the septum of the auricles (D. W. Finlay) . . . . . 262

*FOX (T. Colcott)* see *Fox (Tilbury)*.
*FOX (W. Tilbury)* and *T. Colcott FOX*, rodent ulcer . . . 360
„ — the histology of molluscum contagiosum [Bateman] . . 460
„ — on a case of lymphangiectodes, with an account of the histology of the growth 470
FRACTURE, SPONTANEOUS, of calculi within the bladder, exhibited by J. Croft, *report* on, by W. M. Ord . . . . 318

*GAIRDNER (James)* and *Jos. COATS*, case of multiple (lymphoid ?) tumours, some of which disappeared under observation . . . 387
„ — *report* of the Committee of Morbid Growths on ditto (Jas. F. Goodhart and H. T. Butlin) . . . . . 394
GANGRENE of the corpora cavernosa and spongiosum penis, from thrombosis of iliac vein (?) consequent upon rheumatic phlebitis (J. Gay) . . 323
„ and secondary suppuration in lower lobe of lung (S. Coupland) . . 224
GARGET or ropy milk, or cold in udder (A. H. Smee) . . . 551
*GAY (John)*, gangrene of the entire corpora cavernosa and spongiosum penis, probably from thrombosis of the iliac veins consequent upon rheumatic phlebitis. 323
„ blood cyst removed from the neck (with summary of its distinctive peculiarities) . . . . . 435
GENERATION, ORGANS of, DISEASES, &c., of . . 310-331
GLANDS, DUCTLESS, and LYMPHATIC SYSTEM, DISEASES of . 478-510
*GODLEE (Rickman J.)*, colloid cancer of the breast . . . 416
„ *report* on Ch. Heath's case of removal of the scapula . . . 406
*GOODHART (James F.)*, nodular fibroid phthisis (syphilitic ?) . . 232
„ two cases of tubercle of the lung, spreading from yellow elastic nodules in the lung (gummata ?) . . . . . 233
„ case of rapid enlargement of the heart . . . . 279
„ two cases of early disease of the supra-renal capsules (Addison's disease) . 486
„ *remarks* in the DISCUSSION ON LARDACEOUS DISEASE . . 532
„ *report* on Bellamy and Sangster's case of cancerous ulcer of the face . 373
„ *report* on J. Gairdner's specimen of multiple tumours . . 394
„ *report* on Geo. Hoggan's microscopic specimens of the skin in leprosy . 510
„ *for Branford Edwards*, osseous tumour of superior maxilla . . 358
*GREENFIELD (W. S.)*, *remarks* in the DISCUSSION ON LARDACEOUS DISEASE 525
„ see *Pyæmia* (Report of Committee on).
GROWTHS, MORBID . . . . . 360-438
„ see *Committee* on.
GUMMA in the lungs and testes, tubercle, &c. (J. F. Goodhart) . . 234
GUMMATA in the lungs, with secondary grey tubercle round them (J. F. Goodhart) 233

HÆMORRHAGE into the cerebellum; rupturing into the fourth ventricle (W. A. Sturge) . . . . . 194
„ diffuse punctiform, in cerebral hemispheres in extreme congestion of brain from obstructed pulmonary circulation (S. Coupland) . . . 189
HAIR, specimen of the affection of, described as piedra, trichoclasia, trichorrhexis nodosa (P. H. Pye-Smith) . . . . . 439
„ piedra a new disease of the (M. Morris) . . . . 441
HANDS, disseminated clavus of, and of the feet (N. Davies-Colley) . 451
HANOT, "on hypertrophic cirrhosis," referred to (R. Saundby) . . 302

*HARRIS* (*Vincent*), see *Duckworth* (Iodide of potassium eruption).
HEART, congenital disease of; pulmonary stenosis, with dilated pulmonary artery above the stenosis (T. Barlow) . . . . . 272
„ case of rapid enlargement of the (J. F. Goodhart) . . . 279
„ hypertrophy of the right ventricle of, and dilatation of pulmonary artery (D. W. Finlay) . . . . . 262
„ congenital malformation of, three cases (H. R. Crocker) . 273, 275, 276
„ malformation of the, stenosis of pulmonary valve, with dilatation of pulmonary artery and hypertrophy of right ventricle, &c. (D. W. Finlay) . 262
„ penetrating wound of, involving the transfixion of both ventricles, but not causing death for several minutes (J. P. H. Boileau) . . 278
„ cribriform opening in the septum of the auricles of, and patency of foramen ovale (D. W. Finlay) . . . . . 262
„ ventricular septum of, defect in, probably congenital; unusual site of aperture (S. Coupland) . . . . . 266
„ — account of two cases described by Rokitansky (S. Coupland) . 269
*HEATH* (*Christopher*), recurrent fibroid tumour of the scapula; removal . 405
„ — *report* of the Committee on Morbid Growths on ditto (M. Beck and R. J. Godlee) . . . . . 406
HIP-JOINT, acute disease of (J. H. Morgan) . . . 354
„ incipient synovitis in (A. E. Barker) . . . . 353
*HOGGAN* (*George*), on the changes in the sweat glands in cancer and leprosy, as illustrating the extremes of atrophic and hypertrophic pathology . 421
„ the growth of the fungi in ringworm and favus comparatively studied . 444
„ on the condition of the lymphatics in Eastern leprosy . . 504
„ *report* on ditto, by the Committee on Morbid Growths (J. F. Goodhart and H. T. Butlin) . . . . . 510
HORSE, skin diseases in the (G. Thin) . . . . 586
HOSPITALS (London), decennial returns of deaths from pyæmia and septicæmia in 3
*HOWSE* (*H. G.*), eczema squamosum of leg, associated with elephantiasis, from long-continued congestion, due to backward dislocation of the knee-joint 454
„ *report* on Davies-Colley's specimens of disseminated clavus of the hands . 453
*HULKE* (*J. Whitaker*), cases of "rodent ulcer," reference to (G. Thin) . 386
*HUMPHREYS* (*Henry*), case of infantile paralysis (H. Humphreys) . 211
*HUTCHINSON* (*Jonathan*), *remarks* in the DISCUSSION ON LARDACEOUS DISEASE 528
HYDROPHOBIA and TETANUS, on the pathology of (James Ross) . 215
HYPERTROPHY and ATROPHY, changes in sweat glands, illustrating the pathology of (G, Hoggan) . . . . . 421

ILEUM, perforating ulcers of, from obstruction after ovariotomy (A. Doran) 298
INJECTION, PURULENT, see *Pyæmia* (Report of Committee).
INTESTINAL OBSTRUCTION after ovariotomy, perforating ulcers of ileum from (A. Doran) . . . . . 298
INTESTINES, DISEASES of . . . . 297-309
IODIDE, see *Potassium*.
*IRVINE* (*J. Pearson*), dermoid cyst of the brain . . . 195
„ cases illustrating the lung changes caused by compression of the large bronchial tubes . . . . . 239

"JACOB'S ULCER," rodent cancer so known . . 360, 382
JAW, UPPER, small round-celled sarcoma of (W. J. Walsham) . . 410

JOINTS, see *Hip-joint, Knee-joint.*
*JONES* (*Sydney*), cured subclavian aneurysm . . , . 292

KIDNEYS, GRANULAR, in a case of fibroid phthisis, syphilitic? (J. F. Goodhart) 232
KIDNEYS, BLADDER &c., see *Urinary* organs.
KNEE-JOINT, backward dislocation of, with long-continued congestion, causing eczema squamosum of leg (H. G. Howse) . . . 454
*KRAUS* (*J.*), *per W, M. Ord*, cases of spontaneous disruption of vesical calculi, with report and chemical examination, by W. M. Ord . . . 314

LARDACEOUS DISEASE, DISCUSSION on its anatomical distribution and pathological relations, 1879 . . . . . 511-546
„ *opening address*, by W. Howship Dickinson, . . 511-517
„ *remarks* [analysis of the post-mortem records of the London Hospital, 1875-79], by F. Charlewood Turner . . . . . 517-525
„ — by W. S. Greenfield . . . . . 525-528
„ — by Jonathan Hutchinson . . . . . 528-530
„ — by P. H. Pye-Smith . . . . . 530-532
„ — by J. F. Goodhart . . . . . 532-535
„ — by Stephen Mackenzie . . . . . 335
„ — by Charles Ralfe . . . . . 536
„ *reply* by W. Howship Dickinson . . . . 537
*LEDIARD* (*Henry A.*), unusually large aneurysm of the ascending portion of the arch of the aorta, which burst externally . . . 284
„ aneurysm of the abdominal aorta, associated with disease of the aortic valves, death from uræmia . . . . . 288
*LEECH* (*D. J.*), Addison's disease with peculiar pigmentation . . 478
„ — microscopic examination of capsule, &c., by Dr. Dreschfeld . . 484
*LEES* (*D. B.*), see *Barlow* and Lees, Syphilitic lesions of cranial bones.
LEPROSY, EASTERN, on the condition of the lymphatics in (G. Hoggan) . 504
LEPROSY and CANCER, changes in the sweat glands in, as illustrating the extremes of atrophic and hypertrophic pathology (Geo. Hoggan) . . 421
*LEWIS* (*T. R.*), on hæmatozoa in the blood in chyluria, *Filaria sanguinis*, &c., reference to (Sir J. Fayrer and D. Power) . . . . 489
*LISTER* (*Joseph*), case of rodent ulcer, reference to (G. Thin) . . 376
„ description of his theories and methods in relation to antiseptic dressings (W. W. Cheyne) . . . . . 557
LIVER, cases of abscess of (N. Moore) . . . . 306
„ hypertrophic cirrhosis of, morbid anatomy of (R. Saundby) . . 301
LUNG, changes in, caused by compression of the large bronchial tubes (J. P. Irvine) 239
„ destructive changes in left, from compression of its bronchus by aneurysm of aorta (J. P. Irvine) . . . . . 241
„ ditto ditto (ditto) . . . . . 244
„ peculiar degeneration of, of uncertain nature (Sam. West) . . 220
„ gangrene and secondary suppuration in lower lobe, in a case of chronic lobar pneumonia (S. Coupland) . . . . . 224
„ disseminated caseous nodules in, in a case of fibroid phthisis (J. F. Goodhart) 232
„ obstructed circulation of, extreme congestion of brain due to (S. Coupland) 189
„ tubercle of the, two cases, spreading from yellow elastic nodules in the lung (gummata?) (J. F. Goodhart) . . . . . 233
„ invasion of right, by mediastinal tumour (R. D. Powell) . . 249

*LYELL* (*Robert*), progressive thrombosis of the veins of one lower extremity, with consecutive embolism of the pulmonary artery, from a case which had previously undergone an operation . . . . . 294
LYMPHADENOMATOUS TUMOURS of scalp and neck (W. M. Baker) . 417
LYMPHANGIECTODES, case of, with an account of the histology of the growth (T. Fox and T. C. Fox) . . . . . 470
„ — details of the changes of the epidermis, &c., in . . . 474
LYMPHATIC SYSTEM, diseases of . . . 478-510
LYMPHATICS, on their condition in Eastern leprosy (G. Hoggan) . 504
LYMPHOID TUMOURS, MULTIPLE, case in which some disappeared under observation (Jas. Gairdner and Jos. Coats) . . . . 387

*McCARTHY* (*Jeremiah*), see *Pyæmia* (Report of Committee on).
*MACKENZIE* (*Stephen*), *remarks* in the DISCUSSION ON LARDACEOUS DISEASE 535
MALFORMATION of the heart, congenital, three cases (H. R. Crocker) 273, 275-6
„ stenosis of pulmonary valve, with dilatation of the pulmonary artery and hypertrophy of right ventricle, &c. (D. W. Finlay) . . . 262
MALIGNANT DISEASE, see *Cancer*.
MAMMARY REGION, see *Breast*.
MANSON'S (Patrick) discoveries relative to hæmatozoa, reference to (Sir J. Fayrer and D. Power) . . . . . 489
*MASON* (*Francis*), congenital deformity of the foot [nine toes] . . 583
MAXILLA, SUPERIOR, osseous tumour of (J. F. Goodhart for B. Edwards) . 358
MEATUS URINARIUS, protrusion of orifice of ureter through, in a female child (N. Davies-Colley) . . . . . 310
MEDIASTINUM, see *Tumour* (Mediastinal).
MICROCOCCI in the blood in cases of pyæmia . . . 44
„ proportions of carbolic acid in cucumber infusion, in which they develop (W. W. Cheyne) . . . . . 578
MILK, on the nature of certain observed relations between diphtheria and (W. H. Power) . . . . . 546
„ ropy or garget, or cold in udder (A. H. Smee) . . . 551
MOLLUSCUM CONTAGIOSUM, the histology of (T. Fox and T. C. Fox) . 460
„ — references to writers on the subject . . . 460-461
MOLLUSCUM FIBROSUM (John Wood) . . . . 458
MOORE (Charles) on "rodent ulcer," reference to . . . 361
*MOORE* (*Norman*), rupture of the aorta within the pericardium . . 283
„ case of poisoning by sulphuric acid . . . . 297
„ cases of abscess of liver . . . . . 306
MORBID GROWTHS . . . . . 360-438
„ see *Committee* on.
*MORGAN* (*John H.*), acute disease of the hip-joint . . . 354
„ sarcoma of the scapula in an infant, followed by multiple sarcomata in various organs and tissues . . . . . 399
„ subperiosteal sarcoma of femur . . . . . 403
*MORISON* (*Alex.*), recto-vesical fistula, septicæmia, terminating fatally . 326
*MORRIS* (*Malcolm*), piedra, a new disease of the hair . . . 441
MOSQUITO, the, as intermediary host of the *Filaria sanguinis*, &c. (Sir J. Fayrer) . . . . . 493

MYELITIS, POLIO-, acute anterior, spinal cord from a case of, fatal in six weeks (F. C. Turner) . . . . . 202

NECK, blood-cyst removed from the (J. Gay) . . . 435
„ lymphadenomatous tumours of (W. M. Baker) . . . 417
NECROSIS, ACUTE, or infective periostitis, in pyæmia . . . 127
NERVOUS SYSTEM, DISEASES, &c., of . . . 189-219

OBSTRUCTION, see *Intestinal obstruction.*
*ORD* (*W. Miller*), *report* and chemical examination of J. Kraus's cases of spontaneous disruption of vesical calculi . . . . 315
„ *report* on specimens of spontaneous fracture of calculi within the bladder, exhibited by J. Croft . . . . . 318
„ see *Kraus*
ORGANISMS, on their relation to antiseptic dressings (W. W. Cheyne) . 557
*ORLEBAR* (*Hotham G.*), a case of three aneurysms arising from the descending aorta . . . . . 286
OSSEOUS SYSTEM, DISEASES, &c., of . . . 332-359
OSSEOUS LESIONS in hereditary syphilis (Jules Parrot) . . 339
OSTEOPHYTES, SYPHILITIC, osteoid and rachitic (Jules Parrot) . 343-348
OVARIOTOMY, perforating ulcers of ileum from obstruction after (A. Doran) 298

PAGET (Sir James), "case of rodent ulcer," reference to (G. Thin) . 379
PARALYSIS, INFANTILE, case of (H. Humphreys) . . . 211
„ — spinal cord from a case of (F. Taylor) . . . . 197
*PARROT* (*Jules*), les lésions osseuses de la syphilis héréditaire . . 339
*PARTRIDGE* (*S. Bowen*), description of specimens of elephantiasis arabum (Sir J. Fayrer and D. Power) . . . . . 488
*PEACOCK* (*T. B.*), case of stenosis of the pulmonary artery from disease of the valves, probably of congenital origin . . . . 258
„ disease of the aortic valves originating in congenital defect . . 277
PENIS, corpora cavernosa and spongiosum of, gangrene of, from thrombosis of iliac vein (?), consequent upon rheumatic phlebitis (J. Gay) . . 323
PERICARDIUM, rupture of the aorta within the (N. Moore) . . 283
PERIOSTITIS, INFECTIVE, in pyæmia . . . . 127
PERITONITIS in a case of cancerous ulcer of the colon (J. F. Goodhart) . 234
PHLEBITIS, SUPPURATIVE, of the vesical, iliac, and femoral veins of the left side, following cystitis (W. J. Walsham) . . . . 321
„ RHEUMATIC, thrombosis of the iliac vein consequent on (J. Gay) . 323
PHTHISIS, NODULAR FIBROID, syphilitic (J. F. Goodhart) . . 232
PIEDRA, specimen of the affection of the hair so described: trichoclasia or trichorrhexis nodosa (P. H. Pye-Smith) . . . . 439
„ a new disease of the hair (M. Morris) . . . . 441
PIGMENTATION, PECULIAR, in Addison's disease (D. J. Leech) . . 478
PNEUMONIA, DESTRUCTIVE, and compression of left bronchus by an aneurysm (J. P. Irvine) . . . . . 239
„ destructive, in left lung, from compression of its bronchus by aneurysm of aorta (J. P. Irvine) . . . . . 241
„ ditto ditto (ditto) . 244
„ CHRONIC LOBAR, grey indurating gangrene and secondary suppuration in lower lobe of lung (S. Coupland) . . . . . 224

PNEUMOTHORAX, two cases of the right side (S. West) . . 236
POISONING, case of, by sulphuric acid (N. Moore) . . . 297
POLIOMYELITIS, acute anterior, spinal cord from a case of, fatal in six weeks (F. C. Turner) . . . . . 202
POTASSIUM, iodide of, eruption, pustules removed from the back of the hand, in, microscopic examination (D. Duckworth and V. Harris) . . 476
*POWELL* (*R. Douglas*), mediastinal tumour invading the right lung and occluding its bronchi . . . . . 249
*POWER* (*D'Arcy*), see *Fayrer* and Power (Elephantiasis arabum).
*POWER* (*Henry*), *report* on Sir John Fayrer's two specimens of scrotal tumour 499
*POWER* (*W. H.*) *per G. Buchanan*, thoughts on the nature of certain observed relations between diphtheria and milk . . . . 546
PURULENT INFECTION, see *Pyæmia* (Report of Committee).
PUS, note on the injection of . . . . 152-155
PYÆMIA, septicæmia, and purulent infection, REPORT of the COMMITTEE appointed to investigate the nature and causes of (Charles H. Ralfe, M.D., W. S. Greenfield, M.D., Marcus Beck, and Jeremiah McCarthy) . . 1
PART I.—Sex and age; number of patients at each decade, 2.—Influence of season and meteorological condition; decennial return of deaths from pyæmia and septicæmia in eight London hospitals, 3.—Monthly death-rate at three London hospitals during decennial period, 5.—Relationship of pyæmia and septicæmia to erysipelas, 6.—Duration of disease and frequency of its occurrence after various surgical lesions, 6.—Analysis of 768 cases of pyæmia and septicæmia arising in six London hospitals, 7.
PART II.—Clinical: septicæmia, definitions of the term by Birch-Hirschfeld, Hueter, and Billroth, and references to other writers on septic intoxication and its *post-mortem* appearances, 8-16.—Septic infection without metastatic inflammation, 17.—*Post-mortem* appearances in ditto, 20-1.—Pyæmia: definitions, experiments, &c., 22-3.—Classification of the cases of pyæmia collected, in a series of ten groups, 24-37.—Summary of ditto, 38.
PART III.—Microscopical examination of blood, and chemical examination of the urine, made during life, 39-49.
PART IV.—Microscopic examination of organs, 49-59.
APPENDIX I.—Tables of details of fatal cases of pyæmia and septicæmia in the different London hospitals [by Chas. H. Ralfe, M.D.], 61-77.
APPENDIX II.—Table I. Cases of deaths from blood-poisoning without secondary inflammation, septic intoxication and septic infection, 80-7.—Table II. Pyæmia. Group I. No thrombosis, no abscesses in the viscera, 87-96.—Table III, Pyæmia. Group Ib. Cases with no thrombosis, but with visceral abscesses, 96-104.—Table IV. Pyæmia. Group II. Thrombosis apparently as a secondary effect of blood-poisoning, 104-6.—Table V. Pyæmia. Group III. Thrombosis and softening of the clot without the formation of secondary abscesses, 107-8.—Table VI. Pyæmia. Group IV. Thrombosis and softening of the clot without secondary abscesses in the lung, but with secondary inflammations elsewhere, 109-12.—Table VII. Pyæmia. Group V. Thrombosis and softening of clot, with abscesses in the lungs and other viscera, 112-17.—Table VIII. Pyæmia. Group VI. Thrombosis and softening of clot, with secondary abscesses only in the lung, 118-26.—Table IX, Group VII. Acute necrosis or infective periostitis, 127-31.—Table X, Group VIII. Ulcerative endocarditis, 132.—Table XI. Spontaneous pyæmia and septicæmia, 133-35 [by Marcus Beck].
APPENDIX III.—Notes of microscopical examination of blood during life, twenty-one cases, 137-49.—Note on microscopic examination of blood and organs with reference to Bacteria, 149-52.—Note on the injection of pus, 152-55 [by W. S. Greenfield, M.D.].
APPENDIX IV.—Notes of microscopical examination of organs, together with some special notes of cases; Nos. 1 to 12 examined by W. S. Greenfield, M.D.; Nos. 13 to 31 examined by Jeremiah McCarthy, 157-188.
*PYE-SMITH* (*P. H.*), specimen of the affection of the hair which has been described as piedra, and as trichoclasia or trichorrexis nodosa . . . 439
„ — *remarks* in the DISCUSSION ON LARDACEOUS DISEASE . . 530

RABIES of the dog (Edwards Crisp) . . . . . 584
*RALFE* (*Charles H.*), *remarks* in the DISCUSSION ON LARDACEOUS DISEASE . 536
„ — see *Pyæmia* (Report of Committee on)
RESPIRATION, ORGANS of, DISEASES, &c., of . . . 220-257

RHEUMATIC PHLEBITIS, thrombosis of the iliac vein consequent on (J. Gay) 323
RINGWORM, growth of the fungi in, compared with favus (Geo. Hoggan) . 444
RODENT ULCER (T. Fox and T. C. Fox) . . . . 360
„ further illustrations of the histology of (G. Thin) . . . 373
*ROKITANSKY* (*Carl*) two cases of defect in the ventricular septum of the heart, extracts from (S. Coupland) . . . . . 269
*ROSS* (*James*), on the pathology of tetanus and hydrophobia . . 215
RUPTURE of the aorta within the pericardium (N. Moore) . . 283

*SANGSTER* (*Alfred*) see *Bellamy* and Sangster (Cancerous ulcer of face.)
SARCOMA of the scapula in an infant, followed by multiple sarcomata in various organs and tissues (John H. Morgan) . . . . 399
„ — PRIMARY, of the supra-renal capsule, with secondary growth in the lung (S. West) . . . . . 419
„ MELANOTIC, of the eyeball (W. Spencer Watson) . . . 410
„ MULTIPLE, in various organs and tissues, following sarcoma of the scapula in an infant (John H. Morgan) . . . . . 399
„ MULTIPLE ROUND-CELLED, in a boy (lympho-sarcoma), sequel of a case of (H. T. Butlin) . . . . . 396
„ SMALL ROUND-CELLED, of the upper jaw (W. J. Walsham) . . 410
„ SUBPERIOSTEAL, of the femur (John H. Morgan) . . . 403
*SAUNDBY* (*Robert*), note on the morbid anatomy of hypertrophic cirrhosis of the liver . . . . . 301
SCALP, lymphadenomatous tumours of (W. M. Baker) . . . 417
SCAPULA, recurrent fibroid tumour of, removal (Ch. Heath) . . 405
„ sarcoma of, in an infant (John H. Morgan) . . . 399
SEPTICÆMIA in recto-vesical fistula, terminating fatally (A. Morison) . 326
„ see *Pyæmia* (Report of Committee).
SEPTUM, see *Heart*.
SKIN, DISEASES of . . . . . 439-477
„ disease in the horse; sebaceous tumours, erythema circumscriptum, and eczema (G. Thin) . . . . . 588
„ eruption from iodide of potassium, microscopical examination of pustules from (D. Duckworth and V. Harris) . . . . . 476
„ peculiar pigmentation of, in Addison's disease (D. J. Leech) . . 478
SKULL, see *Cranium*.
*SMEE* (*A. H.*), on garget or ropy milk, or cold in udder. . . 551
SPINAL CORD from a case of infantile paralysis (F. Taylor) . . 197
„ from a case of acute anterior poliomyelitis in a child, fatal in six weeks (F. C. Turner) . . . . . 202
STENOSIS of pulmonary artery from disease of the valves, probably of congenital origin (T. B. Peacock) . . . . . 258
„ of pulmonary valve, with dilatation of the pulmonary artery and hypertrophy of the right ventricle (D. W. Finlay) . . . . 262
„ PULMONARY, with dilated pulmonary artery above the stenosis (T. Barlow). 272
STOMACH, INTESTINES, &c., DISEASES of . . . 297-309
*STURGE* (*W. Allen*), hæmorrhage into the cerebellum, rupturing into the fourth ventricle . . . . . 194
SULPHURIC ACID, case of poisoning by (N. Moore) . . . 297
SUPPURATION, SECONDARY, and gangrene in lower lobe of lung (S. Coupland) 224

SUPRA-RENAL CAPSULES, two cases of early disease of; Addison's disease (J. F. Goodhart) . . . . . 486
„ Addison's disease of, with peculiar pigmentation (D. J. Leech) . 478
„ primary sarcoma of, with secondary growth in the lung (S. West) . 419
SWEAT GLANDS, changes in, in cancer and leprosy, as illustrating the extremes of atrophic and hypertrophic pathology (Geo. Hoggan) . . 421
SYNOVITIS, INCIPIENT, in hip-joint (A. E. Barker) . . . 353
SYPHILIS of the tonsil, chief points of distinction from cancer of tonsil (L. Browne) 409
— CONGENITAL, specimens of disease of skull in (T. Barlow) . . 333
„ — lesions of cranial bones in, three living cases (T. Barlow and D. B. Lees) 350
„ HEREDITARY, osseous lesions of (Jules Parrot) . . . 339
„ — gelatiniform and chondro-calcareous atrophy of bones in (Jules Parrot) 341
SYPHILITIC PHTHISIS, nodular fibroid (J. F. Goodhart) . . 232

TARCHANOFF (Jean), "experiments on frogs," referred to (G. Hoggan) . 509
*TAYLOR* (*Frederick*), spinal cord from a case of infantile paralysis . 197
TETANUS and HYDROPHOBIA, on the pathology of (Jas. Ross) . . 215
THIERSCH "on epithelial cancer," reference to (G. Thin) . 378, 382
*THIN* (*George*), further illustrations of the histology of rodent ulcers . 373
„ skin disease in the horse: sebaceous tumours, erythema circumscriptum, and eczema . . . . . 588
*THOMSON* (*Dr. Alex.*), notes of a case of multiple lymphoid tumours (with post-mortem examination), see *Gairdner* and Coats.
THROMBOSIS of the veins of one lower extremity with consecutive embolism of the pulmonary artery (R. Lyell) . . . . 294
„ of iliac vein, gangrene of corpora cavernosa and spongiosum penis from (J. Gay) 323
„ and softening of clot in the lung in pyæmia, table of . . . 118
TOES, foot with nine (F. Mason) . . . . . 583
TONSIL, primary epithelioma of; living specimen (L. Browne) . . 407
„ chief points of distinction in the clinical history of cancer and syphilis of (L. Browne) . . . . . 409
TRICHOCLASIA, affection of the hair so described (P. H. Pye-Smith) . 439
TRICHORREXIS NODOSA, affection of the hair so described (P. H. Pye-Smith) 439
TRICUSPID VALVES, case of warty growth on (H. R. Crocker) . . 281
TUBERCLE of the lung, two cases, spreading from yellow elastic nodules in the lung (gummata?) (J. F. Goodhart) . . . . 233
TUMOUR, RECURRENT FIBROID, of the scapula; removal (Chr. Heath) . 405
„ LYMPHADENOMATOUS, of scalp and neck (W. Morrant Baker) . . 417
„ MEDIASTINAL, invading the right lung and occluding its bronchi (R. D. Powell) 249
„ MULTIPLE (lymphoid?), case in which some disappeared under observation (Jas. Gairdner and Jos. Coats) . . . . . 367
„ — see *Sarcoma*.
„ OSSEOUS, of superior maxilla (J. F. Goodhart for B. Edwards) . . 358
„ SEBACEOUS, in the horse (G. Thin) . . . . 588
*TURNER* (*F. Charlewood*), portion of the spinal cord from a case of acute anterior poliomyelitis in a child, fatal within six weeks from the onset . . 202
„ *remarks* in the DISCUSSION ON LARDACEOUS DISEASE . . 517

ULCER, CANCEROUS, of the face (E. Bellamy and A Sangster) . . 371
„ PERFORATING, of the ileum, from obstruction after ovoriotomy (A. Doran) 298

ULCER, RODENT (T. Fox and T. C. Fox) . . . . 360
„ — further illustrations of the histology of (G. Thin) . . . 373
URÆMIA, death from, in a case of aneurysm of the abdominal aorta (H. A. Lediard) 288
URÆMIC CONVULSIONS in a case of syphilitic tubercle of the lung (J. F. Goodhart . . . . . 233
URETER, protrusion of orifice of, through meatus urinarius in a female child (N. Davies-Colley) . . . . . 310
URINARY ORGANS, DISEASES, &c., of . . . 310-331
URINE, chemical examination of, in cases of pyæmia . . . 48

VALVES, see *Aortic*, *Tricuspid*.
VASCULAR SYSTEM, DISEASES, &c., of . . . 258-296
VEINS, suppurative phlebitis of the vesical, iliac, and femoral, on the left side, following cystitis (W. J. Walsham) . . . . . 321
„ progressive thrombosis of those of one lower extremity, with consecutive embolism of the pulmonary artery (R. Lyell) . . . . 294
„ ILIAC, thrombosis of, causing (?) gangrene of the corpora cavernosa and spongiosum penis (J. Gay) . . . . . 323
VENTRICLES, see *Heart*.

*WALSHAM* (*W. J.*), suppurative phlebitis of the vesical, iliac, and femoral veins of the left side, following cystitis . . . . . 321
— small round-celled sarcoma of the upper jaw . . . 410
WARREN (C.), case of rodent ulcer, reference to (G. Thin) . . 386
WARTY GROWTH on tricuspid valves, case of (H. R. Crocker) . . 281
*WATSON* (*W. Spencer*), specimen of melanotic sarcoma of the eyeball . 410
*WEST* (*Samuel*), a peculiar degeneration of the lung of uncertain nature . 220
— two cases of pneumothorax of the right side . . . 236
— primary sarcoma of the supra-renal capsule, with secondary growth in the lung 419
WILKS (Samuel), first description in English of piedra in 1859, referred to . 439
*WOOD* (*John*), *per Royes Bell*, molluscum fibrosum . . . 458
WOUND, PENETRATING, of the heart, involving transfixion of both ventricles, but not causing death for several minutes (J. P. H. Boileau) . . 278

PRINTED BY J. E. ADLARD, BARTHOLOMEW CLOSE.

3365 151 12